

CONE-BEAM COMPUTED TOMOGRAPHY STUDY OF THE ROOT CANAL MORPHOLOGY OF MANDIBULAR ANTERIOR TEETH IN SERBIAN POPULATION

Milica Popovic, Milos Papić, Suzana Zivanovic, Aleksandar Acovic, Slobodan Loncarevic, Vladimir Ristic
Department of Dentistry, Faculty of Medical Sciences, University of Kragujevac, Kragujevac, Serbia

KOMJUTERIZOVANA TOMOGRAFIJA KONUSNOG ZRAKA U ISPITIVANJU MORFOLOGIJE KORENSKOG KANALA PREDNJIH ZUBA DONJE VILICE U SRPSKOJ POPULACIJI

Milica Popović, Miloš Papić, Suzana Živanović, Aleksandar Acović, Slobodan Lončarević, Vladimir Ristić
Odsjek za Stomatologiju, Fakultet medicinskih nauka, Univerzitet u Kragujevcu, Kragujevac, Srbija

Received / Priljen: 10. 03. 2017.

Accepted / Prihvaćen: 30. 04. 2017.

ABSTRACT

The aim of this study is to describe the morphological characteristics, the number of roots and number of root canals of mandibular central incisors, lateral incisors and canines, and the relationship of these characteristics with the sex and the jaw side where the tooth is located, in the Serbian population using cone-beam computed tomography (CBCT).

CBCT images of a total of 902 mandible front teeth, including 296 central incisors, 294 lateral incisors and 312 canines were analyzed in the database. For assessing the morphology of the root canal, Vertucci method of classification was used.

Central incisors had two canals in 27%, similar as lateral incisor which had two canals in 26.5%. Mandibular canines had two canals in 7.1% and there was a significant difference between genders. The most prevalent root canal configuration type in all mandibular anterior teeth was type I. In the groups of mandibular incisors with two root canals the most common was type III. In the group of mandibular canines with two root canals, type V had the greatest occurrence.

Most mandibular anterior teeth had one root canal. Two root canals were found in 27% of the mandibular incisors. There is a significant difference in root morphology between genders. It is important for dental practitioner to expect different morphological variations when performing endodontic treatment. More studies are needed to further define morphological characteristics of roots of mandibular anterior teeth in Serbian population.

Keywords: Cone beam computed tomography, mandibular incisors, mandibular canines, root canal configuration, root canal morphology

SAŽETAK

Cilj ove studije je da koristeći komjuterizovanu tomografiju konusnog zraka (CBCT) opiše morfološke karakteristike, broj korena i korenskih kanala centralnih i lateralnih sekutića i očnjaka donje vilice u srpskoj populaciji, kao i da utvrdi korelaciju ovih karakteristika sa polom i stranom vilice u kojoj je zub lokalizovan.

CBCT snimci 902 prednja zuba donje vilice, uključujući 296 centralnih i 294 lateralnih sekutića i 312 očnjaka su analizirani iz baze podataka. Za procenu morfologije korenskog kanala upotrebljen je Vertučijev metod klasifikacije.

Centralni sekutići su imali dva kanala u 27% slučajeva, slično kao i lateralni sekutići koji su imali dva kanala u 26,5% slučajeva. Očnjaci su imali dva kanala u 7,1% slučajeva, pri čemu je bilo značajnih razlika između polova. Preovlađujući tip konfiguracije korenskog kanala svih prednjih zuba donje vilice je bio tip I. U grupi sekutića koji su imali dva kanala najčešći tip konfiguracije je bio tip III. U grupi očnjaka koji su imali dva kanala preovladavao je tip V.

Većina prednjih zuba donje vilice je imala jedan korenski kanal. Dva korenska kanala su pronađena u 27% slučajeva kod sekutića. Postoji značajna razlika u morfologiji korena između polova. Za stomatologa je važno da očekuje različite morfološke varijacije tokom izvođenja endodontskih zahvata. Potrebno je sprovesti više studija za dalje definisanje morfoloških karakteristika korena prednjih zuba donje vilice u srpskoj populaciji.

Ključne reči: Komjuterizovana tomografija konusnog zraka, mandibularni sekutići, mandibularni očnjaci, konfiguracija korenskog kanala, morfologija korenskog kanala





INTRODUCTION

The knowledge of the internal morphology of the roots of the teeth is an essential prerequisite for the successful implementation of endodontic therapy. One of the causes of failure of endodontic therapy is omission of one or more root canals, whose presence was not observed. Most common reason for the omission of endodontic root canal therapy is the morphological variations of the tooth root canal system (1).

In studies of the morphology of roots, different methods of evaluating the internal structure of teeth in clinical and laboratory conditions can be used (2-4). Standard methods of observing the internal morphology of the teeth, in clinical terms, involves the use of retro alveolar radiological examinations. Main disadvantage of this technique is reduction of a three-dimensional object to two-dimensional image, also, features superimposed roots and roots of teeth with each other and with the adjacent anatomical structures, which can give a false idea of internal morphology of the teeth (2). In clinical practice, in addition to retro alveolar radiological examinations, inspection with loupes or/and operating microscope enhance canals inspection (3). In experimental conditions, various method can be used: colouring teeth (clearing and staining technique) and cutting (cross section) and digital radiological examinations, but these methods requires the use of extracted teeth with no signs of pathological changes (usually extracted for orthodontic reasons), thus obtaining samples of younger respondents which may affect the final results (4). In last decade, for the assessment of the internal morphology of the roots computed tomography with cone beam (Cone Beam Computer Tomography, CBCT) is used, which provides an overview of the object of interest in three dimensions without the superimposition of anatomical structures from different angles and planes (axial, sagittal, and coronal) (5).

Numerous studies have demonstrated that the anterior teeth (central incisors, lateral incisors and canines) in the mandible can significantly vary in the root canal configuration (6-8). There are differences in the root canal morphologies in different populations. *Altunsoi et al.* announced that in the Turkish population the most common finding is a single canal of root canal in the mandibular anterior teeth with a range of 77-95%, and then the two canals with a range of 5.3-18.9%. In the same CBCT study, type I canal configuration of Vertucci is the most widespread in the mandibular anterior teeth 77-95%, and then the configuration type V was observed in the range of 1.8-14.4% (6). In studies performed by using the CBCT, *Liu et al.* reported that the type I canal configuration of the lower central and lateral incisors were 91.1% and 82.5% in the Chinese population (7). *Aminsobhani et al.* reported that the type I configuration canal for central, lateral incisors and canines are 72.7%, 70.6% and 71.8%, in the Iranian population (8).

There are many studies examining the morphological characteristics of the mandibular anterior teeth using

CBCT (6-14). In the Serbian population such morphological studies were not conducted.

The aim of this study is to describe the morphological characteristics, the number of roots and number of root canals of mandibular central incisors, lateral incisors and canines, and the relationship of these characteristics with the sex and the jaw side where the tooth is located, in the Serbian population using CBCT.

MATERIAL AND METHODS

The study protocol was approved by the Ethics Committee of the Faculty of Medical Sciences, University of Kragujevac, Serbia and the research was carried out respecting the Declaration of Helsinki and Good Clinical Practice guidelines.

CBCT images of a total of 902 mandible front teeth, including 296 central incisors, 294 lateral incisors and 312 canines were analyzed in the database.

For the purposes of retrospective study we used the CBCT images made in Radiological department, Faculty of Medical Sciences, University of Kragujevac, between September 2014 and October 2016. The scans were obtained using Orthophos XG 3D device (Sirona Dental Systems GmbH, Bensheim, Germany), with three-dimensional settings for recording, VOL1 or VOL1 HD, and a voxel size of 160µm; the layer thickness were 0.16mm and size of observed field (Field of view, FOV) was 5x8x8 cm. The reasons for CBCT scanning were different (prosthetic, surgical, orthodontic and endodontic).

The main images inclusion criterion was the existence of at least one permanent incisor and canine in the mandible. Other Inclusion criteria were following: 1) tooth is fully visible; 2) have completed root growth; 3) have no radiologically visible periapical lesion; 4) have no radiologically visible external or internal root resorption; 5) are not treated endodontically and 6) have no prosthetic restorations.

CBCT images were analyzed using a software program GALAXIS v1.9.4 (Sirona Dental Systems GmbH, Bensheim, Germany), in the axial, sagittal, and coronal sections (Figure 1.) Observations were conducted at Philips LED monitor size 23-inch image with a resolution of 1920 x 1080 pixels in a room with dim lighting. Brightness and contrast are adjusted using a software program.

On CBCT scans we observed following:

- o The root number for each tooth
- o The root canals number
- o Position of the tooth- left or right side of the mandible
- o The root canal configurations of Vertucci classification

For the classification of the morphology of the root canal was a used Vertucci method of classification (15):

Type I: A single canal appears from the pulp chamber to the apex.

Type II: Two separate canals leave the pulp chamber but merge into one to the exit.

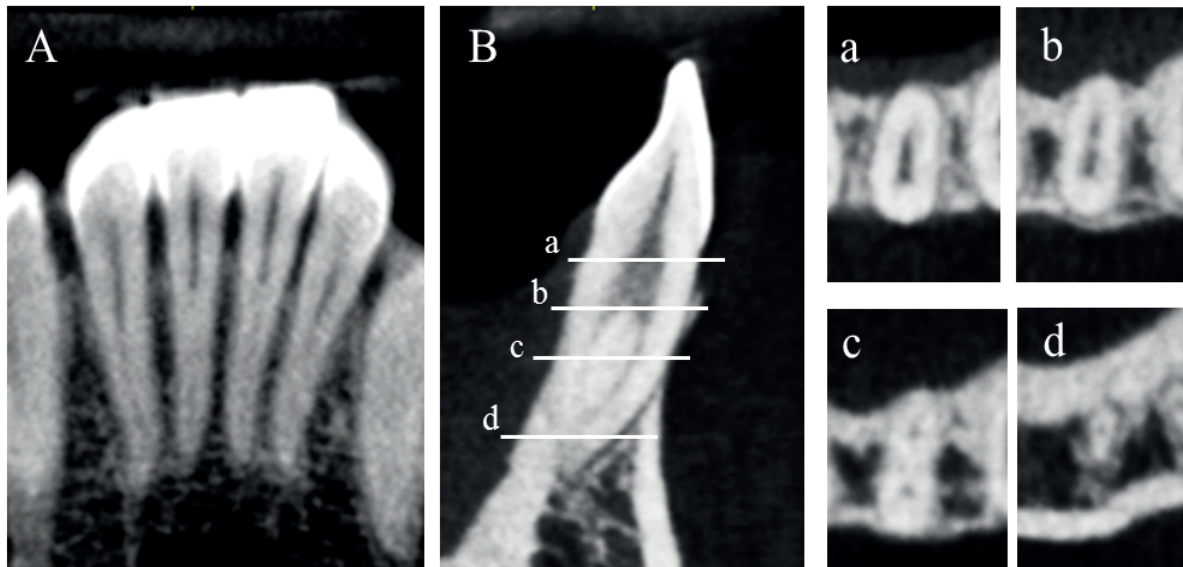


Figure 1. A CBCT image of a mandibular incisor with type III Vertucci root canal configuration. Image A shows a coronal section view of mandibular incisors, image B shows sagittal section view of mandibular central incisor. Different axial section views are shown on images a, b, c, d. Notice how in coronary part of the root, a root canal starts as a single (a), then separates into two canals (b, c) and finishes as one root canal at the apex (d).

- Type III: A single canal leaves the pulp chamber, divides into two within the root, and then merges to the exit.
- Type IV: Two distinctly separate canals are present from the pulp chamber to the apex.
- Type V: A single canal leaves the pulp chamber but divides into two.
- Type VI: 2 separate canals leave the pulp chamber, join at the midpoint, and then divide again into two with two separate apical foramina.
- Type VII: One canal leaves the pulp chamber, divides and then rejoins within the root, and finally redivides into two separate canals with two separate apical foramina.
- Type VIII: Three separate and distinct canals begin from the pulp chamber to the root apex.

Different types of root canal configuration by Vertucci classification is shown in Figure 2.

An additional analysis of statistical data was performed using a commercial software package SPSS v20.0 for Statistics (SPSS Inc., Chicago, IL, USA). The frequency of the

number of roots, the canal number and morphology of root canal root are described using measures of descriptive statistics: frequency, percentage, mean (average), median, standard deviation (SD) and scope (range). The frequencies of the different parameters and correlations were analyzed between the sexes and side of the jaw where the tooth is located. Chi-square (χ^2) test was used to compare the frequency (frequency) of categorical variables and to demonstrate statistical significance. All results where the probability of the null hypothesis was less than 5% ($p < 0.05$), were considered statistically significant.

RESULTS

A total of 902 mandibular anterior teeth, including 296 central incisors, lateral incisors 294 and 312 canines, were observed.

All of the mandibular incisors had one root ($n=590$), while the incidence of two roots was 5.8% in the mandibular canine group ($n=312$). There was a statistically signifi-

Vertucci classification 1984							
Type I 1-1	Type II 2-1	Type III 1-2-1	Type IV 2-2	Type V 1-2	Type VII 2-1-2	Type VII 1-2-1-2	Type VIII 3-3

Figure 2. Different types of root canal configuration by Vertucci classification.



Table 1. Number of roots in mandibular anterior teeth

Tooth	Gender	Number of roots		Number of teeth
		One root	Two roots	
Mandibular central incisors	male	166 (100%)	0	166 (100%)
	female	130 (100%)	0	130 (100%)
	total	290 (100%)	0	290 (100%)
Mandibular lateral incisors	male	164 (100%)	0	164 (100%)
	female	130 (100%)	0	130 (100%)
	total	294 (100%)	0	294 (100%)
Mandibular canines*	male	160 (97.6%)	4 (2.4%)	164 (100%)
	female	134 (90.5%)	14 (9.5%)	148 (100%)
	total	294 (94.2%)	18 (5.8%)	312 (100%)

*Statistical significance at the level of $p=0.013$

cant difference between the number of roots and gender ($p<0.05$, $p=0.013$), where two-rooted canines occur more often among females ($n=14$) than males ($n=4$) (Table 1).

Most mandibular anterior teeth had one root canal. Central incisors had two canals in 27%, similar as lateral incisor which had two canals in 26.5%. There was no significant differences in distribution of number of root canals of central and lateral incisors between the genders ($p>0.05$; $p=0.066$ and $p=0.595$ respectively), although the number of teeth with two root canals was higher among males (52:28 for central, 46:32 for lateral incisors). Mandibular canines had two canals in 7.1% and there was a significant difference between genders ($p<0.05$, $p=0.015$), where two canals were more prevalent among females than males (16 versus 6 teeth respectively) (Table 2).

According to Vertucci classification, the most prevalent root canal configuration was type I in all teeth groups (central incisors 73%, lateral incisors 73.5%, and canines 92.9%). Among the central incisors with two root canals the most common was type III, followed by type II and type IV

(21.6%, 4.7% and 0.7% respectively). Other types were not observed. In the group of lateral incisors, after type I, most prevalent configuration type was type III, then type II, type V and type IV (18.4%, 5.4%, 2% and 0.7% respectively). Type VI and type VII were not observed. In the group of two-canaled mandibular canines, the most common was the type V (5.8%), while of the other types only types II and III were observed in 0.6% each. The difference in the frequency of different configuration types and gender was only significant in the group of mandibular canines, where the type V was more frequently seen in females (Table 3). There was no statistically significant difference between any parameter and side of the jaw where the tooth is located.

DISCUSSION

In previous studies of root morphology, different *in vitro* and *in vivo* methods were used to assess the inter-

Table 2. Number of root canals in mandibular anterior teeth

Tooth	Gender	Number of root canals		Number of teeth
		One root canal	Two root canals	
Mandibular central incisors	male	114 (68.7%)	52 (31.3%)	166 (100%)
	female	102 (78.5%)	28 (21.5%)	130 (100%)
	total	216 (73.0%)	80 (27.0%)	296 (100%)
Mandibular lateral incisors	male	118 (72.0%)	46 (28.0%)	164 (100%)
	female	98 (75.4%)	32 (24.6%)	130 (100%)
	total	216 (73.5%)	78 (26.5%)	294 (100%)
Mandibular canines*	male	158 (26.3%)	6 (3.7%)	164 (100%)
	female	132 (89.2%)	16 (10.8%)	148 (100%)
	total	290 (92.9%)	22 (7.1%)	312 (100%)

*Statistical significance at the level of $p=0.015$



Table 3. Distribution of root canal types of mandibular anterior teeth

Tooth	Sex	Vertucci classification					Number of teeth
		Type 1	Type 2	Type 3	Type 4	Type 5	
Mandibular central incisors	male	114 (68.7%)	12 (7.2%)	38 (22.9%)	0 (0%)	2 (1.2%)	166 (100%)
	female	102 (78.5%)	2 (1.5%)	26 (20.0%)	0 (0%)	0 (0%)	130 (100%)
	total	226 (73.0%)	14 (4.7%)	64 (21.6%)	0 (0%)	2 (0.7%)	296 (100%)
Mandibular lateral incisors	male	118 (72.0%)	8 (4.9%)	36 (22.0%)	0 (0%)	2 (1.2%)	164 (100%)
	female	98 (75.4%)	8 (6.2%)	18 (13.8%)	2 (1.5%)	4 (3.1%)	130 (100%)
	total	216 (73.5%)	16 (5.4%)	54 (18.4%)	2 (0.7%)	6 (2.0%)	294 (100%)
Mandibular canines*	male	158 (96.3%)	0 (0%)	2 (1.2%)	0 (0%)	4 (2.4%)	164 (100%)
	female	132 (89.2%)	2 (1.4%)	0 (0%)	0 (0%)	14 (9.5%)	148 (100%)
	total	290 (92.9%)	2 (0.6%)	2 (0.6%)	0 (0%)	18 (5.8%)	312 (100%)

*Statistical significance at the level of $p=0.011$

nal structure of the tooth roots. *In vitro* methods used in previous studies include the use of clearing and staining techniques, cross sectioning, stereomicroscopy, radiography and micro computed tomography, but their implementation requires tooth extraction (15, 16-21). Dental retro alveolar radiographs were used in clinical examination, but this method is less accurate for assessing internal tooth morphology than others because it shows the complex structure of an object as a two-dimensional image (22). CBCT is a newer, non-invasive radiological methods for observation of orofacial structures, which is used for assessing external and internal morphology of the roots *in vitro* (9) as well as *in vivo* (6, 8, 10-14). CBCT was shown to be as accurate as the gold standard (clearing and staining technique) (23). In this study, data were collected by analysing CBCT images.

Knowing the number of roots of the teeth is important because it is most common for mandibular anterior teeth to have one root (15). In this study, out of 584 mandibular incisors, all had one root, which is equal to the results in the study of Han *et al.*, Lin *et al.*, and Aminsobhani *et al.* who used the same method for analysing the teeth roots (8, 11, 12). By using clearing and staining techniques Rahimi

et al. also showed one root in all mandibular incisors (16). A smaller number of two-rooted lateral incisors (0.3%) were found by Zhengyan *et al.* (13). The results of the number of roots of mandibular canines in earlier studies vary from 0.8% to 12% (8, 11-14, 16). Our results show the incidence of two roots in a group of mandibular canines to be 5.8% and we also showed more frequent occurrence of two roots in females ($p<0.05$). The percentage of number of roots in previous studies comparing to present study are shown in Table 4.

Analysis of the number of root canals in mandibular incisors showed the incidence of one canal to be 73% for the central and 73.5% for lateral incisors. In previous studies that used the clearing and staining technique the frequency of one root canal in mandibular incisors ranged from 62% to 75% (15-18). Studies on CBCT showed the frequency of one canal in rage from 61% to 89% (6, 9-13). In this study, the frequency of two canals in the group of the mandibular canines was 7.1%, which is similar to the research of Rahimi *et al.* (8.4%, using clearing and staining) (16) and Altunsoy *et al.* (6.6%, using CBCT) (6). Statistical analysis did not show the difference in the number of root canals between the genders in mandibular incisors

Table 4. Percentage of number of roots found in mandibular anterior teeth in previous studies and present study

	Method	Central incisors		Lateral incisors		Canines	
		One root	Two roots	One root	Two roots	One root	Two roots
Rahimi <i>et al.</i> (16)	Clearing and staining	100	0	100	0	88	12
Lin <i>et al.</i> (11)	CBCT	100	0	100	0	/	/
Han <i>et al.</i> (12)	CBCT	100	0	100	0	98.7	1.3
Zhengyan <i>et al.</i> (13)	CBCT	100	0	99.7	0.3	99.2	0.8
Soleymani <i>et al.</i> (14)	CBCT	/	/	/	/	98.7	1.3
Aminsobhani <i>et al.</i> (8)	CBCT	100	0	100	0	96.3	4.7
Present study	CBCT	100	0	100	0	94.2	5.8



Table 5. Percentage of different root canal configuration types in central and lateral mandibular incisors found in previous studies and present study

	Method	Group of incisors	Sample	Vertucci classification (%)					
				Type I	Type II	Type III	Type IV	Type V	Other types
Vertucci (15)	Clearing and staining	Central	100	70	5	22	3	0	/
		Lateral	100	75	5	18	2	0	/
Rahimi et al. (16)	Clearing and staining	Central	186	64.5	18.3	16.7	0.5	0	/
		Lateral	128	61.7	16.4	21.1	0.8	0	/
Leoni et al. (21)	mCT	Central	50	50	0	28	0	0	22
		Lateral	50	62	0	28	0	0	10
Da Silva et al. (10)	CBCT	Central	200	64.5	0	18	0	14.5	3
		Lateral	200	60.5	0.5	25.5	0	12	1.5
Lin et al. (11)	CBCT	Central	706	89.1	2.4	6.2	1.7	0.6	/
		Lateral	706	74.5	3.7	19.3	2.1	0.4	/
Han et al (12)	CBCT	Central	1286	84.3	3.4	6.5	1.2	3.9	0.7
		Lateral	1294	72.6	4	15.5	2.3	5	0.4
Altunsoy et al. (6)	CBCT	Central	1582	84.5	0.3	0.8	4.2	10	/
		Lateral	1603	80.2	1.8	1.7	5.4	12.1	/
Zhengyan et al. (13)	CBCT	Central	3375	96.3	0.1	3.5	0.15	0.8	/
		Lateral	3257	89.4	1.05	7.7	0.3	1.15	/
Aminsobhani et al. (8)	CBCT	Central	632	72.7	11.3	4.7	7.7	3.6	/
		Lateral	614	70.6	7.1	3.7	15.4	3.2	/
Present study	CBCT	Central	296	73	4.7	21.6	0.7	0	/
		Lateral	294	73.5	5.4	18.4	0.7	2	/

although the central incisors with two canals were more prevalent in males (31.3%) than females (21.5%). Greater frequency of two canals of mandibular incisors in males was shown by *Lin et al.* (11). In the group of mandibular canines we showed a higher incidence of two root canals in females which is different from the study by *Soleymani et al.* who showed that two roots are more prevalent in males (14).

We used Vertucci classification into eight types for assessing root canal configuration (15), same as most of the previous studies (6, 8-21). In the group of mandibular central incisor with two root canals, the most common was type III in 21.6%. Among the other types, only type II (4.7%) and Type IV (0.7%) were observed. Study of *Vertucci* shows the frequency of type III in 22% and type II in 5%, while the type IV is shown to be more frequent than in our study (3%) (15). Similar results *Vertucci* showed for lateral incisors (type III 18%, type II 5% and type IV 2%) (15). In this study 18.4% of lateral incisors were type III, 5.4% were type II, 2% were type V and 0.7% were type IV. These results differ from study of *Altunsoy et al.* where the most prevalent were type V and type IV in the group of mandibular incisors (6). Study by *Han et al.* showed that among the incisors with two canals, the most common was type III, but with a lower percentage compared to our study (6.5% of central incisors and 15.5% of lateral incisors) (12). The percentage of different root canal configuration types by Vertucci classification of central and lateral man-

dibular incisors in previous studies and present study are shown in Table 5.

Vertucci in his study showed that in the group of the mandibular canines most common was type I (78%), followed by type II (14%), type IV (6%) and type III (2%) (15). Our data hasn't shown a greater diversity in the types of root canal configuration in canines. The most frequent was type I (94.2%), while out of other types significantly present was only type V (5.8%). The types II and III were only found in 2 teeth each, out of total 312 canines. The study of *Amaardeep et al.* who used CBCT on extracted teeth to analyse root canals, found morphological type I in the majority of teeth (79.6%) (9). In contrast to our study, the next most frequent type was the type III (13.6%), while the type V was present in lower percentage (2%) (9). *Pineda and Kuttler* used radiographic images of canines for analysing root canal morphology and also showed greatest occurrence of type I (81.5%), while the type II (13.5%) was the next most common (20). In a research conducted by *Zhengyan et al.*, the results for type I were mostly consistent with the results of our study (95.8%), but the type III was following by frequency (2.1%) (13). *Soleymani et al.* haven't found a significant difference between morphological types of root canals and gender (14), in contrast to our study, where we have shown that the type V was more common among female. Table 6. shows the occurrence of different root canal configuration types by Vertucci classification of mandibular canines in previous studies and present study.



Table 6. Percentage of different root canal configuration types in mandibular canines found in previous studies and present study

	Method	Sample	Vertucci classification (%)					
			Type I	Type II	Type III	Type IV	Type V	Other types
Vertucci (15)	Clearing and staining	100	78	14	2	6	0	/
Rahimi S. et al. (16)	Clearing and staining	149	91.6	6.1	2.3	0	0	/
Sert et al. (18)	Clearing and staining	200	76	15.5	6.5	1.5	0	/
Vaziri PB. et al (19)	Cross section	100	88	5	7	0	0	/
Pineda et al. (20)	Radiography	187	81.5	13.5	0	5	0	/
Da Silva E.J.N. et al. (10)	CBCT	200	90.5	1	4	2.5	2	/
Han et al (12)	CBCT	1291	93.7	0.6	3.3	0	0.5	/
Altunsoy M. et al. (6)	CBCT	1604	92.8	2.1	1.2	1.35	2.65	/
Zhengyan et al. (13)	CBCT	3014	95.8	0.7	2.1	0.2	0.4	/
Soleymani et al. (14)	CBCT	300	89.7	3.7	5.7	0	1	/
Aminsobhani et al. (8)	CBCT	608	71.8	10.3	2.8	12.8	2.3	/
Present study	CBCT	312	92.9	0.6	0.6	0	5.8	/

Previous studies have suggested that in considering number of roots and root canal configuration, other than technique used for evaluation, sex and ethnical background of sample may contribute to diversity in root morphology (6, 11, 13, 14, 18). Our study showed that in a group of mandibular incisors, a higher occurrence of two root canals was among males, while in a group of mandibular canines higher prevalence of two root canals was in females.

Root morphology varies in studies conducted in different countries and even in different regions of the same country (6, 8, 9, 11-14, 16-19). The studies carried out in a Turkish population showed that the incidence of single root canal in mandibular incisors can vary in a range from 36% to 85% (6, 18). In Chinese population the occurrence of two root canals of mandibular incisors in different studies was shown to be in range from 4% to 16% for central and from 11% to 27% for lateral incisors (11-13). Studies of mandibular canines in Iranian population showed that the prevalence of type I of root canal configuration can vary from 72% to 92% (8, 14, 16, 19). There aren't any previous studies of number of roots and/or root canal configuration of mandibular anterior teeth carried out on Serbian population.

CONCLUSION

The results of present study showed that around 27% of mandibular incisors have two root canals and that among incisor with two canals the most prevalent is the type III of Vertucci classification. This study also showed that the incidence of mandibular canines with two canals can be as high as 7.1%. These findings emphasize the importance of knowledge of variations in root canal morphology, since excluding the possibility of morphological variation can lead to failure in endodontic therapy. Also, patient's gender and ethnic origin should be con-

sidered when performing the preoperative evaluation of endodontic treatment. CBCT was shown to be a clinically useful tool for the detection of different root canal configurations. More studies are needed to further define morphological characteristics of roots of mandibular anterior teeth in Serbian population.

REFERENCES

1. Tabassum S, Khan FR. Failure of endodontic treatment: The usual suspects. *Eur J Dent.* 2016; 10(1):144-7.
2. Yu X, Guo B, Li KZ, et al. Cone-beam computed tomography study of root and canal morphology of mandibular premolars in a western Chinese population. *BMC Med Imaging.* 2012; 12:18.
3. de Toubes KM, Côrtes MI, Valadares MA, Fonseca LC, Nunes E, Silveira FF. Comparative analysis of accessory mesial canal identification in mandibular first molars by using four different diagnostic methods. *J Endod.* 2012; 38(4):436-41.
4. Beljić-Ivanović K, Teodorović N. Morphological characteristics of mesiobuccal root canals of the first maxillary molars. *Srpski arhiv za celokupno lekarstvo* 2010; 138(7-8):414-19.
5. Cotton TP, Geisler TM, Holden DT, Schwartz SA, Schindler WG. Endodontic applications of cone-beam volumetric tomography. *J Endod.* 2007; 33(9):1121-32.
6. Altunsoy M, Ok E, Nur BG, AglarciOS, Gungor E, Colak M. A cone-beam computed tomography study of the root canal morphology of anterior teeth in a Turkish population. *European Journal of Dentistry.* 2014; 8(3):302-6.
7. Liu J, Luo J, Dou L, Yang D. CBCT study of root and canal morphology of permanent mandibular incisors in a Chinese population. *Acta Odontol Scand.* 2014; 72:26-30.



8. Aminsobhani M, Sadegh M, Meraji N, Razmi H, Khara-zifard MJ. Evaluation of the root and canal morphology of mandibular permanent anterior teeth in an Iranian population by cone-beam computed tomography. *J Dent (Tehran)*. 2013; 10:358-66.
9. Somalinga Amardeep N, Raghu S, Natanasabapathy V. Root canal morphology of permanent maxillary and mandibular canines in Indian population using cone beam computed tomography. *Anat Res Int*. 2014; 2014:731859.
10. Da Silva EJ, de Castro RW, Nejaim Y, et al. Evaluation of root canal configuration of maxillary and mandibular anterior teeth using cone beam computed tomography: An in-vivo study. *Quintessence Int*. 2016; 47(1):19-24.
11. Lin Z, Hu Q, Wang T, et al. Use of CBCT to investigate the root canal morphology of mandibular incisors. *Surg Radiol Anat*. 2014; 36(9):877-82.
12. Han T, Ma Y, Yang L, Chen X, Zhang X, Wang Y. A study of the root canal morphology of mandibular anterior teeth using cone-beam computed tomography in a Chinese subpopulation. *J Endod*. 2014; 40(9):1309-14.
13. Zhengyan Y, Keke L, Fei W, Yueheng L, Zhi Z. Cone-beam computed tomography study of the root and canal morphology of mandibular permanent anterior teeth in a Chongqing population. *Therapeutics and Clinical Risk Management*. 2016; 12:19-25.
14. Soleymani A, Namaryan N, Moudi E, Gholinia A. Root Canal Morphology of Mandibular Canine in an Iranian Population: A CBCT Assessment. *Iran Endod J*. 2017; 12(1):78-82.
15. Vertucci FJ. Root canal anatomy of the human permanent teeth. *Oral Surg Oral Med Oral Pathol*. 1984; 58(5):589-99.
16. Rahimi S, Milani AS, Shahi S, Sergiz Y, Nezafati S, Lotfi M. Prevalence of two root canals in human mandibular anterior teeth in an Iranian population. *Indian J Dent Res*. 2013; 24(2):234-6.
17. Al-Qudah AA, Awawdeh LA. Root canal morphology of mandibular incisors in a Jordanian population. *Int Endod J*. 2006; 39(11):873-7.
18. Sert S, Bayirli GS. Evaluation of the root canal configurations of the mandibular and maxillary permanent teeth by gender in the Turkish population. *J Endod*. 2004; 30(6):391-8.
19. Bakianian Vaziri P, Kasraee S, Abdolsamadi HR, et al. Root Canal Configuration of one-rooted Mandibular Canine in an Iranian Population: An In Vitro Study. *Journal of Dental Research, Dental Clinics, Dental Prospects*. 2008; 2(1):28-32.
20. Pineda F, Kuttler Y. Mesiodistal and buccolingual roentgenographic investigation of 7,275 root canals. *Oral Surg Oral Med Oral Pathol*. 1972; 33(1):101-10.
21. Leoni GB, Versiani MA, Pécora JD, Damião de Sousa-Neto M. Micro-computed tomographic analysis of the root canal morphology of mandibular incisors. *J Endod*. 2014; 40(5):710-6.
22. Omer OE, Al Shalabi RM, Jennings M, Glennon J, Claffey NM. A comparison between clearing and radiographic techniques in the study of the root-canal anatomy of maxillary first and second molars. *Int Endod J*. 2004; 37(5):291-6.
23. Neelakantan P, Subbarao C, Subbarao CV. Comparative evaluation of modified canal staining and clearing technique, cone-beam computed tomography, peripheral quantitative computed tomography, spiral computed tomography, and plain and contrast medium-enhanced digital radiography in studying root canal morphology. *J Endod*. 2010; 36(9):1547-51.