

New Aspects of Melasma

Katerina DAMEVSKA¹*

¹University Clinic of Dermatology, Medical faculty, Ss Cyril and Methodius University, Skopje, Macedonia

*Correspondence: Katerina Damevska, E-mail: kate_damevska@yahoo.com

UDC 616.5-003.829-092

UDC 616.5-003.829:618.2]-08

DE GRUYTER
OPEN

Abstract

Melasma is a common cosmetic problem and its severity ranges from minor pigmentation during pregnancy that resolves spontaneously, to a chronic, troublesome, disfiguring condition. Today, there are various treatment modalities for melasma, providing a different success rate. The need for an effective treatment for melasma is becoming more and more significant probably due to the current lifestyles with increased UV exposure, broad use of hormones for contraception and hormone replacement therapy, as well as increasing esthetic demands. The mainstay of treatment is regular use of sunscreens along with topical medications suppressing melanogenesis. This review summarizes recent progress in understanding the pathophysiology of melasma and implications for new treatment strategies.

Key words

Melanosis; Dermatologic Agents; Hydroquinones; Sunscreening Agents; Skin Lightening Preparations; Laser Therapy; Diagnosis, Differential

Melasma is a common, acquired, circumscribed hypermelanosis of the face and occasionally of the neck and forearms, which significantly impacts the quality of life. Chloasma comes from the Greek term for “a green spot” and describes melasma during pregnancy or the “mask of pregnancy”.

Although it may affect any race, melasma is much more common in darker-skinned individuals (skin types IV to VI) (1). There are few prevalence studies on melasma, but there is evidence that the prevalence of this disorder differs among different ethnic groups. Melasma is more common in individuals of Hispanic, Oriental and Asian origin (2). The reported prevalence of melasma ranges from 8% among Latinas in the United States, to 30% in Southeastern Asian populations. Melasma is more prevalent in women, especially during their reproductive years, with the peak age between 20 and 30 years. It is rarely reported before puberty (3). Extra-facial melasma is more prevalent in postmenopausal women (4).

Etiology and pathogenesis

Etiopathogenesis of melasma is multifactorial and remains unclear. Genetic and hormonal factors and exposure to UV radiation are classical influencing factors. There are many other factors that may play a role in the etiology of melasma, such as ingredients in cosmetics, phototoxic and anti-seizure drugs, endocrine disorders (ie, ovarian or thyroid dysfunction), hepatic dysfunction, parasitoses, and nutritional deficiency. It is important to note that most cases of melasma in men and up to one third of cases in women are idiopathic (5).

Ultraviolet exposure is a major triggering and aggravating factor in the development of melasma, since it has a well known ability to stimulate proliferation of melanocytes, their migration, and melanogenesis (1). However, UV-induced hyperpigmentation usually recovers spontaneously, whereas melasma does not. Recently, Kim et al. detected down-regulation of the

H19 gene on microarray analysis of hyperpigmented and normally pigmented skin in patients with melasma (6).

Melasma is commonly reported in women using estrogen-progesterone oral contraceptives, hormone replacement therapy for prevention of osteoporosis, and in men using estrogen derivatives for treatment of prostatic cancer (7). The mechanism of induction of melasma by estrogen may be related to the presence of estrogen receptors on the melanocytes that stimulate cells to produce more melanin (8, 9). One study of melasma in patients who had never been pregnant or used hormone therapy, reported increased serum concentrations of luteinizing hormone (10). Sawney and Anand found a high prevalence of chronic pelvic inflammatory disease in women with melasma (11). These findings may implicate mild ovarian dysfunction as a possible cause of idiopathic melasma.

However, many observations strongly suggest the role of genetic factors. Familial occurrence of melasma has been reported to vary from 20% to 70% in different studies (12).

Characteristic clinical features of melasma are symmetry of hyperpigmentation and distribution related to trigeminal nerves, which suggest that the neural involvement may play a role in the pathogenesis of pigmentation. Bak et al. found higher levels of neural endopeptidase in melasma lesions and suggest that neuroactive molecules, including nerve growth factor, are critical factors for the pathogenesis of melasma (13).

It is still unclear why certain areas of the face are predisposed to develop melasma, while others are not. Besides neural factors and hormone receptors, blood vessels may play a role. Human melanocytes may respond to angiogenic factors because normal human melanocytes express functional receptors for vascular endothelial growth factor (VEGF) (14). In some types of melasma, a pronounced telangiectatic erythema confined to melasma-lesional skin has been observed. Furthermore, increased vascularity is one of the major histologic findings in melasma (15). These findings may explain the effects of localized microinjection of plasmin inhibitor tranexamic acid, and good therapeutic efficacy of vascular lasers in the treatment of melasma (16).

Pathology

Few studies have investigated the histologic alterations in melasma lesions. Compared to uninvolved skin, the areas of hyperpigmentation showed increased deposition of melanin in the epidermis and dermis, as well as enlarged intensely stained melanocytes with prominent dendrites (17).

Clinical presentation

Clinically, melasma presents as a symmetrically distributed macular pigmentation with irregular borders, which can vary in color ranging from a light to dark brown or brown-gray. The number of hyperpigmented lesions may range from one single lesion to multiple patches located on the forehead, cheeks, dorsum of the nose, upper lip, chin, occasionally on the V-neck area and forearms. Pigmentation may be guttate or confetti-like, linear, or confluent; it evolves slowly over weeks or years. The hyperpigmented patches often fade in winter and get worse in the summer.

According to the distribution of lesions, there are three clinical patterns of melasma: centrofacial (65%), malar (20%), and mandibular (15%). The centrofacial pattern involves the forehead, cheeks, upper lip, nose, and chin; the malar pattern involves the cheeks and nose, and mandibular the ramus of the mandible (18) (Figure 1).

Wood's lamp (320–400 nm) is used to determine the depth of melanin in the skin. Wood's light may also serve as a prognostic guide in the treatment of melasma, as the epidermal type of melasma is more likely to respond favorably to topical depigmenting agents. Common reasons for diagnostic failure are topical petrolatum and salicylic acid, lint and soap residues since these may fluoresce under Wood's light (19). Based on Wood's light examination, Sanchez et al. (20) classified melasma into four major clinical types, that show good correlation with the depth of melanin pigments:

1. Epidermal melasma is light brown; its color contrast is enhanced by Wood's light examination.
2. Dermal melasma is brown or bluish-gray by visible light; under Wood's light this

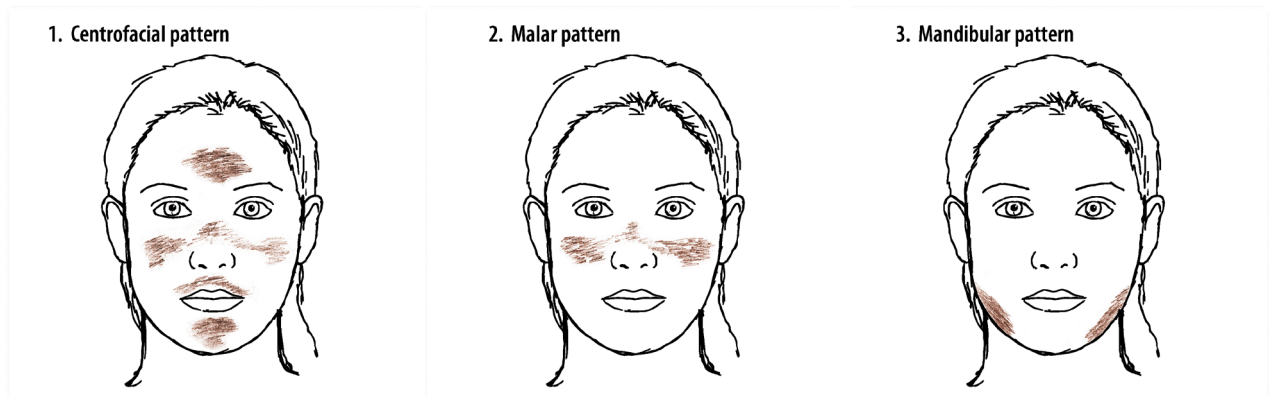


Figure 1. Different patterns of melasma

type expresses less distinct borders, with no enhancement of pigmentation.

3. Mixed melasma is dark-brown; enhancement of pigmentation is present under Wood's light in some areas, but not in all.

4. Indeterminate or inapparent melasma is found in individuals with dark-brown skin.

Wood's light does not localize the pigment. Since dermal melanin deposition may be unrecognized under Wood's light, diagnosis and treatment of patients with apparent epidermal melasma is still difficult (21).

Clinical outcome measures

The Melasma Area and Severity Index (MASI) is a common outcome measure, used to assess melasma patients. The severity of melasma in each of the four regions (forehead, right malar region, left malar region and chin) is assessed based on three variables: percentage of the total area involved (A), darkness (D), and homogeneity (H) (22).

Melasma has a significant negative impact on patients' health related quality of life (QoL), and severely affects social life, emotional well-being, and physical health (23). Several instruments have been developed to evaluate QoL in melasma patients. Such instruments need to undergo translation, validation and cultural adaptation (24).

Diagnosis

The diagnosis is clinical and an effort must be made with every patient to detect the individual risk factors

and triggers. However, a number of other conditions can mimic melasma (Table 1).

Therapeutical approaches

The aim of melasma treatment is to eliminate already existing pigmentation and to block de novo pigmentation. Numerous treatment options are currently available for melasma. The choice of treatment options of their combination depends mainly on the type of melasma, effectiveness of prior treatments, and expectations of the patient (25). New regimens aim to shorten and simplify the treatment. Difficulties in treatment of melasma arise from the following:

1. Melasma is often recalcitrant to treatment
2. High tendency for recurrence/reappearance
3. Risk of adverse events
4. Successful treatment requires long term patient compliance, because therapeutic effects usually become evident after 1-2 months
5. Treatment costs

The basic principles of melasma treatment include: retardation of proliferation of melanocytes, inhibition of melanosome formation, and enhancement of melanosome degradation.

Protection from sun exposure

Melanocytes in melasma are easily stimulated not only by UVB, but also by UVA and visible radiation. In order to maintain good treatment results and to prevent recurrences, one must make major lifestyle changes. Sunbathing is absolutely contraindicated, as a few minutes of sunbathing can reverse the benefit of

Table 1. Differential diagnosis of melasma

Disease/Condition	Differentiating Signs/Symptoms
Post inflammatory hyperpigmentation	Distribution of the eruption, history of inflammation
Cosmetic dermatitis (Riehl's melanosis)	Reddish-brown pigmentation, reticulate pattern
Poikiloderma of Civatte	Reddish-brown, reticulate pattern, atrophy, telangiectasias Distribution (anterior neck, sparing of submental region)
Hori's nevus	Bluish-gray pigmentation, distribution of macules
Drug induced facial pigmentation*	Phenothiazines, tetracyclines, phenytoin, antimalarials cytotoxic drugs, amiodarone
Actinic lichen planus:	Papular lesions, histology

*Hyperpigmentation is reversible but may take up to one year for complete resolution after stopping the drug

months of therapy. Sunscreens must be applied daily, during and after the treatment, throughout the sunny months of the year for an indefinite period (18). Sunscreens are crucial for sun protection, so the use of mineral sunscreens containing titanium dioxide or zinc oxide, with a sun protection factor (SPF) of 30 or higher, is mandatory.

Bleaching agents

Skin lightening or skin bleaching is the practice of using chemical substances in order to lighten the skin color or provide an even toned complexion. Bleaching agents act at various levels of melanin production in the skin, many of which act as competitive tyrosinase inhibitors, the key enzyme in melanogenesis. Others inhibit the maturation of this enzyme or the transport of melanosomes from melanocytes to the surrounding keratinocytes (26). The most important medical

indications for the use of lightening agents are melasma and postinflammatory hyperpigmentation, but also depigmenting conditions, like vitiligo.

There are three different categories of bleaching agents: phenolic compounds, non-phenolic compounds, and combination formulas (Table 2) (27). Some herbal extracts, flavonoids, coumarins and other derivatives are well known hypopigmenting agents (Table 2). Their classification is difficult, due to a great number of products and various mechanisms of action (28). In clinical practice, reflectance chromameters measure not only the skin color, and ultraviolet (UV)-induced pigmentation, but the bleaching effect of depigmenting agents.

Hydroquinone (HQ)

Hydroquinone (C₆H₆O₂) is the most commonly used bleaching agent and the gold standard for

Table 2. Treatment options for melasma

Category	Bleaching agent
Phenolic compounds	Hydroquinone (HQ)
	4-hydroxyanisole (Mequinol)
	N-acetyl-4-Scystaminyphenol (4-S-CAP)
Nonphenolic Compounds	Azelaic acid (AzA)
	Topical Retinoids
	L-ascorbic Acid (vit.C)
	Kojic acid
Chemical peels	Alpha-hydroxy acids (AHAs)
	Beta-hydroxy acid (BHA)
	Jessner's original and modified solutions
	Trichloroacetic acid
Device-Based Therapies	Intense pulsed light
	Lasers
	Microdermabrasion
Plant extracts/active agents	Arbutin, licorice extract, aloesin, oregonin, soy, green tea
	orchid extracts, coumoric acid, ellagic acid, liquirtin, gentisic
	acid, hesperidin, licorice, niacinamide, yeast derivatives
Others	Mercury, indomethacin, ZnSO ₄ , topical corticosteroids

melasma treatment. HQ inhibits the conversion of 3,4-dihydroxyphenylalanine (DOPA) to melanin by tyrosinase inhibition, and it also inhibits RNA and DNA synthesis in melanocytic cells, and degrades melanosomes (27). Since 2001, HQ has been banned in the European Union (EU) as an ingredient in cosmetics (29). The EU decision was based on its mid-term side effects, mainly exogenous ochronosis and leukoderma-en-confetti (30). During the past decade, concerns over the safety of HQ have increased. Its use has been connected with toxicity and mutagenicity, and an increased incidence of exogenous ochronosis (31). Although animal studies demonstrated its toxicity and/or mutagenic effects, these have not been proven in humans (32). In 2009, the Food and Drug Agency (FDA) renewed its call for additional studies on the safety of HQ. The request for evaluation focuses on uncovering the risks of skin disorders, cancer, and genetic mutations from HQ exposure in humans (33).

However, HQ over 2% can only be prescribed from a doctor's office. The effectiveness of HQ is related to the concentration of the preparation, to the vehicle used and the chemical stability of the product. Concentrations of HQ vary from 2% to as high as 10%. Several formulations are commonly prescribed by dermatologists, in order to reach the desired HQ concentration. HQ is easily oxidized, therefore, antioxidants such as 0.1% sodium bisulphate and 0.1% ascorbic acid should be used (34). The following formula can be prescribed: HQ 3-10% in hydroalcoholic solution (equal parts of propylene glycol and absolute ethanol) or hydrophilic ointment or as a gel containing 10% α -hydroxy acids (AHA) with ascorbic acid 0.1% as preservative. Side-effects of HQ mostly include irritant and rarely allergic contact dermatitis and postinflammatory hyperpigmentation. These side-effects are temporary and they resolve upon discontinuation of HQ. A very rare complication of HQ use is exogenous ochronosis, especially in darker phototypes (34).

Combination formulas

The skin lightening effects of HQ can be enhanced by adding various topical agents such as tretinoin and corticosteroids (Table 3). Tretinoin accelerates cell turnover, and facilitates epidermal penetration of HQ, moreover, it suppresses steroid atrophy, and prevents

HQ oxidation. Corticosteroids suppress melanin production, and eliminate the irritation caused by HQ and tretinoin (34).

Azelaic acid

Azelaic acid (AzA) is a naturally occurring byproduct of the metabolism of *Pityrosporum ovale* and is associated with hypomelanosis seen in tinea versicolor. *In vitro*, azelaic acid reversibly inhibits tyrosinase activity and may also interfere with mitochondrial oxidoreductase activity. Azelaic acid does not appear to affect normal melanocytes, but has an antiproliferative effect on abnormal melanocytes. AzA has antibacterial and anti-keratinizing activities. At 10–20% concentration, twice-daily application may treat melasma with minimal side effects; most patients report a mild but transient irritation of the skin at the beginning of treatment. A recent study suggests that 20% azelaic acid cream applied twice daily may be more effective than hydroquinone 4% in reducing mild melasma (35).

Kojic acid

Kojic acid is a fungal metabolite that inhibits catecholase activity of tyrosinase, used in a 1–4% cream base, alone or in combination with tretinoin, HQ, and/or corticosteroids. Although kojic acid alone is less effective than HQ 2%, (36) in combination with glycolic acid 10% and HQ 2%, it seems to have a synergistic action (37).

L-ascorbic acid (vitamin C)

Several forms of topical vitamin C are used to treat melasma in 5 to 10% concentrations and can be formulated with other depigmenting agents, such as HQ. Other advantages of vitamin C include antioxidant effects and photo protective properties. The weakness of ascorbic acid is its chemical instability and the hydrophilic nature limits its skin penetration. Magnesium ascorbyl phosphate, ascorbyl palmitate and sodium ascorbyl phosphate are stable derivatives of ascorbic acid. Iontophoresis has been used to promote percutaneous absorption of vitamin C into the skin (38).

Topical retinoids

Topical retinoids stimulate the cell turnover and promote rapid loss of melanin via epidermopoiesis. Retinoid-induced changes in the stratum corneum

Table 3. The most commonly used combination formulas

Formula	Comment
Kligman's and Willis formula* (5% HQ, 0.1% tretinoin, 0.1% dexamethasone) in ethanol and propylene glycol 1 : 1 or in hydrophilic ointment	Depigmentation begins within 3 weeks after the twice daily application used for a maximum of 5-7 weeks
Pathak's formula (2% HQ, 0.05–0.1% tretinoin)	By omitting steroids it has been suggested that they should be added only if irritation from HQ or tretinoin is observed
Westerhof's formula** (4.7% N-acetylcystein, 2% HQ, 0.1% triamcinolone acetamide)	The formula leads to significant bleaching within 4 to 8 weeks
Katsambas's formula*** (HQ 4%, tretinoin 0.05%, hydrocortisone acetate 1%) in ethanol and propylene glycol 1 : 1 or in hydrophilic ointment	The formulation should be dispensed in a 25-ml volume, in a dark-colored bottle with an airtight screw cap and it should be kept in a refrigerator at 2-4°C.

*, Formulation is not preserved by antioxidants, and therefore should never be more than 30 days old; HQ, hydroquinone; **, The mode of action of N-acetylcystein may be attributed to the intercellular increase of glutathione concentration that stimulates pheomelanin instead of eumelanin synthesis;***, By lowering the concentration of tretinoin and the use of a non-fluorinated steroid, the aim is to minimize the irritation caused by tretinoin and eliminate local steroid side-effects

facilitate the penetration of depigmenting agents in the epidermis, leading to increased depigmentation (39).

Tretinoin used at 0.05 – 0.1% concentrations, applied once nightly, can be effective as monotherapy, but requires 20 to 40-week treatment periods. The most common adverse effects include burning, erythema and scaling. Retinoid dermatitis may itself lead to postinflammatory hyperpigmentation, especially in dark-skinned individuals (40).

Adapalene 0.1% was found to be a safe and effective monotherapy in the treatment of epidermal melasma with a lower potential for skin-irritation compared to tretinoin (41).

A study confirms that the efficiency of tretinoin 1% peeling is similar to glycolic acid 70%, with very rare side-effects (42).

Chemical peels

Superficial chemical peeling agents are beneficial in the management of epidermal melasma and may be used in combination with other forms of melasma treatment. The peel solution is selected according to patient's needs, skin type and sensitivities. Because of their superficial action, superficial peels can be used in nearly all skin types (1).

Medium-depth peels may be an alternative treatment in refractory cases of severe melasma. All types of chemical peels, but mainly alpha-hydroxy acids, beta-hydroxy acid, salicylic acid, Jessner's original and modified solutions, and trichloroacetic acid are used alone or in combination with other depigmenting agents. It has to be emphasized that the response of melasma to chemical peels is rather unpredictable and there is a tendency for changes in pigmentation after chemical peel, especially in dark skinned individuals. Chemical peeling remains as an alternative modality for patients with melasma (34).

Laser and light therapies

Based on actual evidence, laser and light therapies show the best response in light-skinned patients, and are considered as third-line agents. Post inflammatory hyperpigmentation remains the most important side effect. Recurrences are common and are seen in up to 50% (1).

Melanosomes are the primary target of the laser-induced damage, and melanin is the main chromophore. Therefore it is important to choose

wavelengths between 630 nm and 1100 nm which are preferentially absorbed by melanin, and pulse duration between 40 ns and 750 ns (43).

Epidermal melasma can be treated with ablative lasers, such as carbon dioxide (CO₂) laser and erbium (Er):YAG laser. Non-ablative 1,550 nm fractional laser therapy has been reported to improve melasma (1).

Q-switched (QS) lasers deliver their energy in nanosecond pulses, hence they selectively target melanosomes. The 1064 nm QS-Nd:YAG is the most widely used laser for melasma. The number of treatments varies from 5 to 10 at 1-week intervals. Encouraging results have been observed in the treatment of the dermal-type melasma by using a novel 694-nm QS ruby fractional laser (44).

Melasma treatment with pulsed dye laser and the newer antiangiogenic lasers (copper bromide laser) is based on the theory that melasma occurs due to the interaction between cutaneous vasculature and melanocytes. These lasers can be used in patients with melasma and pronounced telangiectasia (45).

A combination of lasers can be beneficial for dermal melasma. Ablative lasers remove the epidermis; this can be followed by the use of the Q switched pigment selective laser which reaches deeper layers of the dermis (dermal melanophages) without causing serious side effects.

Intense pulsed light

Intense pulsed light (IPL) is a broadband light source that can target a wide range of cutaneous structures, including deeper pigmentation and vasculature (46).

A study by Figueiredo Souza et al. found that a single session of IPL combined with stable fixed-dose triple combination treatment is a safe and effective treatment for refractory mixed and dermal melasma (47). A new type of intense pulsed light with pulse-in-pulse (PIP) mode (multiple fractionated subpulses in one pulse width), may be a safe and promising treatment for melasma (48).

New and experimental treatments

Because of escalating concerns about HQ therapy (49), multiple novel agents are being investigated in melasma treatment. Aside from plant extracts, they also include mercury, indomethacin, zinc sulphate (ZnSO₄) and newer phenolic derivatives. At present,

there are no controlled studies investigating the efficacy and safety of these compounds. Although preliminary data showed beneficial effects of zinc for melasma, a recent study confirmed that topical zinc therapy is not highly effective in reducing the severity of melasma (50).

In recent years, the skin whitening industry has used complex mixtures of ingredients that target different mechanisms like tyrosinase expression, transfer of melanosomes, antioxidant and anti-inflammatory effects. Different commercially available whitening products contain various natural (glutathione; leukocyte extracts), particularly herbal ingredients, although information on some formulations are not always clear (51): Paper mulberry (*Broussonetia*

kazinoki); Mitracarpe (*Mitracarpus hirtus*) - the active ingredient is harounoside; Bearberry (*Arctostaphylos uva-ursi*) - the active ingredient is arbutin; Yellow dock (*Rumex crispus*); Licorice root (*Glycyrrhiza glabra*) - the active ingredient is glabridin; Yohimbe (*Pausinystalia Yohimbe*); Cang Zhu (*Atractylodes lancea*), Bai Xian Pi (*Dictamnus albus*); Hu Zhang (*Fallopia japonica*); Gao Ben (*Ligusticum rhizome*); Chuanxiong (*Rhizoma ligustici*); and Fang Feng (Radix sileris also Radix ledebouriella).

Table 4 shows melasma therapies, and level of evidence according to Rendon et al. (52).

Conclusion

At present, there is no universally effective treatment for melasma. The mainstay of treatment is use of

Table 4. Gradation of melasma therapies, due to the level of evidence. according to Rendon et al.

Level*	Therapeutic agent
1	4% HQ + 0.05% RA + 0.01% fluocinolone acetonide
2	4% HQ
3	0.1% tretinoin
4	4% HQ + 10% GA
5	20% Azelaic acid
6	20%-30% GA + 4% HQ
7	70% GA
8	Adapalene
9	2% HQ + 0.05% tretinoin + 0.1% dexamethasone (modified Kligman) + 30%-40% GA peel
10	2% HQ

*, decreasing from 1 to 10; HQ, Hydroquinone; RA, retinoic acid; GA, glycolic acid

sunscreens along with topical medications that suppress melanogenesis. Topical hydroquinone alone or in stable fixed-dose triple combination topical therapy is the first line of treatment; chemical peels are considered second-line therapy for refractory cases, and laser and light are considered the third-line treatment. Nowadays, there are no controlled studies investigating the efficacy and safety of multiple novel and experimental agents.

Abbreviations

UV – ultraviolet
 VEGF - vascular endothelial growth factor
 MASI - Melasma Area and Severity Index
 QoL - quality of life
 SPF - sun protection factor
 HQ - Hydroquinone
 DOPA - dihydroxyphenylalanine
 EU - European Unit
 FDA - Food and Drug Agency
 AHA - α -hydroxy acids
 AzA - azelaic acid
 CO₂ - carbon dioxide
 Er – erbium
 QS - Q-switched
 Nd – neodymium
 IPL - intense pulsed light
 PIP - pulse-in-pulse
 ZnSO₄ - zinc sulphate

References

- Rivas S, Pandya AG. Treatment of melasma with topical agents, peels and lasers: an evidence-based review. *Am J Clin Dermatol.* 2013 Oct;14(5):359-76.
- Ho SG, Chan HH. The Asian dermatologic patient: review of common pigmentary disorders and cutaneous diseases. *Am J Clin Dermatol.* 2009;10(3):153-68.
- Tamega Ade A, Miot LD, Bonfietti C, Gige TC, Marques ME, Miot HA. Clinical patterns and epidemiological characteristics of facial melasma in Brazilian women. *J Eur Acad Dermatol Venereol.* 2013; 27(2):151-6.
- Hexsel D, Lacerda DA, Cavalcante AS, Machado Filho CA, Kalil CL, Ayres EL, et al. Epidemiology of melasma in Brazilian patients: a multicenter study. *Int J Dermatol.* 2014;53(4):440-4.
- Wu IB, Lambert C, Lotti TM, Hercogová J, Sintim-Damoa A, Schwartz RA. Melasma. *G Ital Dermatol Venereol.* 2012 Aug;147(4):413-8.
- Kim NH, Lee CH, Lee AY. H19 RNA downregulation stimulated melanogenesis in melasma. *Pigment Cell Melanoma Res.* 2010 Feb;23(1):84-92.
- Perez-Bernal A, Munoz-Perez MA, Camacho F. Management of facial hyperpigmentation. *Am J Clin Dermatol.* 2000;1(5):261-8
- Kim NH, Cheong KA, Lee TR, Lee AY. PDZK1 upregulation in estrogen-related hyperpigmentation in melasma. *J Invest Dermatol.* 2012 Nov;132(11):2622-31.
- Lieberman R, Moy L. Estrogen receptor expression in melasma: results from facial skin of affected patients. *J Drugs Dermatol.* 2008 May;7(5):463-5.
- Perez M, Sanchez JL, Aguilo F. Endocrinologic profile of patients with idiopathic melasma. *J Invest Dermatol.* 1983;81(6):543-5.
- Sawhney M, Anand R. Chronic pelvic inflammatory disease and melasma in women. *Indian J Dermatol Venereol Leprol.* 2003;69(3):251-2.
- Ortonne JP, Arellano I, Berneburg M, Cestari T, Chan H, Grimes P, et al. A global survey of the role of ultraviolet radiation and hormonal influences in the development of melasma. *J Eur Acad Dermatol Venereol.* 2009 Nov;23(11):1254-62.
- Bak H, Lee HJ, Chang SE, Choi JH, Kim MN, Kim BJ. Increased expression of nerve growth factor receptor and neural endopeptidase in the lesional skin of melasma. *Dermatol Surg.* 2009 Aug;35(8):1244-50.
- Kim EJ, Park HY, Yaar M, Gilchrist BA. Modulation of vascular endothelial growth factor receptors in melanocytes. *Exp Dermatol.* 2005;14(8):625-33.
- Kim EH, Kim YC, Lee ES, Kang HY. The vascular characteristics of melasma. *J Dermatol Sci.* 2007;46(2):111-6.
- Lee JH, Park JG, Lim SH, Kim JY, Ahn KY, Kim My, et al. Localized intradermal microinjection of tranexamic acid for treatment of melasma in Asian patients: a preliminary clinical trial. *Dermatol Surg.* 2006;32(5):626-33.
- Grimes PE, Yamada N, Bhawan J. Light microscopic, immunohistochemical, and ultrastructural alterations in patients with melasma. *Am J Dermatopathol.* 2005;27(2):96-101.
- Katsambas A, Antoniou C. Melasma: classification and treatment. *J Eur Acad Dermatol Venereol.* 1995;4(3):217-23.
- Gupta LK, Singhi MK. Wood's lamp. *Indian J Dermatol Venereol Leprol.* 2004;70(2):131-5 .
- Sanchez NP, Pathak MA, Sato S, Fitzpatrick TB, Sanchez JL, Mihm Mc Jr. Melasma: a clinical, light microscopic, ultrastructural, and immunofluorescence study. *J Am Acad Dermatol.* 1981;4(6):698-710.
- Sheth VM, Pandya AG. Melasma: a comprehensive update: part I. *J Am Acad Dermatol.* 2011 Oct;65(4):689-97.
- Kimbrough-Green CK, Griffiths CE, Finkel LJ, Hamilton TA, Bulengo-Ransby SM, Ellis CN, et al. Topical retinoic acid (tretinoin) for melasma in black patients. A vehicle-controlled clinical trial. *Arch Dermatol.* 1994;130(6):727-33.
- Pawaskar MD, Parikh P, Markowski T, McMichael AJ, Feldman SR, Balkrishnan R. Melasma and its impact on health-related quality of life in Hispanic women. *J Dermatolog Treat.* 2007;18(1):5-9.
- Cestari TF, Hexsel D, Viegas ML, Azulay L, Hassun K, Almeida Ar, et al. Validation of a melasma quality of life questionnaire for Brazilian Portuguese language: the MelasQoL-BP study and improvement of QoL of melasma patients after triple combination therapy. *Br J Dermatol.* 2006 Dec;156 Suppl 1:13-20.
- Prignano F, Ortonne JP, Buggiani G, Lotti T. Therapeutical approaches in melasma. *Dermatol Clin.* 2007 Jul;25(3):337-42.
- Smit N, Vicanova J, Pavel S. The hunt for natural skin whitening agents. *Int J Mol Sci.* 2009 Dec 10;10(12):5326-49.

27. Katsambas AD, Stratigos AJ. Depigmenting and bleaching agents: coping with hyperpigmentation. *Clin Dermatol*. 2001 Jul-Aug;19(4):483-8.
28. Solano F, Briganti S, Picardo M, Ghanem G. Hypopigmenting agents: an updated review on biological, chemical and clinical aspects. *Pigment Cell Res*. 2006 Dec;19(6):550-71.
29. Twenty-fourth directive 2000/6/EG Publication nr L 056, European Union; 2000.
30. Westerhof W, Kooyers TJ. Hydroquinone and its analogues in dermatology – a potential health risk. *J Cosmet Dermatol*. 2005 Jun;4(2):55-9.
31. Enguita FJ, Leitão AL. Hydroquinone: environmental pollution, toxicity, and microbial answers. *Biomed Res Int*. 2013;2013:542168.
32. Gillner M, Moore GS, Cederberg H. International Programme on Chemical Safety Panel of Experts. Environmental Health Criteria 157: Hydroquinone. Available from: <http://www.inchem.org/documents/ehc/ehc/ehc157.htm>
33. U.S. Food & Drug Administration, Department of Health and Human Services. Nomination Profile: Hydroquinone [CAS 123-31-9]. Supporting Information for Toxicological Evaluation by the National Toxicology Program 21 May 2009. Available from: http://ntp.niehs.nih.gov/ntp/noms/support_docs/hydroquinone_may2009.pdf
34. Katsambas AD, Stratigos AJ, Lotti TM. Melasma. In: Katsambas AD, Lotti TM, editors. *European handbook of dermatological treatments*. 2nd ed. Berlin: Springer; 2003. p. 336–41.
35. Farshi S. Comparative study of therapeutic effects of 20% azelaic acid and hydroquinone 4% cream in the treatment of melasma. *J Cosmet Dermatol*. 2011 Dec;10(4):282-7.
36. Monteiro RC, Kishore BN, Bhat RM, Sukumar D, Martis J, Ganesh HK. A Comparative study of the efficacy of 4% hydroquinone vs 0.75% Kojic acid cream in the treatment of facial melasma. *Indian J Dermatol*. 2013 Mar;58(2):157.
37. Deo KS, Dash KN, Sharma YK, Virmani NC, Oberai C. Kojic acid vis-a-vis its combinations with hydroquinone and betamethasone valerate in melasma: a randomized, single blind, comparative study of efficacy and safety. *Indian J Dermatol*. 2013 Jul;58(4):281-5.
38. Taylor MB, Yanaki JS, Draper DO, Shurtz JC, Coglianese M. Successful short-term and long-term treatment of melasma and postinflammatory hyperpigmentation using vitamin C with a full-face iontophoresis mask and a mandelic/malic acid skin care regimen. *J Drugs Dermatol*. 2013 Jan;12(1):45-50.
39. Ortonne JP. Retinoid therapy of pigmentary disorders. *Dermatol Ther*. 2006 Sep-Oct;19(5):280-8
40. Gold M, Rendon M, Dibernardo B, Bruce S, Lucas-Anthony C, Watson J. Open-label treatment of moderate or marked melasma with a 4% hydroquinone skin care system plus 0.05% tretinoin cream. *J Clin Aesthet Dermatol*. 2013 Nov;6(11):32-8.
41. Dogra S, Kanwar AJ, Parsad D. Adapalene in the treatment of melasma: a preliminary report. *J Dermatol*. 2002 Aug;29(8):539-40.
42. Faghihi G, Shahingohar A, Siadat AH. Comparison between 1% tretinoin peeling versus 70% glycolic acid peeling in the treatment of female patients with melasma. *J Drugs Dermatol*. 2011 Dec;10(12):1439-42.
43. Brazzini B, Hautmann G, Ghersetich I, Hercogova J, Lotti T. Laser tissue interaction in epidermal pigmented lesions. *J Eur Acad Dermatol Venereol*. 2001 Sep;15(5):388-91.
44. Lee DB, Suh HS, Choi YS. A comparative study of low-fluence 1064-nm Q-switched Nd:YAG laser with or without chemical peeling using Jessner's solution in melasma patients. *J Dermatolog Treat*. 2014 Dec;25(6):523-8.
45. Lee HI, Lim YY, Kim BJ, Kim MN, Min HJ, Hwang JH, et al. Clinicopathologic efficacy of copper bromide plus/yellow laser (578 nm with 511 nm) for treatment of melasma in Asian patients. *Dermatol Surg*. 2010 Jun;36(6):885-93.
46. Zaleski L, Fabi S, Goldman MP. Treatment of melasma and the use of intense pulsed light: a review. *J Drugs Dermatol*. 2012 Nov;11(11):1316-20.
47. Figueiredo Souza L, Trancoso Souza S. Single-session intense pulsed light combined with stable fixed-dose triple combination topical therapy for the treatment of refractory melasma. *Dermatol Ther*. 2012 Sep-Oct;25(5):477-80.
48. Chung JY, Choi M, Lee JH, Cho S, Lee JH. Pulse in pulse intense pulsed light for melasma treatment: a pilot study. *Dermatol Surg*. 2014 Feb;40(2):162-8.
49. Rendon M, Berneburg M, Arellano I, Picardo M. Treatment of melasma. *J Am Acad Dermatol*. 2006 May;54(5 Suppl 2):S272-81.
50. Draelos ZD. Skin lightening preparations and the hydroquinone controversy. *Dermatol Ther*. 2007 Sep-Oct;20(5):308-13.
51. Yousefi A, Khani Khoozani Z, Zakerzadeh Forooshani S, Omrani N, Moini AM, Eskandari Y. Is topical zinc effective in the treatment of melasma? A double-blind randomized comparative study. *Dermatol Surg*. 2014 Jan;40(1):33-7.
52. Zhu W, Gao J. The use of botanical extracts as topical skin-lightening agents for the improvement of skin pigmentation disorders. *J Investig Dermatol Symp Proc*. 2008 Apr;13(1):20-4.

Novi aspekti melazme

Sažetak

Uvod. Melazma je stečena cirkumskriptna hipermelanoza lica, povremeno vrata i podlaktica, koja značajno utiče na kvalitet života. Hloazma je grčki termin za „zelenu mrlju“ i opisuje melazmu za vreme trudnoće („znak“ trudnoće). Iako može

da se javi kod svih rasa, melazma je mnogo češća kod tamnoputih ljudi (tip kože IV–VI). Melazma je češća kod pojedinaca hispankog, orijentalnog i azijskog porekla. Prevalencija melazme se kreće od 8% kod Latinoamerikanaca u SAD do 30% kod

južnoistočnjačke azijske populacije. Melazma ima veću prevalenciju kod žena, naročito u reproduktivnom periodu, sa pikom između 20 i 30 godina. Retko se pojavljuje pre puberteta. Ekstrafacijalna melazma se mnogo češće sreće kod žena u menopauzi.

Etiopatogeneza. Etiopatogeneza melazme je multifaktorska i nerazjašnjena. Genetska predispozicija, hormonski faktori i izloženost UV zračenju klasični su predisponirajući faktori. Ultravioletno zračenje je najveći uzročnik i otežavajući faktor u razvoju melazme, jer je poznata njegova sposobnost da stimuliše proliferaciju melanocita, njihovu migraciju i melanogenezu. Hiperpigmentacija, UV indukovana, obično se povlači spontano, a melazma ne. Nedavno, Kim i saradnici su otkrili smanjenu ekspresiju H19 gena u hiperpigmentovanoj i normalno pigmentovanoj koži kod pacijenata sa melazmom. Melazma se obično češće javlja kod žena koje koriste oralne kontraceptive sa estrogenom ili progesteronom, hormonsku terapiju za prevenciju osteoporoze i kod muškaraca koji koriste derivate estrogena u tretmanu karcinoma prostate. Melazma indukovana estrogenom može biti povezana sa prisustvom estrogenskih receptora na melanocitima koji stimulišu ćelije da proizvode veću količinu melanina. U jednoj studiji o melazmi, kod pacijentkinja koje nikada nisu bile trudne niti su koristile hormonsku terapiju, uočeno je povećanje koncentracije luteinizirajućeg hormona u serumu. Sovni (Sawney) i Anand utvrdili su visoku prevalenciju hroničnih pelvičnih inflamatornih bolesti kod žena sa melazmom. Ova istraživanja ukazuju na blagu ovarijalnu disfunkciju kao mogući uzrok u idiopatskim slučajevima melazme.

Iako mnoga istraživanja jasno ukazuju na ulogu genetskih faktora, porodična pojava melazme prema različitim studijama kreće se od 20% do 70%.

Karakteristična je klinička distribucija melazme duž trigeminalnih nerava, koja ukazuje na neuralnu ulogu u patogenezi pigmentacije. Bak i saradnici su ustanovili visok nivo nervne endopeptidaze u melanotičnim lezijama i ukazuju da neuroaktivni molekuli, uključujući i neurološki faktor rasta, imaju važnu ulogu u patogenezi melazme.

Još uvek je nerazjašnjeno zašto su određena područja na licu preodređena za nastanak melazme, dok su ostala pošteđena. Pored neuralnih faktora i hormonskih receptora, krvni sudovi mogu da imaju određenu

ulogu. Humani melanociti mogu da odgovaraju na vaskularne faktore zato što normalni humani melanociti imaju stimulišuće receptore za vaskularni endotelni faktor rasta (VEGF). U pojedinim tipovima melazme pojavljuje se ograničen telengiektatični eritem na područjima gde se javila melazma.

Povećana prokrvljenost je jedna od glavnih histoloških karakteristika melazme. Ova otkrića mogu da objasne efekat lokalizovane mikroinjekcije aplikacije plazmin-inhibitora traneksaminske kiseline i dobar terapijski odgovor na lasere koji deluju na krvne sudove u tretmanu melazme.

Patohistologija. Nekoliko studija je izučavalo histološke izmene u melanotičnim lezijama. U poređenju sa nezahvaćenom kožom, područja hiperpigmentacije pokazuju prekomerne depozite melanina u epidermisu i dermisu, uvećane intenzivno obojene melanocite sa uvećanim dendritima.

Klinička prezentacija. Klinički, melazma predstavlja simetričnu makularnu pigmentaciju nejasno ograničenu, koja može da varira u boji od svetlosmeđe do tamnosmeđe ili smeđesive. Prema distribuciji lezija, melazma se javlja u jednom od tri oblika: centrofacijalni (65%), malarni (20%), mandibularni (15%).

Vudova lampa (320–400 nm) može da se koristi kako bi se odredila dubina melanina u koži. Klasifikacija melazme na četiri glavna klinička tipa ukazuje na dobru korelaciju sa dubinom pigmenta melanina:

1. epidermalna melazma je vidljiva pri pregledu Vudovom lampom;
2. dermalna melazma pod Vudovim svetlom pokazuje manje jasne granice;
3. mešana melazma se prikazuje samo na nekim područjima pod Vudovim svetlom;
4. neodređena ili neočigledna melazma pod Vudovim svetlom ne lokalizuje pigment.

Dijagnoza. Dijagnoza je klinička i zahteva znatnije angažovanje sa svakim pacijentom kako bi se otkrili individualni rizici i uzroci. Veliki broj drugih faktora može da prikriva melazmu.

Terapija. Bazični principi u tretmanu melazme uključuju: smanjenje proliferacije melanocita, inhibiciju nastanka melanozoma i povećanje degradacije melanozoma.

Zaštita od sunca. Korišćenje mineralnih krema sa zaštitnim faktorima koji sadrže titanijum-dioksid ili

cink-oksidi sa faktorom zaštite od sunca (SPF) većim od 30 je obavezno.

Sredstva za izbeljivanje. Sredstva za izbeljivanje deluju na različitim nivoima produkcije melanina u koži, mnogi od njih su inhibitori tirozinaze, ključnog enzima u melanogenezi. Drugi inhibiraju sazrevanje ovog enzima ili transport do melanozoma od melanocita iz okolnih keratinocita. Postoje tri različite kategorije sredstava za izbeljivanje: fenolna jedinjenja, nefenolna jedinjenja i kombinovane formule. Neki biljni produkti, flavonidi, kumarini i drugi derivati dobro su poznati hipopigmentovani agensi.

Hidrohinon ispoljava dejstvo tako što inhibiše konverziju 3,4-dihidro-ksifenilalanina (DOPA) u melanin, inhibicijom tirozinaze; takođe inhibiše RNA i DNA sintezu u melanocitnim ćelijama i degradira melanozome. Od 2001. godine, korišćenje HQ kao sastojka u kozmetici je zabranjeno u EU. Odluku je donela EU i zasnovana je na neželjenim efektima, uglavnom spoljašnjim. Tokom protekle decenije, zabrinutost oko sigurnosti HQ se povećala. Njegova upotreba je bila povezana sa toksičnošću i genskim mutacijama i sa povećanom incidencijom egzogene ohronoze. Iako eksperimenti na životinjama ukazuju na toksičnost i/ili mutagene efekte, oni nisu dokazani kod ljudi. Za sada doktorima je dozvoljeno da propisuju HQ u koncentraciji 2–10%. Nekoliko preskripcija – formulacija poznato je u dermatološkim krugovima. HQ brzo oksidiše i zbog toga se prepisuje u kombinaciji antioksidanasa: 0,1% natrijum-bisulfat i 0,1% askorbinska kiselina. Navedena formula može se propisati: 3–10% HQ u hidroalkoholnoj soluciji (u jednakim delovima propilen-glikola i čistog etanola) ili hidrofилna mast ili kao gel koji sadrži 10% α -hidroksi kiseline (AHA) sa 0,1% askorbinskom kiselinom kao konzervansom.

Posvetljivanje kože HQ može biti poboljšano dodavanjem različitih topikalnih agenasa kao što je tretionin i kortikosteridi. Tretionin ubrzava ćelijski ciklus i olakšava epidermalnu penetraciju HQ, te sprečava steroidnu atrofiju i oksidaciju HQ. Kortikosterodi sprečavaju produkciju melanina i eliminišu iritaciju uzrokovanu HQ i tretioninom.

Azelaična kiselina (AzA) nastaje kao prirodni bioprodukt pri metabolizmu Pityrosporum ovale. Azelaična kiselina nema efekta na normalne melanocite, ali ima antiproliferativni efekat na

abnormalne melanocite. Novije studije predlažu da aplikovanje krema sa 20% azelaičnom kiselinom dva puta dnevno može da bude efikasnije nego 4% hidrohininom u blažim oblicima melazme.

Kojic kiselina je gljivični metabolit koji inhibiše kateholinsku aktivnost tirozinaze. Iako je kojic kiselina sama manje efikasna nego 2% HQ u kombinaciji sa 10% glikolnom kiselinom i 2% HQ ima sinergističko delovanje.

Nekoliko oblika topikalnog vitamina C korišćeno je u terapiji melazme u 5–10% koncentracijama i može se koristiti sa drugim depigmentišućim agensima, kao što je HQ. Druge prednosti vitamina C uključuju antioksidativni efekat i fotoprotektivna svojstva. Koristi se jontoforeza radi povećanja penetracije vitamina C u kožu.

Lokalni retionidi stimulišu ćelijski ciklus čime se ubrzava gubitak melanina putem epidermopoeze. Tretionin u koncentraciji 0,05–0,1% aplikovan tokom noći pokazao se kao efikasna monoterapija, ali zahteva 20–40 nedelja lečenja. Adapalen 0,1% predstavlja efikasnu monoterapiju u lečenju epidermalne melazme i pokazuje manju iritaciju u odnosu na tretionin. U jednoj studiji je pokazana ista efikasnost pilinga sa 1% tretioninom u odnosu na 70% glikolnu kiselinu, ali sa manjim neželjenim efektima.

Hemijski pilinzi. Zbog dubine svog delovanja, površinski pilinzi se mogu koristiti na svim tipovima kože.

Pilinzi sa srednjom dubinom delovanja predstavljaju alternativni tretman u refraktornim slučajevima težih oblika melazme.

Svi tipovi hemijskih pilinga, ali uglavnom najčešće korišćeni pilinzi, tj. oni sa α -hidroksi kiselinama, β -hidroksi kiselinama, salicilnom kiselinom, Jesnerovim originalnim i modifikovanim rastvorom, kao i trihlorsirćetnom kiselinom ostaju alternativna terapija kod pacijenata sa melazmom.

Laseri. Lečenje melazme laserom i ostalim vidovima svetlosne terapije daje najbolje efekte kod osoba sa svetlom kožom, a predstavlja treću terapijsku liniju. Postinflamatorne hiperpigmentacije predstavljaju najčešće neželjene efekte. Recidivi se javljaju u oko 50% slučajeva.

Važno je da izbor talasne dužine bude između 630 nm i 1100 nm, s obzirom da se tada postiže apsorpcija melanina, a da dužina pulsa bude između 40 ns i 750 ns.

Epidermalna melazma se može lečiti ablativnim laserima: karbon-dioksid (CO₂) i Erbium (ER): YAG) laser. Dobar terapijski efekat može se postići i frakcionisanim neablativnim 1 550 nm frakcionim laserom.

Q-switched (QS) laser selektivno deluje na melanozome. Tako se QS-Nd : YAG 1 064 nm najčešće koristi za lečenje melazme. Ohrabrujući rezultati u lečenju dermalnog tipa melazme postignuti su sa novim 694 nm QS rubinskim frakcionim laserom.

Pulsni diodni laser i laseri koji se koriste za lečenje vaskularnih promena novijeg datuma, kao što je bakar-bromid laser mogu se koristiti u lečenju melazme sa izraženim telangiektazijama.

Kombinovana upotreba različitih lasera može biti efikasna u lečenju dermalnog tipa melazme. Ablativni laser uklanja epiderm; potom se Q-switched selektivnim pigmentnim laserom mogu dostići dublje

lezije u dermisu čime se utiče na dermalne melanofage i to bez većih neželjenih efekata.

Intenzivna pulsna svetlost. Istovremena primena intenzivne pulsne svetlosti i hidrohina u stabilnim kombinovanim formulama predstavlja bezbedan i efikasan način lečenja mešovitih i dermalnih melazmi. S obzirom na sve veću obazrivost pri primeni hidrohina, pribeglo se otkrivanju novih agenasa: biljni ekstrakti, živa, indometacin, cink-sulfat i derivati fenola.

Zaključak. Zasad ne postoji jednako efikasan vid lečenja melazme. Lečenje se bazira na primeni lekova koji suprimiraju melanogenezu uz sredstva za zaštitu od sunca. Prvu terapijsku liniju čini topijski hidrohina, sam ili u trojnoj kombinovanoj formuli; drugu terapijsku liniju čine hemijski pilinzi; treću terapijsku liniju čine laseri i ostali vidovi svetlosne terapije.

Ključne reči

Melanoza; Dermatološki preparati; Hidrokvina; Fotozaštitni preparati; Preparati za posvetljivanje kože; Laserska terapija; Diferencijalna dijagnoza