

Erythrodermic cutaneous T-cell lymphoma: Two case reports

Miroslav Ž. DINIĆ^{1*}, Lidija KANDOLF-SEKULOVIĆ¹,
Tomislav MLADENović¹ and Radoš D. ZEČEVIĆ¹

¹Department of Dermatology and Venereology, Military Medical Academy, Belgrade

*Correspondence: Miroslav Ž. DINIĆ, E-mail: miroslavdinic@hotmail.com

UDC 616.5-006.44-079.4



Abstract

Primary cutaneous T-cell lymphomas (CTCLs) are Non-Hodgkin lymphomas where skin may be the only involved organ for a long time. The erythrodermic form of CTCL, including Sezary syndrome, with increased IgE concentration, eosinophilia and intense pruritus, may suggest atopic dermatitis, in the lack of evidence for diagnosis of T-cell lymphoproliferative disorder. After vigorous research, two patients with erythroderma, increased IgE and eosinophilia, were not diagnosed with CTCL. Adult atopic dermatitis was diagnosed, based on clinical examination and histopathologic analysis of the skin sample. Therapy with oral cyclosporin A (CsA) and systemic corticosteroids were initiated, but the improvement was minimal and short-lived. Disease progression was noted in both patients, after a month of cyclosporine therapy: malaise, subfebrile and febrile temperatures, and development of generalized skin nodules were evident. In the first patient (aged 30) repeated examinations confirmed presence of Sezary cells in peripheral blood samples, dominant T-cell clone in the skin, peripheral blood and bone marrow, whereas the last repeated histopathologic analysis revealed T-lymphoproliferative skin disorder. In the second patient, (aged 44) primary cutaneous CD30+ T-cell lymphoma was diagnosed, based on histopathologic analysis of the newly appearing skin nodule. Differential diagnosis of erythroderma is always difficult, since clinical, histopathologic and immunophenotypic findings are frequently insufficient to differentiate between inflammatory and lymphomatous erythroderma. Treatment with cyclosporin A always demands careful evaluation of the course of the disorder.

Erythroderma (erythema of at least 90% of the body skin surface) is a rare, but severe skin manifestation of several cutaneous disorders including psoriasis, atopic dermatitis, pityriasis rubra pilaris and cutaneous T-cell lymphoma (CTCL). CTCLs are Non-Hodgkin lymphomas where skin may be the only involved organ for a long time. Erythrodermic CTCLs most often include erythrodermic mycosis fungoides and Sezary syndrome. The erythrodermic form of CTCL, including Sezary syndrome, with increased IgE concentration, eosinophilia and intense pruritus, may be mistaken for atopic dermatitis in the lack of evidence for diagnosis of T-cell lymphoproliferative disorder. We report two patients with erythroderma, increased IgE and eosinophilia in whom, after vigorous research, the diagnosis of CTCL was not established, and adult atopic dermatitis was diagnosed. The therapy with cyclosporine A was initiated and after a month of therapy, which showed

to be ineffective, repeated clinical examination and histopathological, immunohistochemical and gene rearrangement analyses, revealed existence of T-cell cutaneous lymphoma in both patients.

Case 1

A male patient, aged 30 years, was admitted to our Department with extremely itchy erythroderma with generalized peripheral lymphadenopathy and hyperkeratosis of the palms and soles, that lasted for two months (Figure 1). During the previous year he received therapy for dry, red and scaly erythematous macules in the skin folds, with topical and systemic corticosteroids and topical pimecrolimus, without improvement. A short course of P-UVA phototherapy led to minimal improvement.

Laboratory analyses revealed leukocytosis $16,65 \times 10^9/L$, and eosinophilia 8,5%, as well as elevated lactate dehydrogenase (LDH) of 559 U/L

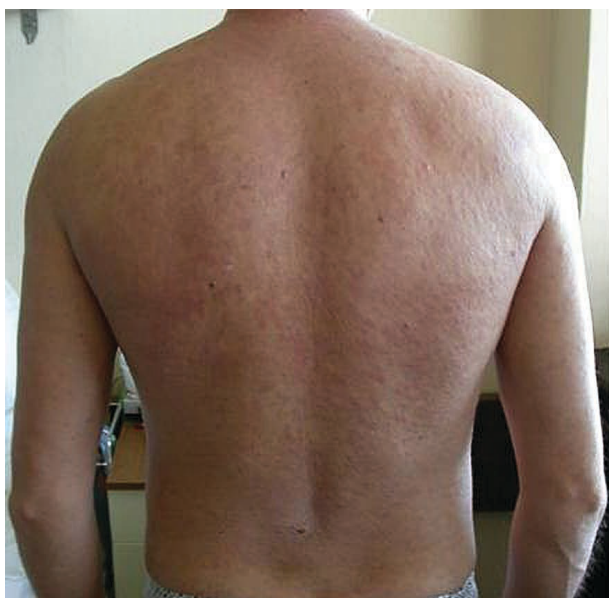

Figure 1. Erythroderma involving the back and upper arms in the first patient

and increased IgE concentration - 5650 IU/L. Other complete blood count (CBC) parameters, electrolytes, urea, creatinine, total bilirubine, aspartate aminotransferase (AST), alanine aminotransferase (ALT), gama glutamyl transpeptidase (γ GT), IgG, IgA, IgM, were within normal range. ELISA HIV test was negative. Increased number of leukocytes was evident ($14 \times 10^9/L$), in the peripheral blood smear, but Sezary cells were not found. Chest X-ray findings and abdominal and pelvic ultrasounds were normal. Histopathologic analysis of the skin sample specimens revealed immune inflammatory response and secondary neutrophilic spongiosis consistent with non-specific inflammatory dermatosis. Cytologic analysis of the left supraclavicular enlarged lymph node smear revealed a non-specific lymphoid hyperplasia. T-cell receptor- γ gene rearrangement analysis of skin and blood specimens showed polyclonal T-cell population. Due to lack of evidence for the diagnosis of T-cell lymphoproliferative disorder, the diagnosis of adult atopic dermatitis was established, and therapy with cyclosporin A (CsA) oral solution (5 mg/kg/bw), and methylprednisolone 40 mg/d i.v. was initiated, with chlorpyramine i.m. and topical corticosteroid therapy.

Three weeks later, the patient referred for check-up with signs of disease progression: malaise, more enlarged peripheral lymph nodes, fever (39.1°C)

generalized erythemolivid nodules, with more intense erythroderma. Repeated peripheral blood smear revealed younger lymphatic cells (5% were suspicious for Sezary cells). In the peripheral blood and skin, a dominant T-cell clone was detected by T-cell receptor- γ gene rearrangement analysis. A dominant T-cell clone was also detected in the bone marrow. CD4/CD8 ratio was increased to 7.8. Chest and abdominal multi-slice computed tomography (MSCT) revealed axillary lymphadenopathy up to 3.5 cm in diameter, while chest and retroperitoneal lymph nodes were not enlarged. Repeated skin biopsy was performed, and histopathological analysis was consistent with T-lymphoproliferative disorder - Sezary syndrome (Figure 2.). Based on repeated hemoculture test, staphylococcal sepsis was also diagnosed, so intravenous sulfametoazol trimetoprim was administered. Based on these findings, diagnosis of Sezary syndrome was established in stage IIIB: T4 (confluence of erythema covering $\geq 80\%$ body surface area) N1 (clinically abnormal peripheral lymph nodes; histopathology Dutch grade 1) M0 (no visceral organ involvement) B2 (high blood tumor burden: positive clone, increased CD4/CD8), according to revised classification of mycosis fungoides/Sezary syndrome (1). The patient was referred to a hematologist for

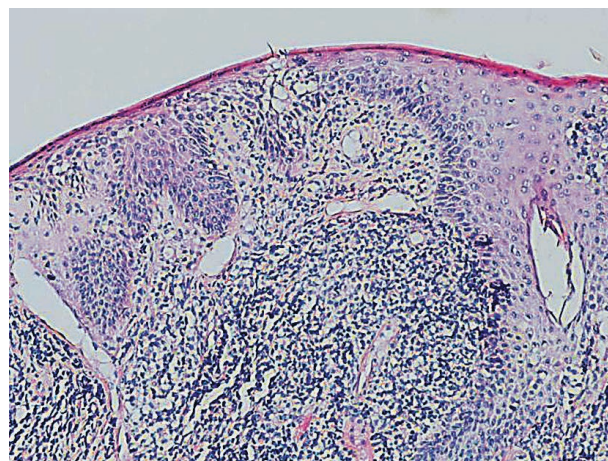


Figure 2. Focal parakeratosis, acanthosis and hypogranular epidermal basal layer are evident. In the superficial dermis, perivascular aggregation of lymphocytes is present, and in one follicle intraepidermal grouping of lymphocytes forming Pautrier's abscess is evident; subepidermal infiltration of eosinophils is evident, rare eosinophils are present intraepidermally (hematoxylin and eosin, x100)

polychemotherapy. He was treated with four cycles of cyclophosphamide, doxorubicine, vincristine, prednisolone (CHOP) chemotherapeutical protocol, that led to regression of erythroderma, but lymphadenopathy still remained unchanged, so treatment with second-line therapy with cytarabine, cisplatin, etoposide and methylprednisolone, was in course at the last follow-up.

Case 2

A male patient, aged 44, was admitted to our Department with generalized dry, scaly and itchy livid skin, and lichenification on the elbows, knees and ankles. At the age of 26, his skin turned dry, scaly and itchy, and at the age of 39 his skin condition worsened, with pronounced livid erythema and scaling of over 95% of the skin surface. He was treated by several dermatologists for generalized ichthyosis of unknown cause. Repeated histopathologic findings, in the last 15 years, were non-specific and inconclusive. There was no other evidence of atopy in personal and family history. Topical corticosteroid therapy and emollients showed no benefit. The patient turned chronically subfebrile 4 months before admission, and generalized peripheral lymphadenopathy occurred.

On admission, increased erythrocyte sedimentation rate (ESR) 38 mm/h, leukocytosis $13.91 \times 10^9/L$, eosinophilia 8.9%, thrombocytosis $604 \times 10^9/L$, and increased concentration of IgE (3200 IU/L) were established. Other parameters of CBC, blood biochemistry, AST, ALT, γ GT, LDH, carcinoembryonic antigens (CEA), alpha fetoprotein antigens (AFP), amylase and immunoglobulins (G, A, M) were within normal range. ELISA tests for anti-HIV and anti-Borrelia burgdorferi antibodies were negative. Chest X-ray and abdominal and pelvic ultrasound findings were normal. Histopathologic analysis of skin specimens and hyperkeratotic skin specimens revealed chronic inflammation and reparative changes suggestive of hypersensitive reaction. Histopathological analysis of the enlarged right axillary lymph node specimen was consistent with dermatopathic lymphadenopathy. Examinations to establish a lymphoproliferative disease, including bone marrow biopsy, histopathological analysis, peripheral blood smear, T-cell receptor- γ gene rearrangement analysis of the skin, peripheral blood and bone

marrow specimens, immunophenotypization of peripheral blood lymphocytes were done, but the nature of the presenting erythroderma was not elucidated. Due to the lack of evidence for diagnosis of T-cell lymphoproliferative disorder, it was concluded that the diagnosis could be an adult form of atopic dermatitis, so a trial of CsA oral solution (5 mg/kg/bw) with methylprednisolone (40 mg/d) i.v. was commenced, with systemic antihistamine and topical corticosteroids and emollients.

Three weeks later, the patient became febrile ($38^\circ C$), with worsened peripheral lymphadenopathy (enlarged lymph nodes in the right groin were evident). Also, disseminated livid papules up to 5 mm in diameter, some with necrotic surface appeared, while erythroderma aggravated during the second admission (Figures 3a and 3b). Leukocytosis ($14.51 \times 10^9/L$) and eosinophilia (9%), with platelets count of $590 \times 10^9/L$ and ESR 67 mm/h were also present. The chemocultures remained sterile. The repeated peripheral blood smear confirmed leukocytosis and eosinophilia, while on flow-cytometry, CD4/CD8 index was within normal range. Histopathologic analysis of the enlarged lymph node specimen in the right groin revealed dermatopathic lymphadenopathy again. However, histopathologic analysis of the livid papule with necrotic surface led

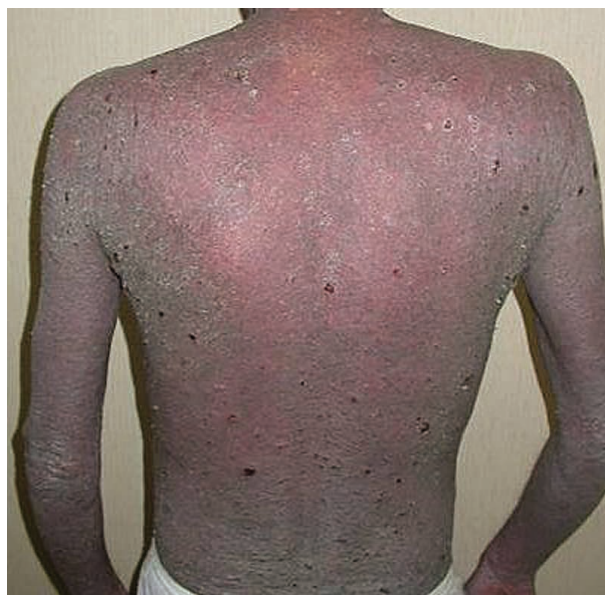

Figure 3.a. Erythemolivid skin color of the back and upper arms, with numerous necrotic papules in the second patient.

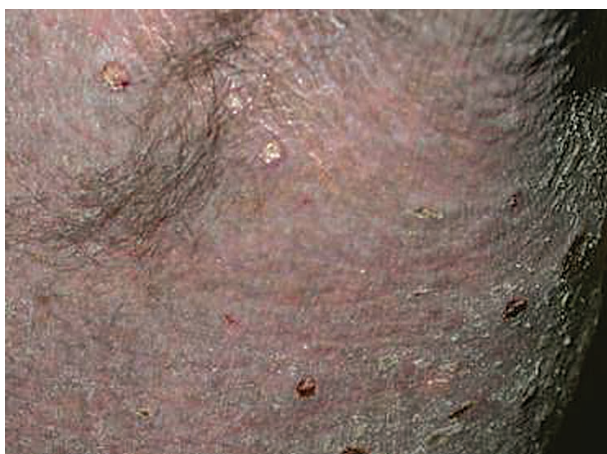

Figure 3.b. Close-up view at livid, scaly skin of the abdomen, with erosions at places of previous necrotic papules

to the following diagnosis: primary cutaneous CD30+ T-cell lymphoma (Figures 4a and 4b). The patient was referred to a hematologist who prescribed bleomycine, cyclophosphamide, doxorubicine, vincristine, prednisolone (B-CHOP) polychemotherapy. After six cycles of (B-CHOP) polychemotherapy, the skin lesions regressed, as well as lymphadenopathy, but the

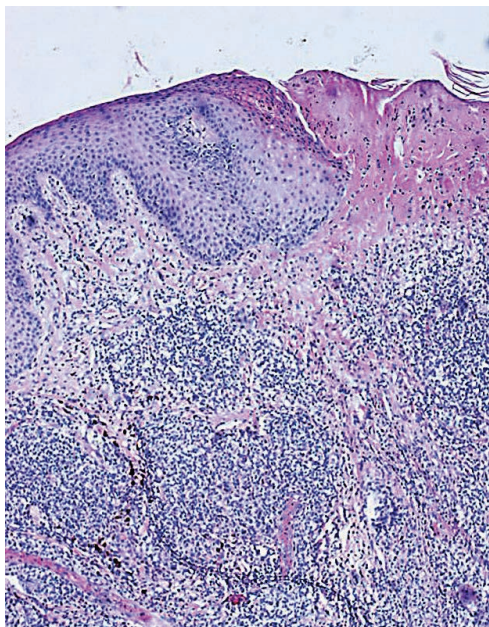


Figure 4.a. Superficial diffuse and pseudonodular deep dermal infiltration with superficial necrosis. The infiltrate consists of medium-sized cells, with one or several nucleoli; mitoses are evident. Eosinophils are present at the periphery (hematoxylin and eosin, x100);

peculiar livid color of the skin was still evident on the last follow-up (Figure 5).

Discussion

Erythroderma is defined as an erythematous dermatitis involving of at least 90% of the cutaneous surface. It is a severe skin manifestation of several cutaneous disorders, including cutaneous T-cell lymphoma (CTCL). If the

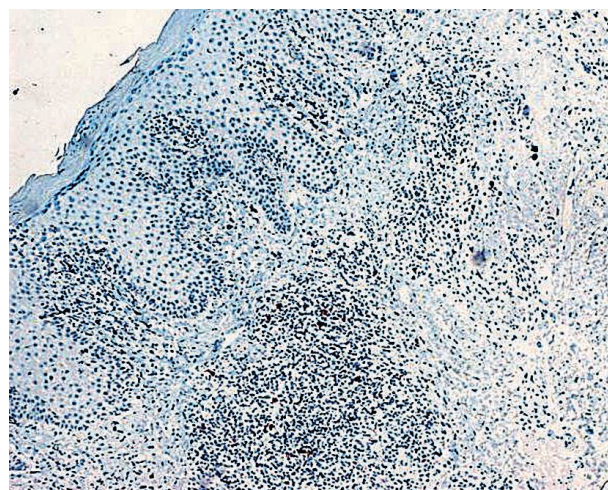


Figure 4. b. At least 20% of cells are CD30+ large cells with polymorphic nuclei and small nucleoli (immunoperoxidase staining, DAB chromogen, contrastained with hematoxylin, x100)

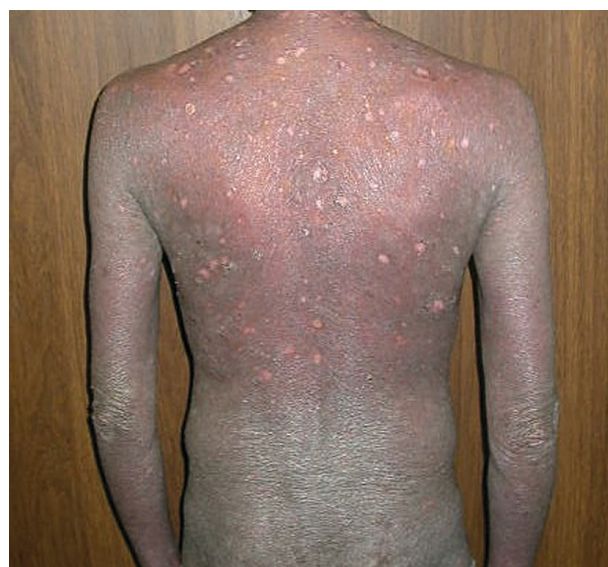

Figure 5. Regression of papulonecrotic lesions, with remaining of livid color of the skin in the second patient

diagnosis of a preexisted skin disorder was previously established, such as psoriasis, atopic dermatitis and pityriasis rubra pilaris, there are no doubts about the nature of erythroderma or its treatment. Considering the fact that CTCL is a slow-developing disorder, evolving skin changes and, often repeated, histopathologic findings of erythrodermic skin may lead to the diagnosis. In some cases, there are difficulties to differentiate between inflammatory dermatosis and skin lymphoma by clinical and histopathological features. Thus correlation of clinical appearance, immunohistochemistry and T-cell receptor- γ gene rearrangement analyses are needed (2). Sometimes, even that is not enough, so regular follow-ups and repeated analyses are necessary to detect the true nature of erythroderma and other skin changes of CTCL. It can be said that the final diagnosis of CTCL is possible during the course of the disease, when the tumor load is sufficient to be detected by vigorous research.

In the first patient, the diagnosis of Sezary syndrome, the most frequent form of erythrodermic CTCL, was diagnosed only after repeated analyses to identify the cause of erythroderma, one month after the initiation of cyclosporine treatment. The other patient was diagnosed with primary cutaneous CD30+ T-cell lymphoma which manifested with erythroderma and necrotic skin nodules that appeared late during the course of the disease. Primary CD30+ CTCL are most frequently manifested as primary cutaneous CD30+ anaplastic large cell lymphoma (ALCL), lymphomatoid papulosis, or borderline cases. Primary cutaneous CD30 + ALCL is manifested with multiple, often ulcerating, skin papules and nodules, like in our patient. On histopathological analysis, the majority of cells have anaplastic appearance, but in 20-25% cases non-anaplastic cells are present, which was the case in our patient (3). Erythroderma is not a typical feature of primary cutaneous CD30 + CTCL. In our patient, the preexisting, long-lasting erythroderma may be considered as secondary to the slowly developing T-cell dyscrasia, that could not be detected earlier by repeated histopathological analyses. Previously published cases of primary cutaneous ALCL with prolonged erythrodermic prodrome support this observation (4, 5).

Administration of CsA demands careful evaluation of the course of the disease. There is no evidence that

CsA, used for the treatment of erythrodermic adult atopic dermatitis, caused lymphoproliferative disorders in these two cases, because the therapy lasted only a few weeks. According to previous reports, in adult atopic dermatitis patients, lymphoproliferative disease developed after at least 6 months of cyclosporine A treatment (6, 7). Also, in a large study, CTCL was not found to be more frequent in patients with atopic dermatitis, although in another study increased prevalence of lymphoma (especially cutaneous lymphoma) was found among patients with atopic dermatitis treated with topical corticosteroids (8, 9). Published case reports suggest that in rare cases CTCL may develop in atopic dermatitis patients who never received cyclosporine A therapy (10).

In conclusion, correlation of the clinical appearance, and, often repeated, histopathologic analysis of the skin, enlarged peripheral lymph nodes and bone marrow, together with peripheral blood smears, T-cell receptor- γ gene rearrangement analysis of the skin, peripheral blood and bone marrow specimens and immunophenotypization of peripheral blood lymphocytes, are useful in the diagnosis of patients with erythroderma without previously existing dermatosis, because the lymphomatous nature of presenting erythroderma may be elucidated (2).

References:

1. Olsen E, Vonderheid E, Pimpinelli N, Willemze R, Kim Y, Knobler R, et al. Revisions to the staging and classification of mycosis fungoides Sézary syndrome: a proposal of the International Society for Cutaneous Lymphomas (ISCL) and the cutaneous lymphoma task force of the European Organization of Research and Treatment of Cancer (EORTC). *Blood* 2007;110:1713-22.
2. Kandolf-Sekulović L, Cikota B, Dinić M, Škiljević D, Medenica Lj, Magić Z. T-cell receptor- γ gene rearrangement analysis in the diagnosis of patients with erythroderma. *Serb J Dermatol Venereol* 2009;1:17-26.
3. Willemze R, Jaffe E, Burg G, Cerroni L, Berti E, Swerdlow S, et al. WHO-EORTC classification for cutaneous lymphomas. *Blood* 2005;105:3768-85.
4. Goyal S, Brinster NK, Goyal S. Ki-1(CD30) positive anaplastic large cell lymphoma: primary nodal disease relapsing as erythroderma. *J Am Acad Dermatol* 2002;47:S201-4.
5. Denton K, Wilson CL, Venning VA. Primary cutaneous anaplastic large-cell lymphoma with a prolonged erythrodermic prodrome. *Br J Dermatol*. 1992;126:297-300.
6. Mougel F, Dalle S, Balme B, Houot R, Thomas L. Aggressive CD30 large cell lymphoma after cyclosporine given for putative atopic dermatitis. *Dermatology* 2006;213:239-41.

7. Laube S, Stephens M, Smith AG, Whitaker SJ, Tan BB. Lymphomatoid papulosis in a patient with atopic eczema on long-term cyclosporine therapy. *Br J Dermatol* 2005;152: 1346-1348.

8. Mehrany K, El-Azhary RA, Bouwhui SA, Pittelkow MR. Cutaneous T-cell lymphoma and atopy: is there an association? *Br J Dermatol* 2003;149:1013-7.

9. Arellano F, Arana A, Wentworth C, Fernandez-Vidaurre C, Schlienger R, Conde E. Lymphoma among patients with atopic dermatitis and/or treated with topical immunosuppressants in the United Kingdom. *J Allergy Clin Immunol* 2009;123:1111-6.

10. Meyer N, Mazereeuw-Hautier J, Launay F, Lamant L, Paul C. CTCL complicating severe atopic dermatitis. *Dermatology* 2009;218:168-71.

Eritrodermalni kutani limfom T-ćelija - prikaz dva slučaja

Sažetak

Uvod: Primarni kutani limfomi T-ćelija su Non-Hoćkinovi limfomi kod kojih koža može biti dugo jedini zahvaćeni organ. U nedostatku nalaza koji bi potvrdili limfoproliferativno oboljenje T-ćelija, eritrodermijski oblik ovih limfoma (uključujući i Sezarijev sindrom), uz visoke koncentracije IgE, eozinofiliju i izrazit svrab može da podseća na atopijski dermatitis.

Prikaz slučaja: Dva bolesnika, hospitalizovana zbog eritrodermije, kod kojih opsežnim ispitivanjima nije dokazano limfoproliferativno oboljenje, pod dijagnozom eritrodermijskog adultnog atopijskog dermatitisa lećeni su oralnim ciklosporinom uz sistemske kortikosteroide, sa privremenim i minimalnim poboljšanjima. Bolest je kod oba bolesnika progredirala u vidu pogoršanja opšteg stanja,

febrilnosti i pojave generalizovanih eritemolividnih nodusa. Kod prvog bolesnika ponovljenim ispitivanjima postavljena je dijagnoza Sezarijevog sindroma na osnovu histopatološkog nalaza kože koji je upućivao na T-limfoproliferativno oboljenje, nalaza Sezarijevih ćelija u razmazu periferne krvi i nalaza monoklonske populacije T-limfocita u koži, perifernoj krvi i kostnoj srži. Kod drugog bolesnika histopatološkom analizom jednog od novonastalih nodusa detektovan je periferni T-ćelijski limfom.

Zaključak: Diferencijalna dijagnoza između inflamatorne dermatoze i eritrodermijskog primarnog T-ćelijskog limfoma uvek je teška i zahteva ponavljana ispitivanja sa ciljem dokazivanja mogućeg limfoma. Primena ciklosporina u terapiji uvek zahteva pažljivo praćenje toka bolesti.