

EDITORIAL

The role of the Keros classification in endoscopic sinus surgery

Daniel Lupoi, MD, Assistant Professor

ENT&HNS Department, “Sfanta Maria” Hospital, Bucharest, Romania
 “Carol Davila” University of Medicine and Pharmacy, Bucharest, Romania



Some of the most feared risks of endoscopic sinus surgery are bleeding and damage to adjacent sinus areas. A good surgeon is one who knows very well the anatomic landmarks he operates and the possible complications that may occur.

Until the introduction of endoscopic sinus surgery (in 1978, by Messerklinger¹), it was said that classical ethmoidectomy is the easiest way to kill a patient². Ethmoidectomy under endoscopic control remained the surgical procedure with the highest risks³. I chosed to write a few words about the roof of the ethmoid because there is some confusion about how to determine the depth of the olfactory fossa. This can be a factor of medical errors like skull base damage with CSF leak or worse, intracranial mistake surgery (intracranial using of the microdebrider). To illustrate this, I performed a little exercise. I searched on the Google search engine for the words “keros ethmoid” and the first results belong to a website radiopedia.org (it is the largest free radiology resource in the world with over 37,233 patient cases and over 14,082 collaborative articles on radiology-related topics). In the article about the Keros classification, the CT examination (Figure 1) is misinterpreted – the lateral lamella shown in the image being the lateral lamella is actually part of the fovea ethmoidalis; so, the olfactory fossa is not correctly measured. Also, in the paper “Anatomical variants of the ethmoid bone on multi-detector CT” by Daniele Gibelli et al., Figure 19 is incorrectly measured to determine the depth of the olfactory fossa⁴. These are some random examples to point that, even in the scientific environment, there is confusing information regarding the olfactory groove and the Keros classification.

Therefore, in order to remind ourselves, the limits of the olfactory fossa are pointed below: medial – crista galli, inferior – cribriform plate of the ethmoid and lateral – lateral lamella of the ethmoid (Figure 2).

Reda Kamel estimates that the thickness of the lateral lamella is on average about 0.2 mm, compared to the ethmoidalis fovea, which is 0.5 mm and has heigher density and strength⁵. At the level of the lateral lamella, the most frequent iatrogenic traumas occur. It is important to measure the lateral lamella because, depending on its height, there are three Keros degreea: degree I (depth of 1 – 3 mm); grade II (depth of 4 – 7 mm); grade III (dept of 8 – 16 mm)⁶.

There is controversy regarding the prevalence of the three degrees. Some studies, such as those published by Paber et al. and Solares et al., indicated that the most common is grade I^{7,8}. Other authors, such as Souza et al. and Sarmad et al., noted that the most common degree is Keros II⁹. All these studies have in common that the third Keros degree is the least common. Patients with this degree have the highest risk of complications (CSF fistulas, meningitis, cranial hemorrhage, abscesses or neurological deficits)^{10,11}.

There is also an asymmetry between the olfactory fossa on the left side and the one on the right. In their study, Ashok and Santosh found an asymmetry between the two olfactory fossae in 23% of patients, with the right side averaging 5.43 mm and the left 4.98 mm¹¹. This data is supported by other authors such as Lebowitz, Nair, Ali¹²⁻¹⁴. It important to know this because the most frequent errors occur in the right side¹¹.

According to the study published by Tung-Wei-

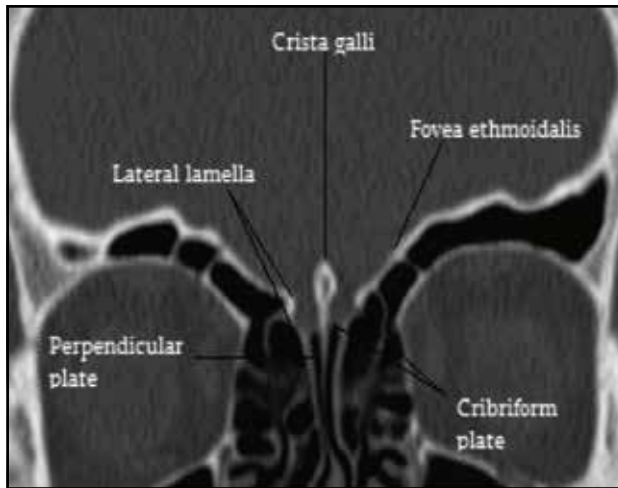


Figure 1. Mismeasurement of the lateral lamella. Case courtesy of Dr Mark Holland, Radiopaedia.org, rID: 19115.

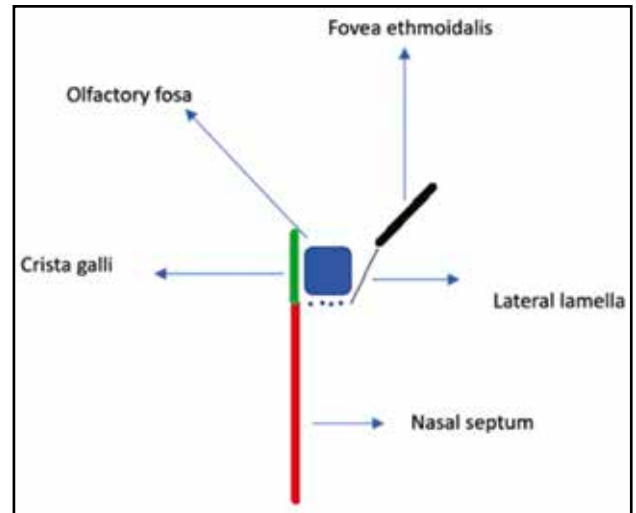


Figure 2. Schematic representation of the olfactory fossa.

Chou et al. per 997 patients, there is a direct relationship between the experience of the ENT doctor and the probability of iatrogenic maneuver (a resident doctor has a risk of 12.67% vs. an experienced doctor who has a risk of only 2.4%)¹⁵.

In conclusion, to minimize the risks of surgery, The Royal College of Surgeons of Edinburgh made several recommendations – a doctor must check some points: experience of at least 100 rhinosinusoidal endoscopic examinations before his first operation; attend courses that allow hand-on surgery; study well preoperatively the rhinosinusoidal CT exam; to obtain the help of a well-skilled doctor during his first surgeries; follow the patient postoperatively¹⁶. It is very important to perform the Keros classification preoperatively in order to avoid iatrogenic procedures at the level of the skull base, considering the fact that it is possible that the olfactory fossa on the right side is deeper than the one on the left side.

REFERENCES

- Messerklinger W. Endoscopy of the nose. Lippincott Williams and Wilkins; 1978.
- Mosher HP. LXXII. Symposium of the ethmoid: The surgical anatomy of the ethmoidal labyrinth. *Ann Otol Rhinol Laryngol*. 1929;38(4):869-901.
- Alazzawi S, Omar R, Rahmat K, Alli K. Radiological analysis of the ethmoid roof in the Malaysian population. *Auris Nasus Larynx*. 2012;39(4):393-6. DOI: 10.1016/j.anl.2011.10.002.
- Gibelli D, Cellina M, Gibelli S, Cappella A, Oliva AG, Termine G, et al. Anatomical variants of ethmoid bone on multidetector CT. *Surg Radiol Anat*. 2018;40(11):1301-11. DOI: 10.1007/s00276-018-2057-6. Epub 2018 Jun 22.
- Kamel R. Endoscopic anatomy of the lateral nasal wall, ostiomeatal complex and anterior skull base: a step-by-step guide. Endo-Press; 2005.
- Keros P. On the practical value of differences in the level of the lamina cribrosa of the ethmoid. *Z Laryngol Rhinol Otol*. 1962;41:808-13.
- Paber JELB, Cabato MSD, Villarta RL, Hernandez JG. Radiographic analysis of the ethmoid roof based on Keros classification among Filipinos. *Philipp J Otolaryngol Head Neck Surg*. 2008;23(1):15-19.
- Solares CA, Lee WT, Batra PS, Citardi MJ. Lateral lamella of the cribriform plate: software-enabled computed tomographic analysis and its clinical relevance in skull base surgery. *Arch Otolaryngol Head Neck Surg*. 2008;134(3):285-9. DOI: 10.1001/archotol.134.3.285.
- Souza SA, de Souza MMA, Idagawa M, Wolosker AMB, Ajzen SA. Computed tomography assessment of the ethmoid roof: a relevant region at risk in endoscopic sinus surgery. *Radiol Bras*. 2008;41(3):143-7.
- May M, Levine HL, Mester SJ, Schaitkin B. Complications of endoscopic sinus surgery: Analysis of 2108 patients—incidence and prevention. *Laryngoscope*. 1994;104(9):1080-3.
- V AM, Santosh B. A study of clinical significance of the depth of olfactory fossa in patients undergoing endoscopic sinus surgery. *Indian J Otolaryngol Head Neck Surg*. 2017;69(4):514-22. DOI: 10.1007/s12070-017-1229-8. Epub 2017 Nov 7.
- Nair S. Importance of ethmoidal roof in endoscopic sinus surgery. [Internet]. *Sci Rep*. 2012;1:251. DOI: 10.4172/scientificreports.251.
- Lebowitz RA, Terk A, Jacobs JB, Holliday RA. Asymmetry of the ethmoid roof: analysis using coronal computed tomography. *Laryngoscope*. 2001;111(12):2122-4. DOI: 10.1097/00005537-200112000-00007.
- Ali A, Kurien M, Shyamkumar NK. Anterior skull base: High risk areas in endoscopic sinus surgery in chronic rhinosinusitis: A computed tomographic analysis. *Indian J Otolaryngol Head Neck Surg*. 2005;57(1):5-8. DOI: 10.1007/BF02907616.
- Chou TW, Chen PS, Lin HC, Lee KS, Tsai HT, Lee JC, et al. Multiple analyses of factors related to complications in endoscopic sinus surgery. *J Chin Med Assoc*. 2016;79(2):88-92. DOI: 10.106/j.jcma.2015.11.001. Epub 2015 Dec 17.
- Maran AGD, Lund VJ, Mackay IS, Wilson J. Endoscopic sinus surgery: Report of Royal College of Surgeons of Edinburgh. Edinburgh: RCSE; 1993.