

## research article

# Is there a role for contrast-enhanced ultrasound in the detection and biopsy of MRI only visible breast lesions?

Aki Nykänen<sup>1,2</sup>, Otso Arponen<sup>1</sup>, Anna Sutela<sup>1</sup>, Ritva Vanninen<sup>1,2,3</sup>, Mazen Sudah<sup>1</sup>

<sup>1</sup> Kuopio University Hospital, Diagnostic Imaging Center, Department of Clinical Radiology, Kuopio, Finland

<sup>2</sup> University of Eastern Finland, Institute of Clinical Medicine, School of Medicine, Kuopio, Finland

<sup>3</sup> University of Eastern Finland, Cancer Center of Eastern Finland, Kuopio, Finland

Radiol Oncol 2017; 51(4): 386-392.

Received 17 August 2017

Accepted 2 October 2017

Correspondence to: Aki Nykänen, BM, Department of Clinical Radiology, Kuopio University Hospital, Puijonlaaksontie 2, P.O. Box 100, FI-70029 Kuopio, Finland. Phone: +358 40 532 0129; E-mail: akinyk@uef.fi

Disclosure: No potential conflicts of interest were disclosed.

**Background.** This study aimed to evaluate the feasibility of contrast-enhanced ultrasound (CEUS) and CEUS-guided interventions in the diagnostics of MRI visible targeted US occult breast lesions.

**Patients and methods.** This retrospective study examined 10 females with 10 occult, MRI only detected breast lesions between July 2014 and April 2017. Targeted second look US followed by CEUS with 2.4 ml of SonoVue<sup>®</sup> were performed for all of the lesions. After positive CEUS localization the same dose was repeated for confirmation and CEUS-guided interventions were performed.

**Results.** MRI revealed 8 mass lesions with a mean size of 9 mm (range 5–16 mm) and 2 non-mass enhancing lesions of 10 and 20 mm in largest diameters. Targeted US revealed no morphological correlate for the lesions. Five out of 10 lesions (50%) were visible on CEUS. CEUS-guided core biopsy was performed on 4 lesions and 1 was marked with a clip for later surgical removal. Histopathological analysis confirmed 4 of them to be malignant. Three out of 5 nonvisible lesions on CEUS underwent MRI-guided interventions, 1 lesion was scheduled for follow-up as it was non-amenable for MRI biopsy, and 1 lesion was biopsied under US-guidance. Three of these nonvisible lesions on CEUS were confirmed to be malignant.

**Conclusions.** Based on our preliminary results, CEUS is a feasible tool for detecting many MRI only visible breast lesions, resulting in a more cost effective and less time-consuming practice. It is a more convenient alternative than MRI guided biopsy and has the potential to be included in the diagnostic algorithm which evaluates MRI only visible breast lesions.

Key words: additional lesions; MRI; MRI-guided interventions; contrast-enhanced ultrasound; CEUS; CEUS-guided interventions

## Introduction

Breast magnetic resonance imaging (MRI) has emerged as the most sensitive imaging modality in the detection and evaluation of breast lesions. One of the major indications for breast MRI is the preoperative local staging of breast cancer and despite controversies about its benefits, the number of preoperatively imaged women has increased.<sup>1,2</sup>

MRI detects additional lesions in 16% (range 11%–24%) of patients in the ipsilateral breast and 9.3% (95% confidence interval, 5.8%–14.7%) in the contralateral breast, depending on the patient population and the definition criteria.<sup>3-5</sup> MRI-detected primarily mammographically and sonographically (US) occult lesions have been shown to rarely display features that are suggestive of malignancy.<sup>6</sup> Therefore, it is important to characterize and man-

age these breast lesions correctly, because if these additional lesions are malignant, this can alter the surgical treatment protocol.<sup>2</sup>

Additional MRI-detected lesions are characterized and evaluated using the BI-RADS<sup>®</sup> lexicon. Lesions categorized as suspicious for malignancy (e.g. BI-RADS<sup>®</sup> 4 or 5) need to undergo a second look targeted ultrasound<sup>7</sup>, and when visible, their nature should be verified histologically with core biopsy (CB) under US guidance whenever possible. A recent meta-analysis of 17 articles that included benign and malignant lesions revealed that the second look ultrasound had a pooled detection rate of 57.5% (range 22.6–82.1%) in the MRI suspicious additional lesions.<sup>7</sup> The second look ultrasound is able to observe mass lesions and malignant lesions better than non-mass-enhancing (NME) or benign lesions.<sup>8,9</sup> The additional lesions that have no morphological correlate on targeted ultrasound should then undergo further MRI-guided vacuum assisted biopsy (VAB). Nevertheless, MRI-guided biopsy is a time consuming, expensive and occasionally, challenging procedure. Furthermore, not all MRI only detected lesions are accessible for MRI biopsy.<sup>10</sup> Therefore, other, more practical, methods to aid in the evaluation of additional MRI-detected lesions are needed.

Contrast-enhanced ultrasound (CEUS) is a non-invasive non-nephrotoxic technique that does not subject the patient to ionizing radiation. The method utilizes microbubble contrast agents, blood flow and tissue perfusion specific imaging.<sup>11</sup> Tissue perfusion is correlated to microvascular density (MVD)<sup>12,13</sup> and angiogenic factor expression<sup>14</sup> are analogous in CEUS and contrast-enhanced MRI (CE-MRI).<sup>11</sup> MRI contrast agents additionally extravasate to the extracellular matrix due to the increased permeability of the microvessels.<sup>15,16</sup> However, the microbubbles in CEUS contrast agent do not extravasate; thus it is the contrast agent accumulating in the intravascular, not in the extracellular space, that is detected in the angiogenetic lesions.<sup>17</sup> CEUS can be administered intravenously to differentiate benign and malignant breast lesions<sup>18</sup>, to assess the disease extent<sup>19</sup> and to monitor the tumour response to neoadjuvant chemotherapy.<sup>20,21</sup>

The utility of CEUS to detect MRI only visible lesions has not been previously reported, yet it is an attractive additional tool to be incorporated into the routine clinical practise, because when the targeted US fails, the patients are already in the US investigation position while rescheduling for MRI-guided biopsy will inevitably delay treatment decisions. In our institution, CEUS is a routine practice

for various indications; in breast diagnostics it is occasionally applied to characterize breast lesions or to identify the sentinel axillary lymph nodes in appropriate situations.<sup>22</sup> The aim of this retrospective study is to report the feasibility of CEUS and CEUS-guided interventions in the detection of US occult MRI visible breast lesions.

## Patients and methods

### Study design and patients

Patients with malignant or suspicious breast findings are referred to our tertiary hospital (catchment area 260,000 inhabitants) for consultation and further management. All patients undergo a full mammography as well as a clinical and bilateral breast US evaluation upon referral. Patients are referred to breast MRI according to national guidelines which are in concordance with those issued by the European Society of Breast Cancer Specialists working group (EUSOMA).<sup>23</sup> Annually, approximately 200 breast MRI examinations are performed for various indications. For the purposes of the present study patients with MRI-detected additional lesions that were investigated with CEUS were retrospectively retrieved from the local picture archiving and communication system. The local chair of the hospital district waived the need for written informed consent from the patients.

Between July 2014 and April 2017, a total of 10 patients fulfilling the following inclusion criteria were evaluated: 1) bilateral mammograms and breast US performed by a breast radiologist; 2) breast MRI according to a structured protocol; 3) an occult, MRI only detected lesion found on MRI that might alter the surgical plan; the lesion had not been evident initially in mammography, US or clinical examination, 4) no morphological correlate of the lesion found during the targeted US performed by a breast radiologist.

### Breast MRI protocol and image analysis

MRI examinations in 8 patients were performed at our institution in the prone position with a seven element, phased-array coil dedicated to breast imaging (Philips Achieva 3.0 T TX, Philips N.V., Eindhoven, The Netherlands). The structural breast MRI protocol consisted of five sequences as seen in Table 1.

Breast radiologists (with > 20 years of experience in breast radiology) primarily evaluated the morphological and kinetic features of MRI findings

TABLE 1. Breast MRI protocol

Sequence	TR/TE (ms)	in-plane resolution mm	Slice thickness (mm)	Scanning time
T1-FFE	4.57/2.3	0.48×0.48	0.7	6 min 11 s
T2-TSE	5000/120	0.6×0.6	2	3 min 20 s
STIR	5000 /60	1×1	2	5 min 40 s
T1 dynamic*	4.67/ 2.31	0.96×0.96	1	58.5 s
DWI#	7168 /95	1.15×1.15	4	min 8 s

#DWI = Diffusion weighted echo planar imaging with five respective b factors (0, 200, 400, 600 and 800 s/mm<sup>2</sup>); \*eTHRIVE spectrally adiabatic inversion recovery (SPAIR) fat suppression; pre-contrast and six phases after the gadoterate meglumine (0.2 ml/kg, 3 ml/s) injection followed by a saline chaser; FFE = fast field echo; STIR = Short tau inversion recovery; TSE = turbo spin echo

together with mammograms and US examinations guided by the BI-RADS<sup>®</sup> lexicon. Two patients were referred to our university hospital from two central hospitals for MRI-guided interventions because of MRI only visible lesions. These patients were scanned with 1.5 T scanners yet with a similar structured MRI protocol. MRI-guided interventions were performed with automated 10 gauge (G) vacuum assisted biopsy device (EnCore Enspire Breast Biopsy System, C.R. Bard Inc., Tempe, AZ, USA).

### Second look targeted US examination

Patients were meticulously scanned with both grey scale and Doppler US. For MRI lesions detected in the lateral part of the breast, patients were scanned in the opposite lateral decubitus position and consequently in the ipsilateral oblique position for medial lesions in an attempt to simulate the MRI position of the breast. If no morphologically concordant lesions were detected in targeted US, then a CEUS examination was considered.

### CEUS procedures

The purpose and nature of the CEUS procedure was discussed with the patient and all patients provided verbal consent. Nonlinear harmonic imaging using an Esaote MyLabClassC ultrasound scanner (Esaote S.p.A., Genova, Italy) equipped with a 7–13 MHz linear array transducer was performed at baseline with a low mechanical index (MI) of 0.08 in three patients. The remaining examinations were performed using Logiq E9 class US scanner (GE, Wauwatosa, Wisconsin, USA) with a low MI of 0.11. A microbubble contrast agent (SonoVue<sup>®</sup>, Bracco S.p.A., Milan, Italy) was used for localizing occult lesions. The contrast agent was adminis-

tered according to the guidelines of the manufacturer: microbubble dispersion was prepared before use by injecting through the septum the contents of the vial a total of 5 ml of sodium chloride 9 mg/ml (0.9%) solution for injection. The vial was then shaken vigorously for a few seconds until the lyophilisate was completely dissolved. A standard dose of 2.4 ml of dispersion was drawn into a syringe and administered intravenously via an 18-G cannula placed in a cubital vein. Injections were flushed with 5 ml of sodium chloride 9 mg/ml (0.9%) solution.

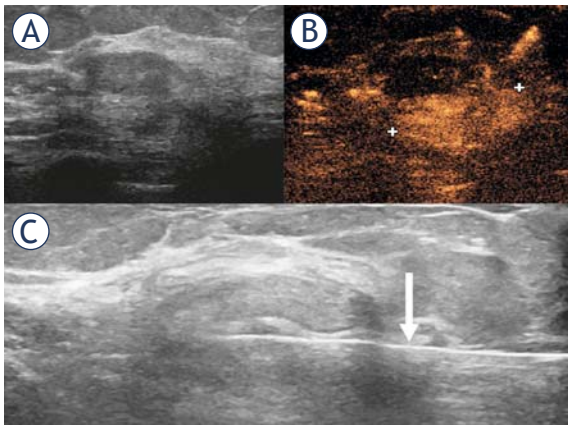
After contrast agent administration, the suspected area was scanned to detect enhancements morphologically concordant with the MRI finding. If the lesion was identified, then the skin area was ink-marked and sterilized. The marked area was confirmed with another SonoVue injection and thereafter, without moving the US probe, the breast area was anesthetized and an incision was made to collect the biopsy. Histopathological CB samples were obtained using 14-G core needle targeted at the area of interest. After the CB, the targeted area was marked with a coil. Both gray scale targeted US and CEUS breast examination were performed in all cases by or under the direct supervision of a breast radiologist with over 20 years of experience in multimodality breast imaging. All interventions were performed by the same senior breast radiologist.

### Histopathological analysis

CB specimens were placed into 10% formalin and embedded in paraffin after fixation. The samples were cut into 5 µm slices at four different levels and stained with haematoxylin and eosin. Biopsy samples were evaluated by two pathologists, first at the time of diagnosis, and then at a multidisciplinary meeting. Diagnosis was confirmed from final surgical specimens when indicated. Both non-invasive and invasive carcinomas were considered malignant.

## Results

MRI detected 8 mass lesions with a mean size of 9 mm (range 5–16 mm) and 2 non-mass enhancement of 10 and 20 mm in largest diameters. Five of these lesions were CEUS positive, of which 4 underwent CEUS-guided CB (Figure 1) and one was primarily marked with a clip for later surgical removal. Of these 5 lesions, 4 proved to be malignant.



**FIGURE 1.** 53 year old female patient with invasive carcinoma of the right breast. MRI detected an occult, BI-RADS 5, oval, 20x16 mm irregular mass lesion in the lower medial quadrant of the left breast (not shown). Targeted US (A) was negative. Contrast-enhanced ultrasound (B) revealed a 21 mm enhancement. Core biopsies were obtained from the enhancement area (C, ARROW) showing the core biopsy needle's position). Both core biopsy and final histology showed high grade invasive carcinoma.

In one of these patients, CEUS showed a round 5 mm lesion which was evaluated to be low grade ductal carcinoma in situ (DCIS) at CB. At final histology, a low grade invasive carcinoma was found in the continuation of the DCIS. It is presumed that the CEUS showed only the DCIS component which was also carefully targeted (Figure 2).

Of the 5 CEUS negative patients, 2 underwent MRI-guided vacuum assisted biopsy and 1 was subjected to MRI-guided coil localization. One patient had a non-mass lesion close to the chest wall deemed non-amenable to MRI-guided biopsy. The patient's preference was follow-up with MRI and mammography. The lesion remained stable after 2 rounds of breast MRI at 6 and 14 months. In one CEUS negative patient, targeted US had revealed only a slight nonspecific architectural distortion at the site of MRI enhancement not deemed to be morphologically concordant with confidence. Nonetheless, it was biopsied and coil marked after the negative CEUS and subsequently proved to be malignant. More detailed patient and lesion characteristics are presented in Table 2.

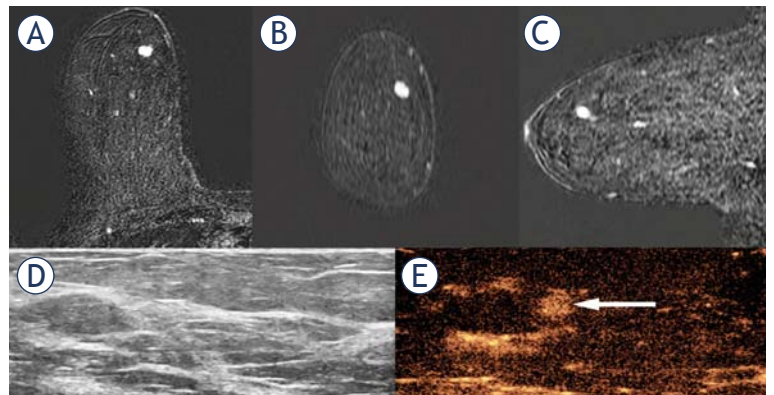
After coiling, a mammogram was acquired in two orthogonal views to confirm the localization of the coil. Seven coil-marked lesions were surgically removed after stereotactic or US-guidance wire localization of the coil. One patient with negative CEUS and malignant MRI-guided vacuum biopsy is treated in another hospital and her

medical records on final treatment decisions are not available.

## Discussion

MRI-detected primarily occult additional lesions are small, have few specific suspicious features, and are therefore challenging to characterize.<sup>6</sup> When imaged by US, these lesions are usually subtle and appear as nonspecific findings.<sup>24</sup> Searching for such lesions can therefore be challenging and time consuming even in the hands of experienced breast radiologists. Our findings indicate that CEUS and CEUS-guided interventions are feasible in the evaluation of half of the MRI only visible lesions and represent a practicable alternative for MRI-guided biopsy in these situations.

In general, CEUS is known to be a safe, rapid, cost-effective and less time-consuming procedure for both the clinician and the patient.<sup>25</sup> In our study, half of the CEUS studies were, however, negative, meaning that there were some additional contrast agent costs. Nevertheless, these costs are less than the savings made when MRI-guidance is avoided. In our institution, the basic list price of CEUS and CEUS-guided biopsy and coil placement is 313 € compared to 1167 € for MRI-guided biopsy. Furthermore, patients can be evaluated and managed immediately in positive cases, thus eliminating the need for rescheduling for MRI-guided intervention.



**FIGURE 2.** 60 year old female patient with invasive carcinoma of no specific type (NST) of the left breast (not shown). MRI detected an occult BI-RADS 4 oval, 7x5 mm mass lesion in the upper medial quadrant of the right breast (A-C thin slice multiplanar reconstruction in axial, coronal and sagittal orientations). Targeted US was negative (D). Contrast-enhanced ultrasound (E, ARROW) revealed a 5 mm round enhancement. Low grade ductal carcinoma in situ (DCIS) was diagnosed in the core biopsy of the enhanced lesion. The final histology was both DCIS (6x4 mm) and low grade invasive carcinoma NST (6x5 mm) in close vicinity.

TABLE 2. Patients, indications for MRI and MRI-only detected lesions' characteristics, interventions and histopathological diagnosis

Case	Age yrs	Indication for MRI	Occult-lesion characteristics on MRI	Occult lesion size	CEUS visualization	Intervention	CB and final histopathological diagnosis and size of lesion
1	71	Preoperative local staging	Mass, round, circumscribed, washout kinetic curve	6 mm	Positive	CEUS-guided CB	CB: Low grade DCIS Final: Low grade DCIS. 3 mm
2	78	Problem solving	Mass, oval, circumscribed, washout kinetic curve	7 mm	Negative	MRI-guided localization	Final: Papilloma. 5 mm
3	64	Incidental breast lesion on CT	NME, focal, heterogeneous	20 mm	Negative	US-guided CB	CB: high grade DCIS. Final: high grade DCIS. 16 mm
4	54	Preoperative local staging	Mass, round, circumscribed, heterogeneous, washout kinetic curve	7 mm	Positive	CEUS-guided clip placement	Final: Intermediate grade IC NST. 5 mm
5	54	Axillary metastasis from an occult breast cancer	Mass, irregular, not circumscribed, plateau kinetic curve	12 mm	Negative	MRI-guided CB	VAB: Carcinoma with medullary feature Final: Carcinoma with medullary feature and high grade DCIS. 10 mm
6	66	Problem solving	Mass, round, circumscribed, ring like enhancement, persistent kinetic curve	5 mm	Positive	CEUS-guided CB. Follow-up	CB: Fibrocystic lesion, liponecrosis
7	30	Problem solving	NME, focal, heterogeneous	10 mm	Negative	Follow-up	--
8	61	Preoperative local staging	Mass, oval, irregular, washout kinetic curve	10 mm	Positive	CEUS-guided CB	CB: Low grade DCIS Final: low grade IC NST 6 mm and Low grade DCIS 5mm
9	53	Preoperative local staging	Mass, oval, irregular, washout kinetic curve	16 mm	Positive	CEUS-guided CB	CB: High grade IC NST Final: High grade IC NST. 13 mm
10	65	Axillary recurrence	Mass, oval, circumscribed, homogeneous, persistent kinetic curve	9 mm	Negative	MRI-guided VAB	VAB: High grade DCIS + suspected microinvasion

CB = Core biopsy; CEUS = Contrast-enhanced ultrasound; CT = Computed tomography; DCIS = Ductal carcinoma in situ; IC NST = Invasive carcinoma no special type; MRI = Magnetic resonance imaging; NME = Non-mass-enhancing; US = Ultrasound; VAB = Vacuum assisted biopsy

Tumor-induced angiogenesis results in immature and dysfunctional vessels with different levels of vascular permeabilities and these are also visualized in dynamic gadolinium enhanced breast MRI. Microvascular density is linked to tumor growth and prognosis. As MRI contrast readily leaks out of the vasculature especially in malignant tumors, it obscures the structures of possible microvessels and complicates the assessment of their density.<sup>26</sup> Nevertheless, it is believed permissible to link the morphology of MRI enhancement to the microvascularity pattern.<sup>27</sup> Furthermore, according to an animal model study conducted by Jansen *et al.*, it has been speculated that gadolinium penetrates and collects inside the dilated DCIS ducts *i.e.* gadolinium accumulation was observed within the intraductal neoplastic space 2 minutes after the administration of the contrast agent. In contrast, CEUS specifically reveals only the microvascular structures without any interfering leakage. Intuitively, it can be assumed that invasive cancers have a denser microvascular network and are thus more

amenable to CEUS visualization. Interestingly, in our study, we were not able to visualize some of the more aggressive DCIS and invasive lesions, indicating that the vascular density of a malignant lesion is not necessarily related to either lesion morphology or histopathology. Therefore, a negative CEUS cannot be used to rule out malignancy and further evaluation with MRI-guided interventions should be deemed necessary. This observation will need to be confirmed in a larger patient population.

The use of CEUS also requires experience and state of the art US scanners with contrast applications. Biopsy and clip-marking of CEUS visualized lesions, although feasible as demonstrated in our study, can prove to be a challenging procedure. It could therefore be speculated that in cases of negative second look targeted US, MRI-guided biopsy would be a straightforward next step procedure. Nevertheless, non-visualization after contrast agent administration does occur also on MRI-guided biopsy in about 8–13% cases requiring

short term follow-up.<sup>28</sup> Furthermore, the technical aspects of MRI-guidance have additional weaknesses including the use of a compression grid system which limits access to areas between grid holes and makes it difficult to localize lesions in the retromamillary region, near the chest wall and in axillary tail. Even though compression grid freehand MRI biopsy technique is not subject to localization limitations, it might prolong examination time due to repeated imaging to confirm proper needle placement.<sup>29</sup> Nonetheless, regardless of all the previously mentioned difficulties, we believe that CEUS confers considerable added value in the immediate evaluation of occult lesions and therefore more investigations into its applicability are warranted.

The small number of patients in this study is a major limitation and therefore no definitive solid conclusions can be made about the diagnostic performance and cost-effectiveness of CEUS in this indication. Nevertheless, our study can be considered as a pilot report, clearly showing that some small US occult lesions do enhance with CEUS and therefore this procedure is feasible and further investigations on this issue are well-founded.

In conclusion, CEUS is a feasible and more convenient alternative to MRI-guided biopsy for some MRI only visible lesions, resulting in a more cost-effective and less time-consuming practice. CEUS has the potential to be included in the diagnostic algorithm for the evaluation of MRI only visible breast lesions. Based on our initial experience, further studies are warranted to confirm our findings and possibly to define which lesions benefit most from this technique.

## Acknowledgements

This study was supported in part (AN) by Kuopio University Hospital (VTR grant: 5063542) and Cancer Society of Finland. The funders had no role in study design, data collection and analysis, decision to publish, or preparation of the manuscript.

## References

- Breslin TM, Banerjee M, Gust C, Birkmeyer NJ. Trends in advanced imaging use for women undergoing breast cancer surgery. *Cancer* 2013; **119**: 1251-6. doi: 10.1002/cncr.27838
- Houssami N, Hayes DF. Review of preoperative magnetic resonance imaging (MRI) in breast cancer: should MRI be performed on all women with newly diagnosed, early stage breast cancer? *CA Cancer J Clin* 2009; **59**: 290-302. doi: 10.3322/caac.20028
- Teifke A, Lehr HA, Vomweg TW, Hlawatsch A, Thelen M. Outcome analysis and rational management of enhancing lesions incidentally detected on contrast-enhanced MRI of the breast. *AJR Am J Roentgenol* 2003; **181**: 655-62. doi: 10.2214/ajr.181.3.1810655
- Brennan ME, Houssami N, Lord S, Macaskill P, Irwig L, Dixon JM, et al. Magnetic resonance imaging screening of the contralateral breast in women with newly diagnosed breast cancer: systematic review and meta-analysis of incremental cancer detection and impact on surgical management. *J Clin Oncol* 2009; **27**: 5640-9. doi: 10.1200/JCO.2008.21.5756
- Houssami N, Turner R, Morrow M. Preoperative magnetic resonance imaging in breast cancer: meta-analysis of surgical outcomes. *Ann Surg* 2013; **257**: 249-55. doi: 10.1097/SLA.0b013e31827a8d17
- Arponen O, Masarwah A, Sutela A, Taina M, Könönen M, Sironen R, et al. Incidentally detected enhancing lesions found in breast MRI: analysis of apparent diffusion coefficient and T2 signal intensity significantly improves specificity. *Eur Radiol* 2016; **26**: 4361-70. doi: 10.1007/s00330-016-4326-2
- Spick C, Baltzer PA. Diagnostic utility of second-look US for breast lesions identified at MR imaging: systematic review and meta-analysis. *Radiology* 2014; **273**: 401-9. doi: 10.1148/radiol.14140474
- Hollowell L, Price E, Arasu V, Wisner D, Hylton N, Joe B. Lesion morphology on breast MRI affects targeted ultrasound correlation rate. *Eur Radiol* 2015; **25**: 1279-84. doi: 10.1007/s00330-014-3517-y
- Newburg AR, Chhor CM, Young Lin LL, Heller SL, Gillman J, Toth HK, et al. Magnetic resonance imaging-directed ultrasound imaging of non-mass enhancement in the breast: Outcomes and frequency of malignancy. *J Ultrasound Med* 2017; **36**: 493-504. doi: 10.7863/ultra.16.03001
- Gao Y, Bagadiya NR, Jardon ML, Heller SL, Melsaether AN, Toth HB, et al. Outcomes of preoperative MRI-guided needle localization of nonpalpable mammographically occult breast lesions. *AJR Am J Roentgenol* 2016; **207**: 676-84. doi: 10.2214/AJR.15.15913
- Wilson SR, Greenbaum LD, Goldberg BB. Contrast-enhanced ultrasound: what is the evidence and what are the obstacles? *AJR Am J Roentgenol* 2009; **193**: 55-60. doi: 10.2214/AJR.09.2553
- Buckley DL, Drew PJ, Mussurakis S, Monson JR, Horsman A. Microvessel density of invasive breast cancer assessed by dynamic Gd-DTPA enhanced MRI. *J Magn Reson Imaging* 1997; **7**: 461-4.
- Giesel FL, Choyke PL, Mehndiratta A, Zechmann CM, von Tengg-Kobligh H, Kayser K. Pharmacokinetic analysis of malignant pleural mesothelioma-initial results of tumor microcirculation and its correlation to microvessel density (CD-34). *Acad Radiol* 2008; **15**: 563-70. doi: 10.1016/j.acra.2007.12.014
- Knopp MV, Weiss E, Sinn HP, Mattern J, Junkermann H, Radeleff J, et al. Pathophysiologic basis of contrast enhancement in breast tumors. *J Magn Reson Imaging* 1999; **10**: 260-6.
- Hayes C, Padhani AR, Leach MO. Assessing changes in tumour vascular function using dynamic contrast-enhanced magnetic resonance imaging. *NMR Biomed* 2002; **15**: 154-63.
- Jansen SA, Paunesku T, Fan X, Woloschak GE, Vogt S, Conzen SD, et al. Ductal carcinoma in situ: X-ray fluorescence microscopy and dynamic contrast-enhanced MR imaging reveals gadolinium uptake within neoplastic mammary ducts in a murine model. *Radiology* 2009; **253**: 399-406. doi: 10.1148/radiol.2533082026
- Giorgio R, Roberta C. *Enhancing the role of ultrasound with contrast agents*. Milan: Springer; 2006.
- Du J, Wang L, Wam CF, Hua J, Fang H, Chen J, et al. Differentiating benign from malignant solid breast lesions: combined utility of conventional ultrasound and contrast-enhanced ultrasound in comparison with magnetic resonance imaging. *Eur J Radiol* 2012; **81**: 3890-9. doi: 10.1016/j.ejrad.2012.09.004
- Jiang YX, Liu H, Liu JB, Zhu QL, Sun Q, Chang XY. Breast tumor size assessment: comparison of conventional ultrasound and contrast-enhanced ultrasound. *Ultrasound Med Biol* 2007; **33**: 1873-81. doi: 10.1016/j.ultras-medbio.2007.06.002
- Corcioni B, Santilli L, Quercia S, Zamagni C, Santini D, Taffurelli M, et al. Contrast-enhanced US and MRI for assessing the response of breast cancer to neoadjuvant chemotherapy. *J Ultrasound* 2008; **11**: 143-50. doi: 10.1016/j.jus.2008.09.007
- Fujisawa T, Hirakata T, Yanagita Y, Iijima M, Horikoshi H, Takeuchi K, et al. The detection of pCR after PST by contrast-enhanced ultrasonography for breast cancer. *Breast Cancer* 2013; **20**: 75-82. doi: 10.1007/s12282-011-0311-4

22. Rautiainen S, Sudah M, Joukainen S, Sironen R, Vanninen R, Sutela A. Contrast-enhanced ultrasound -guided axillary lymph node core biopsy: Diagnostic accuracy in preoperative staging of invasive breast cancer. *Eur J Radiol* 2015; **84**: 2130-6. doi: 10.1016/j.ejrad.2015.08.006
23. Sardanelli F, Boetes C, Borisch B, Decker T, Federico M, Gilbert FJ, et al. Magnetic resonance imaging of the breast: recommendations from the EUSOMA working group. *Eur J Cancer* 2010; **46**: 1296-316. doi: 10.1016/j.ejca.2010.02.015
24. Abe H, Schmidt RA, Shah RN, Shimauchi A, Kulkarni K, Sennett CA, et al. MR-directed ("Second-Look") ultrasound examination for breast lesions detected initially on MRI: MR and sonographic findings. *AJR Am J Roentgenol* 2010; **194**: 370-7. doi: 10.2214/AJR.09.2707
25. Westwood M, Joore M, Grutters J, Redekop K, Armstrong N, Lee K, et al. Contrast-enhanced ultrasound using SonoVue(R) (sulphur hexafluoride microbubbles) compared with contrast-enhanced computed tomography and contrast-enhanced magnetic resonance imaging for the characterisation of focal liver lesions and detection of liver metastases: a systematic review and cost-effectiveness analysis. *Health Technol Assess* 2013; **17**: 1-243. doi: 10.3310/hta17160
26. Heijblom M, Klaase JM, van den Engh FM, van Leeuwen TG, Steenberg W, Manohar S. Imaging tumor vascularization for detection and diagnosis of breast cancer. *Technol Cancer Res Treat* 2011; **10**: 607-23. doi: 10.7785/rt.2012.500227
27. Santamaria G, Velasco M, Farrús B, Caparrós FX, Fernández PL. Dynamic contrast-enhanced MRI reveals the extent and the microvascular pattern of breast ductal carcinoma in situ. *Breast J* 2013; **19**: 402-10. doi: 10.1111/tbj.12135
28. Chevrier MC, David J, Khoury ME, Lalonde L, Labelle M, Trop I. Breast biopsies under magnetic resonance imaging guidance: Challenges of an essential but imperfect technique. *Curr Probl Diagn Radiol* 2016; **45**: 193-204. doi: 10.1067/j.cpradiol.2015.07.002
29. Choi HY, Kim SM, Jang M, Yun BL, Kim SW, Kang E, et al. MRI-guided intervention for breast lesions using the freehand technique in a 3.0-T closed-bore MRI scanner: feasibility and initial results. *Korean J Radiol* 2013; **14**: 171-8. doi: 10.3348/kjr.2013.14.2.171