

● Case report

PRENATAL MICROCEPHALY AND HYDROCEPHALUS AND NORMAL HEART ANATOMY, POSTNATAL DIAGNOSIS OF NIJMEGEN SYNDROME - CASE REPORT

**Authors:**

Monika Wójtowicz-Marzec¹, Maria Respondek-Liberska^{2,3}

1. Student of the Medical University of Lodz 2. Department of Prenatal Cardiology, Polish Mother's Memorial Hospital Research Institute, Lodz, Poland, 3. Medical University of Lodz, Department of Diagnoses and Prevention Fetal Malformations

Prenat Cardio 2018 Jan; 8(1):53-58
DOI: 10.1515/pcard-2018-0008

Abstract

Nijmegen breakage syndrome is a rare autosomal condition mainly characterized by microcephaly. Patients are predisposed to malignancies due to combined immunodeficiency. The presented patient had prenatally diagnosed microcephaly with atypical ventriculomegaly of occipital horns. Fetal echocardiography showed a normal fetal heart anatomy. Diagnosis of Nijmegen syndrome was confirmed postnatally. The differential diagnosis of fetal microcephaly should take into account intrauterine infections, perinatal brain injury, congenital malformations or biological variants..

Key words: fetal echocardiography, Nijmegen syndrome, microcephaly, hydrocephalus

CASE REPORT:

It was third pregnancy of a 30 years old woman, who had two healthy boys born 10 and 1,5 years before. Her first and second trimester scan presented values with the normal range. At the 32th week of gestation ventriculomegaly and suspicion of hypotrophy was detected by primary care obstetrician and fetus was referred to tertiary center for further evaluation.

At the 34th week of gestation fetal biometry was consistent with the 30th week of gestation and suggested fetal weight based on basic parameters such as biparietal diameter, head circumferences, abdominal circumferences and femur length (BPD, HC, AC and FL) was 1432+- 209g (Fig. 1,2,3). Measurements below the norm (-3SD) concerned head circumferences and biparietal circumferences.

The image of the brain revealed ventriculomegaly of occipital horns with dilatation up to 19mm and 23mm (Fig.4). In 3D ultrasound fetal face seemed dysmorphic with sloping forehead and receding mandible (Fig. 5).

Fetal echocardiography showed a normal fetal heart anatomy and the heart diameter at the level of mitral and tricuspid valves was 33mm (Fig.6). At the level of

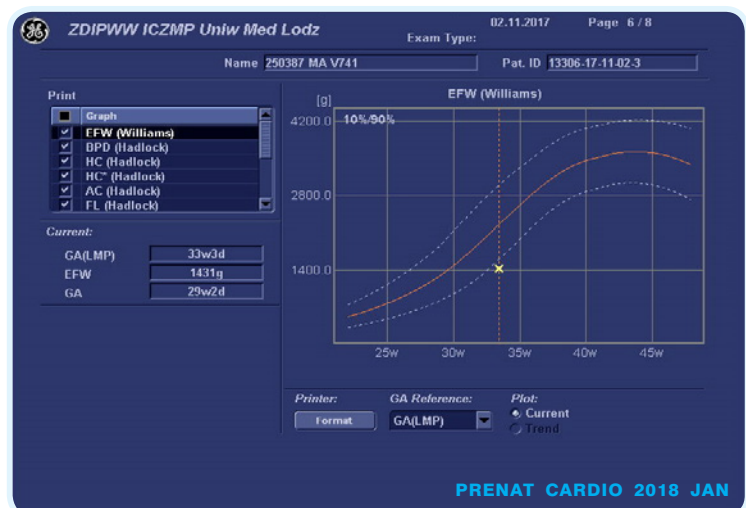


Fig. 1. Fetal biometry EFW

How to cite this article:
Wójtowicz-Marzec M,
Respondek-Liberska M.
*Prenatal microcephaly and
hydrocephalus and normal heart
anatomy, postnatal diagnosis of
Nijmegen syndrome - case report*
Prenat Cardio 2018 Jan; 8(1):53-58

mediastinum there were three vessels with typical arrangement - pulmonary artery and aortic arch with similar size, superior vena cava typically narrower in diameter (Fig. 7). FHR was 135/min, sinus rhythm. Fetus was in a good condition and assessed 10 points in CVPS.

In differential diagnosis several options were considered (Table 1).

No invasive tests were accepted by pregnant woman at this point and conservative approach was taken.

Corresponding author: monikawmarzec@gmail.com

Submitted: 2018-08-13, accepted: 2018-09-23

Congenital malformation seen prenatally					
Differential diagnosis of microcephaly in prenatal period	Microcephaly Mild <10th centile Severe <3rd centile	Brain defects seen prenatally	Congenital heart defects	Other main malformations seen prenatally	Ref.
Chromosomal defects					
Trisomy 21	Mild	-	40% CHD AVSD VSD	Duodenal atresia Increased nuchal translucency	11
Trisomy 13	Severe	Holoprosencephaly Meningocele	VSD dextrocardia	Increased nuchal translucency Eye defects	12
Trisomy 18	Severe	Choroid plexus cysts Dandy-Walker variant	VSD	Increased nuchal translucency Omphalocele Underdeveloped fingers or toes Cleft palate	12
Cri du chat syndrome 5p-	Mild to severe	-	25% CHD ASD VSD ToF	Renal malformation	13
Single genetic defects					
Nijmegen syndrome	Severe (100%)	Single described cases: 1 choroid cyst 2 hydrocephaly	-	-	1
Dubowitz syndrome	Severe	Agenesis of corpus callosum	-	-	14
Meckel-Gruber syndrome	Mild	occipital encephalocele		Polydactyly 95% Dysplastic kidneys	15
Cornelia de Lange syndrome	Severe	-	25% CHD VSD	Increased nuchal translucency UGR	16
Mowat-Wilson syndrome	Severe (81%)	Agenesis of corpus callosum	52% CHD	-	17
Intrauterine infections					
Rubella	Mild to severe	-	PS >95% PDA	-	8
Zika virus	Severe	-	-	-	8
Intrauterine event or problem					
Placental insufficiency – extreme	Mild				8
Vascular incident such as stroke	Mild				8
Teratogens					
Alcohol	Mild	Dysgenesis of corpus callosum Dysgenesis of cerebellum	25-30% CHD VSD PDA ASD TOF	IUGR	8
Antiepileptic drugs	Mild		15-30% CHD TGA VSD TOF		8

Table 1. Differential diagnosis of microcephaly in prenatal period

As fetal heart was normal and no functional abnormalities were detected in family counselling a favourable outcome was discussed regarding the prognosis of the uncomplicated further weeks of pregnancy and neonatal period, and detailed genetic diagnosis was postponed for later on, after delivery.

POSTNATAL OUTCOME

The female baby was delivered by cesarean section at 36th week of gestation, 3 weeks after the last fetal ECHO. Neonate was born in a good condition assessed on 10/10 in the Apgar score. Body weight (2400g) and length (50cm) were in the normal range but head circumference (29cm) was below 3 centile according to Fenton Preterm Growth Charts. Clinical investigation showed prominent midface, sloping forehead, receding mandible and syndactyly of the 4th and 5th toes of the left foot.

Postnatal echo ruled out structural abnormality of the heart. Ultrasonography of the brain confirmed ventriculomegaly mainly of the occipital horns with thinning of the brain tissue in the occipital region to 5mm. Blood flow in the anterior cerebral artery was within the normal range with resistance index 0,67.

Magnetic resonance imaging reveal widening of the occipital horns to 38mm on the right side and 41mm on the left side without the features of increased intracranial pressure (Fig.8,9).

Blood laboratory findings reveal transient decreases in white blood cells count. Congenital infections with cytomegalovirus, rubella and herpes virus were ruled out.

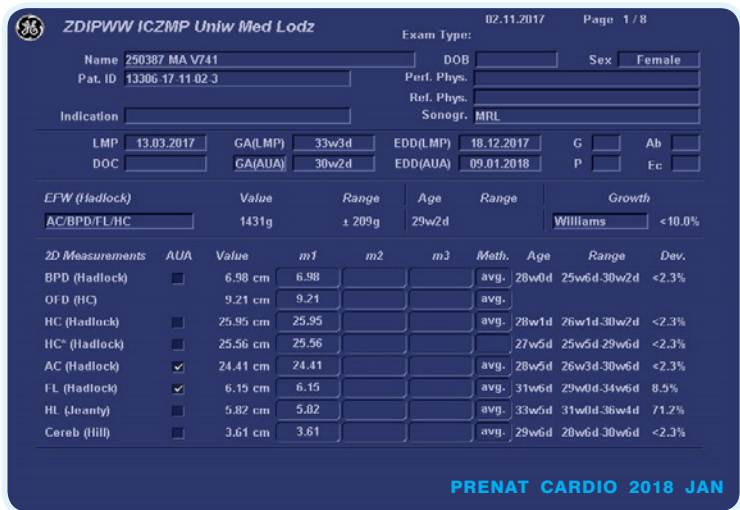


Fig. 2. Fetal biometry AC

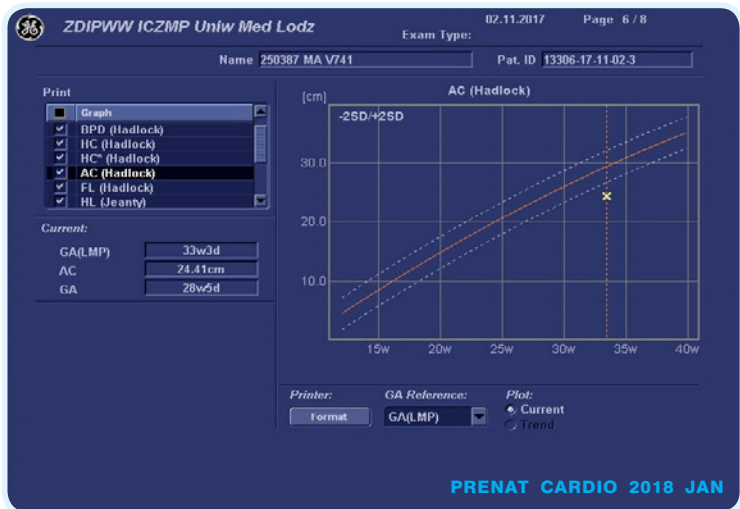


Fig. 3. Fetal biometry

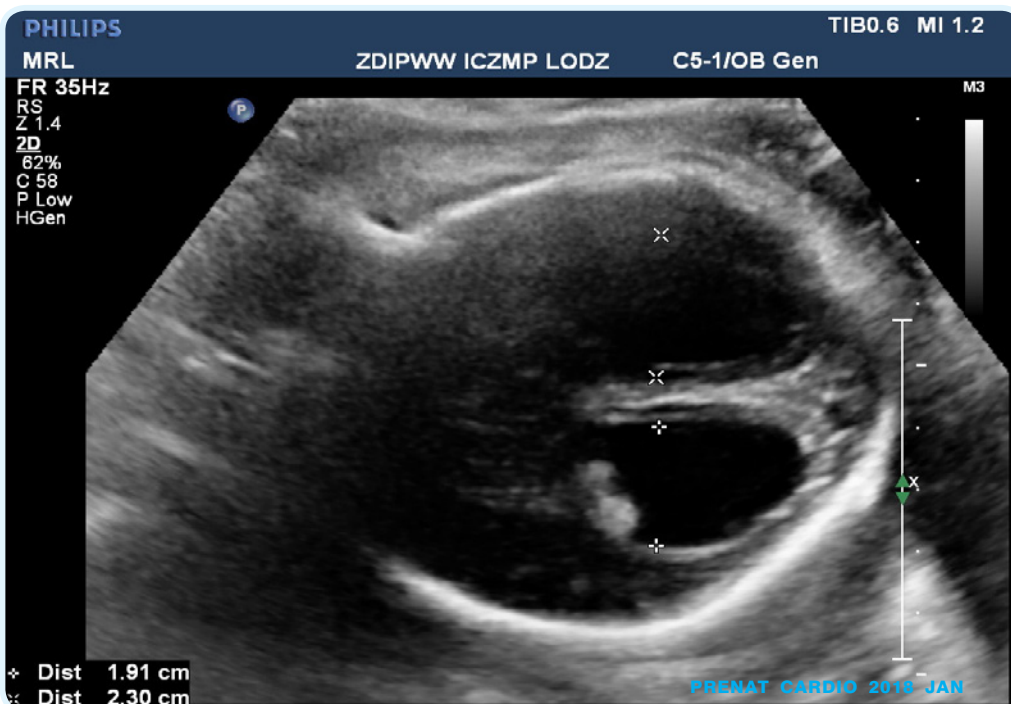


Fig. 4. Ventriculomegaly of occipital horns in fetus

The sleep EEG test was abnormal and was recorded the cyclical group of generalized free delta waves during physiological sleep.

Neurological examination show slightly increased muscle tone of the limbs and increased tremors.

Genetic consultation suggest hereditary course of microcephaly and molecular testing confirmed Nijmegen breakage syndrome (NBS).

At the age of 10 weeks infant girl was in a good condition.

Echocardiography revealed trace regurgitation of tricuspid and mitral valve. Foramen ovale was closed but still was seen small blood flow through patent ductus arteriosus. Symmetrical ventriculomegaly of the occipital horns was stable in diameter and without progression in size (Fig. 10).

DISCUSSION

Nijmegen breakage syndrom (NBS) is rare autosomal recessive condition encountered most frequently among Slavic population due to a founder mutation. The principal clinical manifestations of the syndrome seen prenataly are: microcephaly and mild growth retardation. In rare condition, when hydrocephaly is diagnosed additionally, microcephaly is not so obvious². The dysmorfic facial features result from frontal lobe hypoplasia presents typically: prominent midface, sloping forehead and receding mandible. Additional less frequent congeniatal anomalies seen prenataly are: minor skeletel anomalies, genito-urinary system defects. Worth noticing is normal heart anatomy in most cases. Prognosis is generally poor due to the high rate of malignancies due to disabled DNA repair complex. Till now was reported in the medical literature more than 150 patients, mostly from European countries¹. There are reports of prenatal tests of families burdened with this syndrome using assay of radioresistant DNA synthesis in cultured chorionic villus (CV) cells and/or amniotic fluid (AF) cells^{3,4}. There was also proposed screening of Nijmegen breakage syndrome mutations by polymerase chain reaction using sequence-specific primers⁵. No article was found about prenatal diagnosis of the Nijmegen syndrome in fetus with no family history.

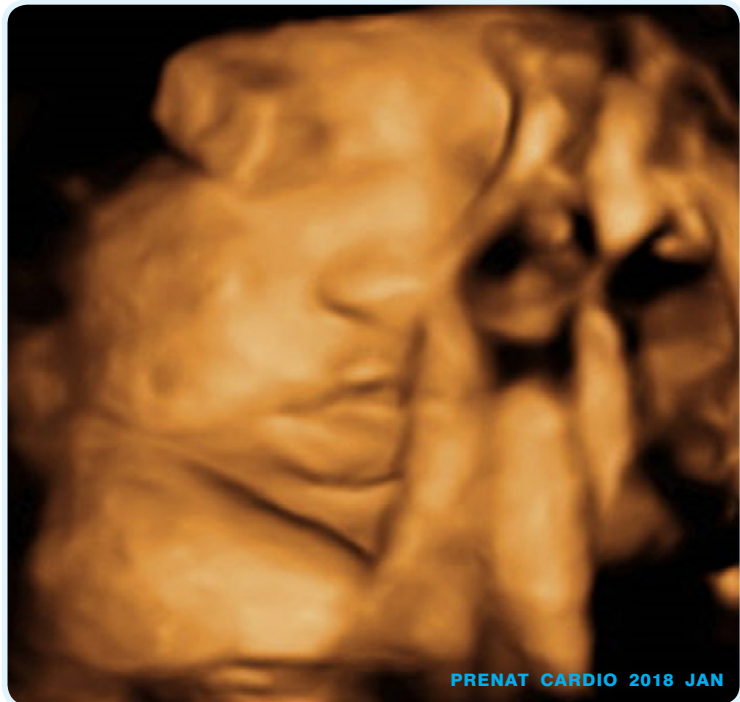


Fig. 5. 3D ultrasound fetal face

Fetal microcephaly (Fmic) is defined as a fetal HC 3SD below the mean (less than the 3rd percentile) for gestational age according to Jeanty et al.'s reference range. The new INTERGROWTH-21(st) Project suggested applied for evaluation of the Fmic positive predictive value (PPV) for diagnosis of microcephaly at birth. Still the evaluated reference ranges result in considerable over-diagnosis of fetal microcephaly with PPV 66.7%⁷.

An occipitofrontal circumference (OFC) at birth is necessary to establish a diagnosis of primary microcephaly^{6,9}. A genetic diagnosis is more likely when

microcephaly is defined by an OFC more than 3 SD below the appropriate mean because is more likely to be associated with disorders affecting brain development⁸.

The differential diagnosis of microcephaly is heterogeneous and many causes are not identified. Fetus with severe microcephaly need to be diagnosed toward intrauterine infections, influence of teratogens, perinatal brain injury and other congenital malformations. Among diagnosed cases, up to 30% of microcephaly might have

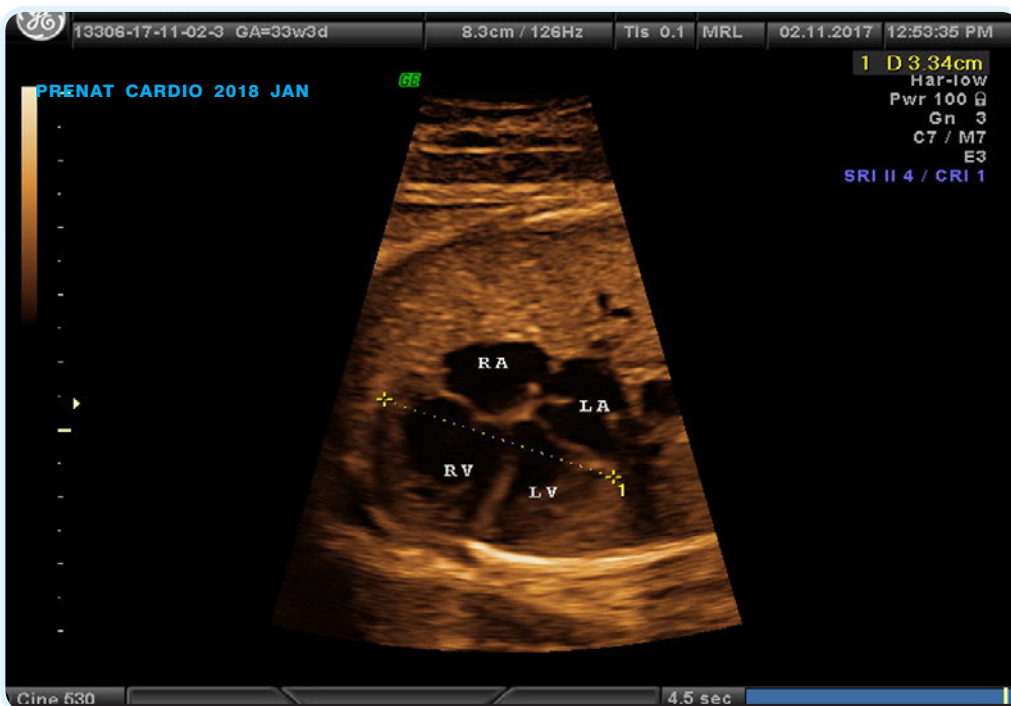

Fig. 6. Fetal heart 4 chamber view

genetic background. Chromosomal defects are often associated with congenital heart defects. Single genetic defects like Nijmegen breakage syndrome are rarely linked with heart malformations^{8,18}.

Late symptoms of the syndrome are another prove for anomaly scan in 3rd trimester and an indication for fetal echocardiography¹⁹.

CONCLUSION

Nijmegen breakage syndrome is a rare condition associated with severe microcephaly and fetal ventriculomegaly might me additional feature, for the first time described in presented case.

Prenatal echocardiography in case of extracardiac anomaly may be helpful for complete work-up of parents cousseling, reassuring good postnatal clinical condition

Severe fetal microcephaly with OFC < 3SD is associated with high risk genetic disorder.

References

1. Chrzanowska K., Varon R., Demuth L., Nijmegen breakage syndrome (NBS). *Orphanet Journal of Rare Disease* 2012;7:13
2. Chrzanowska K., Stumm M., Bekiesińska-Figatowska M., Varon R., Bialecka M., Gregorek H., Michałkiewicz J., Krajewska-Walasek M., Józwiak S., Reis A. Atypical clinical Picture of the Nijmegen breakage syndrome associated with developmental abnormalities of the brain. *J Med Genet* 2001;38
3. Jaspers NG, van der Kraan M, Linssen PC, Maçek M, Seemanová E, Kleijer WJ. First-trimester prenatal diagnosis of the Nijmegen breakage syndrome and ataxia telangiectasia using an assay of radioresistant DNA synthesis. *Prenat Diagn.* 1990 Oct;10(10):667-74.
4. Kleijer WJ, van der Kraan M, Los FJ, Jaspers NG. Prenatal diagnosis of ataxia-telangiectasia and Nijmegen Breakage syndrome by the assay of radioresistant DNA synthesis *Int J Radiat Biol.* 1994 Dec;66(6 Suppl):S167-74.
5. Di Masi A, Antoccia A, Spadoni E, Varon-Mateeva R, Maraschio P, Tanzarella C. Screening of Nijmegen breakage syndrome 1 mutations in four unrelated families by polymerase chain reaction using sequence-specific primers. *Genet Test.* 2006 Spring;10(1):24-30.

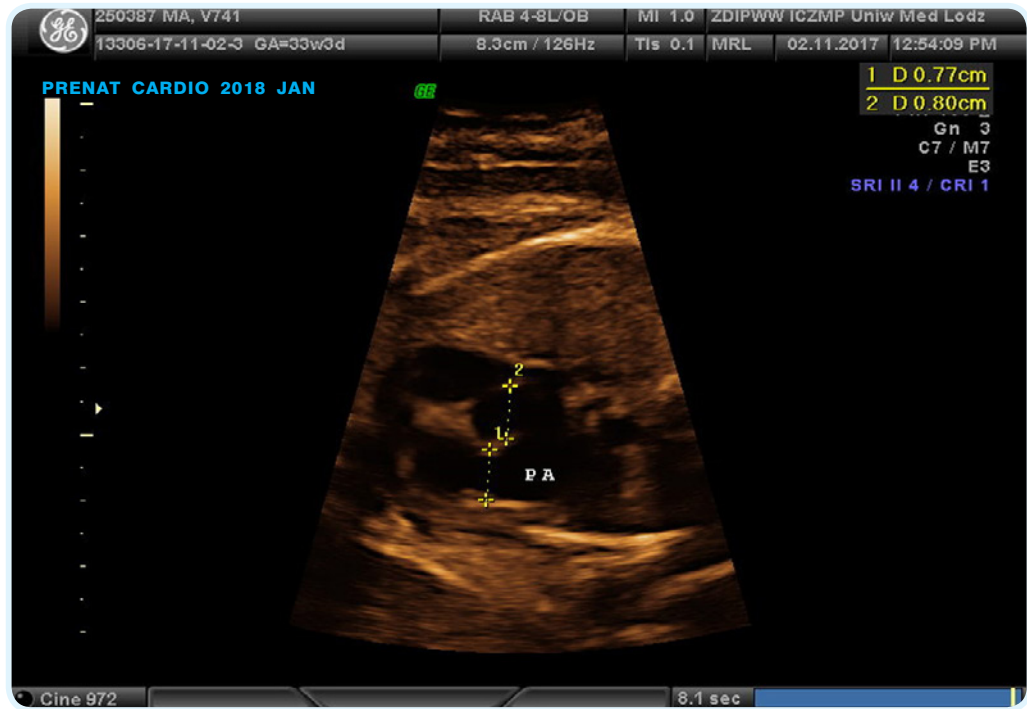


Fig. 7. Fetal mediastinum with typical arrangement of three vessels.

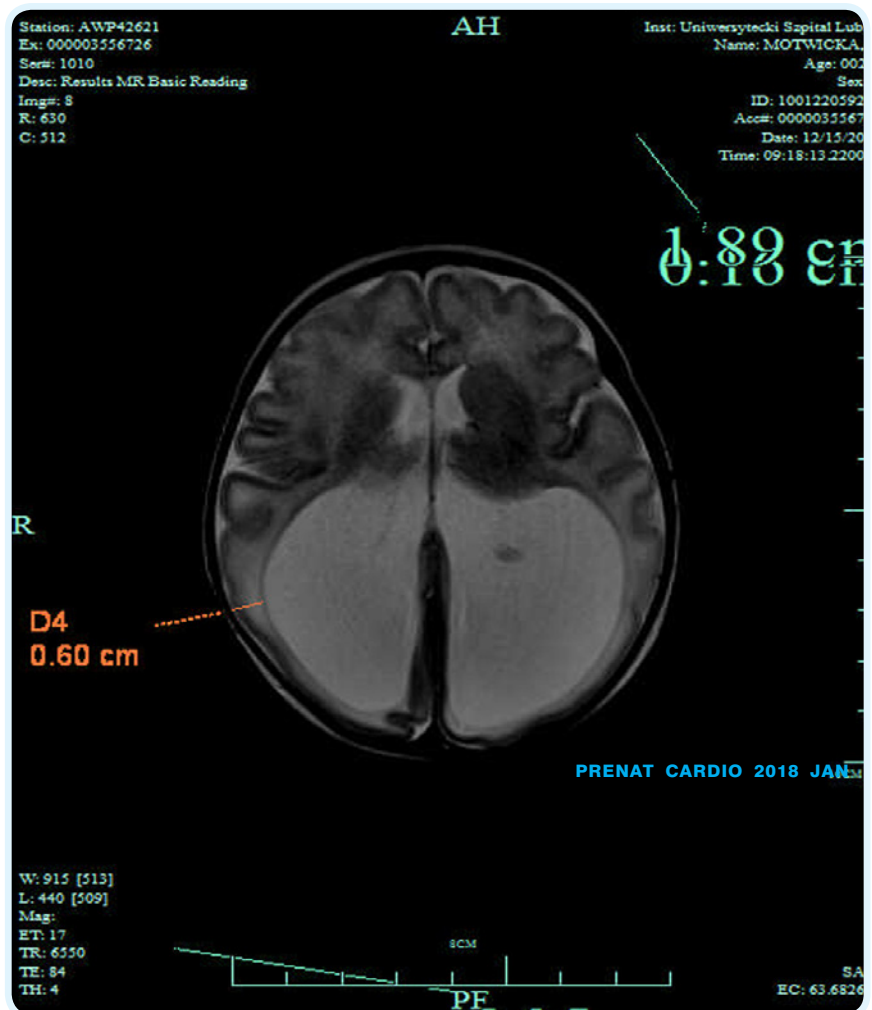


Fig. 8. MRI transverse view ventriculomegaly of occipital horns

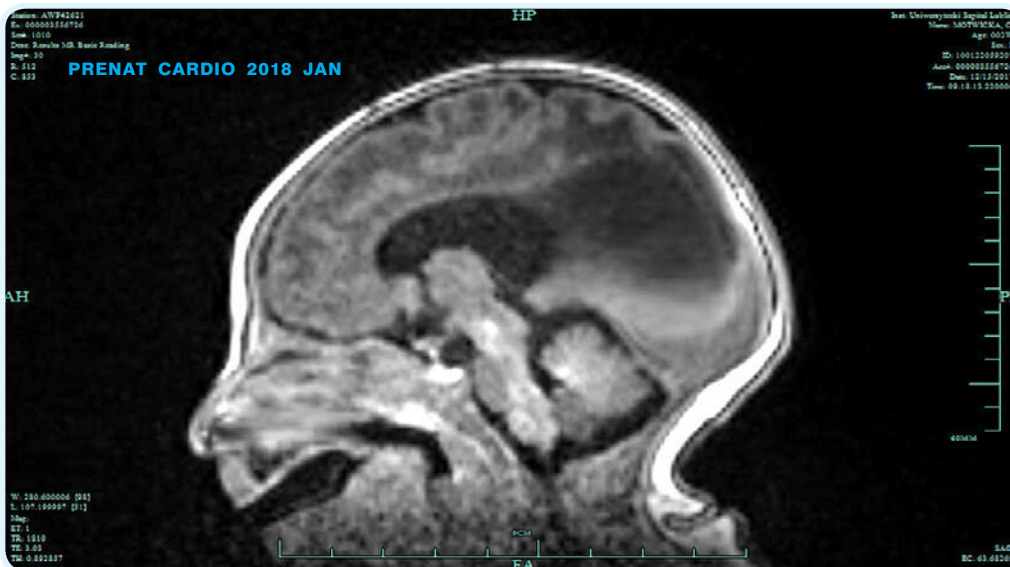


Fig. 9. MRI sagittal view ventriculomegaly of occipital horns



Fig. 10. Infant baby at the age of 10 weeks - photo thanks to mother's courtesy

Division of work:

M. Wójtowicz-Marzec: first draft of the manuscript, analyzes of the data

M. Respondek-Liberska- final version

Disclosure statements:

Financial support: none / **Financial disclosers:** none / **Status:** New submission.

This work has not been previously published in any language anywhere and is not under simultaneous consideration or in press by another journal

Author statement: We have no founding sources to report.

All authors certify that there is no actual potential conflict of interest in relation to this article.

Acknowledgement: The authors would like to thank MD Marcin Pańszczyk for facilitation medical records from primary examinations.

6. Fenton TR, Kim JH. A systematic review and meta-analysis to revise the Fenton growth chart for preterm infants. *BMC Pediatr.* 2013 Apr 20;13:59. doi: 10.1186/1471-2431-13-59.

7. Leibovitz Z, Daniel-Spiegel E, Maligner G, Haratz K, Tamarkin M, Gindes L, Schreiber L, Ben-Sira L, Lev D, Shapiro I, Bakry H, Weizman B, Zreik A, Egenburg S, Arad A, Tepper R, Kidron D, Lerman-Sagie T. Prediction of microcephaly at birth using three reference ranges for fetal head circumference: can we improve prenatal diagnosis? *Ultrasound Obstet Gynecol.* 2016 May;47(5):586-92. doi: 10.1002/uog.15801.

8. Pennesi P., Romanzi D., Verducci Y. The differential diagnosis of fetal microcephaly. *Giorn. It. Ost. Gin. Giornale Italiano di Ostetricia e Ginecologia CIC Edizioni Internazionali* 2014 July-October; 36(4/5): 427-434. ISSN: 0391-9013

9. Harris SR. Measuring head circumference: Update on infant microcephaly. *Can Fam Physician.* 2015 Aug;61(8):680-4.

10. Leibovitz Z, Lerman-Sagie T. Diagnostic approach to fetal microcephaly *Eur J Paediatr Neurol.* 2018 Jun 30. pii: S1090-3798(18)30014-X. doi: 10.1016/j.ejpn.2018.06.002.

11. Epstein, Charles J. *The consequences of chromosome imbalance: principles, mechanisms, and models.* Cambridge: Cambridge University Press. 2007. Pp. 255-256. ISBN 978-0-521-03809-6.

12. Acharya K, Leuthner S, Clark R, Nghiem-Rao TH, Spitzer A, Lagatta J. Major anomalies and birth-weight influence NICU interventions and mortality in infants with trisomy 13 or 18. *J Perinatol.* 2017 Apr; 37(4):420-426. Epub 2017 Jan 12.

13. Cerruti Mainardi. *Cri du Chat syndrome.* Orphanet Journal of Rare Diseases. September 5, 2006; doi:10.1186/1750-1172-1-33.

14. Dubowitz syndrome *Genetic and Rare Diseases Information Center (GARD) – an NCATS Program.* rarediseases.info.nih.gov.

15. Abdelmoneim E. M. Kheir, Abdelmutalab I., Ilham M., Ibtisama M.A., Sara A. Elamin, Esra A. Awadalla, Mohammed H. Gadalla, Tagwa A. Hamdoon Meckel-Gruber syndrome: A rare and lethal anomaly *Sudan J Paediatr.* 2012; 12(1): 93-96.

16. Boyle MI, Jespersgaard C, Brøndum-Nielsen K, Bisgaard AM, Tümer Z. *Cornelia de Lange syndrome.* *Clin Genet.* 2015 Jul;88(1):1-12. doi: 10.1111/cge.12499. Epub 2014 Oct 28. Review.

17. Garavelli L, Cerruti Mainardi P. *Mowat-Wilson syndrome.* *Orphanet J Rare Dis.* 2. 1, s. 42, 2007.

18. Respondek-Liberska M, Szymkiewicz-Dangel J, Tobota Z, Słodki M. *Założenia i wstępne wnioski Ogólnopolskiego Rejestru Patologii Kardiologicznych u płodu.* *Polski Przegląd Kardiologiczny* 2008, 10; 129-135.

19. Strzelecka I, Słodki M, Płużańska J, Moszura T, Węgrzynowski J, Respondek-Liberska M. *Routine third trimester fetal cardiac evaluation: time for consideration.* *Prenat Cardio.* 2015 Sep; 5(3):18-23. doi 10.12847/09154