

# Severity Stratification by Compression Ultrasound Examination in Lipodermatosclerosis and Diabetic Dermopathy Patients: a Report of Three Cases

Cristian Podoleanu<sup>1</sup>, Bogdan Dobrovat<sup>2</sup>, Simona Stolnicu<sup>3,4</sup>, Anca Chiriac<sup>5,6,7</sup>

<sup>1</sup> Department of Internal Medicine, University of Medicine and Pharmacy, Tîrgu Mureş, Romania

<sup>2</sup> "Gr.T. Popa" University of Medicine and Pharmacy, Iaşi, Romania

<sup>3</sup> Department of Pathology, University of Medicine and Pharmacy, Tîrgu Mureş, Romania

<sup>4</sup> Histopat-Invest Laboratory, Tîrgu Mureş, Romania

<sup>5</sup> Apollonia University, Department of Dermatology, Iaşi, Romania

<sup>6</sup> "Petru Poni" Institute of Macromolecular Chemistry of the Romanian Academy, Iaşi, Romania

<sup>7</sup> Nicolina Medical Center, Iaşi, Romania

## CORRESPONDENCE

**Cristian Podoleanu**

Str. Gheorghe Marinescu nr. 38  
540099 Tîrgu Mureş, Romania  
Tel: +40 744 573 784  
E-mail: podoleanu@me.com

## ARTICLE HISTORY

Received: 19 March, 2017

Accepted: 27 May, 2017

**Bogdan Dobrovat** • Str. Universităţii nr. 16, 700115 Iaşi, Romania. Tel: +40 232 267 801

**Simona Stolnicu** • Str. Gheorghe Marinescu nr. 38, 540139 Tîrgu Mureş, Romania. Tel: +40 265 215 551.

**Anca Chiriac** • Str. Muzicii nr. 2, 700399 Iaşi, Romania. Tel: +40 232 210 310

## ABSTRACT

Lipodermatosclerosis and diabetic dermopathy are low-risk skin lesions with many similar clinical features, except for venous abnormalities such as chronic venous insufficiency, but are rarely a reason for referring the patient to vascular ultrasound examination. We present 3 serial cases in which the compression ultrasound examination (CUS) of the venous circulation of the affected limbs was of utmost importance in the severity stratification. Asymptomatic deep venous thrombosis (DVT) was found in the first two cases, while in the third case the CUS excluded any type of vascular involvement, leading to a definite diagnosis of diabetic dermopathy. Lipodermatosclerosis may be associated with asymptomatic DVT due to chronic venous insufficiency, and early referral to CUS positively impacts further patient management.

**Keywords:** lipodermatosclerosis, diabetic dermopathy, compression ultrasound, severity stratification

## INTRODUCTION

Asymptomatic deep venous thrombosis (DVT) and its related disorder, venous thromboembolism (VTE), are major health care challenges: VTE is the 3rd most frequent acute cardiovascular syndrome after myocardial infarction and stroke.<sup>1</sup>

DVT is confirmed by compression ultrasound (CUS) examination, but the patients most likely to be referred to CUS are either symptomatic, or asymptomatic but in a

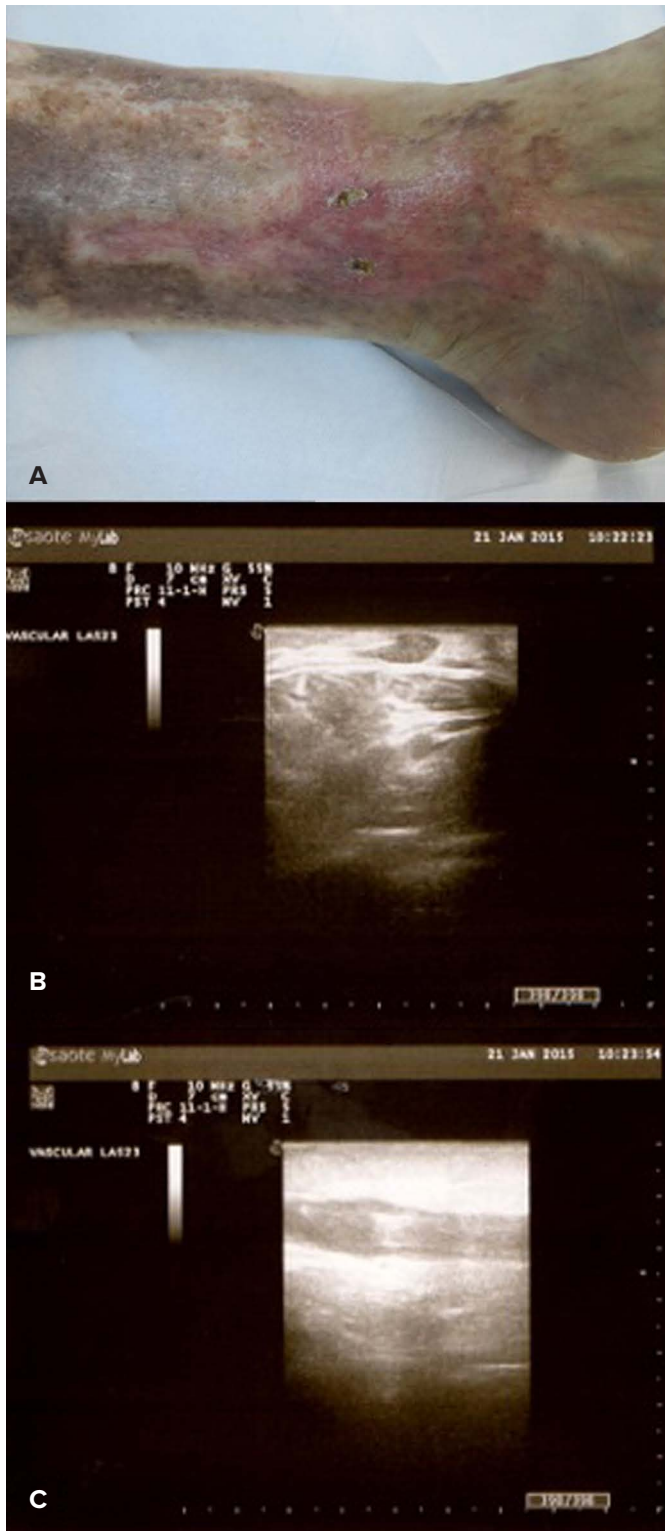
high-risk clinical condition such as prolonged immobilization or malignancy.

## CASE REPORTS

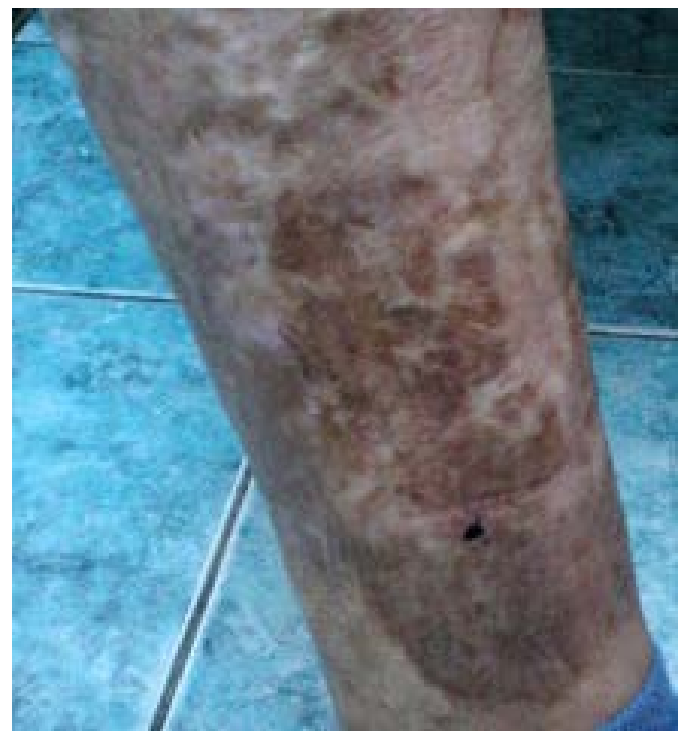We present 3 serial cases with comparable clinical features: lipodermatosclerosis and diabetic dermopathy low-risk skin lesions. In all cases, CUS was essential in revealing an asymptomatic and prognostically significant complication. Asymptomatic DVT was found in the first two cases, while in the third case the CUS excluded any type of vascular involvement, leading to a definite diagnosis of diabetic dermopathy. Lipodermatosclerosis was reported to be associated with venous abnormalities, but to our knowledge this is the first report of a documented association between lipodermatosclerosis and DVT.<sup>2,3</sup>

### Case 1

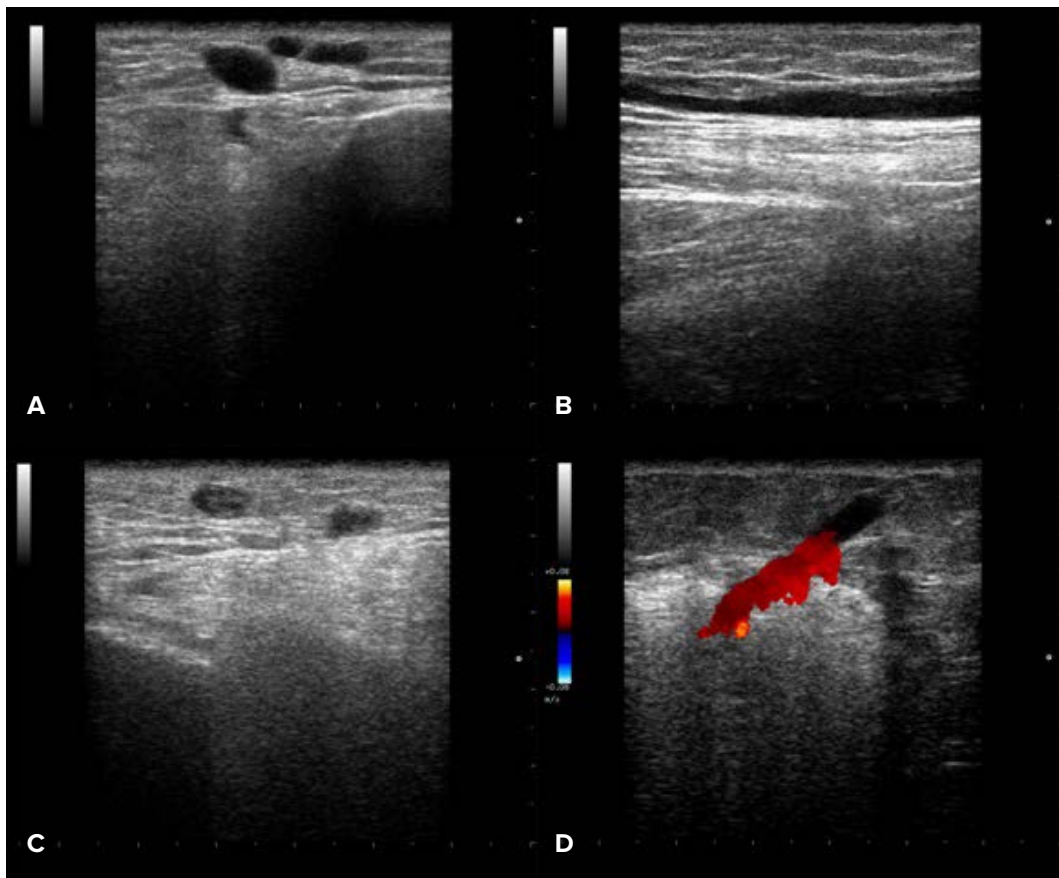
A 68-year-old man presented with the asymptomatic, brown induration of the lateral and dorsal aspects of the right lower leg, which has been present for a few years (Figure 1A). Comorbidities were coronary heart disease, and hypertension treated with perindopril and indapamide. His body mass index was normal. The patient denied smoking and alcohol consumption.



**FIGURE 1.** A – Clinical picture in a case of lipodermatosclerosis; B, C – Compression ultrasound examination: deep venous thrombosis at the level of the greater saphenous vein of the lower right leg



**FIGURE 2.** Lipodermatosclerosis – clinical picture



**FIGURE 3.** Left lower limb venous ultrasound (B-mode and Doppler): important dilatation of left greater saphenous vein ( $\approx 14$  mm) (A) that displays a segment with quasi-complete thrombosis (B); there are also some varicose veins located in the superior part of the left calf, with complete thrombosis (C); in the lower left calf there is a perforating vein with important reflux (D)

Physical examination confirmed a marked palpable induration of the hyperpigmented area on his right lower leg, two small crusts covering superficial ulcerations, atrophic areas, and fibrotic scars. No pruritus or scratch marks were reported. No signs of local acute inflammation were noticed; no edema was reported prior to the consultation. Signs of superficial venous dilatation could be observed on the right thigh, and a diagnosis of lipodermatosclerosis was suspected on clinical grounds.

Lower extremity CUS revealed a DVT localized at the level of the greater saphenous vein of the right leg, in concordance to the skin lesions (Figure 1B, 1C).

Anticoagulant treatment of the DVT was initiated, and emollients were prescribed for the skin disorders.

## Case 2

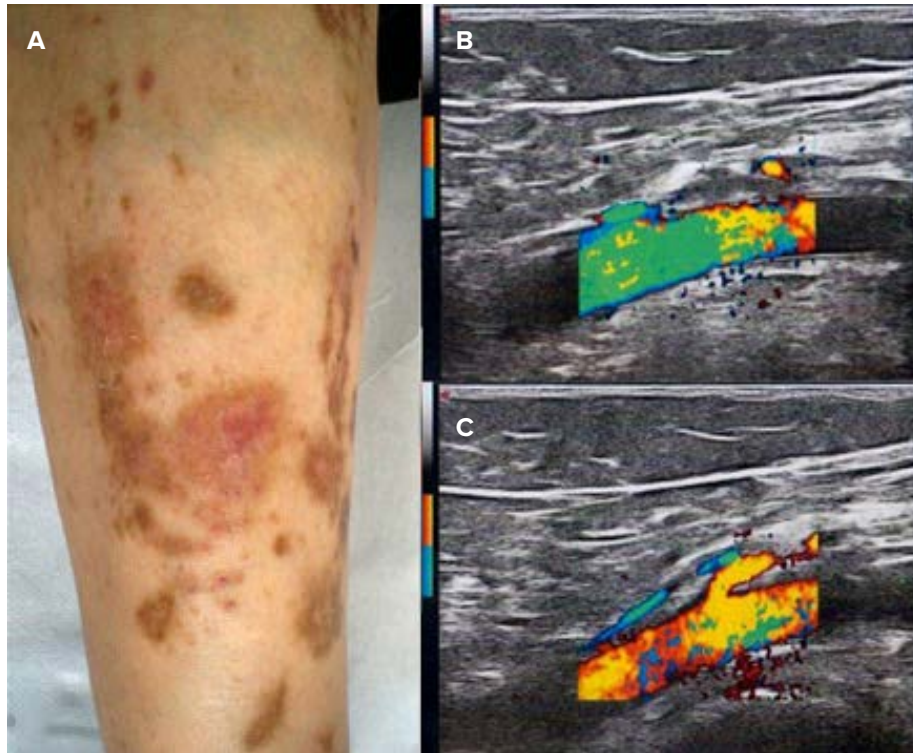
A 65-year-old woman, known with chronic venous insufficiency for years and treated orally with diosmin, reported pain and slight pruritus of the skin on both legs, for the last

years. Varicose veins, induration, skin pigmentations, and atrophic areas were observed on clinical examination, but neither ulcerations nor edema were present. A diagnosis of lipodermatosclerosis was formulated, and CUS found a DVT localized at the level of the left great saphenous vein (Figures 2 and 3).

## Case 3

A 34-year-old man, obese, with a long history of type 1 diabetes mellitus and hypertension, presented at the clinical examination multiple light brown, irregular patches, with atrophic scars and crusts on the shins (Figure 4A).

The skin lesions were totally asymptomatic, and the patient reported no previous trauma and no drug intake apart from insulin. The patient noticed the skin lesions one year before, despite good control of the metabolic status. His glycemic control was good (glycosylated hemoglobin  $< 6-6.8\%$ ), without neuropathy or associated vascular pathology.



**FIGURE 4.** **A** – Diabetic dermopathy; **B, C** – CUS examination of the popliteal vein showing complete compression, consistent with the lack of intravascular thrombosis

In order to exclude a chronic venous insufficiency, clinically expressed by edema, pruritus, stasis dermatitis, hair loss, and lipodermatosclerosis with or without venous ulceration, CUS was performed and proved to be within normal limits (Figure 4B, 4C). Subsequently, a diagnosis of diabetic dermopathy was established.

All patients gave their consent to the publication of the cases.

## DISCUSSION

Lipodermatosclerosis is also known as hypodermatitis sclerodermiformis, sclerosing panniculitis, liposclerosis, pseudoscleroderma, indurated cellulitis, stasis panniculitis, and chronic cellulitis of the leg.<sup>4,5</sup>

Common clinical findings in chronic lipodermatosclerosis include hyperpigmentation, small white-scarred areas (“atrofie blanche”), localized skin induration, small ulcerations, and erythematous plaques in patients who have chronic venous insufficiency.

The characteristic histological features of lipodermatosclerosis are observed in the subcutaneous tissue, in the lobules and septa. The presence of elastic fibers deep in the septa explains the process of fibrosis that defines the disease.<sup>6</sup>

Diabetic dermopathy, also named “shin spots”, is described in 7–70% of patients with diabetes mellitus,<sup>7</sup> more often in men over 50 years, being related pathogenically with diabetic microangiopathy (Figure 3).

The typical aspect of shin spots is caused by hemosiderin and melanin deposition in the epidermis and/or dermis, in conjunction with wall thickening of arterioles and abnormal local skin blood flow, in the absence of fibrosis or venous chronic insufficiency.<sup>7,8</sup> High-frequency (20 MHz) ultrasound and CUS display normal images, dermal thickness is within normal limits, and there are no signs of chronic venous insufficiency and/or venous thrombosis, or peripheral arteriopathy.

Classically, the clinical factors required to result in venous thrombosis are known as the Virchow’s triad and consist of impaired blood flow, endothelial injury, and conditions that increase the coagulability of the blood. Acquired major risk factors for DVT include trauma, immobilization, malignancy, specific drugs, and congestive heart failure.

The current guidelines recommend the use of CUS mainly in symptomatic or asymptomatic high-risk patients, such as those with prolonged immobilization, major orthopedic procedures, or malignancy.<sup>9</sup> Skin disorders are rarely the reason for referring the patient to vascular ul-



trasound examination, also because of the scarce evidence on the benefit of CUS in asymptomatic patients.

The incidence of asymptomatic DVT varies with the age and the underlying disorder: from 5.5% in patients hospitalized in internal medicine units and examined by CUS to 17.8% in patients aged over 80 years; in cancer patients asymptomatic DVT can be twice as frequent compared with symptomatic DVT, underlying the need of routine CUS scanning.<sup>1,10</sup>

## CONCLUSIONS

We presented 3 cases of skin disorders in which vascular CUS was essential for the assessment of the outcome and the further management of the patients: asymptomatic DVT was found to be associated with lipodermatosclerosis in 2 patients, while the same disorder was ruled out by the absence of DVT in a patient with similar findings at the physical examination but a different entity: skin manifestations of a long-standing evolution of diabetes mellitus. Lipodermatosclerosis may be associated with asymptomatic DVT due to chronic venous insufficiency, and early referral to CUS positively impacts the outcome of the patients with a significant vascular disorder.

## CONFLICTS OF INTEREST

None for all authors.

## REFERENCES

1. Heit JA. The epidemiology of venous thromboembolism in the community. *Arterioscler Thromb Vasc Biol.* 2008;28:370-372.
2. Naschitz JE, Yeshurun D, Schwartz H, et al. Pathogenesis of lipodermatosclerosis of venous disease: the lesson learned from eosinophilic fasciitis. *Cardiovasc Surg Lond Engl.* 1993;1:524-529.
3. Gross EA, Wood CR, Lazarus GS, Margolis DJ. Venous leg ulcers: an analysis of underlying venous disease. *Br J Dermatol.* 1993;129:270-274.
4. Caggiati A, Rosi C, Casini A, et al. Skin iron deposition characterises lipodermatosclerosis and leg ulcer. *Eur J Vasc Endovasc Surg.* 2010;40:777-782.
5. Hafner C, Wimmershoff M, Landthaler M, Vogt T. Lipodermatosclerosis: successful treatment with danazol. *Acta Derm Venereol.* 2005;85:365-366.
6. Walsh SN, Santa Cruz DJ. Lipodermatosclerosis: a clinicopathological study of 25 cases. *J Am Acad Dermatol.* 2010;62:1005-1012.
7. Ferringer T, Miller F. Cutaneous manifestations of diabetes mellitus. *Dermatol Clin.* 2002;20:483-492.
8. Brugler A, Thompson S, Turner S, Ngo B, Rendell M. Skin blood flow abnormalities in diabetic dermopathy. *J Am Acad Dermatol.* 2011;65:559-563.
9. American Institute of Ultrasound in Medicine, American College of Radiology, Society of Radiologists in Ultrasound. Practice guideline for the performance of peripheral venous ultrasound examinations. *J Ultrasound Med.* 2011;30:143-150.
10. Bressollette L, Nonent M, Oger E, et al. Diagnostic accuracy of compression ultrasonography for the detection of asymptomatic deep venous thrombosis in medical patients – the TADEUS project. *Thromb Haemost.* 2001;86:529-533.