

HELMINTHOLOGIA, 55, 166 - 172, 2018

Case Report

Concurrent infection of a young tourist by hookworm and *Strongyloides stercoralis* during low budget travel in Southeast AsiaM. WESOŁOWSKA¹, W. RYMER², M. KICIA¹, M. POPIOLEK³

¹Department of Biology and Medical Parasitology, Wrocław Medical University, J. Mikulicza-Radeckiego 9, 50-367 Wrocław, Poland, E-mail: *maria.wesolowska@umed.wroc.pl, marta.kicia@umed.wroc.pl; ²Department of Infectious Diseases, Hepatology and Acquired Immune Deficiencies, Wrocław Medical University, Koszarowa 5, 51-149 Wrocław, Poland, E-mail: weronika.rymer@gmail.com; ³Department of Parasitology, Institute of Genetics and Microbiology, Wrocław University, Przybyszewskiego 63, 51-148 Wrocław, Poland, E-mail: marcin.popiolek@uwr.edu.pl

Article info

Received July 11, 2017
Accepted January 18, 2018

Summary

Strongyloidiasis and hookworm infections are neglected helminth diseases widespread in tropical and subtropical areas. In humans, particularly in immunocompromised patients infections potentially may lead to the life-threatening clinical conditions involving the respiratory as well as gastrointestinal systems. The increased number of tourists travelling to tropical regions is associated with more frequent infection with parasites such as *Strongyloides* and hookworm. The infection takes place when filariform larvae penetrate the skin exposed to soil, then migrate through the lungs and finally reach the intestine. Travelers are often not aware of how they could get infected. Physicians may suspect strongyloidiasis and hookworm infections in tourists with diarrhea returning from endemic areas, especially when an elevated eosinophilia is observed. In the literature there are many reports about the presence of parasites in indigenous communities, but very few are available regarding travelers. This paper describes a dual infection with hookworm and *Strongyloides stercoralis* in a young female tourist returning from Southeast Asia. To our knowledge, this is the first report of hookworm and *Strongyloides stercoralis* infection in a tourist from Europe, acquired in an endemic area.

Keywords: *Strongyloides*; hookworms; soil-transmitted helminths; tourists; diarrhea

Introduction

Due to expansions in transport and tourist facilities, an increase in tourist travel has been observed since mid of the 20th century (Gyr, 2010). The number of international tourists increased from 25 million in 1950 to 1186 million in 2015 (UNTWO 2016). International travel can cause risks to the health, and various infections are one of the most common (WHO 2012). Up to 40 % of European tourists have been affected with traveler's diarrhea (TD) (Pitzurra *et al.*, 2010) where bacterial and protozoan infections are the predominant causes of TD, however, occasionally helminths are also the causative agent (McGregor AC & Wright 2015). Hookworms (*Ancylostoma* and *Necator*) and *Strongyloides stercoralis* are endemic intestinal parasites to which travelers may

be exposed in countries with warm and humid climates (Tylor *et al.* 2014) and are transmitted through contaminated soil (Ojha *et al.*, 2014). Together with *Ascaris* and whipworm they represent a group of parasites named soil-transmitted helminths (STH). Due to the similar way of infection (Hotez *et al.*, 2004; Baker *et al.*, 2011) hookworms and *Strongyloides* are often spread together. The transmission of the parasite takes place either through direct penetration of the skin by filariform larvae or via the fecal-oral route. (Hotez *et al.*, 2004; Taylor *et al.* 2014) *Strongyloides* and hookworms have a very complex life cycle which consists of infective larvae migration through the lungs and finally reach the intestine (Hotez *et al.*, 2004; Kassalik & Mönkemüller, 2011). Both, the *Strongyloides* and hookworm adult females produce eggs in the human small intestine. The hookworm eggs deposited by the

* – corresponding author

female are excreted in the feces and mature to its infective stage in the soil, while *Strongyloides* eggs rapidly hatch within the intestinal lumen and release rhabditiform larvae (Ojha *et al.*, 2014; Puthiyakunnon *et al.*, 2014). Most of the *Strongyloides* larvae are discharged by feces, but some of them transform within the gut into infective filariform larvae (iLF3). After that the larvae can penetrate the end part of the bowel (endoautoinfection) or perianal skin (exoautoinfection) and restart the entire cycle in the human body (Kassalik & Mönkemüller, 2011; Taylor *et al.*, 2014).

Both strongyloidiasis and hookworm infection can present a wide differences in the clinical picture. Starting from abdominal cramping, nausea, and severe diarrhea up to respiratory symptoms and skin reactions (larva currens) (Taylor *et al.* 2014; Forrer *et al.*, 2017). High levels of eosinophils are reported for both infections and anemia can also be observed (Buonfrate *et al.*, 2013; Loukas *et al.*, 2016).

During clinical course of infection with *S. stercoralis* many forms of the disease can be observed. It can be presented as acute and chronic infection or autoinfection. However, some cases are asymptomatic (Foreman *et al.*, 2006; Olsen *et al.*, 2009). The most severe symptoms are observed in immunocompromised patients caused by malnutrition, HIV infection, glucocorticosteroid therapy, recipients of kidney allograft, as well as the other immunosuppressive factors, where the immune system is no longer able to keep the auto-infective larval cycle under control (Siddiqui & Berk, 2001; Buonfrate *et al.*, 2013; Puthiyakunnon *et al.*, 2014). As a consequence it may cause a severe outcome of strongyloidiasis leading to the life-threatening hyperinfection and dissemination of infection in organs usually not infected during the parasite's normal life cycle (Puthiyakunnon *et al.*, 2014; Tylor *et al.*, 2014). In such cases, symptoms depend on the organs involved (e.g., liver, heart, lungs, urinary tract, central nervous system). *Strongyloides* filariform larvae also can be responsible for intestinal translocation of bacteria, and subsequent bacteremia, which in immunocompromised patients can be fatal in a few days or weeks (Buonfrate *et al.*, 2013, 2016; Puthiyakunnon *et al.*, 2014).

The decision about the treatment regimen depends on type of infection detected. Albendazole can be used for treatment of hookworm and *Strongyloides* infection where two different therapeutic schemes are utilized. In hookworm the albendazole dose is 400 mg daily for 3 consecutive days; and in strongyloidiasis it is 400 mg twice daily for 7 consecutive days. Regarding the strongyloidiasis, the albendazole is a less effective drug when compared with ivermectin (Tylor *et al.*, 2014; Gilbert *et al.*, 2015). Some authors report of albendazole treatment failure in patient with strongyloidiasis (Boulware *et al.*, 2007; Taylor *et al.*, 2014).

Strongyloides and hookworm infestations are rare in moderate climate zones and primarily occur in tropical and subtropical areas. Particularly those with poor sanitary conditions, where feces are used as a fertilizer or persons who defecate outdoor near fields or gardens (Schär *et al.*, 2014). Hookworms are prevalent in tropical and subtropical climates especially in Africa, Latin America, and

Asia. (Ojha *et al.*, 2014). It is estimated that about 740 million people worldwide could become infected by hookworms (Ipankaew *et al.*, 2014). Global prevalence of *Strongyloides* remains unknown, but the World Gastroenterology Organization (WGO) reports that these infections are endemic in the tropics and subtropics. Particularly in Southeast Asia, Latin America, and Sub-Saharan Africa and up to 370 million people are infected worldwide (Tylor *et al.* 2014; Buonfrate *et al.* 2015; WGO, 2017). There are many reports about the presence of parasites in indigenous communities, but very few concerning travelers (Angheben *et al.*, 2011; Ramírez-Olivencia *et al.*, 2014).

Here we report an unusual case of dual infection caused by *Ancylostoma* and *S. stercoralis* in a young tourist and discuss the treatment problems and importance of the medical examination of tourists returning from the endemic areas.

Abbreviations

WBC – white blood cells, Hb – hemoglobin, PLT – platelets, CRP – C-reactive protein, IgE – total immunoglobulin E level

Case presentation

A 23-year-old Polish (Caucasian) woman was admitted to the hospital with diarrhea and abdominal pain. Symptoms started four weeks after her five months trip to the Southeast Asia (Thailand, Myanmar, Laos, and Cambodia). It was a "low budget" trip which involved living in low cost accommodation. She also worked as a waitress and walked barefoot at a beach bar for a few weeks in Cambodia. Apart from diarrhea (five watery bowel movements per day), abdominal pain and mild cough occurred for a few days during hospitalization, and no other clinical symptoms were observed. There were no changes in clinical examination such as lung X-ray examination or abdominal ultrasound. Apart from a high level of eosinophil granulocytes (23.6×10^3 cells/ μL , 73.9 % of WBC [norm: 50 – 500 cells/ μL , 2 – 5 %]), no other evidence was observed in the laboratory tests (Hb: 13.3 g/dL [norm: 11.5 to 15.5 g/dL], PLT: 158×10^3 cells/ μL [norm: 140 to 440×10^3 cells/ μL], CRP: 1.6 mg/L [norm: <6 ml/L]). Anemia was also not observed.

Fecal specimens were examined for the presence of intestinal parasites at the Department of Biology and Medical Parasitology, Wrocław Medical University, Poland. Three stool specimens passed at intervals of two days were collected. The samples were examined for parasites by light microscopy and wet smears after formyl-ethyl acetate concentration were performed. Hookworm eggs were found in two fecal samples and eggs measuring 56 – 60 μm in length by 36 – 39 μm in width were discovered (Fig. 1A). Stool examination by Harada-Mori culture (Garcia, 2001) revealed *Strongyloides* rhabditiform larvae. The identification of larvae was based on their biometrics and the morphology. For the most part by the presence of a bulbed esophagus which is shorter than in hookworm rhabditiform larvae, especially the buccal cavity (Fig. 1B).




Fig. 1. Wet mounts of feces: panel A depicts hookworm egg measuring 59 μm by 37 μm ($\times 400$); panel B shows living rhabditiform larva of *S. stercoralis* ($\times 200$). Charcot-Leyden crystals formed from the breakdown of eosinophils are visible in the background. The presence of these crystals in the fecal smear indicates an immune response.

No other parasites were found. Direct fecal smear showed the presence of numerous Charcot-Leyden crystals, which may indicate an immune response during parasitic infection (Fig. 1 A and B) (Pantanowitz and Balogh, 2004). As soon as the parasite infection (before hookworm infection confirmation) was suspected the albendazole was used for treatment (400 mg twice a day) for seven consecutive days. In two weeks follow-up examination no parasites in feces were observed, and the eosinophil granulocyte levels decreased to 0.88×10^3 cells/ μL (15 %).

One month after completing the treatment the symptoms returned. The patient suffered from abdominal pain and had loose stools (up to three per day and some containing mucus). At that time the laboratory examinations showed a higher level of eosinophils (23.4×10^3 cells/ μL , 22.5 %). Once again fecal direct smear revealed motile *S. stercoralis* rhabditiform larvae. The patient was repeatedly treated with albendazole (400 mg BID) which was extended up to three weeks). A laboratory examination of the stool specimen (fecal direct smear, formalin-ethyl acetate sedimentation and Harada-Mori culture) after three-week treatment confirmed the elimination of the parasites. The eosinophil granulocyte level decreased to 0.184×10^3 cells/ μL (3.28 %).

Three months later loose stools and increased levels of eosinophils (1.539×10^3 cells/ μL , 27.0 %) developed again and transient eye edema was observed. No parasites were found in the stool examination as determined by fecal direct smear, formalin-ethyl acetate sedimentation and Harada-Mori culture. For the reason of suspected strongyloidiasis relapse the patient was treated with ivermectin (9 mg once a day for 2 days, repetition of the regimen three months later). Subsequent laboratory studies performed one month and six months after the treatment showed an eosinophil count below 0.5×10^3 cells/ μL . All examination of stool samples

confirmed the absence of *Strongyloides* infection. Figure 2 present the time frame for the disease symptoms outcome and treatment.

Ethical Approval and/or Informed Consent

Informed consent has been obtained from the patient.

Discussion

Both *S. stercoralis* and hookworms can cause chronic infections, and if not treated properly it can lead to serious clinical complications. We present unusual dual *S. stercoralis* and hookworm infections of a traveler from Poland – a low-prevalence country. The prepatent period and high-risk factors such as barefoot walking suggest that the disease was acquired while staying in Cambodia. The diarrhea appeared four weeks after returning from Asia, which is in line with the parasite life cycle. The average prepatent period [time from penetration of iLF3 to egg stage (hookworm)/larval stage (*Strongyloides*) appearing in feces] for both infections is about 4 weeks (Puthiyakunnon *et al.*, 2014). Since this parasite in our country occurs sporadically and for many years no cases of infection have been recorded it is unlikely that the patient was infected with *Strongyloides* in Poland. Data on *Strongyloides* occurrence in Poland are few and apart. Several cases were recorded in 1976 among brickworks workers and farmers, and one case in an adult person was confirmed in 2006 (Nowak *et al.*, 2007). Cambodia is one of the endemic countries for both parasites. The prevalence of hookworm infection among inhabitants of Cambodia varies from 9.6 % to 63.3 % of the population (Inpankaew *et al.*, 2014; Schär *et al.*, 2014; Yong *et al.*, 2014), and prevalence rate for strongyloidiasis is from 2.6 % to 44.7 % (Khieu *et al.*, 2013).

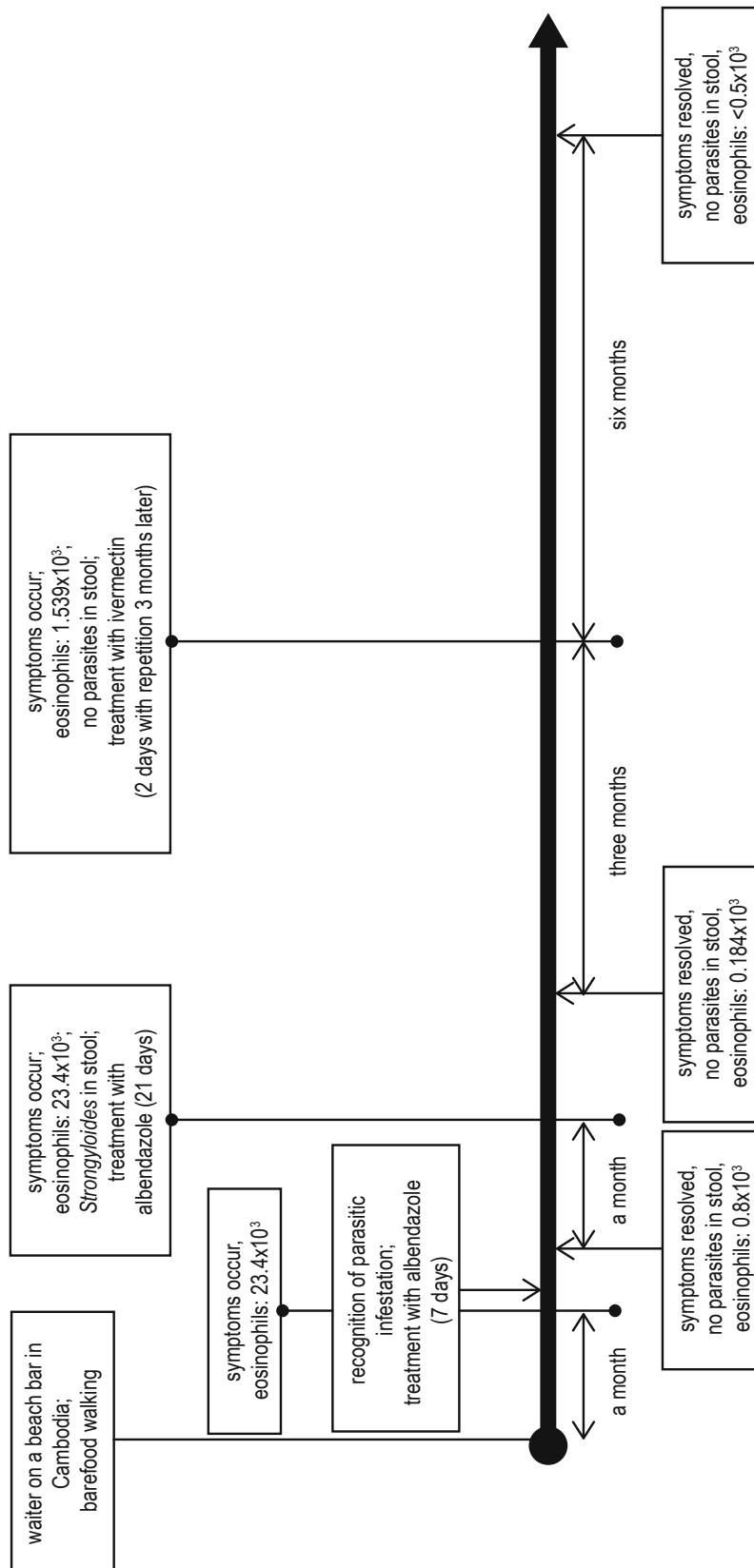


Fig. 2. Dynamics of eosinophils and clinical symptoms prior to and after anthelmintic treatment.

In spite of double infection, oligosymptomatic clinical manifestation and lack of anemia in the described case were observed. We suspect that it was due to a paucity in immunodeficiency factors, the early (invasive) stage of the disease and lack of massive invasion. However, de Silva (2002) in a study on immigrants and refugees with chronic *S. stercoralis* infection in Australia found no correlation between parasite infection and abnormalities in red blood cell morphology or anemia (de Silva *et al.* 2002).

The examination of strongyloidiasis or hookworm infection should be taken into consideration where clinical signs and symptoms, such as diarrhea, eosinophilia or suggestive serologic findings up to at least 1 month after returning from an endemic area occur (Siddiqui & Berk, 2001; Angheben *et al.* 2011; Ramirez-Olivencia *et al.*, 2014). The laboratory diagnosis of hookworm and *Strongyloides* is difficult. Negative result does not necessarily imply the absence of infection (Kassalik & Mönkemüller, 2011). Standard diagnostic methods include direct parasite finding as well as culture of stool (e.g. Harada-Mori culture) for the detection of larvae and eggs or serological testing (Siddiqui & Berk, 2001; Ojha *et al.*, 2014). Many studies have shown that the analysis of a single stool sample is inadequate and can fail in up to 70 % of cases (Knopp *et al.*, 2008; Ojha *et al.*, 2014). Repeated stool examinations may increase sensitivity by 50 % and with 3 – 7 stool samples and up to 70 %–100 % (Siddiqui & Berk, 2001; Buonfrate *et al.*, 2015). Also, concentration methods such as formalin-ethyl acetate are recommended for the improvement the efficiency of microscopic techniques (Puthiyakunnon *et al.*, 2014; Buonfrate *et al.*, 2015). A recent study on STH infection diagnosis confirmed high sensitivity of serological methods, which have specificity over 90 % (Siddiqui & Berk, 2001; Buonfrate *et al.*, 2013, 2015). Molecular diagnosis is valuable in parasitological investigation, but as yet it is limited by costs and equipment and therefore is not widely available in developing countries (Ojha *et al.*, 2014; Buonfrate *et al.*, 2015). The detection of concurrent infection seems to be more difficult and may create a bigger problem for diagnostics. In particular when *Strongyloides* rhabditiform larvae occur in feces in small numbers or sporadically (Ojha *et al.*, 2014). This suggest that the prevalence rates of dual infection could be underdiagnosed due to insufficient methods as well as small size of the sample (Baker *et al.*, 2011; Khieu *et al.*, 2014; Forrer *et al.*, 2017). It may have effect on false negative results in the diagnostic process (Olsen *et al.*, 2009; Puthiyakunnon *et al.*, 2014; Taylor *et al.*, 2014).

In the present case the treatment of the first infection started as soon as parasite infection was suspected. Because the confirmation of hookworm was later than the initiation of therapy, the patient received empiric albendazole treatment, which was convergent with the alternative regimen for strongyloidiasis (Gilbert *et al.*, 2015). However, after the completion of first treatment regimen, the relapse of strongyloidiasis was observed. According to the various studies anthelmintic drugs such as thiabendazole, albendazole and mebendazole, have shown diverse results including treatment failure (Taylor *et al.*, 2014). The relapse in this

case was probably associated with lower sensitivity of the parasite to albendazole, which has also been noted by the other authors (Boulware *et al.*, 2007; Puthiyakunnon *et al.*, 2014). The mechanism of albendazole resistance in *Strongyloides* is still not well understood (Taylor *et al.*, 2014). Since ivermectin, according to some authors, has shown better elimination rates of about 82 %, this drug is the first choice for therapy of *Strongyloides* infection (Kassalik & Mönkemüller, 2011; Gilbert *et al.*, 2015). In Poland there is no registered ivermectin product in a formula for human use. Because obtaining the permission for import from abroad takes a few weeks, it makes our treatment with this drug more problematic. Therefore the patient received prolonged albendazole treatment. We strived to fully eliminate the *Strongyloides* infection, because only the complete eradication of *Strongyloides* allows us to avoid autoinfection and the development of serious illness (Kassalik & Mönkemüller, 2011; Buonfrate *et al.*, 2015, 2016). Lawn *et al.* suggest empiric treatment with ivermectin plus albendazole or mebendazole for travelers returning from the tropics, who have present infective diarrhea and eosinophilia without a known cause (Lawn *et al.*, 2003). Our case confirms that patient monitoring after the treatment, stool examination and eosinophil count are necessary (three to six months after treatment; due to the risk of treatment failure) to perform. The patient remains under observation, but it seems that the treatment with ivermectin was effective.

Most papers which describe the epidemiology and risk of acquisition of STH infections focus on indigenous people or refugees. The limited studies conducted among tourists returning from endemic areas suggest that the problem of STH infections remain underrated (e.g., German, Belgian Switzerland, Italian and Spanish tourists), (Angheben *et al.*, 2011; Ramirez-Olivencia *et al.*, 2014; Forrer *et al.*, 2017). We suspect it is lower than for indigenous people. However, year by year, the number of international tourists traveling to the STH endemic regions increases. In 2014 Cambodia was visited by more than 3.6 million tourists (Ministry of Tourism of Cambodia, 2016). It may have an influence on the increasing frequency of imported STH infections. As long as the STH infections are not subject to mandatory notification by the sanitary services in the European Union, the real number of infected tourists from low-epidemic countries will remain unknown (Puthiyakunnon *et al.*, 2014).

Tourists are often unaware of the risk of STH during their travel and do not know how to keep away from hookworm and *Strongyloides* infections. Barefoot walking is one of the most important risk factors associated with these infection. Coastal regions are among those with the highest rates of transmission. Air-entrained, well-drained sand creates favorable conditions for survival of infective larvae and allows them to take a vertical position for easy attack of the host. The gardens surrounding recreation centers seem to be safe but can also be potentially considered as a risk areas for acquiring strongyloidiasis as well as hookworm infection (Schär *et al.*, 2014).

In conclusion, *S. stercoralis* and hookworm infections make im-

portant health problems and are major contributors to morbidity and mortality in the developing world (Becker *et al.*, 2011). For this reason, tourists should be informed about the risk of strongyloidiasis and hookworm infections before traveling to the endemic areas. Therefore, physicians should be more aware of the helminth infections presence and focus not only on immigrants from endemic regions, but also on tourists. Failure in treatment of strongyloidiasis, even with the proper therapy should also be taken into account.

Conflict of Interest

Authors state no conflict of interest.

Acknowledgements

The authors would like to thank Prof. Krzysztof Simon and Karolina Rostkowska MD, who treated the patient during hospitalization, and Prof. Brygida Knysz for consultation.

References

- ANGHEBEN, A., MISTRETTA, M., GOBBO, M., BONAFINI, S., IACOVAZZI, T., SEPE, A., GOBBI, F., MAROCCO, S., ROSSANESE, A., BISOFFI, Z. (2011): Acute strongyloidiasis in Italian tourists returning from Southeast Asia. *J. Travel. Med.*, 18(2): 138 – 140. DOI: 10.1111/j.1708-8305.2010.00496.x
- BECKER, S.L., SIETO, B., SILUÉ, K.D., ADJOSSAN, L., KONÉ, S., HATZ, C., KERN, W.V., N'GORAN, E.K., UTZINGER, J. (2011): Diagnosis, clinical features, and self-reported morbidity of *Strongyloides stercoralis* and hookworm infection in a Co-endemic setting. *PLoS Negl. Trop. Dis.*, 5(8): e1292. DOI: 10.1371/journal.pntd.0001292
- BOULWARE D.R., STAUFFER, W.M., HENDEL-PATERSON B.R., ROCHA, J.L., SEET, R.C., SUMMER, A.P., NIELD, L.S., SUPPARATPINYO, K., CHAIWARITH, R., WALKER, P.F. (2007): Maltreatment of *Strongyloides* infection: Case series and worldwide physicians-in-training survey. *Am. J. Med.*, 120(6): 545.e1 – 545.e8
- BUONFRATE, D., REQUENA-MENDEZ, A., ANGHEBEN, A., MUÑOZ, J., GOBBI, F., VAN DEN ENDE, J., BISOFFI, Z., (2013): Severe strongyloidiasis: a systematic review of case reports. *BMC Infect. Dis.*, 13: 78
- BUONFRATE, D., FORMENTI, F., PERANDIN, F., BISOFFI, Z. (2015): Novel approaches to the diagnosis of *Strongyloides stercoralis* infection. *Clin. Microbiol. Infect.*, 6(21): 543 – 552. DOI: 10.1016/j.cmi.2015.04.001
- BUONFRATE, D., GOBBI, F., BELTRAME, A., BISOFFI, Z. (2016): Severe Anemia and Lung Nodule in an Immunocompetent Adopted Girl with *Strongyloides stercoralis* Infection. *Am. J. Trop. Med. Hyg.*, 95: 1051 – 1053
- DE SILVA, S., SAYKAO, P., KELLY, H., MACINTYRE, C.R., RYAN, N., LEYDON, J., BIGGS, B.A. (2002): Chronic *Strongyloides stercoralis* infection in Laotian immigrants and refugees 7 – 20 years after resettlement in Australia. *Epidemiol. Infect.*, 128(3), 439 – 444
- FOREMAN E.B., ABRAHAM P.J., GARLAND J.L., (2006): Not your typical *Strongyloides* infection: a literature review and case study. *South. Med. J.*, 99(8), 847 – 852
- FORRER, A., KHIEU, V., SCHÄR, F., HATTENDORF, J., MARTI, H., NEUMAYR, A., CHAR, M.C., HATZ, C., MUTH, S., ODERMATT, P. (2017): *Strongyloides stercoralis* is associated with significant morbidity in rural Cambodia, including stunting in children. *PLoS Negl. Trop. Dis.*, 11(10): e0005685. DOI: 10.1371/journal.pntd.0005685
- GARCIA, L.S. (2001): *Diagnostic Medical Parasitology*. 4th Edition, Washington DC, American Society for Microbiology, 746 – 788 pp.
- GILBERT, D.N., CHAMBERS, H.F., ELIOPOULOS, G.M., SAAG, M.S. (2015): *The Sanford Guide to Antimicrobial Therapy 2015*. 45th Edition, Antimicrobial Therapy, 2015, 238 pp.
- GYR, U. (2010, December): *The History of Tourism: Structures on the path to modernity*. Retrieved May 23, 2017 from <http://ieg-ego.eu/en/threads/europe-on-the-road/the-history-of-tourism/ueli-gyr-the-history-of-tourism>
- HOTEZ, P.J., BROOKER, S., BETHONY, J.M., BOTTAZZI, M.E., LOUKAS, A., XIAO, S. (2004): Hookworm infection. *N. Engl. J. Med.*, 351: 799 – 807
- INPANKAEW, T., SCHÄR, F., DALSGAARD, A., KHIEU, V., CHIMNOI, W., CHHOUN, C., SOK, D., MARTI, H., MUTH, S., ODERMATT, P., TRAUB, R.J. (2014): High prevalence of *Ancylostoma ceylanicum* hookworm infections in humans, Cambodia, 2012. *Emerg. Infect. Dis.*, 20: 976 – 982. DOI: 10.3201/eid2006.131770
- KASSALIK, M., MÖNKEMÜLLER, K. (2011): *Strongyloides stercoralis* hyperinfection syndrome and disseminated disease. *Gastroenterol. Hepatol.*, (N Y), 7(11): 766 – 768
- KHIEU, V., SCHÄR, F., MARTI, H., SAYASONE, S., DUONG, S., MUTH, S., ODERMATT, P. (2013): Diagnosis, treatment and risk factors of *Strongyloides stercoralis* in schoolchildren in Cambodia. *PLoS Negl. Trop. Dis.*, 7: e2035. DOI:10.1371/journal.pntd.0002035
- KNOPP, S., MGENI, A.F., KHAMIS, I.S., STEINMANN, P., STOTHARD, J.R., ROLLINSON, D., MARTI, H., UTZINGER, J. (2008): Diagnosis of soil-transmitted helminths in the era of preventive chemotherapy: effect of multiple stool sampling and use of different diagnostic techniques. *PLoS Negl. Trop. Dis.*, 2(11): e331. DOI:10.1371/journal.pntd.0000331
- LAWN, S.D., GRANT, A.D., WRIGHT, S.G. (2003): Case reports: acute hookworm infection: an unusual cause of profuse watery diarrhoea in returned travelers. *Trans. R. Soc. Trop. Med. Hyg.*, 4(97): 414-415. DOI:10.1016/S0035-9203(03)90073-3
- LOUKAS, A., HOTEZ, P.J., DIEMERT, D., YAZDANBAKHSH, M., MCCARTHY, J.S., CORREA-OLIVEIRA, R., CROESE, J., BETHONY, J.M. (2016): Hookworm infection. *Nat. Rev. Dis. Primers.*, 2: 16088. DOI: 10.1038/nrdp.2016.88
- MCGREGOR A.C., WRIGHT S.G. (2015): Gastrointestinal symptoms in travelers. *Clin. Med. (Lond.)*, 1(15): 93 – 95. DOI: 10.7861/clinmedicine.15-1-93
- MINISTRY OF TOURISM OF CAMBODIA (2016): *Tourism Statistics Report*. Retrieved November 07, 2017 from http://www.tourismcambodia.org/mot/index.php?view=statistic_report
- NOWAK, P., JOCHYMEK, M.,

- PIETRZYK, A. (2007): Occurrence of human intestinal parasites in selected populations of Cracow region in the years 2000–2006 on the basis of parasitological stool examinations performed in the Laboratory of Parasitology of the District Sanitary – Epidemiological Center. *Wiad. Parazytol.*, 53(4): 285 – 293
- OJHA, S.C., JAIDE, C., JINAWATH, N. (2014): Geohelminths: public health significance. *J. Infect. Dev. Ctries.*, 8(1): 5 – 16. DOI: 10.3855/jidc.3183
- OLSEN, A., VAN LIESHOUT, L., MARTI, H., POLDERMAN, T., POLMAN, K., STEINMANN, P., STOTHARD, R., THYBO, S., VERWEIJ, J.J., MAGNUSSEN, P. (2009): Strongyloidiasis - the most neglected of the neglected tropical diseases? *Trans. R. Soc. Trop. Med. Hyg.*, 103: 967 – 972. DOI: 10.1016/j.trstmh.2009.02.013
- PANTANOWITZ, L., BALOGH, K. (2004): Charcot-Leyden crystals: pathology and diagnostic utility. *Ear Nose Throat J.*, 83(7): 489 – 490
- PITZURRA, R., STEFFEN, R., TSCHOPP, A., MUTSCH, M. (2010): Diarrhoea in a large prospective cohort of European travellers to resource-limited destinations. *BMC Infect. Dis.*, 2010(10): 231. DOI: 10.1186/1471-2334-10-231
- PUTHIYAKUNNON, S., BODDU, S., LI, Y., ZHOU, X., WANG, C., LI, J., CHEN, X. (2014): Strongyloidiasis – an insight into its global prevalence and management. *PLoS Negl. Trop. Dis.*, 148: e3018. DOI: 10.1371/journal.pntd.0003018
- RAMÍREZ-OLIVENCIA, G., ESPINOSA M.Á., MARTÍN, A.B., NÚÑEZ, N.I., DE LAS PARRAS, E.R., NÚÑEZ, M.L., PUENTE, S.P. (2014): Imported strongyloidiasis in Spain. *Int. J. Infect. Dis.*, 18: 32 – 37. DOI: 10.1016/j.ijid.2013.09.009
- SCHÄR, F., INPANKAEW, T., TRAUB, R.J., KHIEU, V., DALSGAARD, A., CHIMNOI, W., CHHOUN, C., SOK, D., MARTI, H., MUTH, S., ODERMATT, P. (2014): The prevalence and diversity of intestinal parasitic infections in humans and domestic animals in a rural Cambodian village. *Parasitol. Int.*, 63: 597 – 603. DOI: 10.1016/j.parint.2014.03.007
- SIDDIQI, A.A., BERK, S.L. (2001): Diagnosis of *Strongyloides stercoralis* infection. *Clin. Infect. Dis.* 1, 33(7), 1040 – 1047
- TAYLOR, M.J., GARRARD, T.A., O'DONAHOO, F.J., ROSS, K.E. (2014): Human strongyloidiasis: identifying knowledge gaps, with emphasis on environmental control. *Res. Rep. Trop. Med.*, 2014(5): 55 – 63. DOI: 10.2147/RRTM.S63138
- UNTWO (2016): *World Tourism Organization. Annual Report*. Retrieved November 07, 2017 from <http://media.unwto.org/publication/unwto-annual-report-2016>
- WORLD HEALTH ORGANIZATION (WHO) (2012): *World Health Statistics*. Retrieved November 07, 2017 from http://www.who.int/gho/publications/world_health_statistics/2012/en/
- WORLD GASTROENTEROLOGY ORGANISATION (2017): *WGO Practice Guideline - Management of Strongyloidiasis*. Retrieved November 07, 2017 from <http://www.worldgastroenterology.org/guidelines/global-guidelines/management-of-strongyloidiasis>
- YONG, T.S., CHAI, J.Y., SOHN, W.M., EOM, K.S., JEOUNG, H.G., HOANG, E.H., YOON, C.H., JUNG, B.K., LEE, S.H., SINUON, M., SOCHEAT D. (2014): Prevalence of intestinal helminths among inhabitants of Cambodia (2006 – 2011). *Korean J. Parasitol.*, 52(6): 661 – 666. DOI: 10.3347/kjp.2014.52.6.661