

Implant Therapy In The Esthetic Zone-Surgical Considerations

SUMMARY

Implant placement in the esthetic zone is a complex procedure and requires a restoration-driven approach. Proper selection of patients and implant together with individual assessment of the risk of esthetic complications are very important. Correct 3D-implant positioning and sufficient bone volume should provide long-term esthetic and function. Esthetic region is a zone in which expectations and possibilities collide. Clinician should bring the important decision on the appropriate time of implant placement. Immediate implant placement is particularly challenging in the esthetic zone. Patient desire for reduced treatment time should be weighed against the possible risk factors. Protocol of immediate implant placement in conditions of unfavourable gingival biotypes, the lack of bone or soft tissue in patients with a high smile line lead to esthetic failure which is very important in the esthetic region.

Key words: 3D-implant positioning, esthetic region, immediate implant placement

A. Marković, T. Mišić

Oral Surgery Clinic, School of Dental Medicine,
University of Belgrade

ORIGINAL PAPER (OP)

Balk J Dent Med, 2016; 20(2):83-88

Introduction

In the beginning of the application of dental implants in the oral rehabilitation of edentulous patients the main goal was to achieve osseointegration that would provide functional prosthetic solution. Today, long-term aesthetics together with functionality are integral parts of successful implant treatment outcome. Predictable esthetic result is of a particular importance in the esthetic zone defined as dentoalveolar segment that is visible upon full smile or any area of esthetic importance to the patient. Implant placement in the esthetic zone is a complex procedure that requires comprehensive preoperative planning and precise operative procedure based on restoration driven concept¹⁻³.

Patient selection

Preoperative analysis of edentulous site and assessment of general risk allow clinician to determine a potential of achieving successful esthetic outcome of implant treatment. General risk assessment

includes medical status, periodontal susceptibility and smoking habits^{1,3,4,7}. Smoking habits may jeopardize osseointegration, incorporation of bone or soft tissue grafts as well as stability of periimplant tissues. Heavy smokers consuming more than 10 cigarettes daily are at high risk of esthetic failure and cessation should be suggested prior to implant placement. Patients suffering from bone or immunologic disease, uncontrolled diabetes mellitus or those who are taking steroids, or with a history of irradiated therapy of jaw are high risk patients^{4,5}. Active or refractory periodontal disease, poor oral hygiene and bruxism are associated with high risk^{1,3,8}.

High lip line allowing visibility of entire maxillary anterior teeth together with significant amount of supportive tissue represents great esthetic risk. This risk is associated with soft tissue and emergence profile esthetic failure and it even increases in cases with multiple tooth replacement. Thin gingiva biotype poses a risk of recession and soft tissue discoloration, often requiring periodontal surgery. Triangular shape of adjacent tooth and implant-supported restoration increase visibility of interproximal spaces (“black triangles”) and represent high risk for esthetic outcome¹.

Present or previous infection at/or adjacent to the future implant site is a risk factor for the esthetic result due to loss of bone and soft tissue. Crestal bone at adjacent teeth provides support for interproximal papilla leading to the esthetic appearance of implant supported restoration. Crestal bone loss at adjacent tooth resulting in the distance of 5.5 mm or greater to the contact point compromises esthetic result due to insufficient interproximal papilla. This problem is highlighted in extended edentulous spaces with multiple missing teeth, particularly at positions between the adjacent implants. Therefore, wide edentulous span with several adjacent teeth missing increases risk for esthetic failure, particularly when site of lateral incisor is included. Insufficient height and width of bone and soft tissues at future implant site disables correct 3D implant positioning and presents high risk of implant failure requiring site development through augmentation procedures. The most challenging situation is vertical deficiency of alveolar

ridge and it is associated with the highest risk for the esthetic outcome. Finally, for the esthetic risk profile, it is important to assess patient's esthetic expectations and whether they are realistic. For patients with high risk of esthetic failure, alternative restorative methods should be suggested^{1,3}.

Timing of implant placement

Following tooth extraction, implant can be placed immediately (Type 1), early after soft tissue healing (Type 2) or partial bone healing (Type 3), as well as after complete socket healing (Type 4). Clinician should bring the important decision on the appropriate time of implant placement. Patient desire for reduced treatment time should be weighed against the possible risk factors (Table 1)².

Table 1. Timing of implant placement following tooth extraction²

Classification	Advantages	Disadvantages
Type 1	<ul style="list-style-type: none"> Extraction and implant placement are combined in the same surgical procedure Reduced overall treatment time compared to types 2, 3, and 4 an implant in an ideal position Peri-implant defects often present as two- or three-walled defects, which are favorable for simultaneous bone augmentation procedures 	<ul style="list-style-type: none"> Morphology of the site may increase the difficulty of placing Morphology of the site may compromise initial implant stability Lack of soft tissue volume makes attainment of tension-free primary closure more difficult Increased risk of marginal mucosal recession Inability to predict bone modeling may compromise outcomes
Type 2	<ul style="list-style-type: none"> Reduced treatment time Additional soft tissue volume allows for easier attainment of tension-free closure Additional soft tissue volume may enhance soft tissue esthetic outcomes Flattening of facial bone contours facilitates grafting of the facial surface of the bone Peri-implant defects often present as two- or three-walled defects, which are favorable for simultaneous bone augmentation procedures Allows for resolution of pathology associated with the extracted tooth 	<ul style="list-style-type: none"> Two surgical procedures are required Morphology of the site may compromise initial implant stability
Type 3	<ul style="list-style-type: none"> Partial bone healing usually allows implant stability to be more readily attained Additional soft tissue volume allows for easier attainment of tension-free closure Additional soft tissue volume may enhance soft tissue-esthetic outcomes Peri-implant defects often present as two- or three-walled defects, which are favorable for simultaneous bone augmentation procedures Flattening of facial bone contours facilitates grafting of the facial surface of the bone Allows for resolution of pathology associated with the extracted tooth 	<ul style="list-style-type: none"> Two surgical procedures are required Extended treatment time as compared to type 1 and type 2 placement Socket walls exhibit varying amounts of resorption Increased horizontal bone resorption may limit the volume of bone for implant placement

<p>Type 4</p>	<ul style="list-style-type: none"> • Bone healing usually allows implant stability to be readily attained • Additional soft tissue volume allows for easier attainment of tension-free closure • Additional soft tissue volume may enhance soft tissue esthetic outcomes and type 3 placement • Allows for resolution of pathology associated with the extracted tooth 	<ul style="list-style-type: none"> • Two surgical procedures are required • Extended treatment time compared to type 1, type 2, • Socket walls exhibit greatest amounts of resorption • Greatest chance of increased bone resorption limiting the volume of bone for implant placement
---------------	--	--

The recommended protocol for the esthetic zone is Type 2 placement, 4 to 8 weeks following tooth extraction^{1,2,9}. At that time the soft tissue is healed and a slight flattening of the buccal wall is present as a result of a bundle bone resorption (Figure 1a, 1b). The main aim of this protocol is the soft tissue healing that would provide its sufficient volume and the wide zone of keratinized mucosa allowing the primary tension-free closure following guided bone regeneration procedure. In this way risk of esthetic complications is minimized. This approach is suitable for the most cases with low to high esthetic

risk. Deviation from this protocol is necessary in cases of large apical bone defects that compromise primary implant stability. In this situation, early implant placement with partial bone healing following 12 to 16 weeks (Type 3) is indicated². Although newly formed bone in the extraction socket supports implant and provides sufficient primary stability, at the same time flattening of the facial bone wall occurs as a result of bone remodelling and requires contour augmentation using bone filler with slow resorption rate for acceptable esthetic result^{1,2}.

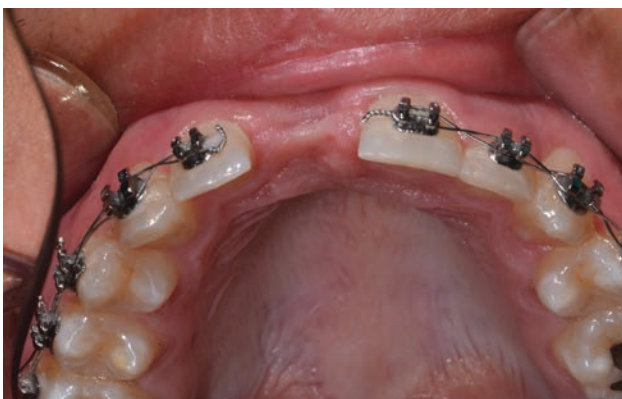

Figure 1a. Type 2 placement. Soft tissue healed allowing the primary tension-free closure following guided bone regeneration procedure

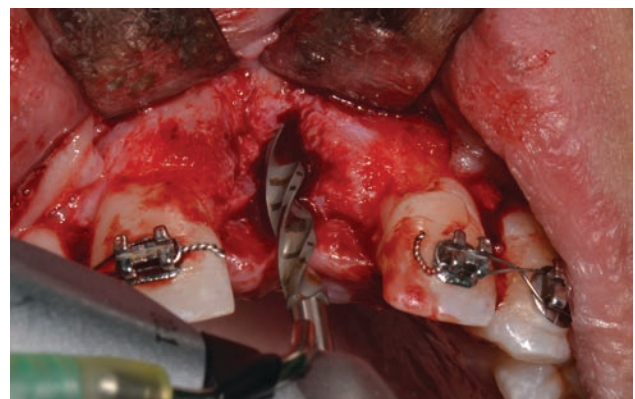


Figure 1b. Type 2 placement. Slight flattening of the buccal wall is present as a result of a bundle bone resorption.

Immediate implant placement is particularly challenging in the esthetic zone (Figure 2). Only limited number of patients with low esthetic risk, intact bone walls, thick facial bone wall (at least 1 mm), with no infection at the extraction site and bone volume providing sufficient primary implant stability, and are candidates for such approach². Despite the reduced treatment time and optimal bone volume available for the implant placement, immediate protocol is associated with increased risk of gingival recession. Approximately 30 % of such sites have gingival recession of at least 1 mm¹⁰. Protocol of immediate implant placement in conditions of unfavourable gingival biotypes, the lack of bone or soft tissue in patients with a high smile line lead to esthetic failure which is very important in the esthetic region¹⁻³.

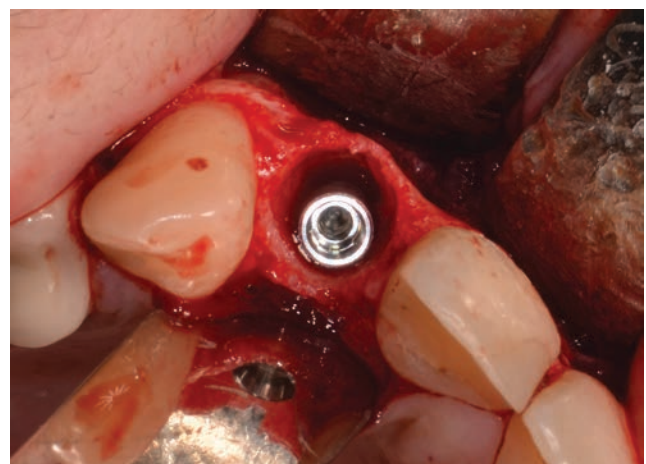


Figure 2. Immediate implant placement. Implant positioned in the fresh extraction socket.

Implant selection

Implant shape and size are determined by the site anatomy and future implant supported restoration^{11,12}. Screw-type implants with micro and nano rough titanium surfaces provide predictable treatment outcome. Improved chemically modified surfaces with hydrophilic feature accelerate osseointegration and allow earlier implant loading¹³. Yttrium-partially stabilised tetragonal zirconia (Y-TZP) due to favourable esthetics, its flexural strength, high resistance to fracture and excellent osseointegration, might be an alternative^{14,15}. For the regions of central incisor and canine where the tooth width is at least 7 mm regular neck implants are recommended whereas for lateral incisor region narrow neck implants should be used. Implants of reduced diameter with new titanium zirconium alloy that exhibit high mechanical resistance can be a viable alternative to extensive bone augmentation procedures. Wide-neck and wide-platform implants should be avoided in the esthetic zone since implant shoulder positioned to facially causes resorption of facial wall and gingival recession^{1,3}.

Number and distribution of implants in extended edentulous sites

Bone remodelling following tooth extraction reduces the width of the alveolar crest resulting in flattened ridge curvature. These changes are associated with reduced linear dimension of the ridge and affect number of implants needed for restoration. The main problem in extended edentulous sites in the esthetic zone is a lack of interimplant soft tissue between the two adjacent implants resulting in short interproximal papilla that represents obvious esthetic shortcoming. Therefore, maintenance of the bone that would provide support for interproximal papilla is of great importance. Proper number and distribution of implants have a great role in this issue. Following implant placement, circumferential vertical (of 2 mm) and horizontal (of 1.5 mm) bone loss from implant abutment level inevitably occurs to establish biological width. At radiograms it is represented as bone "saucer" around implant shoulder. When two adjacent implants are placed at distance less than 3 mm adjacent "saucers" will overlap and interproximal bone will resorb resulting in reduced height of papilla^{1,3}.

In the esthetic zone any two implants should be separated by pontics. Cases with two missing adjacent teeth are the most challenging. In the region of central incisors it could be overcome with two implants at a distance of at least 3 mm. However, in edentulous sites including lateral incisor, it is replaced by cantilever unit and implant should be placed in the region of central incisor or canine³.

Implant positioning

Correct 3D implant positioning is essential for the long-term periimplant bone and soft tissue maintenance that would provide functional and esthetical restoration. In the mesio-distal dimension, implant shoulder should be at least 1.5 mm away from the root of the adjacent tooth in order to prevent resorption of the interproximal alveolar crest. Implant shoulder should be positioned about 1mm apically to the cemento-enamel junction of the adjacent teeth. In the orofacial dimension implant shoulder should be positioned about 1.5-2.0 mm palatally from the imaginary line connecting the point of emergence of adjacent teeth¹. Proper implant alignment in orofacial dimension is especially challenging in immediate implant placement. In order to maintain sufficient thickness of the facial bone wall important for esthetic result, implant site should be prepared in palatal wall of the socket (Figure 2). However, dense palatal cortex guides drill towards the facial bone leading to implant malposition that will end up with gingival recession^{1,2}.

Implant malposition results in bone resorption and thin and deficient facial wall of the implant bed site or leads to gingival recession and prosthodontic complications related to restorations. Correct 3D implant position can be assessed preoperatively using CBCT and radiographic stent consisting of barium sulphate incorporated into the acrylic. In complex cases, where proper implant positioning is a challenge, such as in expanded edentulous area, the usage of conventional surgical template or guided-surgery guide is recommended. If bone deficiency disables correct implant positioning, augmentation procedures are mandatory^{1,3,16}.

Simultaneous versus staged approach

Dimensional changes of the alveolar ridge following tooth extraction or as a result of different pathological issues, usually requires bone augmentation procedures performed either simultaneously with the implant placement or using staged approach^{2,4}. Although simultaneous approach is preferred due to reduced number of operations and reduced treatment time it is predictable only when favourable defect morphology exists i.e. at least two bony walls. In this clinical situation, present bony walls will provide osteogenic elements and supports bone substitute together with barrier membrane allowing predictable regenerative outcome (Figure 3). A residual alveolar ridge with crestal width less than 4 mm disables correct 3D implant positioning and requires staged approach using autologous block bone graft. For this purpose cortico-cancellous bone grafts are harvested

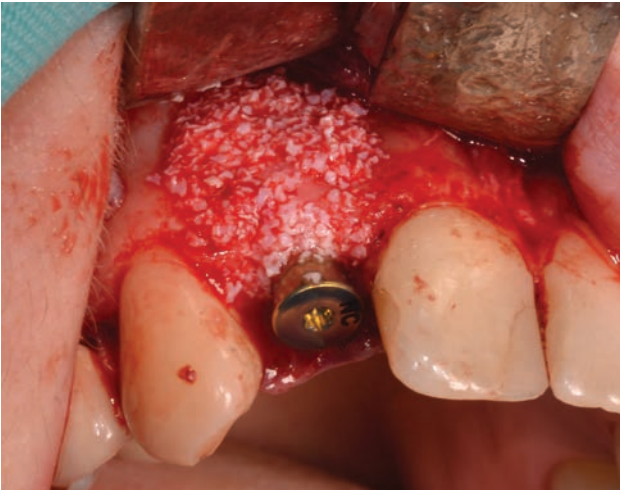

Figure 3. Guided bone regeneration performed simultaneously with the implant placement.

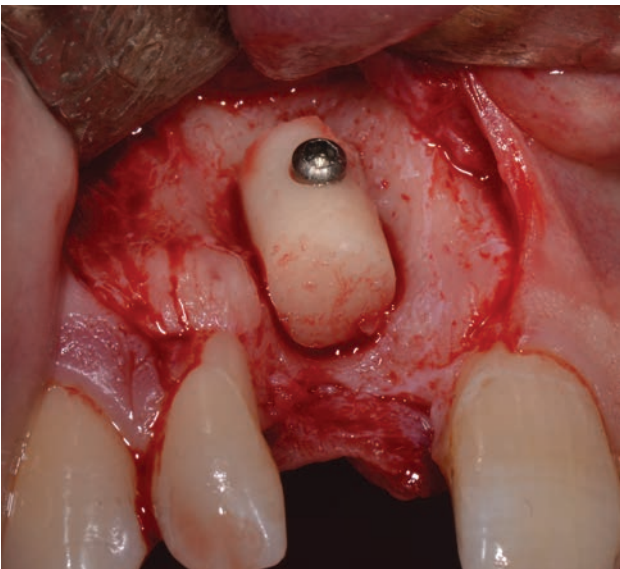


Figure 4a. Staged approach. Bone block harvested from retromolar area and fixed at the recipient site

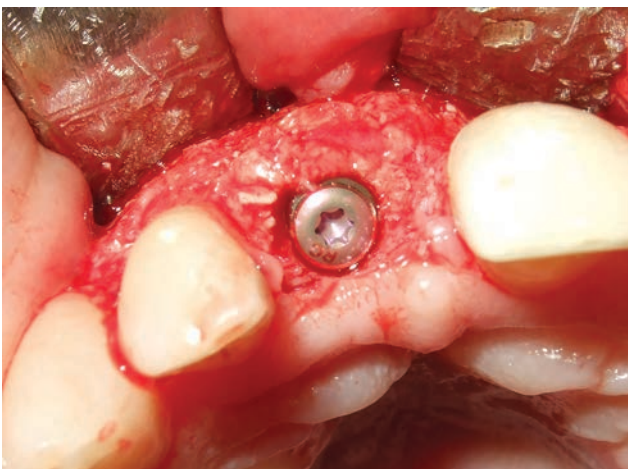

Figure 4b. Staged approach. Implant placed in correct 3D position after 5 months of block bone graft healing.

from chin or retromolar area. Implant should be placed in correct 3D position after 5 months of healing in order to prevent graft resorption¹⁶.

Note: The results of this paper were presented as a part of an invited lecture at the 21st BaSS Congress.

References:

1. Buser D, Belser U, Wismeijer D. Implant Therapy in the Esthetic Zone - Single Tooth Replacements. Berlin; London: *Quintessence*, 2007.
2. Chen S, Buser D. Implant Placement in Post-Extraction Sites - Treatment Options. Berlin; London: *Quintessence*, 2008.
3. Wismeijer D, Chen S, Buser D. Extended Edentulous Spaces in the Anterior Zone. Berlin; London: *Quintessence*, 2013.
4. Turri A, Rossetti PH, Canullo L, Grusovin MG, Dahlin C. Prevalence of Peri-implantitis in Medically Compromised Patients and Smokers: A Systematic Review. *Int J Oral Maxillofac Implants*, 2016;31:111-118.
5. Bornstein MM, Cionca N, Mombelli A. Systemic conditions and treatments as risks for implant therapy. *Int J Oral Maxillofac Implants*, 2009;24:12-27.
6. Gomez-Moreno G, Aguilar-Salvatierra A, Pemandez-Cejas E, Delgado-Ruiz RA, Markovic A, Calvo-Guirado JL. Dental implant surgery in patients in treatment with the anticoagulant oral rivaroxaban. *Clin Oral Implants Res*, 2016;27:730-733.
7. Cochran D, Schou S, Heitz-Mayfield LJ, Bornstein MM, Salvi GE, Martin WC. Consensus statements and recommended clinical procedures regarding risk factors in implant therapy. *Int J Oral Maxillofac Implants*, 2009;24:86-89.
8. Zhou Y, Gao J, Luo L, Wang Y. Does Bruxism Contribute to Dental Implant Failure? A Systematic Review and Meta-Analysis. *Clin Implant Dent Relat Res*, 2016;18:4104-20.
9. Boardman N, Darby I, Chen S. A retrospective evaluation of aesthetic outcomes for Single-tooth implants in the anterior maxilla. *Clin Oral Implants Res*, 2016;27:443-451.
10. Chen ST, Buser D. Clinical and esthetic outcomes of implants placed in postextraction sites. *Int J Oral Maxillofac Implants*, 2009;24:186-217.
11. Gehrke SA, Perez-Albacete Martinez C, Piattelli A, Shibli A, Markovic A, Calvo-Guirado L. The influence of three different apical implant designs at stability and osseointegration process: experimental study in rabbits. *Clin Oral Implants Res*, 2016 Mar. DOI: 10.1111/clr.12807.
12. Markovic A, Calvo-Guirado L, Lazic Z, Gomez-Moreno G, Calasan D, Guardia J, et al. Evaluation of primary stability of self-tapping and non-self-tapping dental implants. A 1 z-week clinical study. *Clin Implant Dent Relat Res*, 2013;15:341-349.
13. Wallkamm B, Ciocco M, Ettlin D, Syfrig B, Abbott W, Listrom R, et al. Three-year outcomes of Straumann Bone Level SL Active dental implants in daily dental practice: a prospective non-interventional study. *Quintessence Int*, 2015;46:591-602.

-
14. Delgado-Ruiz RA, Gomez Moreno G, Aguilar-Salvatierra A, Markovic A, Mate-Sanchez JE, Calvo-Guirado JL. Human fetal osteoblast behavior of zirconia dental implants and zirconia disks with microstructured surfaces. An experimental in vitro study. *Clin Oral Implants Res*, 2015 Mar 25. DOI: 10.1111/clr.12585.
15. Delgado-Ruiz RA, Markovic A, Calvo-Guirado JL, Lazić Z, Plattelli A, Boticelli D, et al. Implant stability and marginal bone level of microgrooved zirconia dental implants: A 3-month experimental study on dogs. *Vojnosanit Pregl*, 2014;451-461.
16. Chen S, Buser D, Wismeijer D. Ridge Augmentation Procedures in Implant Patients - A Staged Approach. Berlin; London: *Quintessence*, 2014.

Corresponding author:

Prof. Aleksa Marković
Clinic of Oral Surgery
School of Dentistry
University of Belgrade
Dr Subotica 4
11 000 Belgrade, Serbia
Tel: +381 11 2685860
Fax: +381 11 2685268
e-mail: maleksa64@gmail.com