

Neurovascular Content of the Mandibular Canal and Its Clinical Relevance: A Literature Review of the Related Anatomical and Radiological Studies

SUMMARY

In literature, anatomical variations of the inferior alveolar nerve branches (infratemporal, extraosseous and intraosseous) are reported and their importance in clinical practice is discussed too. The spatial vessels' position in relationship with the nerve in the mandibular canal was explored, which is of clinical significance in impacted third molar and implant surgery. It is believed that the neurovascular content of the main mandibular canal follows any variations of the mandibular canal i.e. bifid mandibular, retromolar and accessory mental canals. Retrospective studies and case reports reported the presence of multiple foramina on the medial surface of the ramus, near the main mandibular foramen. In some cases, one supplementary mandibular foramen was found to be connected with the lower third molar, which is called "temporal crest canal". Others found an accessory mandibular foramen that led into a second mandibular canal which joined the main mandibular canal (double) anteriorly. The bony canals contained a terminal branch of the anterior trunk of the mandibular nerve or a branch of inferior alveolar nerve before it entered the mandibular foramen.

The aim of the study was to describe and classify anatomical structures of the mandibular canal and posterior foramina of the mandible through an extensive review of the corresponding studies via the PubMed, Scopus and Google Scholar databases.

Keywords: Mandibular Canal; Inferior Alveolar Nerve, Artery, Vein; Mandibular Foramen

**Apostolos N. Eliades, Kalliopi H. Manta,
Anastasios T. Tsirlis**

Aristotle University of Thessaloniki
Faculty of Dentistry, Department of Oral Surgery
Implantology and Oral Radiology
Thessaloniki, Greece

LITERATURE REVIEW (LR)

Balk J Dent Med, 2014; 18:124-132

Introduction

Mandibular canal crosses the mandibular body and part of the ramus. Knowledge of the anatomic structures enclosing the mandibular canal, the relationships with each other and with adjacent structures is important for both the general dentist as well as for the oral surgeon and implantologist. Moreover, anatomical variations of the inferior alveolar nerve branches are reported in bibliography and their importance in clinical practice too. For the purposes of the article, only the branches of the mandibular nerve providing innervation to mandibular teeth and periodontal tissues will be described with emphasis to the inferior alveolar nerve.

The aim of the study was to give a detailed description and classification of the anatomical structures of the mandibular canal and posterior foramina of the mandible and an extensive review of the corresponding published studies. Databases reviewed included the PubMed (MEDLINE), Scopus and Google Scholar.

The *long buccal nerve* derives from the anterior stem of the mandibular nerve. It usually passes between the two heads of the lateral pterygoid muscle, then follows the inferior part of the temporal muscle and emerges under the anterior border of the masticator muscle, continuing in an anterolateral direction¹. At the level of the occlusal plane of the mandibular third molar, it crosses in front of the anterior border of the ramus and enters the cheek through the buccinator muscle¹. The long buccal nerve provides sensory

innervation to the mucosa and skin of the cheek^{1,2}. In some cases, it gives anastomotic branches to the facial nerve¹. Also, sensory fibres pass into the retromolar triangle, providing innervation to the buccal gingiva of the lower third molars and the buccal mucosa of that region^{1,2}.

Mylohyoid nerve originates from the inferior alveolar nerve before the latter enters the mandibular foramen. It runs downward and forward in the mylohyoid groove, between the medial pterygoid muscle and the internal surface of the ramus¹. Then, it crosses between the submandibular gland and the lower surface of the mylohyoid muscle. The mylohyoid nerve bifurcates from the inferior alveolar nerve at a distance of 14.7 mm from the mandibular foramen³. Mylohyoid nerve is a mixed nerve being responsible for the motor innervation of the mylohyoid muscle and the anterior belly of digastric muscle, and for the sensory innervation of the skin on the inferior and anterior surfaces of the mental protuberance and submental region¹.

DeSantis et al³ stated that in 43% of the examined cadaver dry mandibles osseous lingual foramina were identified in the anterior lingual surface of the mandible, which were associated with nerve branches of the mylohyoid nerve that are inserted the mandible, whereas in another study⁴ the branches of mylohyoid nerve were found to innervate the pulp and gingiva of lower incisors in 50% of the cadaver dry mandibles. There is evidence that the mylohyoid nerve may be involved in supplying pulpal innervation to mandibular molars in some persons, usually the mesial root of the 1st molar¹, and to the anterior teeth³⁻⁶.

The mandibular nerve is one of the 3 divisions of the fifth cranial nerve, trigeminal nerve, and passes through the oval foramen to the infratemporal fossa, wherein it subsequently branches in several nerves¹. One of them is the **inferior alveolar nerve (IAN)** which is situated posteriorly and laterally the lingual nerve between the pterygoid muscles. IAN enters the mandible through mandibular foramen with homonyms blood and lymphatic vessels². The **inferior alveolar neurovascular bundle**, usually, travels through the mandibular canal, inferiorly to the lower posterior teeth, and continues until the premolar region dividing into its 2 terminal branches:

a) **mental neurovascular bundle** - it is the branch leaving the mandible through the mental foramen, giving 3 terminal ends that innervate skin and mucous membrane of the lower lip and skin of the chin region^{1,7}. In several cases, before the mandibular neurovascular bundle exits the jaw, it creates an endosteal curved loop proximal to the mental foramen, called **anterior loop**, and then returns distally to finally leave the mandible through the mental canal as mental neurovascular bundle (Fig. 1).

b) **lower incisor neurovascular bundle** - it is the terminal branch of the endosteal course of the inferior alveolar bundle, which travels in the incisive canal inferiorly to the mandibular anterior teeth and terminates in the midline of the jaw where it is anastomosed with the corresponding bundle of the opposite side^{5,7-10} (Fig. 2). The incisive nerve

remains within the incisive bony canal and forms a nerve plexus that innervates the pulpal tissues of the mandibular first premolar, canine and incisors *via* the dental branches¹.

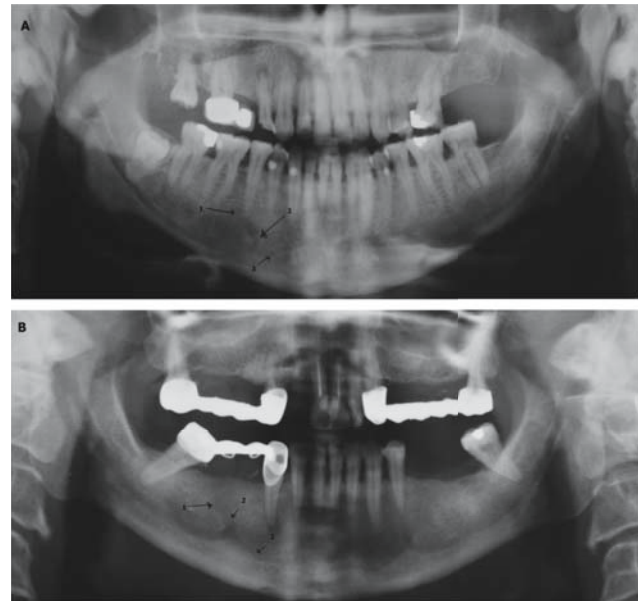

Figure 1. Panoramic radiographs of two patients 35 (Fig 1A) and 58 (Fig 1B) years old respectively, showing the mental foramen (arrow No1), the endosteal canal of the anterior loop of the inferior alveolar neurovascular bundle (arrow No2) and the mandibular incisive canal (arrow No3)

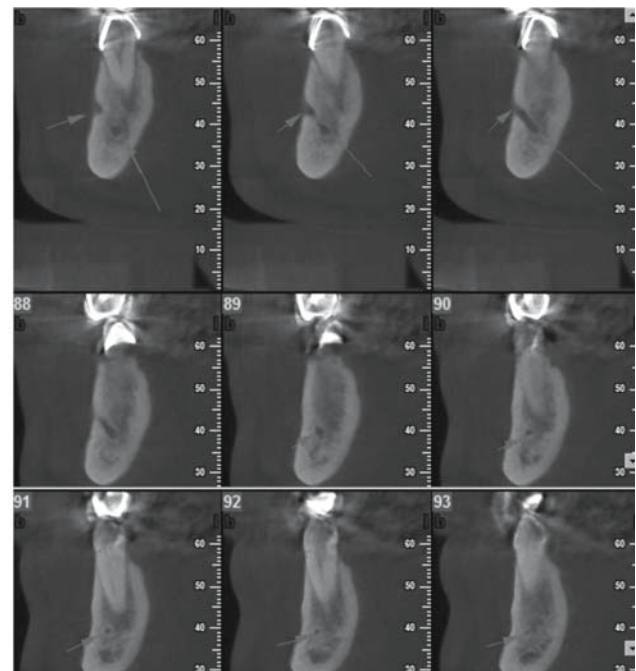


Figure 2. Cross-sectional images from cone beam computed tomography (CBCT): a) the cross sections 85-87 show the endosteal course of the inferior alveolar neurovascular bundle (osseous mental canal: large arrow) until it exits the mandible through the mental foramen (small arrow) and finally it is called as mental neurovascular bundle. b) the cross sections 88-93 shows that inferior alveolar neurovascular bundle gives an endosteal branch, which courses through the osseous incisive canal until the midline of the jaw (small arrow)

The IAN innervates the lower jaw, teeth, periodontal tissues and buccal soft tissues of the premolars and anterior teeth, the skin of the chin and the mucosa of the lower lip^{1,5,8}.

The position of the mandibular foramen varies depending on the race and ethnicity². It is located on a bony insolence, the lingula, at the middle of the ramus' medial surface, at about 19.7 mm from the anterior border of the ramus^{2,7,11}. The distance from the injection point for the inferior alveolar block anaesthesia to the foramen is about 21 mm equal to the length of the short needle or to $\frac{2}{3}$ of the large one^{1,2}.

By determining as a hypothetical vertical distance the line joining the condyle with the inferior border of the ramus and as a horizontal distance the line joining the posterior edge of the ramus until the most concave point of the anterior border of the ramus, the mandibular foramen is usually situated in the ventral and inferior $\frac{2}{3}$ of the ramus without difference according to the side, sex or age¹². However, studies report conflicting results about the exact location of the foramen. One study¹³ reported that, in adults, the foramen was inferior, at the same level and superior to the occlusal level at a percentage of 75%, 22.5% and 2.5%, respectively, while another¹⁴ stated percentages 29.4%, 47.1% and 23.5%, respectively. Hence, if the insertion of the needle occurs at the same level as the occlusion plane the foramen is likely to be at a highest location point at 2.5-23.5% and the anaesthesia will fail². Thus, it is recommended to insert the needle of injection at the deepest part of the pterygomandibular raphe at 6-10 mm above the occlusal plane of the mandibular molar teeth.

Authors of contemporary dental anaesthesia books emphasize on an alternative method of administering the IAN block anaesthesia^{1,15-19}. The traditional way of determining the injection point for the needle of syringe is by using the index finger intraorally at the most concave point of the ramus' anterior border. Hence, the clinicians insert the $\frac{2}{3}$ of the needle at the pterygomandibular raphe, at a height of 1 cm above the occlusal plane of the mandibular molars and with a direction coming from the opposite mandibular premolars. Alternatively, the clinicians may place the thumb intraorally on the coronoid notch and the index finger extraorally on the posterior border of the ramus and estimate the distance between these points, which is in other words the width of the ramus. The alternative technique offers the sense of horizontal length of the ramus in comparison with the traditional way which cannot. There is a need of a randomized clinical trial to prove the advantage of this method in comparison with the conventional one of inferior alveolar block anaesthesia in achieving better anaesthesia results.

In the literature, several case reports stated the presence of multiple foramina on the medial surface of the ramus, near the main mandibular foramen²⁰⁻²², while

an anatomical study²³ indicated that double mandibular foramina were found in a percentage of 8.9% of the examined jaws. Murlimanju et al²⁴ observed accessory mandibular foramina in 11 out of 67 adult human dry mandibles (double mandibular foramina in 9 cases and triple in 2 cases). Freire et al²⁵ found that 27.9% and 43.2% of the 222 examined dry mandibles presented at least one accessory mandibular foramen located on the medial surface in position below and above, respectively, of the main mandibular foramen. Samanta and Kharb²⁶ stated a presence of accessory mandibular foramina in 16.7% of 60 human adult dry mandibles. In 10% mandibles, a single accessory foramen was present, and in 6.7% double foramina were present. Haveman and Tebo²⁷ found that foramina of 0.4mm in diameter, or greater, occurred bilaterally superiorly or inferiorly to the main mandibular foramen in more than 90% of 150 examined dry adult human mandibles. The bony canals that started from these foramina contained branches of the IAN or mandibular nerve, which gave these branches at a highest point of the usual mandibular foramen^{20,28}.

In two case reports^{20,29}, metallic wires were inserted within the osseous canals of the supplementary mandibular foramina. The results showed that 1 supplementary mandibular foramen, situated 17 mm superiorly to the main mandibular foramen, was connected with the crypt of the lower third molar in each side of the jaw. In our opinion, the anatomical variation of the above studies was a subtype of *temporal crest canal*, which was connected with the third molar of the mandible. Temporal crest canal is a bony canal that starts from a supplementary mandibular foramen located anteriorly to the main foramen at the temporal crest and finally opens at the retromolar fossa³⁰⁻³³. It is believed that it contains a terminal branch of the anterior trunk of the mandibular nerve (long buccal nerve variant) or a branch of the IAN before it enters the mandibular foramen^{6,30-33}. The dissection and histopathological study of the temporal crest canal confirmed the presence of an internal neurovascular structure³⁴.

The presence of multiple foramina and paramandibular canals was explained by the conduct of Serres development, a formation which was described by the French anatomist Antoine Etienne Reynaud Augustin Serres in 1817³⁵. It was initially called "conduct of the first teething", believed to contain a branch of the inferior alveolar artery and vein dedicated to irrigation of temporary teeth³⁵. This entity was just distally to the main mandibular foramen and highly prevalent in infantile jaws and in newborn it reached 100%³⁵. However, the anatomical study of Suazo et al³⁶ on 324 jaws of 68 sub-adults aged 0-2 years and 256 adults aged 18-100 years showed a prevalence of "conduct of Serres" in 100% in sub-adults group and 42.6% in the adults group. The study showed that the term "Serres' conduct" is observed in almost all the ages.

With these data, the character of this anatomical variation as Serres' conduct is questionable due to the fact that it is actually a bony canal that has its opening distally to the main mandibular foramen, at a supplementary foramen. Furthermore, the term "conduct" refers to a structure of soft walls, but with the analyzed formation being a structure of hard walls this then should be called "canal"³⁶. With these considerations, besides the parallel orientation of the mandibular canal, the name of the foramen and conduct of Serres should be replaced with "accessory mandibular foramen" and "para-mandibular canal", respectively, while this canal is not joined with the main mandibular canal during its anteriorly intraosseous course (without confluence with the main mandibular canal).

Moreover, a large accessory mandibular foramen was present in 1 mandible out of 335 mandibles (0.3%) observed in a cadaveric study³⁷. The accessory foramen led into a canal that passed forward and lateral to the mandibular canal and joined the lateral at the level of the wisdom tooth. This kind of canal is called in bibliography a "double mandibular canal", which originates from 2 separate mandibular foramina³⁸⁻⁵².

The inferior alveolar artery (IAA) originates from the internal maxillary artery, branch of the external carotid. Before its insertion at the mandibular foramen, it branches the mylohyoid artery^{53,54}. Throughout its path in the mandibular canal it accompanies the IAN and the inferior alveolar vein (IAV) and courses with them in a parallel direction^{1,55}. Its diameter is of 0.7-2 mm and provides dental, gingival and alveolar bony branches^{38,55}. At the level of the jaw between premolars the artery cleaves in mental artery, which exits through the mental foramen, and incisive artery, which courses anteriorly through the homonymous canal and finally is anastomosed with its opposite. It is believed that the variations of IAA accompany any of the variants of the mandibular canal.

Recent studies have explored the spatial position of vessels in relationship with the IAN^{1,8,55-58}. The IAV is composed by multiple venulae (3-5), while the artery (IAA) was found to be solitary⁵⁷. In a percentage of 80%, the vessels were found to be superiorly to the nerve and the artery was always linguallly to the vein⁵⁷. Consistent of the above topographic layout in the entire examined sample were the results in most anatomical, histological and MRI studies^{55,56,58}. On the other hand, the other study⁵⁷ stated that in 60% of the examined sample IAA was inferiorly to the nerve at the level of the mandibular foramen, while until the mental foramen versa, in 20% the IAA was always superiorly to the nerve and in the rest 20% the vessels were found buccal to the nerve. Another study⁸ reported that the IAV was superiorly to the IAA, which in turn was also superiorly to the nerve. Similarly, Hur et al⁵⁹ found that in most cases of the cadaveric sample the arterial branch was located at the superior buccal aspect of the mandibular canal in the mandibular molar and retromolar regions.

The clinical importance of these observations is that when a surgeon accidentally perforates the cortical roof of the mandibular canal while drilling for an implant

placement, a trauma of the inferior alveolar vessels will occurred and a corresponding haemorrhage, but if the procedure is interrupted then the direct injury of the IAN will be avoided⁵⁵⁻⁵⁷. Thus, a corresponding temporary paraesthesia of the IAN will be due to the indirect trauma of the nerve caused by the pressing force of the hematoma to the nerve. Hence, when the hematoma will be surrendered, the numbness would probably cease⁵⁵⁻⁵⁷. However, the vessels' position in the mandibular canal is of clinical significance in impacted third molar surgery with proximity to the mandibular canal for the same reasons.

Discussion

The IAN and its variations were described by several researchers as below:

Throughout its infratemporal course, the IAN may give communication fibres to the mylohyoid nerve, the lingual nerve or the long buccal nerve³⁰ and an innervation branch to the lateral pterygoid muscle⁶⁰;

The IAN, before entering the mandibular canal, may give multiple extraosseous branches. In some cases this variation is associated with the presence of accessory mandibular foramina and insertion of these neural branches in the osseous canals. Then, the branches: a) may communicate through a bony canal (temporal crest canal) with the retromolar triangle and end at an exit foramen called "retromolar foramen" distal to the third molar³¹⁻³³, b) may communicate with the third molar^{20,28,31}, c) may travel within the supplementary canal through the ramus or body of the mandible until exiting the mandible through a supplementary buccal mental foramen³⁹ or a lingual foramen⁴¹ or d) may join the main mandibular nerve^{31,38,39};

Even if the IAN enters the mandible by a single mandibular foramen, it can have intraosseous branches, during its course into the mandibular canal, which are not always surrounded by bony tissue, such as to be radiographically imaged⁴⁰. Several authors have described the intraosseous course of IAN and its branches variations in different ways. A literature review of the related publications was conducted *via* PubMed (MEDLINE), Scopus and Google Scholar from January 1970 until July 2013 (Tab. 1)^{8,28,31,55,61-63}.

Carter and Keen³¹ examined 8 dissected human mandibles and described 3 types of inferior alveolar arrangement: Type I (n=6) was a single nerve lying close to the root apices, Type II (n=1) ran lower down in the mandible and gave off long oblique branches to the teeth, Type III (n=1) gave off 2 posterior branches that ran in separate canals (bifid canal). A large inferior branch passed to the mental foramen and incisor teeth, whereas a more superior alveolar branch supplied the molar and premolar teeth. The findings were also confirmed radiographically on 80 dried mandibles.

Table 1. Classifications of intrabony branching patterns of the inferior alveolar nerve (IAN). Anatomical (dissection), histological and MRI studies describing variations of the IAN, published from January 1970 until July 2013, were only included. Radiological studies were excluded.

Authors	Year of study	Method of study	No of specimens studied (cadaveric mandibles)	Types of inferior alveolar nerve and variations	Frequency (%)
Carter & Keen ³¹	1971	Dissection, radiographic examination	8 80	Type I The IAN is a large structure lying in a bony canal (single canal). Subsequently, the nerve terminated in a mental arborization, with offshoots to the plexus adjacent to the incisors, before it enters the mental foramen. The incisor plexus, while connected to the branches mentioned, was not the source of the dental branches.	75
				Type II The IAN is situated substantially lower down in the mandible (lower canal) some distance from the roots of the molars. The dental branches are given off more posteriorly and are more oblique in position than in type I. The further course of the nerve is described as above.	12.5
				Type III The IAN is separated posteriorly into two large branches, which together could be regarded as equivalent to an alveolar branch (bifid nerve) while the main continuation of the nerve occupied a more inferior position and continued, as in other types, towards the mental foramen and the supply of the anterior teeth.	12.5
Ikeda et al ⁵⁵	1996	MRI examination, histology	6	The IAN inside the mandibular canal is composed of three branches: retromolar branch: it is separated from the main stem of IAN at the level of the mandibular foramen and it travels at company with IAN for a 2-5 mm course; in continue it turns up right at a level just behind the wisdom tooth. molar branch: is responsible for the innervations of posterior teeth and starts from IAN or the retromolar region, follows a parallel course with the ridge and inferiorly to the teeth and when it reaches its final destination it turns up. incisive branch: it is branched from the stem of IAN near the mental foramen region and travels anteriorly. The IAN exits the mandible from the mental foramen as mental nerve.	100
Wadu et al ⁸	1997	Dissection, radiographic examination	29	The nerve trunk is divided into a molar plexus in the molar area. The main nerve is then secondly divided into the incisive and mental branches in the molar area well before reaching the mental foramen. There were communications between the mental and incisive nerves proximal (incisal plexus) to and at the mental foramen.	100
Polland et al ⁶¹	2001	Dissection, panoramic examination, histology	7	The inferior alveolar nerve near the mandibular foramen was a large trunk, consisting of three to four nerve bundles with connective tissue sheaths. It became more loosely arranged toward the mental foramen. Medial to the latter, the nerves were frequently in the form of small bundles in the marrow. Any incisive canal, when present, ran through a labyrinth of intertrabecular spaces.	100
Kieser et al ⁶²	2004	Dissection	39	Type I Single trunk that coursed anteriorly toward the mental foramen without obvious branches (unbranched).	38.5
				Type II A single trunk and a series of individual simple branches directed at the superior border of the mandible.	7.7
				Type III A small (fine) molar plexus of branches from the proximal half of the IAN.	28.2
				Type IV There are two nerve plexuses, one associated with the proximal half and one the distal half of the IAN, proximal and distal nerve plexus respectively.	25.6

Kieser et al ⁶³	2005	Dissection	107	Type I	A common neural stem with a series of nerve branches directed towards the alveolar ridge in a vertical plane joining the ridge with the canal.	52-59
				Type II	A common neural stem with a small nerve plexus in the molar region.	21-26
				The spatial fascicular arrangement of the IAN took various forms. The somatotopic arrangement of the IAN was categorized according to the nerve fascicles innervating each tooth.		
				In all of 15 cases of nerve fascicle separation, the nerve fascicles located at the superior buccal portion of the IAN within the MC innervated the mandibular second and third molars.		100
				In case of presenting the retromolar branch, this branch also arose from the superior buccal nerve fascicles of the IAN.		
				The nerve fascicles innervating the first molar were classified into two categories:		
				1. those running in the superior buccal portion of IAN and		66.7
				2. those running in the superior portion of the IAN.		33.3
				A nerve branch innervating the second premolar was observed for two categories of nerve fascicles running in:		
				1. the superior portion of the IAN and		86.7
				2. the superior buccal portion of the IAN.		13.3
				The nerve fascicles innervating the first premolar were classified into four types, with the nerve fascicles running in:		
				1. the superior lingual portion,		60
				2. the superior buccal portion,		20
				3. inferior lingual portion, and		13.3
				4. the superior portion of the IAN.		6.7
Hur et al ⁵⁹	2013	Dissection	15	The courses of the nerve fascicles innervating the mandibular anterior teeth (central, lateral incisors, and canine) could be divided into six categories, with nerve fascicles running in:		
				1. the superior lingual portion of the IAN within the posterior MC and the lingual portion within the anterior MC;		33.3
				2. the superior and inferior lingual portions of the IAN within the posterior MC, and then in the lingual portion within the anterior MC after merging;		33.3
				3. the superior lingual portion of the IAN throughout the MC;		13.3
				4. the inferior lingual portion of the IAN throughout the MC,		6.7
				5. the inferior portion of the IAN, receiving the nerve fascicles from the inferior lingual and inferior buccal portions within the posterior MC, and then in the inferior lingual portion of the IAN within the anterior MC; and		6.7
				6. the lingual and buccal portions of the IAN within the posterior MC, and then in the lingual portion of the IAN within the anterior MC.		6.7
				The MN travelled mainly within the IAN and contained nerve fascicles running in the buccal portion throughout the MC.		100

Ikeda et al⁵⁵ identified with MRI and histology that in edentulous patients the IAN (higher signal intensity than the surrounding connective tissue) inside the mandibular canal is composed of 3 branches: a) retromolar branch, which is separated from the main stem of the IAN at the level of the mandibular foramen

and travels at company with IAN for a 2-5 mm course; it continuous and turns up right at a level just behind the wisdom tooth; b) the second (molar) branch, which was responsible for innervation of posterior teeth and starts from the IAN at the retromolar region, follows a parallel course with the ridge and inferiorly to the teeth and when

it reaches its final destination it turns up; c) the third branch, which is called incisive nerve is branched from the stem of the IAN near the mental foramen region and travels anteriorly. The IAN exits the mandible from the mental foramen as mental nerve. The mandibular canal contains IAN, the inferior alveolar vessels (low level signal), loose connective tissue and sometimes the retromolar and molar branches⁵⁵. Histologically, the IAN is composed by 2-8 nerve bundles⁵⁵.

Kieser et al⁶² reported that the IAN was located in the superior part of the body of the mandible in 31% of the cases, all of which showed a small posterior molar plexus of branches. In 69% of cases the IAN was half-way or closer to the inferior border of the mandible. Of the latter cases, 1% demonstrated a small posterior molar neural plexus, 37% showed posterior and anterior plexuses and 22% showed no branches or a single trunk with a small number of single branches directed superiorly to the alveolar ridge. However, in another study, Kieser et al⁶³ reported that in edentulous patients the arrangement of the IAN was found to be: a) a common neural stem with a series of nerve branches directed towards the alveolar ridge in a vertical plane joining the ridge with the canal (52-59%); or b) a common neural stem with a small nerve plexus in the molar region (21-26%). This may explain the alveolar ridge alterations after tooth loss and why these patients report pain or discomfort in the molar region during mastication with a dentition⁶⁴.

According to Hur et al⁵⁹ the most common pattern of nerve fascicle innervation to the mandibular teeth could be grossly classified into 3 types: (1) the superior buccal portion of the IAN innervating the molars; (2) the superior portion innervating the premolars; and (3) the superior lingual or the superior lingual and inferior lingual portions in the posterior MC and the lingual portions in the anterior MC, innervating the incisors and canine. The buccal $\frac{2}{3}$ portion of the IAN innervated the lower lip, skin of the chin, and the vestibular gingiva.

Radiographically, the mandibular canal appears as a dark, linear shadow with thin, radiopaque superior (or roof) and inferior (or bottom) borders, cast by the cortical bone that bounds the canal (Fig. 1). The total length of the canal is in average 62.5 mm, while in men it is usually longer by 2.5 mm⁶⁵. The canal's diameter is always wider near the mandibular foramen and is approximately 4 mm, while its average diameter is found to be 2-3.4 mm^{7,55,63}. The canal was found to be oval-shaped near the mandibular foramen and round-shaped near the molars^{28,42,66}. Indicatively, Miller et al⁶⁶ reported that the shape of the mandibular canal was oval-shaped with vertical and horizontal dimension of 2.9 and 2.5 mm respectively in examined cases of impacted wisdom teeth. The smallest canal diameter of 1.2 mm concerned a case where the canal was coursed between the roots of the impacted tooth⁶⁶. It is believed that the neurovascular content of the main mandibular canal follows the

variations of the mandibular canal, i.e. bifid mandibular canal, retromolar mandibular canal and accessory mental canal^{42-49,51,52,55,67-71}.

Chavez et al⁷² reported that during embryonic development there may be 3 canals innervating 3 groups of mandibular teeth. The canal to the incisors appeared first followed by the canal to the primary molars and subsequently canal to the permanent molars. These canals are directed from the lingual surface of mandibular ramus towards different tooth groups. During rapid prenatal growth and remodelling in the ramus region, there is a spread of intra-membranous ossification that commences where the IAN divides into mental and incisive branches around 7 weeks prenatal⁷²⁻⁷⁴. The extension of ossification posteriorly along the lateral border of Mechel's cartilage produces a gutter around the IAN that eventually forms the single mandibular nerve canal⁷²⁻⁷⁴. Hence, a possible explanation of the presence of bifid or even three-fid mandibular canal is the incomplete embryological fusion of these nerve canals. Branching of the IAN or communications with other nerves would be reflected in various types of mandibular canal and/or neural morphology^{41,73,74}.

Conclusion

To summarize, reviewing the literature, it can be concluded that there are variations of the mandibular canal and the IAN that are not well reported in anatomic textbooks or are not classified in detail. The course and the content of the mandibular canal, its variations and foramina are of clinical importance in oral surgery, implantology and dental anaesthesia. The IAN is accompanied by the homonymous vessels inside the mandibular bony canal. The knowledge of topographic relationship between the IAN and the homonymous vessels are of crucial importance for any clinician. Preoperative radiographic evaluation of a mandibular canal variation or the location and course of a retromolar or accessory mental canal is necessary in order to avoid any complications during oral surgery procedures, i.e. bleeding or paraesthesia.

References

1. *Malamed FS*. Handbook of Local Anesthesia. 5th ed. Elsevier St Louis: Mosby. 2004; pp 171-253.
2. *Greenstein G, Cavallaro J, Tarnow D*. Practical application of anatomy for the dental implant surgeon. *J Periodontol*, 2008; 79:1833-1846.

3. DeSantis JL, Liebow C. Four common mandibular nerve anomalies that lead to local anesthesia failures. *J Am Dent Assoc*, 1996; 127:1081-1086.
4. Madeira MC, Percinoto C, das Gracas M, Silva M. Clinical significance of supplementary innervation of the lower incisor teeth: a dissection study of the mylohyoid nerve. *Oral Surg Oral Med Oral Pathol*, 1978; 46:608-614.
5. Jacobs R, Lambrechts I, Liang X, Martens W, Mraiwa N, Adriaenssens P, Gelan J. Neurovascularization of the anterior jaw bones revisited using high-resolution magnetic resonance imaging. *Oral Surg Oral Med Oral Pathol Oral Radiol Endod*, 2007; 103:683-693.
6. Kaufman E, Serman NJ, Wang PD. Bilateral mandibular accessory foramina and canals: a case report and review of the literature. *Dentomaxillofac Radiol*, 2000; 29:170-175.
7. Aalam AA, Nowzari H. Mandibular cortical bone grafts. Part 1: Anatomy, healing process, and influencing factors. *Compendium*, 2007; 28:206-213.
8. Wadu SG, Penhall B, Townsend GC. Morphological variability of the human inferior alveolar nerve. *Clin Anat*, 1997; 10:82-87.
9. Krasny A, Krasny N, Prescher A. Study of inferior dental canal and its contents using high-resolution magnetic resonance imaging. *Surg Radiol Anat*, 2012; 34:687-693.
10. Krasny A, Krasny N, Prescher A. Anatomic variations of neural canal structures of the mandible observed by 3-Tesla magnetic resonance imaging. *J Comput Assist Tomogr*, 2012; 36:150-153.
11. Hayward J, Richardson ER, Malhotra SK. The mandibular foramen: its anteroposterior position. *Oral Surg Oral Med Oral Pathol*, 1997; 44:837-843.
12. Trost O, Salignon V, Cheynel N, Malka G, Trouilloud P. A simple method to locate mandibular foramen: preliminary radiological study. *Surg Radiol Anat*, 2010; 32:927-931.
13. Nicholson ML. A study of the position of the mandibular foramen in adult human mandible. *Anat Rec*, 1985; 212:110-112.
14. Mbajjorgu EF, Ekanem AU. A study of the position of the mandibular foramen in adult black Zimbabwean mandibles. *Cent Afr J Med*, 2000; 46:184-190.
15. Meechan J, Robb N, Segmour R. Pain and anxiety control for the conscious dental practice. New York: Oxford University Press, 1998; pp 121-131.
16. Korbendau MJ, Korbendau X. Clinical success in impacted third molar extraction. Paris: Quintessence International, 2003; pp 51-56.
17. Roberts GJ, Rosenbaum NL. A colour atlas of dental analgesia & sedation. London: Wolfe Publishing LTD, 1991; pp 41-45.
18. Archer W. A manual of dental anesthesia. Philadelphia & London, 2nd ed. Saunders Company, 1958; pp 89-99.
19. Bennett C. Monheim's Local anesthesia and pain control in dental practice. 6th ed, Saint Louis; Mosby, 1978.
20. Barker BCW, Lockett BC. Multiple canals in the rami of a mandible. *Oral Surg Oral Med Oral Pathol*, 1972; 34:384-389.
21. Heller AA, Shankland WE. Alternative to the inferior alveolar nerve block anesthesia when placing mandibular dental implants posterior to the mental foramen. *J Oral Implantol*, 2001; 3:127-133.
22. Jeyaseelan N, Sharma JK. Morphological study of unnamed foramina in north Indian human mandibles and its possible role in neurovascular transmission. *Int J Oral Surg*, 1984; 13:239-242.
23. Serman NJ. An osteo-radiographic study of the mandibular canal. M.S. Thesis. University of Stellenbosch, S. Africa, 1982; pp 77-108.
24. Murlimanju BV, Prabhu LV, Prameela MD, Mohammed Ashraf C, Krishnamurthy A, Ganesh Kumav C. Accessory mandibular foramina: prevalence, embryological basis and surgical implications. *J Clin Diagn Res*, 2011; 5:1137-1139.
25. Freire AR, Rossi AC, Prado FB, Caria PHF, Botacin PR. Incidence of the mandibular accessory foramina in Brazilian population. *J Morphol Sci*, 2012; 29:171-173.
26. Samanta PP, Kharb P. Morphometric analysis of mandibular foramen and incidence of accessory mandibular foramina in adult human mandibles of an Indian population. *Rev Arg De Anat Clin*, 2013; 5:60-66.
27. Haveman CW, Tebo HG. Posterior accessory foramina of the human mandible. *J Prosthet Dent*, 1976; 35:462-468.
28. Sutton JP. The practical significance of mandibular accessory foramina. *Aust Dent J*, 1974; 19:167-173.
29. Das S, Suri RK. An anatomic and radiological study of an accessory mandibular foramen on the medial mandibular surface. *Folia Morphol*, 2004; 63:511-513.
30. Erdogmus S, Govsa F, Celik S. Anatomic position of the lingual nerve in the mandibular third molar region as potential risk factors for nerve palsy. *J Craniofac Surg*, 2008; 19:264-270.
31. Carter RB, Keen EN. The intramandibular course of the inferior alveolar nerve. *J Anat*, 1971; 108:443-440.
32. Ossenberg NS. Retromolar foramen: a mandibular variant important to dentistry. *Am J Phys Anthropol*, 1987; 72:119-128.
33. Ossenberg NS. Temporal crest canal: case report and statistics on a rare mandibular variant. *Oral Surg Oral Med Oral Pathol*, 1986; 62:10-12.
34. Kawai T, Asanmi R, Kamazawa Y, Sato I, Yosue T. Observation of the temporal crest canal in the mandibular ramus by cone beam computed tomography and macroscopical study. *Int J Comput Assist Radiol Surg*, 2013; (In Press)
35. Serres AERA. Essai sur l'anatomie et al physiologie des dents, ou novella théorie de la dentition. 1st ed. Paris: Chez Mequignon-Marvis, 1817.
36. Suazo GIC, Zavando MDA, Smith RL. Is the conduct of Serres an anatomical variation in adults? *Int J Morphol*, 2009; 27:43-47.
37. Narayana K, Prashanti N. Incidence of large accessory mandibular foramen in human mandibles. *Eur J Anat*, 2003; 7:139-141.
38. Sheikhi M, Badrian H, Ghorbanizadeh S. Bilateral bifid mandibular canal. *Dent Res J (Isfahan)*, 2012; 9:S132-S135.
39. Berberi A, Mani J, Nasseh I. Duplicated mandibular canal: report of a case. *Quintessence Int*, 1994; 25:277-281.
40. Claeyss V, Wackens G. Bifid mandibular canal: literature review and case report. *Dentomaxillofac Radiol*, 2005; 34:55-58.
41. Kiersch TA, Jordan JE. Duplication of the mandibular canal. *Oral Surg Oral Med Oral Pathol*, 1973; 35:133-134.
42. Rouas P, Nancy J, Bar D. Identification of double mandibular canals: literature review and three case reports with CT scans and cone beam CT. *Dentomaxillofac Radiol*, 2007; 36:34-38.
43. Barclay KJ. Enlarged mandibular canals. *Oral Surg*, 1971; 32:665-666.

44. Patterson JE, Funke FW. Bifid inferior alveolar canal. *Oral Surg Oral Med Oral Pathol*, 1973; 36:287-288.
45. Strider JW. Anomaly of the mandibular canal. *Oral Surg Oral Med Oral Pathol*, 1988; 65:376-377.
46. Mader CL, Kanzelman JL. Branching mandibular canal. *Oral Surg Oral Med Oral Pathol*, 1981; 51:332.
47. Manikandhan R, Mathew PC, Naveenkumar J, Anantanarayanan P. A rare variation in the course of the inferior alveolar nerve. *Int J Oral Maxillofac Surg*, 2010; 39:185-187.
48. Farman AG, Nortjé CJ. Panoramic radiographic appearance of the mandibular canal in health and in disease. *Panoramic Corporation*, 2002; 2:1-7.
49. Nortjé CJ, Farman AG, Grotepass FW. Variations in the normal anatomy of the inferior dental (mandibular) canal: a retrospective study of panoramic radiographs from 3612 routine dental patients. *Br J Oral Surg*, 1977; 15:55-63.
50. Fredekind RE, Schiff T, Valeriano V. Complete duplication of the mandibular canal: Case report. *Oral Surg Oral Med Oral Pathol Oral Radiol Endod*, 1995; 79:666.
51. Sanchis JM, Penarrocha M, Soler F. Bifid mandibular canal. *J Oral Maxillofac Surg*, 2003; 61:422-424.
52. Langlais RP, Broadus R, Glass BJ. Bifid mandibular canals in panoramic radiographs. *J Am Dent Assoc*, 1985; 110:923-926.
53. Tsikaras P, Paraskeuas G, Natsis K. Descriptive and applied anatomy. Volume II. The blood circulation system. Thessaloniki: University Studio Press, 2005; pp 82-102.
54. Lamas-Pelayo J, Peñarrocha-Diago M, Marti-Bowen E, Peñarrocha-Diago M. Intraoperative complications during oral implantology. *Med Oral Patol Oral Cir Bucal*, 2008; 13:239-243.
55. Ikeda K, Ho KC, Nowicki BH, Haughton VM. Multiplanar MR and anatomic study of the mandibular canal. *Am J Neuroradiol*, 1996; 17:579-584.
56. Pogrel MA, Dorfman D, Fallah H. The anatomic structure of the inferior alveolar neurovascular bundle in the third molar region. *J Oral Maxillofac Surg*, 2009; 67:2452-2454.
57. Kim ST, Hu KS, Song WC, et al. Location of the mandibular canal and the topography of its neurovascular structures. *J Craniofac Surg*, 2009; 20:936-939.
58. Deng W, Chen SL, Zhang ZW, Huang DY, Zhang X, Li X. High-resolution magnetic resonance imaging of the inferior alveolar nerve using 3-dimensional magnetization-prepared rapid gradient-echo sequence at 3.0T. *J Oral Maxillofac Surg*, 2008; 66:2621-2626.
59. Hur MS, Kim HC, Hu KS, Song WC, Koh KS, Kim HJ. Topography and spatial fascicular arrangement of the human inferior alveolar nerve. *Clin Implant Dent Res*, 2013; 15:88-95.
60. Buch HA, Agnihotri RG. A recurrent variant branch of the inferior alveolar nerve: is it unique? *Clin Anat*, 2012; 25:437-443.
61. Polland KE, Munro S, Reford G, Lockhart A, Logan G, Brocklebank L, McDonald SW. The mandibular canal of the edentulous jaw. *Clin Anat*, 2001; 14:445-452.
62. Kieser JA, Paulin M, Law B. Intrabony course of the inferior alveolar nerve in the edentulous mandible. *Clin Anat*, 2004; 17:107-111.
63. Kieser J, Kieser D, Hauman T. The course and distribution of the inferior alveolar nerve in the edentulous mandible. *J Craniofac Surg*, 2005; 16:6-9.
64. Rodella LF, Buffoli B, Labanca M, Rezzani R. A review of the mandibular and maxillary nerve supplies and their clinical relevance. *Arch Oral Biol*, 2012; 57:323-334.
65. Liu T, Xia B, Gu Z. Inferior alveolar canal course: a radiographic study. *Clin Oral Impl Res*, 2009; 20:1212-1218.
66. Miller CS, Nummikoski PV, Barnett DA, Langlais RP. Cross-sectional tomography. A diagnostic technique for determining the buccolingual relationship of impacted mandibular third molars and the inferior alveolar neurovascular bundle. *Oral Surg Oral Med Oral Pathol*, 1990; 70(6):791-797.
67. Naitoh M, Hiraiwa Y, Aimiya H, Arijji E. Observation of bifid mandibular canal using cone-beam computerized tomography. *Int J Oral Maxillofac Implants*, 2009; 24:155-159.
68. Naitoh M, Nakahara K, Suenaga Y, Gotoh K, Kondo S, Arijji E. Comparison between cone-beam and multislice computed tomography depicting mandibular neurovascular canal structures. *Oral Surg Oral Med Oral Pathol Oral Radiol Endod*, 2010; 109:e25-e31.
69. Orhan K, Aksoy S, Bilecenoglu B, Sakul BU, Paksoy CS. Evaluation of bifid mandibular canals with cone-beam computed tomography in a Turkish adult population: a retrospective study. *Surg Radiol Anat*, 2011; 33:501-507.
70. Orhan AI, Orhan K, Aksoy S, Ozgül O, Horasan S, Arslan A, Kocyigit D. Evaluation of Perimandibular Neurovascularization With Accessory Mental Foramina Using Cone-Beam Computed Tomography in Children. *J Craniofac Surg*, 2013; 24:e365-e369.
71. Naitoh M, Nakahara K, Hiraiwa Y, Aimiya H, Gotoh K, Arijji E. Observation of buccal foramen in mandibular body using cone-beam computed tomography *Okajimas Folia Anat*, 2009; 86:25-29.
72. Chavez-Lomeli ME, Mansilla Lory J, Pompa JA, Kjaer I. The human mandibular canal arises from three separate canals innervating different tooth groups. *J Dent Res*, 1996; 75:1540-1544.
73. Lew K, Townsend G. Failure to obtain adequate anaesthesia associated with a bifid mandibular canal: a case report. *Aust Dent J*, 2006; 51(1):86-90.
74. Wadhvani P, Mathur MR, Kohli M, Sahu R. Mandibular canal variant: a case report. *J Oral Pathol Med*, 2008; 37:122-124.

Correspondence and request for offprints to:

Apostolos N. Eliades
 Dion. Mylwna 13
 Thessaloniki 546 46, Greece
 E-mail: eliadesapostolos@gmail.com