

## SIMULTANEOUS FRACTURES OF SCAPHOID, TRIQUETRUM AND HAMATE

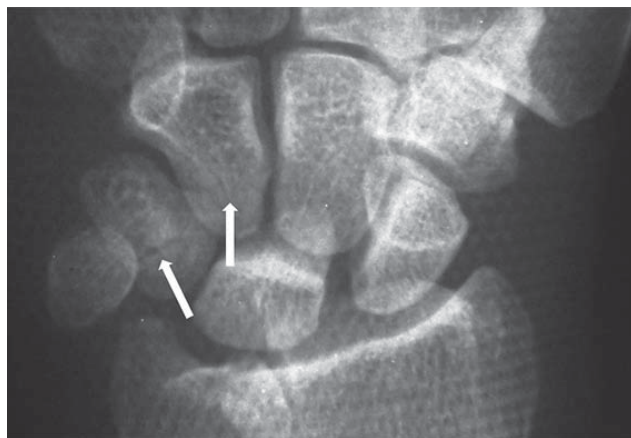
B. Baghianimoghadam<sup>1</sup> and F. Abolghasemzadeh-Ahangar<sup>2</sup>

<sup>1</sup>Department of Orthopedic Surgery, Babol University of Medical Sciences, Babol, Iran

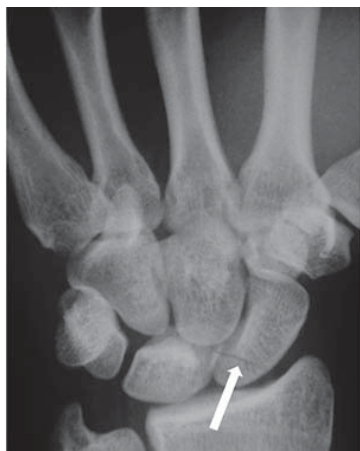<sup>2</sup>Department of Orthopedic surgery, Iran University of Medical Sciences, Tehran, Iran

### CASE PRESENTATION

In September of 2014, a 19-year-old man has presented in our hospital with wrist pain after a motor vehicle accident. During primary physical examination wrist motion was restricted at all directions due to pain and wrist was painful during palpation. A primary radiography was taken from wrist which only a scaphoid fracture was detected and due to swelling a volar splint including thumb was done for the patient (fig. 1). Another anteroposterior (AP) and lateral radiography in splint was ordered for the patient. In second film, a transverse fracture was detected in triquetrum and also hamate bones of the wrist (fig. 2).



**Fig. 1.** Primary radiography of wrist, Scaphoid fracture is apparent (the arrow)



**Fig. 2.** Secondary radiography of wrist, triquetrum and hamate fractures (the arrows)

## DISCUSSION

Scaphoid fracture is one of the most common injuries of carpal bones as it accounts about 69% of wrist injuries [1, 2, 3]. Triquetrum is the second popular carpal bone that might be injured [3, 4]; but hamate fractures are rare [3, 4, 5]. Simultaneous fractures of these bones are entirely rare and were not reported to be diagnosed in plane radiography. The important point of our patient was the primary radiograph, which was taken in AP view, and only revealed the scaphoid fracture while during second picture, which was done in radial deviation, the fractures of other two bones were shown. This showed the extent of possible misdiagnosis which could be done during assessment of wrist injuries and must be considered.

## REFERENCES

1. Haisman JM, Rohde RS, Weiland AJ. Acute fractures of the scaphoid. *J Bone Joint Surg Am.* 2006;88:2749-2758.
2. Sherman SB, Greenspan A. Osteonecrosis of the distal pole of the carpal scaphoid following fracture: a rare complication. *Skeletal Radiol.* 1983;9:189-191.
3. Hey HW, Chong AK, Murphy D. Prevalence of carpal fracture in Singapore. *J Hand Surg Am.* 2011 Feb;36(2):278-83.
4. Happel B, Breitenseher M, Trattnig S. Middle field and low field magnetic resonance tomography in wrist injuries. *Wien Med Wochenschr Suppl.* 2002;(113):41-2.
5. Christian Gaebler and Margaret M. McQueen. *Carpus fractures and dislocations in Rockwood and Green's fractures in adults.* Lippincott Williams & Wilkins; Seventh edition (2009)

### Corresponding author:

Behnam Baghianimoghadam  
Resident in orthopedic surgery  
Shahid Beheshti Hospital  
Babol University of Medical Sciences  
Keshvari Square, Babol, Iran  
e-mail: Behnam.Baghian@gmail.com