

A triad of exophthalmos, pretibial myxedema and acropachy in a patient with Graves' disease

Mirjana PARAVINA^{1*}, Milenko STANOJEVIĆ^{1, 2}, Mirjana VELIČKOVIĆ³,
Stanoje PETROVIĆ⁴, Mirjana. MILOSAVLJEVIĆ¹

¹Clinic of Skin and Venereal Diseases, Clinical Center of Niš, Serbia

²Center of Pathology, Clinical Center of Niš, Serbia

³Clinic of Endocrinology, Clinical Center of Niš, Serbia

*Correspondence: Mirjana Paravina, E-mail: mirjanaparavina@gmail.com

UDC 616.441-008.64-06:616.5



Abstract

A classical triad of extrathyroidal manifestations of Graves' disease known as EMO syndrome (exophthalmos, pretibial myxedema and osteoarthritis) is a rare condition. This paper presents a 39-year old male patient who underwent chemo- and radiation therapy of the supradiaphragmatic area due to Hodgkin's disease at the age of 35 and 36 leading to remission. Two years later, the patient developed general symptoms of Graves' disease and ophthalmopathy, with high thyroid stimulating hormone levels. Four months later, the patient presented with pretibial myxedema. Thirteen months after the onset of the disease, higher levels of thyroxine and decreased levels of thyroid stimulating hormone were registered. The diagnosis of EMO syndrome was confirmed by radiologic and histopathological analyses. Thiamazole and intralesional corticosteroid therapy were administered, resulting in euthyrosis and decrease of pretibial myxedema. The question is whether the autoimmune thyroid disease was triggered by the previous disease, or by chemo- and radiation therapy..

Key words

Graves' Disease; Exophthalmos; Myxedema; Osteoarthritis, Primary Hypertrophic; Syndrome

Back in 1786, Parry described the association between exophthalmos and goiter. Apart from these two manifestations, in 1935 Graves described thyrotoxicosis, and in 1840 Basedow described palpitations. Today, this disease is commonly called Graves', or Graves'-Basedow disease (1).

It is a chronic autoimmune disease characterized by diffuse goiter, hyperthyrosis, ophthalmopathy and dermatopathy (2). Hyperthyrosis affects 1-2% of women under the age of 40 years, whereas in men it is about ten times less common. It occurs in 0.3% of the general population, and out of this number, 4.3% have a subacute form of the disease (3).

Not all the abovementioned symptoms are always present, and others may occur as well. Thus, Thomas (in 1933) and Diamond (in 1959) described a triad of exophthalmos, pretibial myxedema and acral

osteopathy, while Braun-Falco and Petzoldt suggested the term EMO syndrome (exophthalmos, pretibial myxedema and hypertrophic osteoarthritis) in 1967 (4).

Out of extrathyroidal manifestations, ophthalmopathy, dermatopathy and acropachy are most common. Pretibial myxedema is rarely an initial symptom of Graves' disease (5). Ophthalmopathy affects about 30% of patients with Graves' disease, dermatopathy about 4%, and acropachy about 1% of patients (6). Symptoms of the disease occur independently of the production of thyroid hormones. Dermopathy was also described in euthyrosis (7, 8), and in hypothyrosis with subsequent hyperthyrosis (9). Cases of exophthalmos and myxedema in Hashimoto thyroiditis were reported as well (10), generally leading to hypothyrosis. There are opinions according to which all autoimmune thyroid

diseases are variants of one disease that has a predominant evolution in one direction or another (2).

Case report

This is a report of a 39-year old man, locksmith by profession, who underwent treatment of Hodgkin's disease at the age of 35 and 36 with ABVD-MOPP [adriamycin, bleomycin, vinblastine, dacarbazine – mustargen (mechlorethamine HCl), oncovin (vincristine), procarbazine, and prednisone] principle of chemotherapy (6 cycles), and 10 cycles of radiation therapy of the supradiaphragmatic area (mantle field), 20 sessions of TD=36 Gy (Grays). This treatment regimen showed to be effective in inducing stable remission.

Two years later, the patient presented with eyelid swelling, eyeball extrusion, fatigue, anxiety, insomnia, and normal appetite and body weight. Normal levels of triiodothyronine (T3) and thyroxine (T4) were found, with increased levels of the thyroid stimulating hormone (TSH). Four month later, red lumps appeared on the patient's shins and dorsal feet. Nine months after that, about 13 months from the onset of the disease, elevated levels of T4 and decreased levels of TSH were recorded. Tiamazol therapy was initiated, 10 mg per day. The patient visited a dermatologist two months later. Skin biopsy was collected from the lesion on the lower leg and a diagnosis of circumscribed pretibial myxedema was confirmed. Apart from exophthalmos and myxedema, the patient presented with lesions on distal fingers and clubbing (Hippocratic) nails. At that time, the patient lost 3kg.

Objective examination: the patient was of medium height and a little undernourished. He had bilateral exophthalmos with lid edema (Figure 1). His thyroid gland was firm and nodular on the left side. He also presented with asthenia of the thorax and a narrowed mid-vertebral space. Heart: the patient had extrasystolic arrhythmia, systolic heart murmur at the

Erb's point. Lungs and abdomen: without symptoms.

Dermatological examination showed lesions of the lower extremities (Figure 2) and dorsal feet (on the sites of old injury scars). The lesions were almost symmetrical, with clearly defined painless infiltrates and nodules of firm consistency. The skin showed mild erythema, uneven surface with orange peel appearance due to prominent hair follicles. The hair was rough and partly missing. The small hand joints were painful to touch, with drumstick fingers and watch glass nails (Figure 3.).

Laboratory analyses: at the onset of the disease the following results were established: T3: 1,9 mmol/l (normally 1,2 – 3,0); T4: 101,0 mmol/l (normally 55.0 – 165.0); TSH: 9,1 U/l (normally 0.17 – 4.05). Thirteen months after onset: T3: 3.2 mmol/l, T4: 257 mmol/l, TSH: 0,14 U/l. After two, three and four months, levels of T3, T4, TSH, thyroglobulin and anti-thyroglobulin antibodies were normal. Other test results were in the normal range.

Ophthalmologic findings: exophthalmos and subacute conjunctivitis.

Radiological findings of the hands and long bones: the x-ray showed acropachy with hyperostosis of the diaphyseal portion of phalanges of the index and middle fingers (Figure 4), the rest without symptoms. Ultrasound of the thyroid gland: the thyroid gland was of normal size (isthmus 3mm, the right lobe 19x21, the left lobe 17x21), of hypoechogenic and nonhomogenous structure, without visible nodules. Orbital computed tomography: the orbital bone was of normal diameter, contours, without morphologic structural alterations. Both bulbs were of normal position and structure. The retrobulbar spaces were unremarkable, and both optic nerves normal. Hypophyseal computed tomography: *sella turcica* was of normal diameter with normal bone structures and without densimetric alterations.

Histopathological findings: the corneal layer and epidermis were without prominent changes

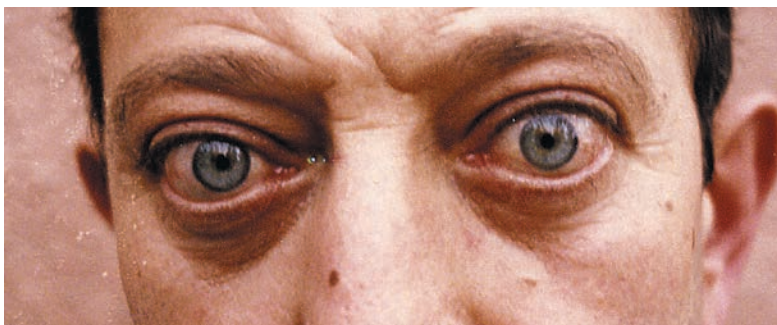

Figure 1. Exophthalmos

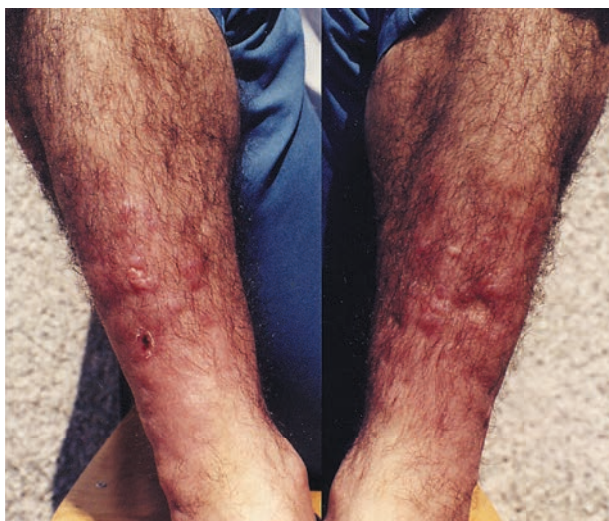

Figure 2. Pretibial myxedema: bilateral, almost symmetrical, clearly defined painless infiltrates and nodules of firm consistency, showing mild erythema and uneven surface with orange peel appearance

(Figure 5). The dermis layer was thickened and collagen fiber networks were cross-linked. Fibroblasts were present, within normal levels, some star-shaped. Mucin dermal deposits were scarce in the papillary and more prominent in the rest of the dermis, presenting between abundant collagen fibers.

Therapy

Favistan® (tiamazol) tablets of 20mg were used, 2 x 1, later 2 x ½. The treatment with topical corticosteroids showed no visible improvement. Intralesional

hydrocortisone injections caused reduction of pretibial changes to some extent. Exophthalmos and acropachy remained unchanged. The patient's general condition was good all the time.

Discussion

The cause of Graves' disease is unknown. A certain genetic predisposition is indicated by several family members suffering from the disease and its association with other autoimmune diseases, for example endocrine diseases (2).

Apart from heritage, other risk factors are evident as etiologic factors of Graves' disease: smoking, immunosuppression, stress, some medications (for example amiodarone, interferon, lithium carbonate), iodine contrasts, radiation therapy of the neck, viral and bacterial infections, iodine insufficiency in the diet (4). Hyperthyroidism in Graves' disease is due to the binding of stimulatory autoantibodies to the TSH receptor (TSHr) on thyroid follicular cells. The stimulation of this G protein coupled receptor by autoantibodies leads to excessive and uncontrolled production of thyroid hormone (11).

Development of extrathyroidal manifestations, such as ophthalmopathy and pretibial myxedema, is associated with positive feedback mechanisms including mechanical (trauma/pressure), immune (accumulation of immune cells, inflammatory cytokines, increased expression of TSHr) and cellular processes (adipogenesis, increased production of glycosaminoglycans/prostaglandin E₂) (11). "A subclinical systemic inflammatory process might develop in Graves' disease as activated T cells and

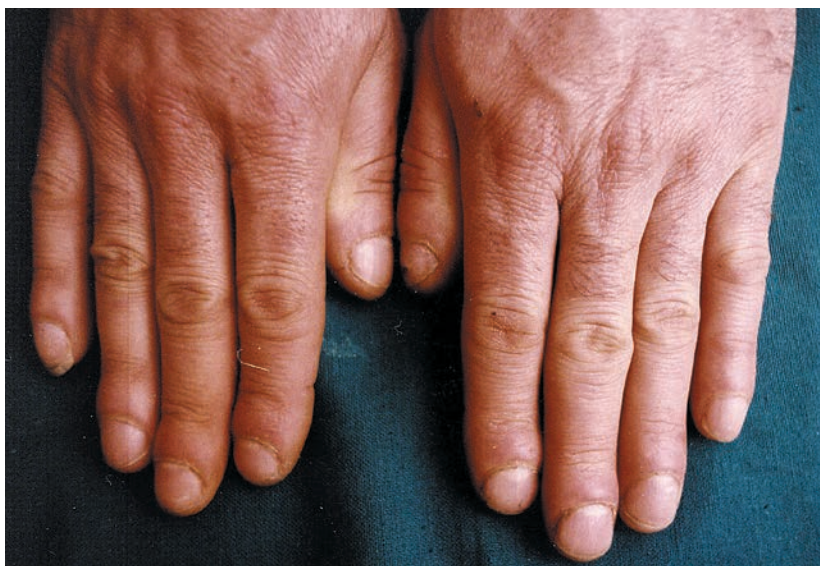

Figure 3. Clubbing of the fingernails: drumstick fingers and watch glass nails

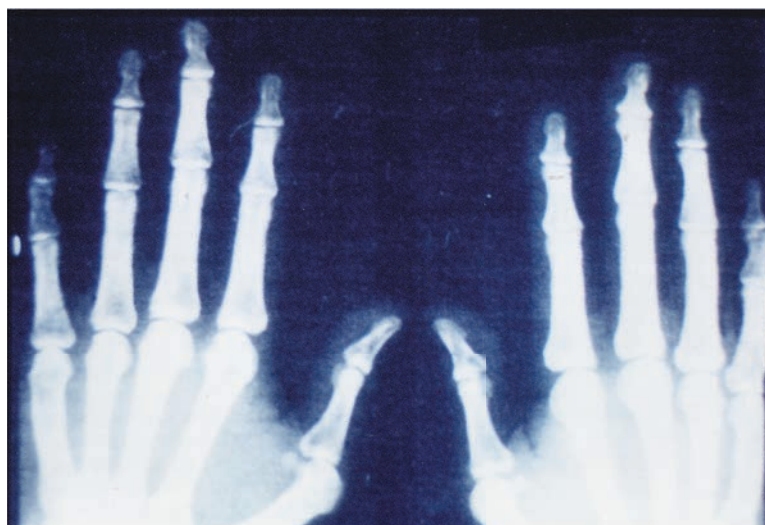


Figure 4. X-ray of the hands: hyperostosis of the diaphyseal portion of phalanges of the index and middle fingers

IgG recognize TSHr expressed in connective tissues. More significant involvement of the orbits and lower extremities might result from the accumulation of edema and inflammatory cytokines in these particular regions. This pooling of inflammatory mediators might be facilitated by unique anatomical and mechanical features of these regions. As fibroblasts from these sites appear to be especially sensitive to cytokine stimulation of metabolic processes, the local production of glycosaminoglycans (GAG) and inflammatory mediators would increase. In addition, cytokines or other local factors might stimulate the differentiation of orbital precursor cells into mature adipocytes with

increased expression of TSHr. This increase in target antigen expression might cause further propagation of the immunological process in the orbit and pretibial skin. Increased orbital fat and GAG production would probably cause further impairment of venous and lymphatic drainage from the orbits and lower extremities, resulting in progression of Graves' ophthalmopathy (GO) and pretibial dermatopathy (PTD)" (11).

Ophthalmopathy is the first extrathyroidal manifestation of Graves' disease. In a study including 150 consecutive patients with pretibial myxedema, only one patient presented without ophthalmopathy (12). The clinical picture of this manifestation is characterized by proptosis, conjunctival injection, chemosis, diplopia, corneal ulcerations, and extreme cases of blindness due to optic nerve compression (13). Anti-TSHr antibodies correlate with clinical features of Graves' ophthalmopathy. Anti-TSHr antibodies and orbital TSHr levels are clearly associated with Graves' ophthalmopathy. The next extrathyroidal manifestation is pretibial myxedema or thyroidal dermatopathy, which includes accumulation of GAG (glycosaminoglycans) in the dermis and subcutaneous tissue (15). It accounts for 10-12% of patients with Graves' ophthalmopathy (12). Early lesions are bilateral, asymmetrical, with firm non-pitting edema, nodules or skin-colored, pink or purple papules. Late lesions develop by confluence of early lesions, symmetrically covering the pretibial region and may result in grotesque involvement of shins and feet. The skin is of orange-peel texture, sometimes even varicose. Depending on the clinical picture, several forms of dermatopathy are described: nodular, diffuse and elephantiac (17).

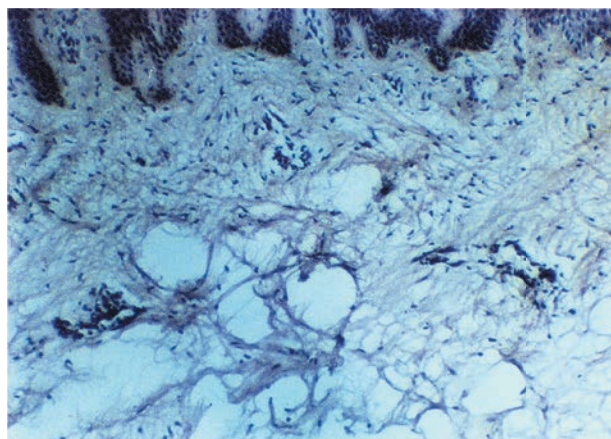


Figure 5. Histopathological finding showing thickened dermis with cross-linked collagen fiber networks and scarce mucin deposits in the papillary dermis and more prominent deposits in the rest of the dermis, presenting between abundant collagen fibers (HE staining x 100)

Results of a study including 178 patients with thyroidal dermopathy showed that: only 3% of patients provided no anamnestic data and were without signs of ophthalmopathy; mild ophthalmopathy was recorded in 41% of patients, moderate in 31% and severe in 15.2%; optic neuropathy was established in 9.4% of patients with dermopathy (18). In the same study, 93.3% of patients suffered from pretibial dermopathy, 3.9% from pretibial and foot dermopathy, and 1.19% had pretibial and upper extremity dermopathy. Dermopathy manifested as non-pitting edema in 43.3% of patients, plaque dermopathy in 27.0%, nodular in 18.52% and elephantiasis in 2.8% (18). Although much less commonly, dermopathy may affect hands, arms, shoulders, head and neck, as well as sites of trauma, surgery, scars or skin grafts (5, 19, 20).

The thyroid acropachy is a rare extrathyroidal manifestation (2) with prevalence of 0.8 – 1.0%. It is a marker for severe thyroid-associated autoimmune process and ophthalmopathy (21).

The most common manifestation of acropachy is clubbing of fingers and toenails (18) - so called Hippocratic nails (1). It is characterized by clubbing and swelling of fingers, with periosteal reaction on distal bones (9). Radiography shows fusiform finger swelling and subperiosteal formation on metacarpal bones, proximal and middle phalanx and metatarsal bones and proximal phalanx of the toes (18).

In the diagnosis of Graves' disease, it is very important to control T3, T4 and TSH. Sometimes TSH is too low to be measured (2).

Histopathological changes are also characteristic and include mucin deposits, especially in the lower dermis.

The first step in the treatment of Graves' disease is elimination of risk factors, if possible. Obesity is an important risk for the development of venous stasis and edema in the lower extremities, affecting the severity of pretibial myxedema (9). Smoking has also been established as a marker of severity of autoimmune manifestations in Graves' disease (22).

Thyroid dysfunction therapy is done by endocrinologists and surgeons. It includes thyreosuppressants, medications for hormone suppression, and two forms of ablation therapy: surgical and using radioactive iodine (2).

In order to prevent extrathyroidal manifestations that may develop in some patients after therapy by radioactive iodine, concomitant corticosteroid therapy is applied (9). Apart from systemic corticosteroids, systemic immunomodulators are also used in the treatment of ophthalmopathy (cyclosporine and

intravenous immunoglobulins); plasmapheresis and somastatin analogues such as octreotide (insulin-like growth factor type-1-antagonist); systemic immunomodulators are used for regression of skin lesions (18); radiation therapy is also used, while surgical orbital decompression is used in the correction of exophthalmos, and surgery of extraocular muscles in the correction of diplopia (23).

Potent topical corticosteroids under occlusion may be used in the treatment of mild forms of pretibial myxedema. Oral use of pentoxifylline and topical use of clobetasol propionate are recommended for the improvement of myxedema and ophthalmopathy (24). In severe forms of myxedema, intralesional corticosteroids are used, which had positive effects in our patient; compression and complete decongestive physiotherapy are also used (25) as well as CO₂ laser (7); surgical ablation and intravenous immunoglobulins are used in severe cases (26). In severe refractory pretibial myxedema, a combination of surgery and octreotide is performed (27), or intralesional octreotide (28).

Anyhow, the course of the disease does not only depend on applied medications, but also on the immune status of patients. Long-term remissions are possible, and in mild cases complete regressions as well.

Conclusion

This is a case report of a patient who developed exophthalmos, pretibial myxedema and hyperthyreosis after chemo- and radiation therapy of the supradiaphragmatic area due to Hodgkin's disease. Osteoarthropathy developed in the end, causing EMO syndrome. The applied therapy induced euthyreosis and regression of myxedema, but did not affect ophthalmopathy and acropachy.

Abbreviations

EMO syndrome - The combination of exophthalmos, pretibial myxoedema and hypertrophic osteoarthropathy

Gy - Gray

T3 - Thyronine

T4 - Thyroxine

TSH - Thyroid-stimulating hormone

TSHr - Thyroid-stimulating hormone receptor

GAG - glycosaminoglycans

GO - Graves' ophthalmopathy

PTD - Pretibial dermatopathy

References

1. Firkin BG, Whitworth JA. Dictionary of medical eponyms. Basel: Roche; 1996.
2. Kocić R, Radenković S. Bolesti štitne žlezde [Thyroid disorders]. U: Ilić S, ur. Interna medicina [In: Ilić S, ed. Internal Medicine]. Niš: Medicinski fakultet Niš; 2009. p. 307-19. (Serbian).
3. Micić D. Oboljenja štitne žlezde [Thyroid disorders]. U: Klinički centar Srbije, ur. Enciklopedija zdravlja [In Clinical center of Serbia, ed. Encyclopedia of health]. Beograd: Press; 2012. Volume 26.p. 1-4. (Serbian).
4. Braun-Falco O, Petzold D. E.M.O. syndrome. Exophthalmos-circumscribed pretibial myxedema-hypertrophic osteoarthropathy. Münchn Med Wochenschr 1967;79:1523-9.
5. Georgala S, Katoulis AC, Georgala C, Katoulis EC, Hatzilou E, Stavrianeas NG. Pretibial myxedema as the initial manifestation of Graves' disease. J Eur Acad Dermatol Venereol 2002;16: 380-3.
6. Anderson CK, Miller F. Triad of exophthalmos, pretibial myxedema, and acropachy in a patient with Graves' disease. J Am Acad Dermatol 2003; 48 (6): 970-2.
7. Castineiras I, Del Pozo J, Robles O. Euthyroid nodular pretibial mucinosis: palliative treatment with carbon dioxide laser. Dermatol Surg 2009;35: 719-21.
8. Şenel E, Güleç AT. Euthyroid pretibial myxedema and EMO syndrome. Acta Dermatovenereol Alp Panonica Adriat 2009;18(1):21-3.
9. Fatourehchi V. Pretibial myxedema. Pathophysiology and treatment options. Am J Clin Dermatol 2005;6(5):295-309.
10. Cannavò SP, Borgia F, Vaccaro M, Guameri F, Magliolo E, Guarneri B. Pretibial myxedema associated with Hashimoto's thyroiditis. J Eur Acad Dermatol Venereol 2002;16:625-7.
11. Bahn RS. Pathophysiology of Graves' ophthalmopathy: The cycle of Disease. J Clin Endocrinol Metab 2003;88(5):1939-45.
12. Fatourehchi V, Pajouhi M, Fransway A. Dermopathy of Graves' disease (pretibial myxedema). Review of 150 cases. Medicine 1994;73:1-7.
13. Ludgate M, Baker G. Unlocking the immunological mechanisms of orbital inflammation in thyroid eye disease. Clin Exp Immunol 2002;127:193-8.
14. Heufelder AE, Weetman AP, Ludgate M, Bahn RS. Pathogenesis of Graves' ophthalmopathy. In: Prummel MF, Wirsinga WM, Mourits MP, eds. Recent developments in Graves' ophthalmopathy. Dordrecht: Kluwer Academic Publishers; 2000. p. 15-37.
15. Daumerie C, Ludgate M, Costagliola S, Many MC. Evidence for thyrotropin receptor immunoreactivity in pretibial connective tissue from patients with thyroid-associated dermopathy. Eur J Endocrinol 2002;146:35-8.
16. Wolf K, Johnson RA, Suurmond D. Fitzpatrick' color atlas and synopsis of clinical dermatology. 5th ed. New York: McGraw-Hill Professional; 2005. p 443-4.
17. Jolles S, Hughes J. Use of IIGIV in the treatment of atopic dermatitis, urticaria, scleromyxedema, pyoderma gangrenosum, psoriasis and pretibial myxedema. Int Immunopharmacol 2006;6:579-91.
18. Schwartz KM, Fatourehchi V, Ahmed DDF, Pond GR. Dermopathy of Graves' disease (Pretibial myxedema): long-term outcome. J Clin Endocrinol Metab 2002;87(29):438-46.
19. Cho S, Choi J-H, Sung K-J, Moon KC, Koh J-K. Graves's disease presenting as elephantiasic pretibial myxedema and nodules of the hands. Int J Dermatol 2001;40:276-7.
20. Schwartz KM, Ahmed DDF, Ahmed I, Fatourehchi V. Development of localized myxedema in skin graft. Int J Dermatol 2002;41:401-3.
21. Fatourehchi V, Bartley GB, Eghbali-Fatourehchi GZ, Powell CC, Ahmed DD, Garrity JA. Graves' dermopathy and acropachy are markers of severe Graves's ophthalmopathy. Thyroid 2003;13(12):1141-4.
22. Mack WP, Stasior GO, Cao JH, Stasior OG, Smith TJ. The effect of cigarette smoke constituents on the expression of HLA-DR in orbital fibroblasts derived from patients with Graves' ophthalmopathy. Ophthal Plast Reconstr Surg 1999;15(4):260-71.
23. Weetman AP. Graves' disease. N Engl J Med 2000;26:1236-48.
24. Pineda AMM, Tianco EAV, Tan JB, Casintahan FA, Beloso MB. Oral pentoxifylline and topical clobetasol propionate ointment in the treatment of pretibial myxedema, with concomitant improvement of Graves' ophthalmopathy. J Eur Acad Dermatol Venereol 2007;21:1441-2.
25. Susser WS, Heermans AG, Chapman MS, Baughman RD. Elephantiasic pretibial myxedema: A novel treatment for an uncommon disorder. J Am Acad Dermatol 2002;46:723-6.
26. Terheyden P, Kahaly GJ, Zillikens D, Brücher E-B. Lack of response of elephantiasic pretibial myxoedema to treatment with high-dose intravenous immunoglobulins. Clin Exp Dermatol 2003;28:224-6.
27. Felton J, Derrick EK, Price ML. Successful combine surgical and octreotide treatment of severe pretibial myxoedema reviewed after 9 years. Br J Dermatol 2003;148:825-6.
28. Shinohara M, Hamasaky Y, Katayama J. Refractory pretibial myxedema with response to intralesional insulin-like growth factor 1 antagonist (octreotide): downregulation of hyaluronic acid production by the lesional fibroblasts. Br J Dermatol 2000;143:1083-6.

Egzoftalmus, pretibijalni miksedem i akropatija – trijada prisutna kod obolelog od Grejsove bolesti

Sažetak

Uvod: Grejvsova bolest je hronična autoimunska bolest koju karakteriše difuzna struma sa hipertireozom, oftalmopatijom i dermopatijom. Hipertireoza se javlja kod 1-2% žena mlađih od 40 godina, dok je kod muškaraca ređa za oko deset puta. Javlja se kod 0,3% pripadnika opšte populacije, a čak 4,3% ima supkliničku formu bolesti. Od ekstratiroidnih manifestacija najčešće se prvo javlja oftalmopatija, zatim dermopatija, pa akropatija. Retko

pretibijalni miksedem može da bude inicijalni simptom Grejvsove bolesti. Oftalmopatija se javlja kod 30% bolesnika sa Grejvsom bolešću, dermopatija kod 4%, a akropatija kod 1% bolesnika. Simptomi bolesti se javljaju nezavisno od produkcije tiroidnih hormona. Kompletna trijada ekstratiroidnih manifestacija pod imenom EMO sindrom (egzoftalmus, pretibijalni miksedem, osteoartropatija) u sklopu Grejvsove bolesti retko se registruje.

Prikaz slučaja: U ovom radu prikazan je bolesnik star 39 godina koji je u 35. i 36. godini lečen citostaticima i zračnom terapijom (supradijafragmalna regija) zbog Hočkinove bolesti i nakon toga doveden u stanje remisije. Dve godine kasnije javili su se opšti simptomi Grejvsove bolesti i oftalmopatija. Tada su registrovane povišene vrednosti tireostimulišućeg hormona TSH. Četiri meseca kasnije nastao je i pretibijalni miksedem. Trinaest meseci od početka bolesti registrovane su i povišene vrednosti tiroksina (T4) i snižene vrednosti TSH. Dijagnoza EMO sindroma je potvrđena radiološkim i patohistološkim analizama. Ordinirana je peroralna terapija tiamazol tabletama, uz intraleziono injiciranje kortikosteroida, što je dovelo do eutiroidnog stanja i smanjenja pretibijalnog miksedema.

Diskusija: Postavlja se pitanje da li je za autoimunu bolest štitne žlezde faktor okidač bila prethodno postojeća Hočkinova bolest ili tada primenjena terapija. Uzrok Grejvsove bolesti je nepoznat. Postoji izvesna genetska predispozicija, što potvrđuje pojavljiva bolesti kod više članova pojedinih porodica i udruženost sa drugim autoimunim bolestima, npr. endokrinim. Pored genetskih činilaca, faktori rizika za nastanak Grejvsove bolesti su pušenje, imunosupresija, psihički stres, lekovi (npr. amiodaron, interferon, litijum-karbonat), kontrastna sredstva na bazi joda, zračna terapija vratne regije, virusne i bakterijske infekcije, nedostatak joda u ishrani.

Oftalmopatija predstavlja ekstratiroidnu manifestaciju Grejvsove bolesti. Za kliničku sliku ove manifestacije karakteristični su: proptiza, pojačana konjunktivalna injekcija i konjunktivalni edem (*chemosis*), diplopija, kornealna ulceracija, a u ekstremnim slučajevima gubitak vida zbog kompresije očnog živca.

Druga ekstratiroidna manifestacija je pretibijalni miksedem ili tiroidna dermopatija, koju karakteriše akumulacija glikozaminoglikana (GAG) u dermisu i supkutnom tkivu. Prisutna je kod 10–12% bolesnika sa Grejvsom oftalmopatijom. Rane lezije su bilateralne, asimetrične, čvrste – u vidu napetog edema, nodusa ili plakova ružičaste, boje kože ili ljubičaste. Kasne lezije nastaju konfluencijom ranih lezija, simetrično zahvataju pretibijalnu regiju i mogu rezultirati grotexnim zahvatanjem potkolenica i stopala. Koža ima izgled „pomorandžine kore“, može biti čak i verukozna. U zavisnosti od kliničke prezentacije, u literaturi se opisuje nekoliko različitih formi dermopatije: nodularna, difuzna i elefantijazna. Iako znatno ređe, dermopatija može biti lokalizovana i na šakama, nadlakticama, ramenima, glavi i vratu, na mestima traume, operacije, ožiljaka, kao i na koži transplantiranih graftova.

Tiroidna akropatija je retka kasna ekstratiroidna manifestacija, sa prevalencijom 0,8–1 % i predstavlja marker za težinu autoimunog procesa i marker za težinu udružene oftalmopatije.

Najčešća manifestacija akropatije jeste pojava maljičastih prstiju šaka i stopala: Hipokratovi prsti. Koža prstiju može biti otečena i zategnuta, sa prisutnom periostalnom reakcijom na distalnim kostima. Radiografski se konstatuje fuziformni otok tkiva prstiju i subperiostalna formacija na metakarpalnim kostima, proksimalnim i srednjim falangama prstiju ruku i metatarzalnim kostima i proksimalnim falangama prstiju nogu.

U dijagnostici Grejvsove bolesti vrlo važno je kontrolisanje trijodtironina (T3), naročito T4 hormona i TSH. Neka je TSH izrazito nizak i nemerljiv.

Patohistološke promene su takođe karakteristične i podrazumevaju nakupljanje depozita mucina, naročito u donjem dermisu.

Lečenje tiroidne disfunkcije spada u domen endokrinologa i hirurga: podrazumeva primenu tireosupresiva, lekova za smanjenje produkcije hormona i dva vida ablativne terapije, hirurške i zasnovane na primeni radioaktivnog joda.

U lečenju oftalmopatije, pored sistemskih kortikosteroida, koriste se i sistemski imunomodulatori (ciklosporin i intravenski imunoglobulini), plazmafereza i oktreotid (eng. *octreotide: insulin-like growth factor type 1- antagonist*). Takođe se primenjuju: radioterapija, hirurška dekompresija orbite, koja koriguje egzoftalmus, i hirurgija ekstraokularnih mišića koja koriguje diplopiju.

U lečenju lakših oblika pretibijalnog miksedema primenjuju se potentni lokalni kortikosteroidi pod okluzijom. Kod izrazitijih formi miksedema mogu se primeniti: kortikosteroidi intraleziono, što je dalo pozitivne efekte i kod našeg bolesnika; takođe se koristi kompresivna i kompletna dekongestivna fizioterapija; CO₂ laser; a u težim slučajevima i hirurška ablacija i intravenski imunoglobulini. U svakom slučaju, tok bolesti zavisi ne samo od primenjenog leka nego i od imenskog statusa obolelog. Moguće su dugotrajne remisije, a kod lakših slučajeva čak i kompletna regresija promena.

Zaključak: Prikazan je bolesnik kod koga je, posle primene citostatika i zračenja supradijafragmalne regije sa ciljem lečenja Hočkinove bolesti, nastao egzoftalmus, zatim pretibijalni miksedem, a onda je registrovana hipertireoza. Osteoartropatija je nastala poslednja u sklopu EMO sindroma. Primenjena terapija je dovela do eutireoze i smanjenja miksedema bez uticaja na oftalmopatiju i akropatiju.

Ključne reči

Gravesova bolest; Exophthalmos; Miksedem; Primarna hipertrofna osteoartropatija; Sindrom