Serbian Journal of Dermatology and Venereology 2010; 2 (2): 45-53
DOI: 10.2478/v10249-011-0021-0

The role of histopathology in the diagnosis of dermatophytoses

Đorđi Gocev, Katerina Damevska

University Clinic of Dermatology, Faculty of Medicine, University "Ss Kiril and Metodij", Skopje, Republic of Macedonia
Corresponding author: Prim. Dr. Đorđi Gocev, E-mail: Dr.Gocev@t-home.mk

UDC 616.5-002.828-076.1

Abstract

Histopathological analysis is not a routine procedure for diagnosing fungal skin infections. In the histopathological specimens, fungi are visible only when using special stain such as *periodic acid–Schiff* (PAS). However, histopathological analysis may not be performed in small laboratories. Histopathological characteristics of fungal skin infections are not specific. In all skin biopsy cases, obtained without clinical suspicion of fungal infection, the knowledge of certain, most frequent histopathological reaction patterns, as well as specific histopathological indicators (a diagnostic histopathological "clue"), of certain superficial mycoses e.g., dermatophytoses, may raise a suspicion of fungal infection and warrant a fungal-specific staining. A retrospective analysis of all PAS-stained sections was carried out. All PAS-positive biopsy specimens were assessed for clinical features, histopathological patterns of skin reactions, and presence of histopathological indicators. Our results have shown that out of the total of 361 PAS-stained sections, fungal hyphae were identified in 12 (3.3%) specimens. In 5 (1.4%) cases, the diagnosis of fungal infection was suspected on clinical grounds, while in 7 (1.9%) cases detection of fungi was an unexpected finding. The most frequent type of histopathological pattern was spongiotic, and the most frequent histopathological indicator was the presence of neutrophils within the epidermis. Our results confirm that dermatophytoses may present with clinical and histological non-specific findings. PAS staining represents a relatively cheap and simple fungal-specific staining. It has been suggested that it not only confirms that the selected material is actually invaded, but also reduces the number of false-negative direct reports, where fungi are cultured from a microscopically negative specimen. Apart from a small percentage of positive findings, our results justify the need for routine PAS staining of all clinically and histologically non-specific inflammatory skin conditions.

Fungal infections account for 3-5% of all consultations in dermatology practice (1). Cutaneous manifestations of superficial fungal infections are rather common. The most frequent causative agents are dermatophytes, while less common are those that cause deep skin infections or primary systemic infections with a secondary skin involvement. The diagnosis is usually strongly suspected on clinical grounds, and supported by both direct microscopic findings, which is easily carried out by clearing the specimen in 10-30% potassium hydroxide solution, and by culture in selective media. Less commonly, fluorescent microscopy of stained specimens, Wood's light, histopathological analysis, cutaneous and immunological tests, as well as PCR are used.

Histopathological analysis is not the routine procedure for diagnosing fungal skin infections. Histopathological analysis of specimens is required in all cases in which deep and/or superficial fungal infection, e.g., dermatophytosis or tinea with negative direct microscopic and culture results, is suspected (1). Moreover, histopathology is the most sensitive technique for diagnosing onychomycoses (2).

Dermatophytes cannot be easily identified with routine histopathological stains, such as hematoxylin-eosin (H&E), even by experienced histopathologists, because fungal elements, the hyphae, are stained pale blue (Figure 1). If stained with H&E, hyphae can be detected in less than 60% of cases (3). Visualization of fungal elements in histological slides is facilitated with fungal-specific stainings, such as periodic acid–Schiff (PAS) and PAS-d (PAS-diastase) which stain hyphae red (Figure 2), as well as Grocott's

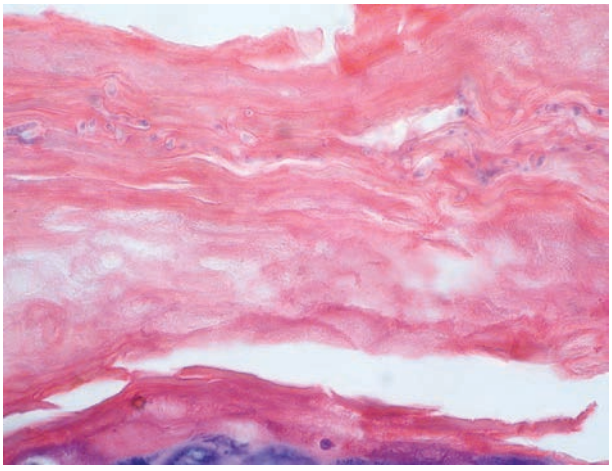

Figure 1. H&E-stained section showing pale blue stained hyphae in the corneal layer (hematoxylin and eosin, x 400)

methenamine silver (GMS) that stains them black (1).

Only on rare occasions, the skin biopsy is obtained and sent for dermatopathology evaluation, in order to confirm clinically diagnosed dermatomycosis. More often, the diagnosis of fungal skin infections is only one differential diagnosis among the others (e.g., psoriasis, parapsoriasis, eczema, palmoplantar pustulosis, annular erythema, granuloma annulare, etc.). According to many reports, the diagnosis of dermatophytic infection can be established histopathologically even in cases where it is not clinically suspected (4). Beside the atypical clinical appearance (Figure 3), dermatophyte infections may also exhibit atypical histological features. Cases of bullous (5), acantholytic (6), purpuric (7) reaction pattern, or even cases of eosinophilic folliculitis (8) have been described.

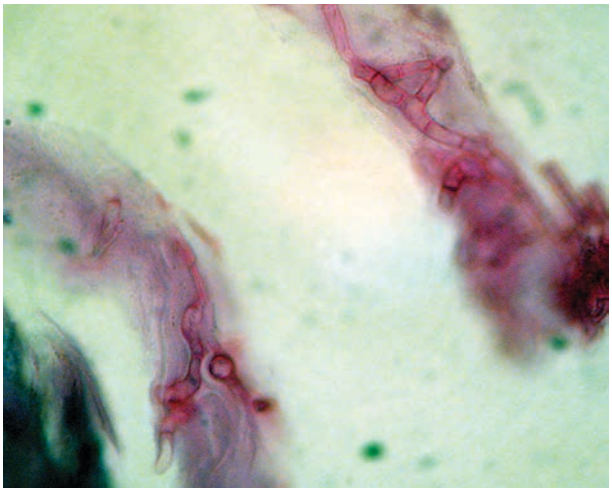

Figure 2. PAS-stained section showing red stained hyphae in the corneal layer (periodic-acid-Shiff, x 800)

If dermatophyte infection (dermatophytosis), represents one among other clinically established diagnoses, then presence of fungal elements can be easily confirmed by biopsy, since slides will be stained not only with a H&E, but with a fungal-specific stains as well. In cases where skin biopsies were obtained without clinical suspicion of dermatophytosis, the most frequent patterns of histopathological reactions in dermatophytoses, as well as specific histopathological "indicators" (particularly important in establishing diagnosis of superficial fungal skin infections), can lead to suspicion of fungal infection and additional fungal staining. The presence of hyphae in slides is the only histopathological (HP) proof of dermatophytosis (1).

By the definition, the pattern of histological reactions is a combination of histological findings that are helpful in reducing the list of possible histological differential diagnoses, while a histologicical indicator – "diagnostic clue" is a subtle histologic finding that significantly leads to specific histological diagnosis. However, histologic patterns and indicators are not sufficient

Figure 3. Tinea incognita

to establish the diagnosis of dermatophytosis, but they suggest taking further steps, such as special staining for fungal elements in order to confirm the diagnosis.

The most frequent histopathological reaction patterns of dermatophytoses

The presence of fungal elements in the epidermis induces tissue inflammatory reactions which vary from almost undetectable responses to severe reactions. The histologic pattern reactions highly depend on the fungi, immune status of the host and local factors (1).

1. Superficial perivascular dermatitis/ perivasculitis is characterized by sparse perivascular infiltrates in the superficial dermis, and minimal or absent epidermal changes (discrete hyperkeratosis and intercellular edema). This finding is not specific, and it can be found in many other dermatological conditions. However, basket weave hyperkeratosis may indicate a fungal infection. Hyphae can be seen within the corneal layer on the H&E stained sections.

2. Spongiotic/eczematous reaction pattern is the most frequent finding in acute inflammatory skin conditions. This pattern shows perivascular, predominantly lymphocytic infiltrates in the upper dermis associated with prominent epidermal intercellular edema, hyperkeratosis and focal parakeratosis. If present, fungal elements are usually found close to the parakeratotic foci, making their visualization on H&E stained slides extremely difficult. This pattern is the most common finding in dermatophytoses.

3. Psoriasiform reaction pattern is characterized by psoriasiform epidermal hyperplasia, hyperkeratosis and parakeratosis. The existence of neutrophils in the spinous and corneal layers with formation of small "abscesses" is almost identical with the so called eruptive psoriasis. However, coexistence of parakeratosis and neutrophils can make visualization of hyphae and spores almost impossible, so PAS staining procedure is warranted.

4. Folliculitis and perifolliculitis reaction patterns are characterized by perifollicular inflammation of various intensity, and mononuclear as well as mixed cellular infiltrates. Spongiotic follicular epithelia with lymphocyte and neutrophil migration may be seen. PAS staining is of great importance in differentiating trichomycoses from folliculitis and perifolliculitis of other etiology (Figure 4). In slides with dense inflammatory infiltrates and follicle destruction, it is very difficult to identify fungal elements even in PAS-stained sections.

5. Granulomatous reaction pattern is usually associated with deep fungal infections. Dermal granulomatous inflammatory infiltrate finding requires additional PAS staining regardless of clinical diagnosis (1).

Histopathologic features ("clues") of dermatophytoses

H&E stained slides provide few valid signs that not only suggest the diagnosis of dermatophytosis, but also show the location where fungal elements should be sought.

1. Neutrophils in the epidermis are directly related to the presence of fungi in the epidermis, since fungi elicit neutrophil chemotaxis and migration into the epidermis (9). According to Ackerman, the presence of neutrophils and/or their fragments in the corneal layer, in association

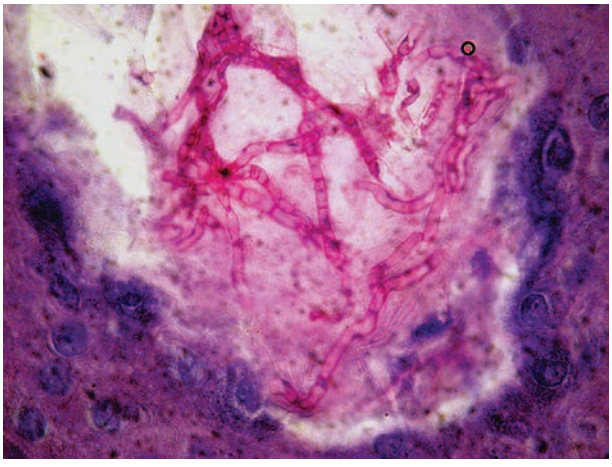

Figure 4. PAS-stained section showing hyphae in the hair follicle (periodic-acid-Shiff, x 400)

with compact orthokeratosis and/or parakeratosis, should be considered a positive symptom of dermatophytosis. Since 1986, it has been termed the diagnostic "clue to dermatophytoses" (10) (Figure 5).

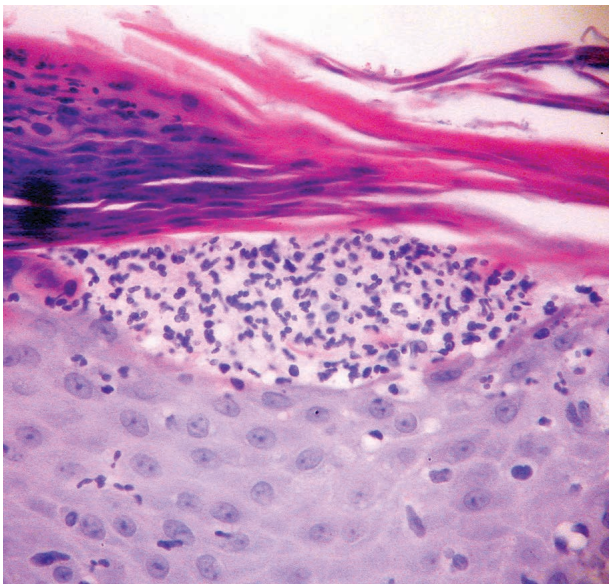

Figure 5. H&E-stained section showing neutrophils in the epidermis layer (hematoxylin and eosin, x 800)

2." Sandwich" sign results from the presence of fungal hyphae between two zones of cornified cells. Superficially, there is a orthokeratotic lamella, partially or completely parakeratotic lamellae beneath, with formation of fissure in between (12). These histological findings strongly support the need for special staining. If present, fungal elements can be seen within the fissure – in the "sandwich", between the two morphologically different lamellae of the corneal layer (Figure 6 and Figure 7). Although specific, this clue is not a common finding in histopathologic micrographs of fungal infections (3).

3. Basket-weave pattern or compact hyperkeratosis is frequently reported as a histopathological indicator, although it has been proven that this sign is a common finding in non-dermatophytic infections (3).

4. Prominent papillary dermal edema (PPDE), originally described by Ackerman and

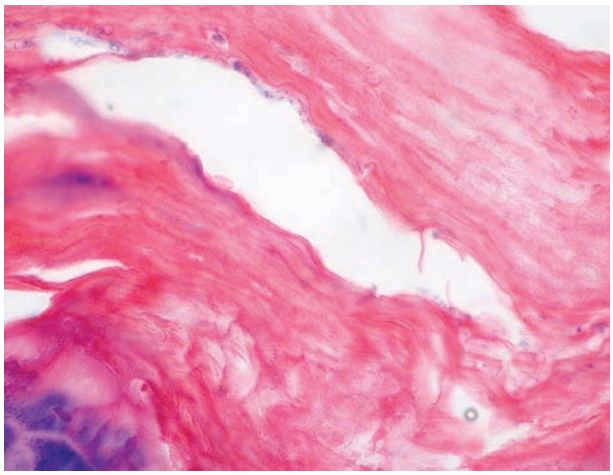

Figure 6. H&E-stained section showing a sandwich sign - hyphae in the corneal layer fissure (hematoxylin and eosin, x 400)

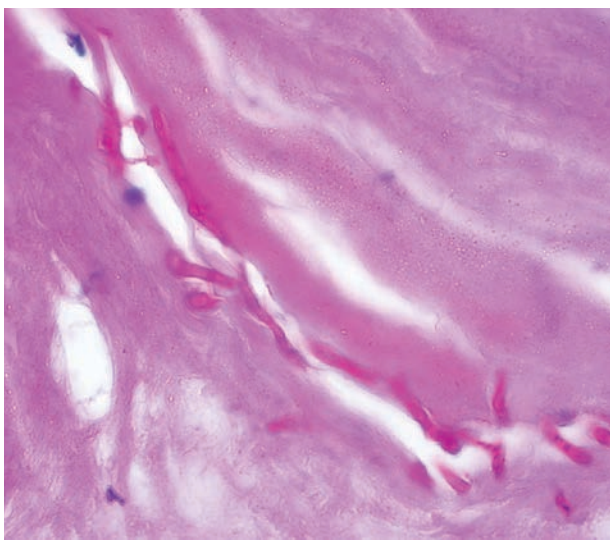

Figure 7. PAS-stained section showing a sandwich sign - hyphae in the corneal layer fissure (periodic-acid-Shiff, x 400)

confirmed by Hoss et al., was present in a series of 16 reported cases of dermatophytic infections in glabrous skin (13).

Purpose

The purpose of this study was to estimate the prevalence of PAS-positive skin biopsies among all PAS-stained biopsies performed during the past six years and to analyze their clinical and histopathological features. All PAS-positive biopsy

specimens were assessed for histopathologic patterns of skin reactions, and presence of histopathological indicators.

Material and methods

During the period from January 2004 to December 2009, a total of 361 PAS-stained biopsies were retrospectively re-examined and clinical data were analyzed in the Dermatopathology Laboratory of the University Clinic of Dermatology in Skopje. Clinical data were obtained by reviewing pathology referral information.

All PAS-positive biopsy specimens were assessed for histopathological patterns of skin reactions and presence of histopathological indicators.

Results

Out of a total of 2.391 biopsies received during the past six years, PAS staining was performed in 361 (15%). In 134 cases, dermatophytosis was one of the clinical differential diagnosis. In 127 cases skin biopsies were PAS-stained due to additional requirements of histopathologists.

Out of the total number of PAS-stained samples, fungi were identified in 12 (3.3%) slides. In 5 cases (1.4%), fungal infection was one among other differential diagnoses and in 7 cases (1.9%) newly diagnosed dermatophytosis was established.

The most frequent location of skin lesions were palms, soles (5) and face (2). The most common differential diagnoses were eczema, contact dermatitis and palmo-plantar psoriasis (Table 1).

The most frequent histopathological inflammatory reaction patterns (in 12 PAS-positive slides) were spongiotic, found in 7 (58%) cases, and psoriasiform pattern present in 3 cases (25%) (Table 2).

Neutrophils in the corneal layer were the most common histopathological indicators registered in 8 (66%) cases. Prominent papillary dermal edema was registered in 2 cases. Both patients suffered from tinea corporis.

Hyphae have been visible in H&E stained sections in 3 cases (cases number 8, 11 and 12).

In our series, few unusual clinical manifestations of fugal skin infections were registered. One patient (number 9) was diagnosed and treated for DLE instead for tinea faciale. One patient (number 12) with the diagnosis of HIV infection had extensive scaly and pustular lesions located on extremities. The biopsy specimen obtained from this patient showed predominantly eosinophylic dermal infiltrate and numerous hyphae visible in H&E stained section.

Discussion

Two factors make the histopathological diagnosis of dermatophytoses difficult. Firstly, hyphae cannot be easily seen in H&E stained sections. In one series, only 57% of PAS positive cases exhibited hyphae in H&E stained sections (3). In our study, only three cases (25%) presented with visible hyphae in H&E stained sections. Secondly, in most biopsies, dermatophytosis is only rarely suspected. Al-Almiri et al. reported that tinea was included in the differential diagnosis only in 45% of PAS positive cases (3).

We found 3.3% (12/361) PAS positive cases, moreover 1.9% (7 cases) were newly diagnosed dermatophytoses, where fungal infection was not clinically suspected. These results are similar to the results reported by Murphy whose study included a total of 99 PAS stained skin biopsies: 3 cases of clinically suspected dermatophytoses were confirmed, and 4 cases were newly diagnosed dermatophytoses (14). A cost-effective analysis was also performed, and it was concluded that a finding of at least one case of unexpected fungal infection is financially justified (14).

The importance of histopathological reaction patterns and indicators

Inflammatory response to superficial fungal infection highly depends on the fungal virulence, the host immune system, and local factors (1). Skin reactions may vary, ranging from mild to

Table 1. Clinical and histological findings in 12 patients with PAS positive staining

Patient #: age/gender/location	Submitted clinical diagnosis	Histopathological findings (H&E)
#1:43years/female/forearm	Allergic contact dermatitis	Scale, crust and fibrin NE Mixed dermal infiltrate
#2: 33 years/male/foot	Pustular psoriasis Tinea	Scale, crust, numerous hyphae SS, NE Mixed dermal perivascular infiltrate
#3: 21 years/female (no data about location)	Nummular dermatitis	Scale, crust NE, PPDE Mixed dermal infiltrate
#4: 45 years/female/shin	Tinea Contact dermatitis	Scale, crust, numerous hyphae NE Superficial/deep lymphocytic infiltrate
#5: 46 years/female/foot	Eczema Tinea Pustular psoriasis	Scale, crust, microvesicles NE Mixed dermal infiltrate
#6: 49 years/female/palm	Tinea Eczema tyloticum	Compact keratin Focal scale, crust SS Perivascular lymphocytic infiltrate
#7: 27 years /male/shin	Eczema Pustular psoriasis	Scale, crust PPDE Superficial and deep mixed infiltrate
#8: 33 years/female/palm	Eczema Tinea Pustular psoriasis	Scale, crust, numerous hyphae NE Superficial lymphocytes Hyphae on H&E staining
#9: 27 years/female/face	DLE	Basket weave and compact keratin Superficial and deep mixed infiltrate
#10: 38 years/female/face	Leishmaniasis DLE	Basket weave and compact keratin SS Superficial and mid-dermal mixed infiltrate
#11: 68 years/male/glans penis	Erythroplasia of Queyrat	Scale, crust with numerous hyphae Subcorneal pustule NE Mixed infiltrate Hyphae on H&E staining
#12: 27 years/male/palm	AIDS Ofuji's Disease	Scale crust with numerous hyphae NE Superficial and deep infiltrate with eosinophils and neutrophils Hyphae on H&E staining

H&E: hematoxylin-eosin; NE: neutrophils in the epidermis; PPDE: prominent papillary dermal edema; SS: sandwich sign; DLE: discoid lupus erythematosus

severe forms. In the majority of cases, superficial fungal infections may present with spongiotic, psoriasiform, vasculopathic and folliculitis/perifolliculitis histopathological reaction patterns. However, non-typical microscopic findings were recently described: lichenoid, vesiculobullous acantholytic and eosinophilic folliculitis (4-8).

The peresence of neutrophils in the epidermis/corneal layer, is the most frequently reported symptom that was considered as the

Table 2. Histopathological reactions and indicators in 12 patients with PAS-positive tinea

Histopathological reaction patterns	Number of cases	Histopathological indicators	Number of cases
Superfitial perivascular dermatitis	1	Neutrophils in the epidermis	8
Spongiotic pattern	7	Sandwich sign	3
Psoriasiform pattern	3	Basket weave hyperkeratosis	2
Folliculitis and perifolliculitis	1	Prominent papillary dermal edema	2

specific sign in the diagnosis of dermatophytoses for a long time. Meymandi et al. reported intraepidermal presence of neutrophils in 63% of tinea infection cases, and in 41% of psoriasis or eczema cases, the difference was not statistically significant (11). Al-Amiri et al. reported this histopathohological finding in 28% of tinea cases. In our study, the presence of neutrophils in the epidermis represented the most frequent histopathological indicator, found in 8/12 (66%) of all PAS positive cases.

Prominent papillary dermal edema (PPDE) may occur in various dermatologic conditions: polymorphous light eruptions, arthropod bite reactions, Sweet syndrome, erysipelas, perniosis, lichen sclerosus et atrophicus (early stages) (15). Hoss et al. reported 16 cases of tinea associated with PPDE (15). All 16 cases occurred in the extremities of female patients. The authors proposed that lesions with PPDE should be strongly considered in the differential diagnosis of dermatophytoses. In our series, PPDE was found in two cases of tinea corporis.

In our study, the "sandwich" sign, which is a typical histopathological clue for skin fungal infections was present only in 3 (25%) cases. In a similar study it was reported in 12% of all studied cases (3).

These results show that histopathological H&E stained slides are not reliable histopathologic parameters for establishing the diagnosis of dermatophytoses. Our study confirms that the presence of neutrophils in epidermis represents the most common histopathological diagnostic clue for fungal skin infections.

Conclusion

Histopathological analysis is of great benefit in the diagnosis of dermatophytoses and represents a substantial adjuvant diagnostic method. PAS staining represents a relatively cheap and simple fungal-specific staining. It has been suggested that this method not only confirms that the selected material is actually invaded, but also reduces the number of false-negative reports, where fungi are cultured from a microscopically negative specimen. Despite a low prevalence of positive findings, our results justify the need for routine PAS staining of all clinically and histologically non-specific inflammatory skin conditions.

References:

1. Hinshaw M, Longley BJ. Fungal diseases. In: Elder DE, Elenitsas R, Johnson BL, Murphy GF, editors. Lever's histopathology of the skin. Philadelphia: Lippincott Williams and Wilkins; 2004. p. 603.
2. Lawry MA, Haneke E, Strobeck K, Martin S, Zimmer B, Romano PS. Methods for diagnosing onychomycosis: a comparative study and review of the literature. Arch Dermatol 2000;136(9):1112-6.
3. Al-Amiri A, Chatrath V, Bhawan J, Stefanato CM. The periodic acid-Schiff stain in diagnosing tinea: should it be used routinely in inflammatory skin diseases? J Cutan Pathol 2003;30:611.

4. Ziemer M, Seyfarth F, Elsner P, Hipler UC. Atypical manifestations of tinea corporis. Mycoses 2007;50(Suppl 2):S31-5.
5. Terragni L, Marelli MA, Oriani A, Cecca E. Tinea corporis bullosa. Mycoses 1993;36(3-4):135-7.
6. Sánchez Yus E, Requena L, Simón P, de Hijas CM. Incidental acantholysis. J Cutan Pathol 1993;20(5):418-23.
7. Kim HS, Cho BK, Oh ST. A case of tinea corporis purpurica. Mycoses 2007;50(4):314-6.
8. Shindo M, Nakashima K, Yoshida Y, Yamamoto O. Trichophyton rubrum infection histologically identical to eosinophilic pustular folliculitis. Clin Exp Dermatol 2008;33(4):500-1.
9. Tani K, Adachi M, Nakamura Y, Kano R, Makimura K, Hasegawa A, et al. The effect of dermatophytes on cytokine production by human keratinocytes. Arch Dermatol Res 2007;299(8):381-7.
10. Ackerman AB. When you see-think. In: Ackerman AB, editor. Histologic diagnosis of inflammatory skin diseases. Philadelphia: Lea and Febiger; 1978. p. 830.
11. Meymandi S, Silver SG, Crawford RI. Intraepidermal neutrophils: a clue to dermatophytosis? J Cutan Pathol 2003;30:253.
12. Gottlieb GJ, Ackerman AB. The „sandwich sign" of dermatophytosis. Am J Dermatopathol 1986;8:347.
13. Hoss D, Berke A, Kerr P, Grant-Kels J, Murphy M. Prominent papillary dermal edema in dermatophytosis (tinea corporis). J Cutan Pathol 2010;37(2):237-42.
14. Murphy JK, O'Donohue L. The diagnostic value and cost effectiveness of routine fungal stains in a dermatopathology service of a district general hospital. J Clin Pathol 2004;57:139-40.
15. Ackerman AB. Polymorphous light eruption. In: Ackerman AB, Chongchitnant N, Sanchez J, Guo J, Bennin B, Reichel M, et al, editors. Histologic diagnosis of inflammatory skin diseases. 2nd ed. Baltimore: Williams & Wilkins; 1997. p. 642.

Značaj patohistološkog nalaza u dijagnostici dermatofitoza

Sažetak

Uvod**:** Patohistološka analiza nije rutinska metoda u dijagnostikovanju gljivičnih oboljenja kože. Gljivice se u patohistološkim preparatima bojenim rutinskim bojama, npr. hematoksilin-eozinom, praktično ne mogu identifikovati, s obzirom da se gljivični elementi, tj. hife, boje bledo plavo (Slika 1). Gljivice postaju vidljive pomoću specijalnih bojenja, npr. *periodic-acid-Shiff* (PAS) bojenje, koje gljivice boji u crveno (Slika 2). Patohistološke promene kod gljivičnih infekcija nisu specifične, analogno kliničkom nalazu (Slika 3). U slučajeve kada je uzeta biopsija sa lezije bez prethodno postavljene sumnje na gljivičnu infekciju kože, poznavanje najčešćih modela patohistoloških reakcija kao i određenih patohistoloških indikatora (tzv. histološki *ključevi* za dijagnozu), kod pojedinih dermatomikoza, npr. dermatofitoza (površinske infekcije kože izazvane dematofitama sinonim tinea), mogu navesti patohistologa da posumnja na gljivičnu infekciju i dodatno uradi specijalno, npr. *periodic-acid-Shiff* (PAS) bojenje za prikazivanje gljivica.

Patohistološki modeli. Najčešći modeli patohistoloških reakcija kod dermatofitoza: 1. *superficijalni perivaskulitis*, u kome je inflamatorni proces smešten pretežno oko krvnih sudova u površinskim delovima dermisa i koji je najmanje specifičan, a može se videti kod velikog broja različitih dermatoloških oboljenja; *2. spongiotično/ekcemski,* koji je najčešći i za koji su karakteristični spongioza i ekcem; *3. psorijaziformni,* u kome se prisustvo neutrofilnih granulocita u spinoznom i kornealnom sloju sa formiranjem mikroapscesa praktično ne može razlikovati od eruptivne psorijaze; *4. folikulitis i perifolikulitis,* u kome gust inflamatorni infiltrat i destrukcija folikula otežavaju detekciju gljivičnih elemenata i u PAS bojenim preparatima (Slika 4); *5. granulomatozni,* koji se najčešće nalazi kod dubokih gljivičnih infekcija, i koji po pravilnu zahteva obavezno PAS bojenje nezavisno od kliničkog nalaza.

Patohistološki indikatori (*ključevi*): Na preparatima bojenim hematoksilin/eozinom mogu se u pojedinim slučajevima uočiti znaci koji ne samo da pobuđuju sumnju na infekciju izazvanu dermatofitima, nego mogu tačno da ukažu i na mesto na kome se nalaze gljivični elementi: 1. *neutrofilni granulociti u epidermisu* se dovode u direktnu vezu sa dermatofitima i ovaj nalaz se smatra *ključem za dermatofitoze* (Slika 5); *2. znak "sendviča",* u kome se u kornealnom sloju nalaze hife, smeštene u pukotini nastaloj između dve lamele, gornje ortokeratotične i donje parakeratotične (slike 6 i 7) - iako se

smatra specifičnim, ovaj znak je izuzetno retko prisutan; *3. kornealni sloj u vidu pruća na korpi ili kompaktna hiperkeratoza,* nalaz koji se često navodi u funkciji indikatora, ali se praktično viđa u mnogim infekcijama kože koje nisu izazvane dermatofitima; *4. edem u papilarnom dermu,* koji je karakterističan za gljivičnu upalu kože koja nije obrasla dlakom, tzv. glatke kože. Navedeni modeli i indikatori nisu sami po sebi dovoljni za postavljanje dijagnoze, oni indikuju bojenje datog preparata bojama specifičnim za gljivice.

Cilj: Ispitivanje je imalo za cilj da među svim PAS bojenim bioptatima kože, koji su rađeni tokom šestogodišnjeg perioda, od januara 2004. do decembra 2009. godine, utvrdi prevalenciju PAS-pozitivnih bioptata i da analizira njihove kliničke i patohistološke osobine.

Metod: Retrospektivno su analizirane biopsije sa izvršenim PAS bojenjem. Kod PAS pozitivnih biopsija određivani su sledeći parametri: kliničke karakteristike, modeli patohistoloških reakcija i prisustvo određenih patohistoloških indikatora.

Rezultati: Od 361 PAS-bojenih biopsija, kod 12 (3,3%) je dokazano prisustvo hifa. Kod 5 (1,4%) slučajeva bilo je kliničke sumnje za gljivično oboljenje, a kod 7 (1,9%) radilo se o novoj dijagnozi. Kod 127 od ukupno 361 PAS-bojenih biopsija, nije postojala prethodno postavljena klinička dijagnoza ali ni sumnja da se može raditi o gljivičoj infekciji kože. U tim slučajevima je PAS bojenje naknadno indikovao patohistolog. Najčešći model patohistološke reakcije bio je spongiotični, a najčešći patohistološki indikator, nalaz neutrofila u epidermu.

Zaključak: Dobijeni rezultati u ovom ispitivanju potvrđuju da se dermatofitoze, mogu prezentovati sa klinički i histološki nespecifičnim nalazima. PAS bojenje je relativno jeftina i jednostavna metoda za bojenje gljivica. I pored malog procenta pozitivnih nalaza, s obzirom na finansijsku opravdanost svake neočekivano dokazane gljivične infekcije, ova serija podržava potrebu za rutinskom primenom PAS bojenja kod klinički i histološki nespecifičnih inflamatornih dermatoza.

