

LITERATURE REVIEW

Treatment difficulties in salivary gland cancer

Elena Patrascu^{1,2}, Violeta Melinte^{1,2}, Carmen Paraschiv-Ferariu², Codrut Sarafoleanu^{1,2}

¹“Carol Davila” University of Medicine and Pharmacy, Bucharest, Romania

²Center of excellence for research of sensorial and sensitive disorders, study of infecto-inflammatory, tumoral and obstructive aero-digestive pathology (CESITO), ENT&HNS Department, “Sfanta Maria” Clinical Hospital, Bucharest, Romania

ABSTRACT

Salivary gland cancers are represented by a heterogeneous histologic group of tumors, with low incidence, which may appear both in major and minor salivary glands. This article presents a review of the difficulties which may be encountered in this pathology during the treatment. The diagnosis of salivary gland cancers is often delayed, due to the histopathologic and immunohistochemistry results given in different period of times. There can be several difficulties in following the oncologic pre-treatment protocols, in terms of imaging technique, as MRI, useful for disease staging.

The treatment of salivary gland cancers is complex, due to the local anatomy and their aggressive potential. Because of their decreased incidence, there are few data that investigate the treatment in the case of these diseases. The current therapy available for the patients with salivary gland cancers is represented by complete surgical resection. Several treatment difficulties in cancers of the salivary glands may come from the surgical limitations and the insufficient data for adjuvant and palliative treatment. Due to the limitations of the local health system, there is a heterogeneous distribution of the oncologic centers, lack of equipment, prolonged time to follow general protocols, despite the aspect of case- individualized therapy according to the guidelines. We must not forget the tumor behaviour and individual reactivity of different patients to the same treatment protocol.

KEYWORDS: salivary gland cancer, fine needle aspiration, salivary glands surgery.

INTRODUCTION

Salivary gland cancers have a relatively low incidence, representing 3-7% of head and neck malignant tumors¹. Salivary gland tumoral masses may appear inside the major salivary glands (submandibular, sublingual or parotid) or inside the minor salivary glands found submucosally, in the upper aero-digestive pathway¹. The parotid glands are the most frequently involved, in 64% to 80% of the cases, followed by the submandibular salivary glands (in 7% to 11% of the cases), sublingual glands (1%) and minor salivary glands (9% to 23%). These malignancies tend to appear in the fourth or fifth decade of life, with an increasing incidence with age and especially in men².

The etiology of these tumors is mainly unknown. There have been proven correlations between the Epstein Barr virus or Human papilloma virus infections or immune system suppression, like lymphoepithelial carcinomas, medulloblastomas or HIV infections, and salivary gland neo-

plasms. At the same time, there has not been reported any association between the etiology of this pathology and smoking or drinking^{3,5}. A great role may be played by the exposure to ionizing radiations.

The general classification of salivary gland cancers is made by the World Health Organization recommendations from 2005, which recognizes 24 histopathological types. These tumor types are divided into two categories, related to their aggressive potential and prognosis⁶. High-risk tumors determine early frequent local metastasis to the lymph nodes and to distance, through haematogenous pathways. The intermediate types are mainly represented by adenoid cystic carcinomas, which invade the cranial nerves and disseminate to the base of the brain. Low-grade cancers have a decreased malignancy potential^{7,8}, the most frequent types being the muco-epidermoid carcinomas, with 2.8-15% incidence¹.

The diagnosis of salivary gland cancers is complex, with clinical and paraclinical investigations – imaging (ultrasound, CT scan or MRI). Before proceeding to ther-

apy, the histopathologic diagnosis is needed⁹.

Through the diagnostic methods, fine needle aspiration cytology (FNAC) is a special technique able to provide histopathological samples, which can help us establish the proper therapeutic plan. Despite the fact that the method has elevated specificity (85%) and sensitivity (86%), it is operator-sensitive and depends to the doctor's experience, because it requires properly trained physicians¹⁰. Similar to every diagnosis methods, it has several proven advantages, but it is not infallible.

The advantages are mainly represented by the fact that it is a minimally invasive technique, which is well accepted by the patients. The results obtained are able to distinguish neoplastic from non-neoplastic diseases, to identify lymphoma and salivary gland metastasis from skin cancers, so the doctor can decide between a surgical procedure or non-surgical treatment^{11,12}. Moreover, this diagnostic technique can be a useful tool for the specialist to make the surgical planning and provide a proper preoperative counselling to the patient^{11,12}.

In the current practice, there are some opponents who related that the information provided through the fine needle aspiration does not change the therapeutic plan, which is mainly surgical. Also, in the case of lymphomas, this technique is not always able to establish a diagnosis; it may require several biopsies, which extend the time for diagnosis and treatment, with increased costs¹². From the anatomical point of view, the parotid glands have the highest rates of inaccuracy, because they tend to have a large tumoral diversity, and it is not always easy to differentiate between these types. Also, some parotid carcinomas appear nonthreatening at cellular level.

In a study conducted by Balakrishnan et al., they observed that FNAC is not reliable in distinguishing between a malignant and a benign salivary gland tumor¹². Physicians should interpret the results with extreme precaution. The results of their study indicated that 46% of the samples were diagnostic suggestive, whilst 31% of the samples non-diagnostic, 15% of the cases were aspirates errors and 15% of the samples misleading. The specificity of the fine needle aspiration technique in identifying malignancies was 79%, the sensitivity 84%, whilst the method provided a 68% positive predictive value. In case of lymphomas, fine needle aspiration is not specific, inducing diagnostic errors, with subsequent therapeutic failure; in some of the cases, radical parotidectomy might have been avoided¹².

In case of failure, FNAC may be replaced with an alternative investigation, ultrasound-guided core biopsy (USCB) used especially for the parotid glands. This technique is performed under local anaesthesia, with 18-20 G needles, and it has a diagnostic sensitivity of 100%¹¹. Open biopsies are not usually recommended, because they might have a high risk of seeding the tumoral cells.

Imaging techniques are represented by the ultrasound examination, which is less expensive and highly sensitive, and CT scan, MRI or PET-CT scan¹³.

PET-CT scan is a useful technique for tumoral staging, by identifying locoregional or distant metastasis, as well as for therapeutic follow-up. In most of the cases (69%), the method has specificity for the tumoral nature, benign or malignant, with almost 100% sensitivity for the malignant disease, with 30% rate of false-positive results. Those false-positive results usually appear in the case of inflammatory modifications, Warthin tumor or pleomorphic adenoma^{13,14}.

In a study conducted by Koyuncu et al., the authors performed a retrospective study, in which they compared the CT and MRI results in the identification of salivary gland cancers¹⁵. The conclusion was that the MRI technique better distinguished intrinsic lesions, compared to the extrinsic ones. Tumoral infiltration was detected equally by the CT scan and MRI, but MRI is three times more expensive than the CT scan. CT scan and MRI technique are equivalent from the morphological point of view, with similar diagnostic potential in parotid gland tumors, but MRI has proven to be better in evaluating perineural spread.

TREATMENT STRATEGIES IN SALIVARY GLAND CANCERS

The therapeutic approach of salivary gland cancers is currently not standardized¹⁶. It is mainly represented by surgical approach, along with radiotherapy and chemotherapy, depending on the tumor stage, aggressive potential and the patients' option¹⁷. Complete tumor resection, with negative margins, is considered nowadays the basic treatment for salivary gland cancers. For example, the only therapy in the case of low-grade cancers that involve the superficial lobe of the parotid gland is superficial parotidectomy. In general, for all other localizations, it is indicated to perform a total parotidectomy¹⁸. Due to the permanent clinical research in this pathology, the therapeutic results for the patients diagnosed with salivary gland cancers have improved in the past years.

In the current management of salivary gland cancers, there are several difficulties which may be encountered during the treatment and they may be represented by surgical approach of the primary site or the lymph nodes or the adjuvant therapy, radiotherapy or chemotherapy¹⁹ (Table 1).

Most of the patients diagnosed in early stages tend to have surgery as the main therapeutic step, whereas the patients with advanced disease tend to undergo only radiotherapy, or in combination with systemic chemotherapy (Table 1). Tumor stage, histology, grading, facial nerve paralysis, extra-parotid tumor extension and cervical node involvement are the most important tumor-related predictors of survival²⁰.

Radiotherapy

Salivary gland cancers present a high radiosensitivity and irradiation is currently established as a part of

Table 1
General therapeutic recommendations in salivary gland cancers¹⁹

Only surgery	Surgery + radiotherapy	Neck dissection	Chemotherapy
Free margins	Close (less than 2 mm) or positive tumoral margins	cN+ tumors	Metastasis or inoperable tumors
		cN0, high-grade types	
Low-grade types	High-grade types	cN0, with high risk histologic type	
Low risk histologic subtypes	High risk - infiltrative histologic subtypes	cN0	
T1/T2	T3/T4	T3	
	pN+	T4	
	Perineural spread		
cN+ = clinically lymph node positive; cN0 = clinically lymph node negative; pN+ = pathologically lymph node positive			

the postoperative adjuvant therapy, in patients who are at risk of locoregional tumor recurrence^{21,22}. There are several studies which indicate that regional tumor control is enhanced with the addition of the postoperative irradiation.

The recommended radiation dose for the main tumoral site and local lymph nodes is 60Gy and 56Gy in the case of negative lymph nodes. For the undissected sites, a total dose of 50Gy is used, with a daily fraction of 2Gy²⁰.

Radiotherapy alone, especially with fast neutron, is the preferred treatment in patients who are not eligible for surgical approach, due to tumor extension or comorbidities. In general, the patients who are treated only with radiotherapy have an unfavourable prognosis. Because of the fact that this pathology has a low incidence, there is a lack of randomized clinical studies for establishing the role of adjuvant radiotherapy¹.

Postoperative radiation therapy (PORT) is recommended in patients with negative prognostic, like T3 or T4 stages, with incomplete or close resection margins, high-grade tumors with perineural spread or vascular invasion; invaded lymph nodes¹. The role of adjuvant radiotherapy in patients with T1 or T2 stages and complete surgical resection has not been confirmed yet²⁴.

Compared with intensity-modulated radiation therapy (IMRT) and three-dimensional conformal radiation therapy (3D-CRT), the new treatment through intensity-modulated proton therapy (IMPT) is able to allow the optimal radiation dose distribution to the tumoral site, which determines a total dose decrease and improves the sparing of healthy tissues, but with similar therapeutic results²⁴.

Recent studies show that neutron-beam radiation therapy has a higher efficiency compared to conventional radiation in salivary gland cancers, because it is able to reduce the tumoral mass, with less adverse effects upon the surrounding normal tissue^{25,26}. This radiation technique is

recommended in the case of advanced or recurrent disease, although it does not improve the survival rate.

Neck dissection

The presence of the cervical lymph node at the moment of diagnosis represents an important prediction factor¹. In 10-20% of the cases, there are also occult lymph nodes metastases, especially in high-grade cancers.

At the moment of primary surgery, it is recommended to perform also a therapeutic neck dissection in patients with clinically positive lymph nodes. Postoperative radiotherapy must be applied in these cases, regardless of the histological tumor type²⁴.

In the case of clinical negative lymph nodes, N0, the treatment is still controversial and it may consist in elective neck dissection, observation or prophylactic radiation. The studies recommend that elective neck dissection should be performed for high-grade tumor types¹.

Valstar et al. performed a metanalysis in order to determine the usefulness of the elective neck dissection in patients with clinically negative lymph nodes²⁶. The study consisted in reviewing 39 papers for a period of ten years, between 1997 and 2007. The results of their metanalysis indicated that 83% of the patients, from a total number of 871 patients, were considered N0 using clinical (palpation) and imaging assessment. The histopathology from elective neck dissection identified occult metastases in 23% of the patients. Local tumoral recurrence appeared in approximately 5% of the cases, after aggressive approach. In terms of facial nerve involvement, nerve sacrifice has proven a great local disease control, but with the disadvantage of poor quality of life. Postoperative radiotherapy improved local control rates in the patients included in the study.

The aggressiveness of the disease may be quantified using several prognostic factors, such as high-grade

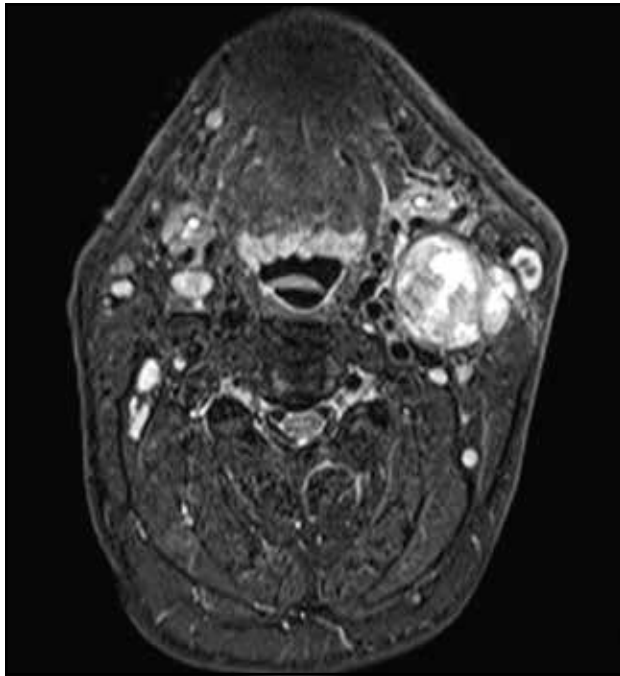


Figure 1 Neck MRI, axial slice –left parotid tumor with extension at vital vascular structure and facial nerve involvement.

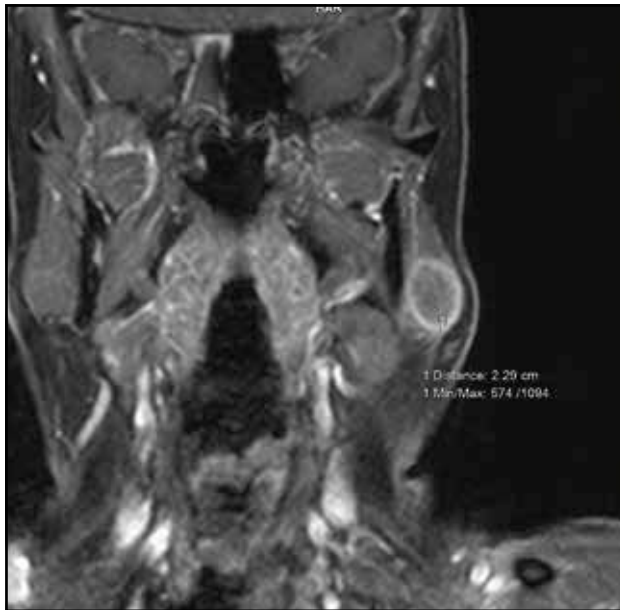


Figure 2 Neck MRI, coronal slice. Left parotid carcinoma interpreted by the radiologist as “benign cystic tumor” – encapsulated, well defined tumor, with cystic aspect. Intraoperatively, we identified a mass tumor with no cystic aspect, which included and infiltrated the left parotid gland. Thus, a more extensive surgical technique was needed.

tumor type, facial nerve involvement, age higher than 54 years old, perilymphatic spread, stages T3 or T4 of the disease. In the presence of negative predictive factors, neck dissection must be performed in addition to local surgery^{27,28}.

Chemotherapy

In the case of localized disease, the therapeutic approach consists in surgery alone or associated with post-operative radiotherapy, whilst in the case of recurrent or advanced disease, systemic therapy is preferred. There are few things clearly described in the chemotherapy for salivary gland cancers, due to its low incidence. The patients with local recurrence or distant metastasis still represent a challenge, in order to identify the proper therapeutic approach. Currently, there is no consensus either to perform surgery alone, radiotherapy alone or both therapy types combined^{1,28}.

Salivary gland cancers are considered to be chemotherapy-resistant, but almost half of these patients will still experience tumoral shrinkage. Usually, salivary gland cancers are associated with local relapsing and metastasis and systemic therapy does not provide satisfactory results. Conventional chemotherapy substances (cisplatin, 5-FU and cyclophosphamide) are considered the first-line chemotherapies for the patients with advanced disease. Some studies showed that the survival rates for the patients with distant metastasis were similar, regardless of chemotherapy (35.2% vs. 27.6%, $P = 0.747$)¹.

In order to improve the patients' outcome and prognosis, there is an urgent need to perform future clinical studies, to identify new molecules or therapeutic agents. The study of the epidermal growth factor - EGF receptor family (EGFR and HER2) and androgen receptors seems like a promising option in the future, due to their overexpression in this pathology²⁹. EGFR blockage with Cetuximab and Erlotinib is considered to inhibit tumoral growth. Other molecules, like Bevacizumab and Vanitib, are proposed in the treatment of this pathology, due to their ability to inhibit the vascular endothelial growth factors (VEGF), with a secondary inhibition of the tumoral angiogenesis.

TREATMENT DIFFICULTIES

The treatment difficulties with which we can confront in the salivary gland neoplasm arise from the surgery technique or the health system.

Surgery difficulties

In order to improve the therapeutic outcome, the type of surgery must be considered, either functional or radical, taking into consideration the patients' comorbidities and expectancy, along with tumor characteristics. It is difficult to decide how much functional surgery may be performed, in order to be oncologically correct^{1,30}.

Regarding the surgical therapy, there are several difficulties that might be encountered, especially in parotid gland cancers, due to the facial nerve involvement (Figure 1). Intraoperative facial nerve monitoring is recommended to be used, in order to try to decrease the post-

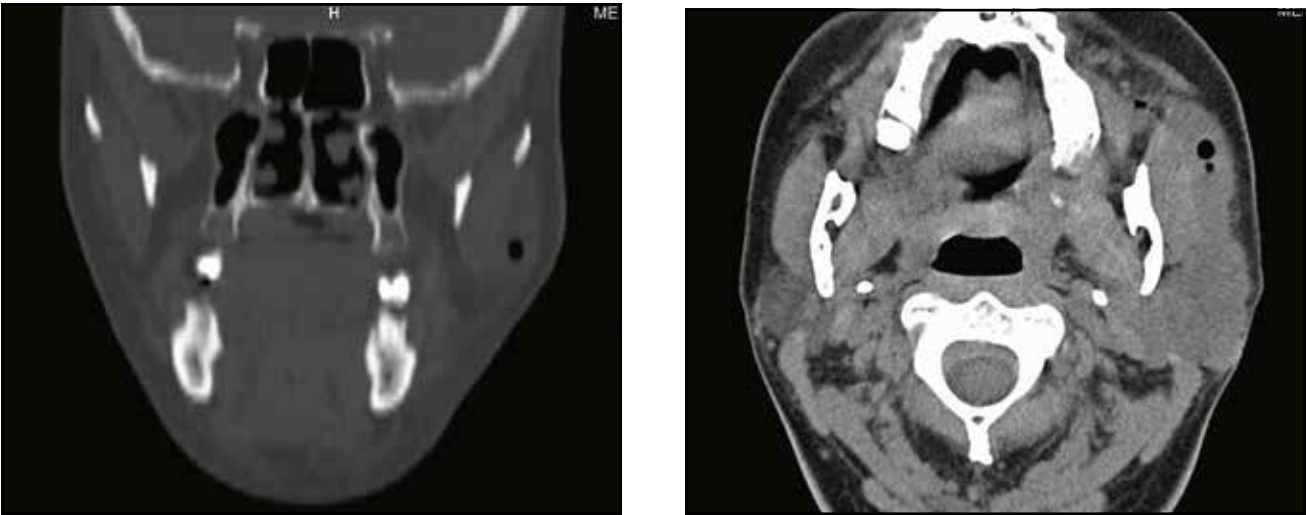


Figure 3 Cranio-facial CT scan (coronal slice – left, axial slice – right) findings described as a mass tumor at the level of the left parotid gland, with important infiltration into the adjacent structures. As one can see, on the CT scan there are air bubbles in the mass tumor, aspect which can suggest an abscess; this observation was confirmed during the surgery.

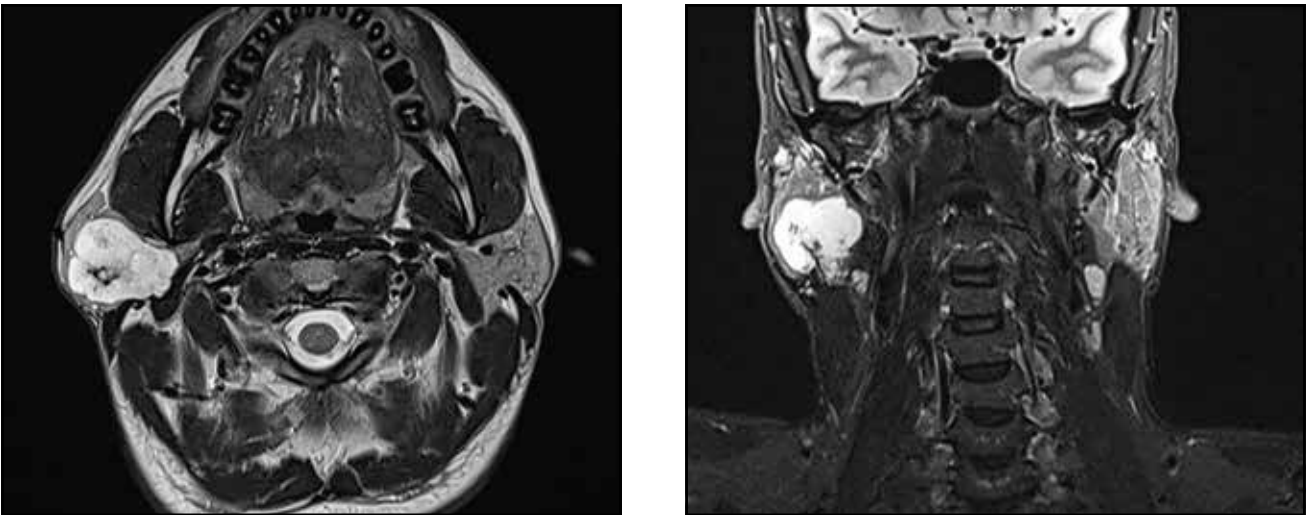


Figure 4 Head and neck MRI, axial and coronal slices – confirmed the presence of a left parotid gland mass tumor with imaging characteristics suggestive for a malignant tumor. The fine needle aspiration cytology diagnosis revealed cytological aspects suggestive of a Warthin tumor. The histopathological examination confirmed the Warthin tumor described by cytology, thus defying the suggestive appearance of malignant tumor seen on the MRI.

Localizare leziune	TRIGON SUBMANDIBULAR/ TRIGON CAROTIC DREPT
Funcții anterioare C	
Aspirat	mixt hemoragic
Cantitate aspirat ml	0,2
Dg citologic	EPITELII GLANDULARE BINE REPREZENTATE CU ASPECTE DE TIP ACINAR, COMPACT SI FIN TRABECULARE TIP OXIFIL (HURTHLE) : FARA ATIPII SEMNIFICATIVE, CU BUNA COEZIVITATE GENERALA, MODERAT SI PARCELAR MARCAT INFILTRAT INFLAMATOR CRONIC PERIEPITELIAL, ARII DE COLESTAZION. ASPECTE CITOLOGICE SUGESTIVE PENTRU TUMORA WARTHIN

operative associated facial nerve paralysis. In the case of facial nerve tumoral involvement, sacrifice is the mainstay, with a nerve repair that can be done during the same surgical procedure. In locally advanced diseases, with tumor extension at vital vascular or neural structures (the mandible, the cervical spine), the surgical approach is difficult. Positive N3 neck lymph node is difficult to surgically manage.

In many cases, local reconstruction is needed for the facial nerve, the remaining skin defects or mandible³¹. In some cases, it is possible for the imaging (CT or MRI) to not fit with the local examination and intraoperative findings (Figure 2, Figure 3 and Figure 4). These discrepancies can make the surgical treatment of salivary gland tumors difficult in the light of the chosen surgical technique and patient counselling.

Health system difficulties

In the current practice, there is a lack of a multidisciplinary head and neck center, which determines the limitation of the complex surgical procedures and the team work. In many departments, the absence of the oncology board does not allow a proper therapeutic planning and follow-up.

The diagnosis of salivary gland cancers is often delayed due to the histopathologic and immunohistochemistry results given in different periods of times. In practice, there are difficulties in following the oncologic pre-treatment protocols, in terms of imaging technique, as MRI, useful for disease staging. Also, some of the physicians tend to ignore the therapeutic guidelines, establishing improper and unrealistic indications.

Once the therapeutic plan is established based on the patients' investigations results, appointments for radiotherapy usually delay the non-surgical treatments. The heterogeneous instrumentation and technologies in different departments do not allow the patients to have a realistic view of the disease.

Treatment difficulties in cancers of the salivary glands come from the heterogeneous distribution of the oncologic centers, lack of equipments, prolonged time to follow general protocols, despite the aspect of case-individualized therapy according to the guidelines. We must not forget the tumor behaviour and individual reactivity of different patients to the same treatment protocol.

We must not forget that patients who are diagnosed with salivary gland cancers have a high risk of developing secondary cancers, especially in other salivary glands, in the oral cavity, the thyroid, the lungs or the kidneys³². The main cause for therapeutic failure is local recurrence, cervical lymph nodes metastasis and distant metastasis. This risk depends on the tumoral stage and grade, presence of positive lymph nodes, facial nerve involvement and extraparenchymal extension³³.

Most of the recurrences appear in the first three years, which means this is the critical period when patients must be followed up strictly.

CONCLUSIONS

Salivary gland cancers are a heterogeneous group of neoplasms, with a relatively decreased incidence, but they present a large variety, in terms of histological types. The diagnosis must be established rapidly, through clinical and paraclinical investigations. FNAC is considered an important diagnostic tool, with high sensitivity and specificity, but CT scan and MRI should also be taken into consideration for the therapeutic planning.

The treatment of salivary gland cancers is complex, due to the local anatomy and their aggressive potential. Because of their low incidence, there are few data investigating their management, aspect which arises in several

difficulties that we may encounter during the treatment, difficulties that we have presented above. The current therapy available for the patients with salivary gland cancers is represented by complete surgical resection, with negative margins. Also, therapeutic neck dissection must be performed in patients with clinically or imaging positive lymph nodes.

Postoperative radiation therapy is able to improve therapeutic outcomes, especially in high-grade cancers, with positive margins, large tumors and histologic positive lymph nodes.

In patients with advanced inoperable cancers or who refuse the surgical approach, radiotherapy may be taken into consideration. Chemotherapy continues to be used as a palliation in the current therapeutic practice of salivary gland tumors, but constant research is trying to find a curative role as well, in order to improve the outcomes.

Conflict of interest: The author has no conflict of interest to declare.

Contribution of authors: All authors have equally contributed to this work.

REFERENCES

1. Arrangoiz R, Papavasiliou P, Sarcu D, Galloway TJ, Ridge JA, Lango M. Current thinking on malignant salivary gland neoplasms. *Journal of Cancer Treatment and Research*. 2013;1(1):8-24. DOI: 10.11648/j.jctcr.20130101.12.
2. El-Naggar AK. Tumours of salivary glands. In: El-Naggar AK, Chan JKC, Rubin Grandis J, Takata T, Sliotweg PJ, editors. *WHO Classification of Head and Neck Tumours*. France, Lyon: International Agency for Research on Cancer; 2017, p.159–202.
3. Wang X, Luo Y, Li M, Yan H, Sun M, Fan T. Management of salivary gland carcinomas - a review. *Oncotarget*. 2017;8(3):3946-56. DOI: 10.18632/oncotarget.13952.
4. Ho K, Lin H, Ann DK, Chu PG, Yen Y. An overview of the rare parotid gland cancer. *Head Neck Oncol*. 2011;3:40. DOI: 10.1186/1758-3284-3-40.
5. Johnston ML, Huang SH, Waldron JN, Atenafu EG, Chan K, Cummings BJ, Gilbert RW, et al. Salivary duct carcinoma: treatment, outcomes, and patterns of failure. *Head Neck*. 2016;38(Suppl 1):E820–6. DOI: 10.1002/hed.24107. Epub 2015 Jul 15.
6. Seethala RR. An update on grading of salivary gland carcinomas. *Head Neck Pathol*. 2009;3(1):69–77. DOI: 10.1007/s12105-009-0102-9.
7. Adelstein DJ, Koyfman SA, El-Naggar AK, Hanna EY. Biology and management of salivary gland cancers. *Semin Radiat Oncol*. 2012;22(3):245–53. DOI: 10.1016/j.semradonc.2012.03.009.
8. Haderlein M, Scherl C, Semrau S, Lettmaier S, Uter W, Neukam FW, et al. High-grade histology as predictor of early distant metastases and decreased disease-free survival in salivary gland cancer irrespective of tumor subtype. *Head Neck*. 2016;38(Suppl 1):E2041–8. DOI: 10.1002/hed.24375. Epub 2016 Feb 3.
9. Spiro RH, Thaler HT, Hicks WF, Kher UA, Huvoos AH, Strong EW. The importance of clinical staging of minor salivary gland carcinoma. *Am J Surg*. 1991;162 (4):330-6.
10. Kim BY, Hyeon J, Ryu G, Choi N, Baek CH, Ko YH, et al. Diagnostic accuracy of fine needle aspiration cytology for high-grade salivary gland tumors. *Ann Surg Oncol*. 2013;20(7):2380–7. DOI: 10.1245/s10434-013-

- 2903-z. Epub 2013 Feb 26.
11. Rossi ED, Wong LQ, Bizzarro T, Petrone G, Mule A, Fadda G, et al. The impact of FNAC in the management of salivary gland lesions: institutional experiences leading to a risk-based classification scheme. *Cancer Cytopathol.* 2016;124(6):388–96. DOI: 10.1002/cncy.21710. Epub 2016 Mar 9.
12. Balakrishnan K, Castling B, McMahon J, Imrie J, Feeley KM, Parker AJ, et al. Fine needle aspiration cytology in the management of a parotid mass: a two centre retrospective study. *Surgeon.* 2005;3(2):67-72.
13. Jeong HS, Chung MK, Son YI, Choi JY, Kim HJ, Ko YH, et al. Role of 18F-FDG PET/CT in management of high-grade salivary gland malignancies. *J Nucl Med.* 2007;48(8):1237–44. DOI: 10.2967/jnumed.107.041350.
14. Jegadeesh N, Liu Y, Prabhu RS, Magliocca KR, Marcus DM, Higgins KA, et al. Outcomes and prognostic factors in modern era management of major salivary gland cancer. *Oral Oncol.* 2015;51(8):770-7. DOI: 10.1016/j.oraloncology.2015.05.005. Epub 2015 May 29.
15. Koyuncu M, Sesen T, Akan H, Ismailoglu AA, Tanyeri Y, Tekat A, et al. Comparison of computed tomography and magnetic resonance imaging in the diagnosis of parotid tumors. *Otolaryngol Head Neck Surg.* 2003;129(6):726-32.
16. Cho JK, Lim BW, Kim EH, Ko YH, Oh D, Noh JM, et al. Low-grade salivary gland cancers: treatment outcomes, extent of surgery and indications for postoperative adjuvant radiation therapy. *Ann Surg Oncol.* 2016;23(13):4368–75. DOI: 10.1245/s10434-016-5353-6.
17. Hosni A, Huang SH, Goldstein D, Xu W, Chan B, Hansen A, et al. Outcomes and prognostic factors for major salivary gland carcinoma following postoperative radiotherapy. *Oral Oncol.* 2016;54:75–80. DOI: 10.1016/j.oraloncology.2015.11.023. Epub 2015 Dec 23.
18. Mendenhall WM, Werning JW, Pfister DG. Treatment of head and neck cancer. In: DeVita VT Jr, Lawrence TS, Rosenberg SA, DePinho RA, Weinberg RA (editors). *Cancer: Principles and Practice of Oncology.* 9th ed. Philadelphia, Pa: Lippincott Williams & Wilkins; 2011, p.729-80.
19. Pernas FG. Current Controversies in the Management of Malignant Parotid Tumors. Grand Rounds Presentation, The University of Texas Medical Branch (UTMB), Dept. of Otolaryngology. [Internet]. Available from: <https://www.utmb.edu/otoref/grnds/malig-parotid-tumors-2011-02-25/malig-parotid-tumors-0211-02-25.pdf>.
20. Nance MA, Seethala RR, Wang Y, Chiosea SI, Myers EN, Johnson JT, et al. Treatment and survival outcomes based on histologic grading in patients with head and neck mucoepidermoid carcinoma. *Cancer.* 2008;113(8):2082–9. DOI: 10.1002/cncr.23825.
21. Richter SM, Friedmann P, Mourad WF, Hu KS, Persky MS, Harrison LB. Postoperative radiation therapy for small, low-/intermediate-grade parotid tumors with close and/or positive surgical margins. *Head Neck.* 2012;34(7):953-5. DOI: 10.1002/hed.21843. Epub 2011 Aug 17.
22. Seifert G. *Histological Typing of Salivary Gland Tumours.* 2nd ed. Springer-Verlag Berlin Heidelberg; 1991.
23. Borthne A, Kjellefold K, Kaalhus O, Vermund H. Salivary gland malignant neoplasms: treatment and prognosis. *Int J Radiat Oncol Biol Phys.* 1986;12(5):747-54. DOI: 10.1016/0360-3016(86)90032-5.
24. Spiro RH. Factors affecting survival in salivary gland cancers. In: McGurk M, Renehan AG (editors). *Controversies in the Management of Salivary Gland Disease.* Second edition. Oxford, UK: Oxford University Press; 2012, p.127-33.
25. Krüll A, Schwarz R, Engenhart R, Huber P, Lessel A, Koppe H, et al. European results in neutron therapy of malignant salivary gland tumors. *Bull Cancer Radiother.* 1996;83 (Suppl): 125-9s.
26. Valstar MH, van den Brekel MW, Smele LE. Interpretation of treatment outcome in the clinically node-negative neck in primary parotid carcinoma: a systematic review of the literature. *Head Neck.* 2010;32(10):1402-11. DOI: 10.1002/hed.21316.
27. Nam SJ, Roh JL, Cho KJ, Choi SH, Nam SY, Kim SY. Risk factors and survival associated with distant metastasis in patients with carcinoma of the salivary gland. *Ann Surg Oncol.* 2016;23(13):4376-83. DOI: 10.1245/s10434-016-5356-3.
28. van Weert S, van der Waal I, Witte BI, Leemans CR, Bloemena E. Histopathological grading of adenoid cystic carcinoma of the head and neck: analysis of currently used grading systems and proposal for a simplified grading scheme. *Oral Oncol.* 2015;51(1):71-6. DOI: 10.1016/j.oraloncology.2014.10.007. Epub 2014 Oct 28.
29. Clauditz TS, Gontarewicz A, Lebok P, Tsourlakis MC, Grob TJ, Munscher A, et al. Epidermal growth factor receptor (EGFR) in salivary gland carcinomas: potentials as therapeutic target. *Oral Oncol.* 2012;48(10):991-6. DOI: 10.1016/j.oraloncology.2012.05.005. Epub 2012 Jun 12.
30. Mifsud MJ, Tanvetyanon T, McCaffrey JC, Otto KJ, Padhya TA, Kish J, et al. Adjuvant radiotherapy versus concurrent chemoradiotherapy for the management of high-risk salivary gland carcinomas. *Head Neck.* 2016;38(11):1628-33. DOI: 10.1002/hed.24484. Epub 2016 Apr 21.
31. Theriault C, Fitzpatrick PJ. Malignant parotid tumors. Prognostic factors and optimum treatment. *Am J Clin Oncol.* 1986;9(6):510-6.
32. Brandwein MS, Ferlito A, Bradley PJ, Hille JJ, Rinaldo A. Diagnosis and classification of salivary neoplasms: pathologic challenges and relevance to clinical outcomes. *Acta Otolaryngol.* 2002;122(7):758-64.
33. Terhaard CH, Lubsen H, Van der Tweel I, Hilgers FJ, Eijkenboom WM, Marres HA, et al. Salivary gland carcinoma: independent prognostic factors for locoregional control, distant metastases, and overall survival: results of the Dutch head and neck oncology cooperative group. *Head Neck.* 2004;26(8):681-92; discussion 692-3.