

## ORIGINAL STUDY

# A paradigm shift: “Defect of the fontanel” instead of “Accessory ostium” and classified nasal septal deformities instead of “septal deviation”

**Ranko Mladina<sup>1</sup>, Neven Skitarelić<sup>2,3</sup>, Cemal Cingi<sup>4</sup>, Nuray Bayar Muluk<sup>5</sup>**

<sup>1</sup>The Board of Surgical Sciences, Croatian Academy of Medical Sciences, Zagreb, Croatia

<sup>2</sup>Department of Health Studies, University of Zadar, Zadar, Croatia

<sup>3</sup>Faculty of Medicine, University of Rijeka, Rijeka, Croatia

<sup>4</sup>ENT Head and Neck Surgery Department, Faculty of Medicine Eskisehir Osmangazi University, Eskisehir, Turkey

<sup>5</sup>ENT Head and Neck Surgery Department, Faculty of Medicine, Kirikkale University, Kirikkale, Turkey

## ABSTRACT

**OBJECTIVES.** The purpose of this article is to highlight some terms which have been ingrained in the rhinosinusology literature.

**MATERIAL AND METHODS.** It regards the term “accessory ostium” and the term “septal deviation”. The well-known and deeply ingrained term “accessory ostium” has been widely used for decades, but essentially it is absolutely incorrect. “Septal deviation” is an inadequate term for the changes of the nasal septum form.

**RESULTS.** From the linguistic point of view, “accessory” means something (or someone) which (or who) helps someone or gives support (to something or someone) in some process. We recommend the use of the term “defect of the fontanel” instead of “accessory ostium”. The use of the term “septal deformity” (from Latin: de forma, meaning the change in the shape) is etymologically much more appropriate. Septal deformities appear in man in several, well defined shapes and, therefore, can be correctly classified. The classification contributes to the further scientific conversations regarding the clinical issues connected to the changes of the nasal septum form.

**CONCLUSION.** The usual term “accessory ostium” suggests almost a normal finding on the lateral nasal wall, but, on the contrary, it clearly signalizes that the respective maxillary sinus is chronically inflamed. The usual term “septal deviation” is not at all specific and only suggests that something is wrong with the position of the nasal septum. It does not at all imply any of the six well known types of septal deformities in man.

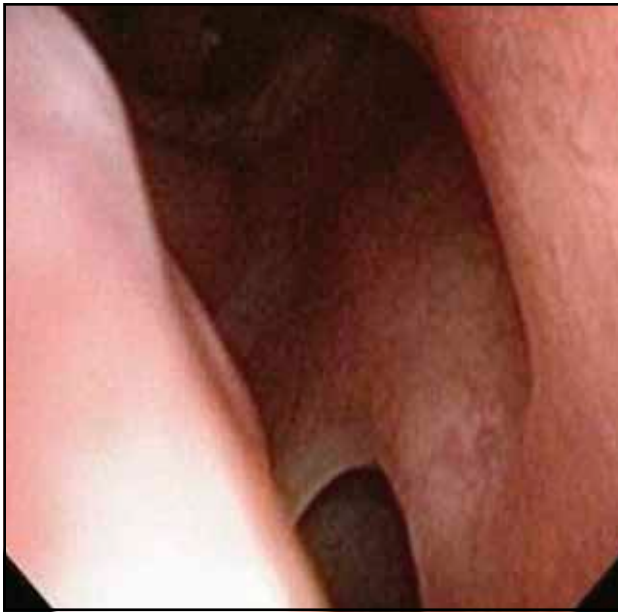**KEYWORDS:** accessory ostium, fontanels, defect, septal deviation, septal deformity.

## INTRODUCTION

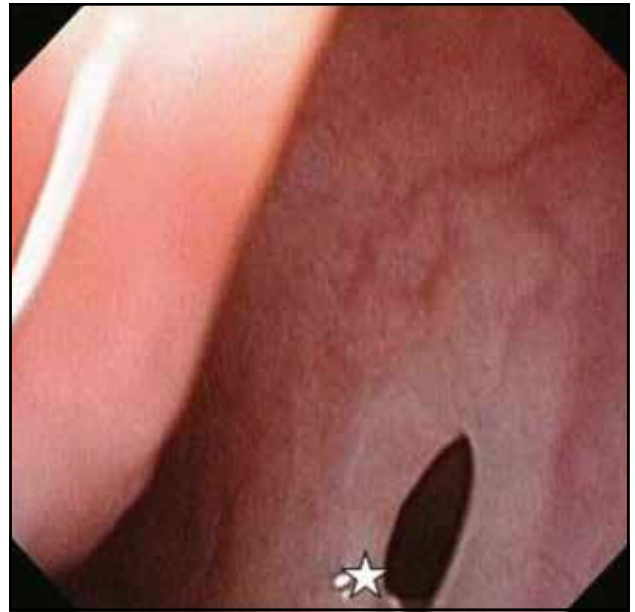
The purpose of this article is to give an opportunity to the younger generation of rhinologists and endoscopic sinus and skull base surgeons all over the globe to think twice about some anatomical terms that were introduced decades ago by venerable pioneers of the endoscopic sinus surgery.

The well-known and deeply ingrained term “accessory ostium” has been widely used for decades,

but essentially it is absolutely incorrect. The pioneers in this field knew a lot about the physiology and pathophysiology of the maxillary sinuses. For example, Hilding described his findings on mucus clearance in detail as early as 1932<sup>1</sup>. He studied and showed precisely, even at that time, using a simple cystoscope, that the mucociliary transport system in the maxillary sinus works well even in the presence of a defect of the lateral nasal wall. At that time, it was already known that mucus coming out through

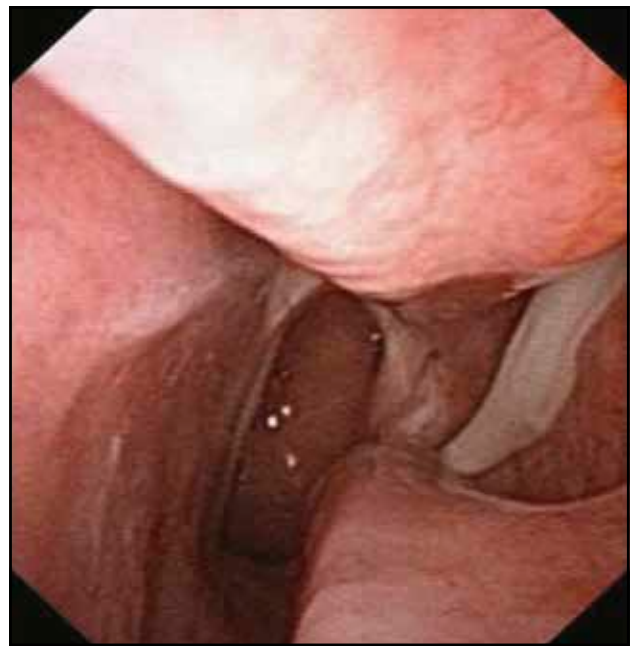

**Figure 1** Close up view to the superior border of the left-sided defect of the posterior fontanel.



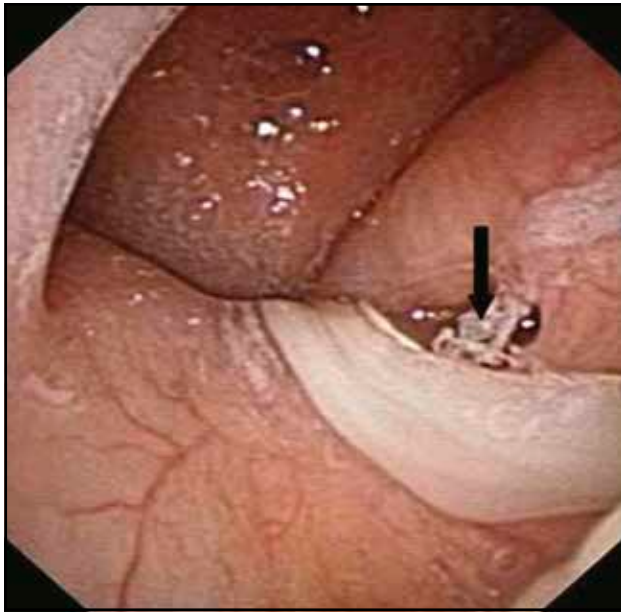**Figure 2** A panoramic view of the entrance to the left ostiomeatal complex. The defect of the fontanel is almost fully presented. One can see a trace of the mucus riding over the inferior edge of the defect (white star).

the natural ostium of the maxillary sinus, on its natural pathway towards the nasopharynx, simply falls into the “trap”, i.e. into the defect of the fontanel. The maxillary sinus mucosa, when functioning normally, expels this unexpected guest through the natural ostium owing to the action of the mucociliary system, thus forming the so-called recirculating mucus. This specific “carrousel” promotes and supports the maintenance of the chronic inflammation of the respective maxillary sinus. Mucosal, or in some cases muco-purulent content, rotates around the tissue bridge that divides the hole in the fontanel and the natural ostium of the maxillary sinus. Sometimes, it can even happen between the inferior antrostomy and middle antrostomy, as has been nicely shown by Kane<sup>2</sup>! Kane clearly showed that the mucus simply overrides the hole in the fontanel and always flows towards the natural ostium as to get out of the sinus itself. Messeklinger discovered, during his observations of the internal anatomy of the nasal lateral wall, that nasal fontanels are elastic, and that they move inward the maxillary sinus during the inspiration through the nose, and vice versa<sup>3</sup>! Fontanels are obviously the “weak points” of the lateral nasal wall since there is no bone between the maxillary sinus mucosa and the lateral nasal mucosal lining. Nobody knows for sure why they exist in humans. We can only speculate that they have been created as possible “emergency exits” for the cases of empyema of the maxillary sinus, when the natural ostium is otherwise already completely blocked. Since in cases of empyema the pressure within the

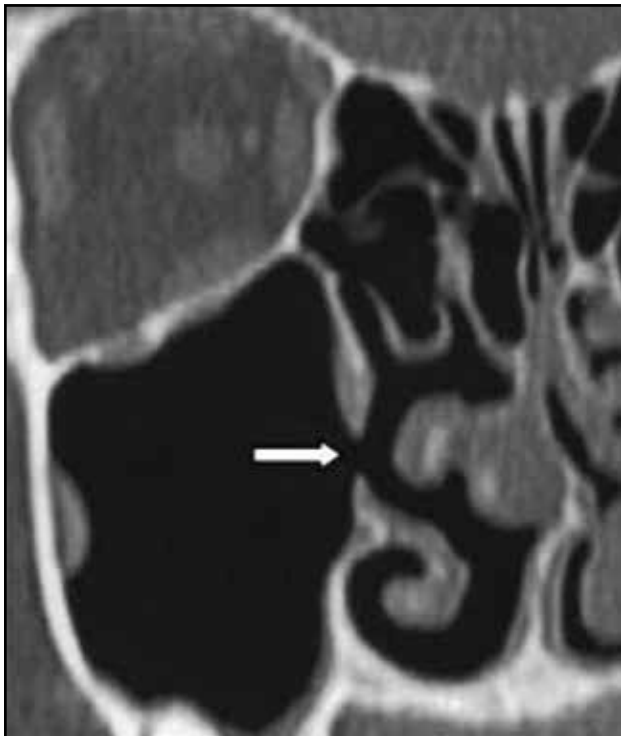


**Figure 3** Endoscopic view of the internal half of the left nasal cavity. The whitish band of mucopurulent mucus flows towards the tail of the left inferior turbinate.

maxillary sinus gradually rises, the only way out is the spontaneous rupture of the weak point, i.e. the fontanel. The same is true for cases which are still treated using an old, fortunately almost abandoned technique: maxillary sinus puncture. The high pressure of the saline during the irrigation can produce the rupture of the gentle fontanel tissue since there



**Figure 4** An endoscopic view of the nasopharyngeal space. The band of mucopurulent discharge flows over the Eustachian tube orifice (black arrow) and continues downwards to the hypopharynx, consequently causing deglutition (postnasal drip).



**Figure 5** The coronal scan of the right maxillary sinus. The defect of the fontanel is obvious (white arrow), but very often remains overlooked and unrecognized both by clinicians and radiologists! The nasal septum shows the deformity to the left (so-called type 5, colloquially termed "septal spur" in literature). Please bear in mind that here we are looking at very deep parts of the nasal cavity (orientate yourself by looking to the orbits: this is the level of retrobulbar space, the optic nerve is perfectly visible!). view of the internal half of the left nasal cavity. The whitish band of mucopurulent mucus flows towards the tail of the left inferior turbinate.

is no chance for saline to come out of the maxillary sinus: the natural ostium has already been blocked by edematous, inflamed mucosa! It seems, however, that the defect in this region, once incurred for whichever reason, never cicatrizes! To the best of our knowledge, nobody so far has clearly explained why this is so.

### **"DEFECT OF THE FONTANEL" INSTEAD OF "ACCESSORY OSTIUM"**

Unfortunately, the defect of the fontanel got the ethereal name "accessory ostium". This was terribly wrong. Why? First of all because, from the linguistic point of view, "accessory" means something (or someone) which (or who) helps someone or gives support (to something or someone) in some process. A hole in the fontanel cannot be helpful to the patient. Today, everybody knows that mucus within the maxillary sinus always, with no exceptions, overrides this opening and flows towards the natural ostium thanks to mucociliary system activity. So, how the defect of the lateral nasal wall could be helpful to the respective maxillary sinus? Quite the opposite! This hole (Figure 1) does not in any respect aid the sinus, so it is far from the definition of "accessory", it is simply a defect in the fontanel. It is, in fact, the onset of what we today call the Two Holes Syndrome (THS)<sup>4</sup>. By the way, it was found that THS was present in more than half of the postnasal drip patients<sup>5</sup>. That is why we do believe that the term "accessory ostium" belongs to the venerable history of the era of functional endoscopic sinus surgery. It seems that it simply is not appropriate any longer. To our mind, finding a defect in the nasal fontanel means the same as finding a hole in the eardrum. A hole in the eardrum undoubtedly means chronic otitis media, whereas a hole in the "nasal eardrum" (the delicate tissue of the fontanel) should mean a kind of help for the maxillary sinus?! In short, to our mind, a hole in the region of the nasal fontanel does not at all belong to a normal endoscopic finding! In our experience it means chronic illness of the respective maxillary sinus (Figures 2, 3, 4, 5). Rhinology as a science desperately needs a paradigm shift: the term "accessory ostium" suggests that there is no need to make any further steps in clarifying the background of such a finding. On the other hand, the term "defect of the fontanel" alerts doctors to think twice and try to discover whether or not it points to the Two Holes Syndrome in that particular patient. Not only rhinosinologists, but also radiologists should become aware of findings shown in Figure 5, where an obvious defect in the region of the fontanel is clearly visible.

## NASAL SEPTAL DEFORMITIES INSTEAD OF "SEPTAL DEVIATION"

Our second objection is the following one: I wonder why the anatomy of the nasal septum has been abandoned in this highly valuable paper. Just to get an idea on the problem, Mladina et al.'s paper<sup>6</sup> and its callout, where septal deformity was named "septal deviation" despite the fact that this is obviously a type 5 nasal septal deformity (in the literature also known as "septal spur"). This deformity, since it is ascendant in the anterior-posterior direction, lies mostly in the horizontal plane and thus is always perfectly presented at coronal CT scans. Radiologists all over the world should be educated regarding this clinical entity and its possible clinical importance<sup>6</sup>. The term "septal deviation" is widely accepted and has been used colloquially for a very long time. But, to our mind, it means nothing to the modern rhinologist. Why? Because, from an etymological point of view, it means a kind of deflection from the middle line or from some other given path and nothing more (from Latin: *de via*, meaning a kind of deflection or misalignment from the expected, normal path). Such a term, once entered into the patient's records, would already lose its meaning even for the same physician after a week or two when the patient comes for a control examination, because the physician will not be able to remember what exactly he or she has found in the patient's nose during the first examination. Moreover, it means nothing particularly to any other physician the patient brings his records to. "Septal deviation" is a general term with no specific meaning. It says nothing about the real appearance of the particular septum! On the other hand, if the deformity is assigned and named properly according to some of the well-known classifications (we use Mladina classification<sup>7</sup> for decades), it will help any physician reviewing the patient's records in the future to know exactly what the septum looked like at the time of the first examination. The classification we use consists of four so-called vertical deformities, and two horizontal deformities. The seventh type (so-called "Passali deformity") is a combination of the previous types. This type is called "crumpled septum" because of the variety of changes in its shape. According to the most recent publications, for example "International Consensus Statement on Allergy and Rhinology: Rhinosinusitis", published as a supplement of the International Forum of Allergology and Rhinology (IFAR)<sup>8</sup>, this type as well as type 3 ("C" or "reverse C" shaped septum) play the most important role in the development of chronic rhinosinusitis!

Furthermore, to know the types of nasal septal deformities could be very helpful also in the domain

of forensic medicine since types 5 and 6 have been clinically proved to be inherited. That means that both of them have nothing to do with whichever trauma against the nose. In case the rhinologist who is familiar with types 5 or 6 is summoned to court as an expert witness, he or she will be able to categorically state that the certain trauma against the nose did not produce those types since they are inherited and this can be easily proved in every single case (examination of the nose of the closest members of the family).

In addition, this way of recording nasal septal deformities gives us hope for the future breakthroughs in this field of medicine. We do believe that rhinologists can contribute to the future medicine: prevention instead of treating. We have already published on the hypothetical possibilities to prevent Acute Coronary Syndrome (ACS) by means of the most recent molecular biology techniques by the removal of deletions in the chromosomes, which seems to be responsible for the onset of ACS<sup>9,10</sup> ("knocking out of the bad guy") or to forever prevent the genesis of the cleft lip/palate in future newborns<sup>11-14</sup>.

## OUR SUGGESTIONS

1. The "defect of the fontanel" certainly means chronic inflammation of the respective maxillary sinus and therefore cannot be named "accessory ostium" any longer;

2. The term septal deviation means nothing per se, but septal deformity means that the nasal septum has some specific form. There are six essential types of nasal septal deformities in man, two of them having been proven as dominantly inherited. Those which are inherited could be a part of some, so far unknown, syndrome which includes the predilection to the onset of acute coronary syndrome or the onset of the congenital malformations like the cleft lip/palate. Further investigations in this field are required. Any of the further investigations will have to be based on some of the precise and clear septal deformities classifications as to make it possible for all interested scientists to join the investigations and, maybe, get a good result in the future.

## WHAT IS THE EVIDENCE OUR SUGGESTIONS ARE BASED ON

### Defect of the fontanel

The evidence for this hypothesis lays in the fact that the defect of the fontanel was found in more than half of all patients suffering from postnasal drip<sup>5</sup>. The fact that postnasal drip in such cases dis-



appears after performing middle antrotomy, i.e. the removal of the tissue bridge between the natural ostium of the maxillary sinus and the fontanel itself, speaks in favour of that.

### Septal deformity

There is a "must" in science: the investigations must be repeatable. Therefore, the measurements must be performed in the clear way, using the same tools etc. Statistics are essential as to measure the validity of some new results. General terms as "septal deviation" are not at all objective neither precise enough to be a reliable component of any scientific research regarding this part of the nose.

## CONCLUSIONS

The usual term "accessory ostium" suggests almost a normal finding on the lateral nasal wall, but, on the contrary, it clearly signalizes that the respective maxillary sinus is chronically inflamed.

The usual term "septal deviation" is not at all specific and only suggests that something is wrong with the position of the nasal septum. It does not at all imply any of the six well known types of septal deformities in man.

**Ethics approval:** There was no need to have the Ethical Committee Approval.

**Acknowledgements:** "With the exception of data collection, the preparation of this paper, including design and planning, was supported by the Continuous Education and Scientific Research Association." There is no financial support. There is only scientific support."

**Financial disclaimer:** There is no financial disclosure of the authors.

**Conflict of interest:** The authors report no conflicts of interest. The authors alone are responsible for the content and writing of the paper.

### Contribution of authors:

**Ranko Mladina:** Planning, designing, data collection, literature survey, writing.

**Neven Skitarelić:** Planning, designing, literature survey.

**Cemal Cingi:** Planning, designing, literature survey.

**Nuray Bayar Muluk:** Planning, designing, literature survey.

## REFERENCES

1. Hilding A. Physiology of drainage of nasal mucus. Experimental work on accessory sinuses. *Am J Physiol.* 1932;100:664-70. DOI: <https://doi.org/10.1152/ajp:egacy.1932.100.3.664>.
2. Kane KJ. [Recirculation of mucus as a cause of persistent sinusitis.](#) *Am J Rhinol.* 1997;11(5):361-9.
3. Messerklinger W. Endoscopy of the nose. Urban & Schwarzenberg; 1978.
4. Mladina R, Vuković K, Poje G. [The two holes syndrome.](#) *Am J Rhinol Allergy.* 2009;23(6):602-4. DOI: 10.2500/ajra.2009.23.3375.
5. Mladina R, Skitarelić N, Casale M. Two holes syndrome (THS) is present in more than half of the postnasal drip patients? *Acta Otolaryngol.* 2010;130(11):1274-7. DOI: 10.3109/00016489.2010.480983.
6. Mladina R, Skitarelić N, Poje G, Šubarić M. Clinical implications of nasal septal deformities. *Balkan Med J.* 2015;32(2):137-46. DOI: 10.5152/balkanmedj.2015.159957. Epub 2015 Apr 1.
7. Mladina R. The role of maxillar morphology in the development of pathological septal deformities. *Rhinology.* 1987;25(3):199-205.
8. Orlandi RR, Kingdom TT, Hwang PH, Smith TL, Alt JA, Baroody FM, et al. International Consensus Statement on Allergy and Rhinology: Rhinosinusitis. *Int Forum Allergy Rhinol.* 2016;6 Suppl 1:S22-209. DOI: 10.1002/alr.21695.
9. Mladina R, Skitarelić N, Carić T, Raguž M. Type 5 and 6 nasal septal deformities: Could we predict and prevent acute coronary syndrome attacks in the future? *Med Hypotheses.* 2015;85(5):640-4. DOI: 10.1016/j.mehy.2015.08.001.
10. Liang P, Xu Y, Zhang X, Ding C, Huang R, Zhang Z, et al. CRISPR/Cas9-mediated gene editing in human triploid zygotes. *Protein Cell.* 2015;6(5):363-72. DOI: <http://dx.doi.org/10.1007/s13238-015-0153-5>.
11. Mladina R, Skitarelić NB, Skitarelić NP. Could we prevent unilateral cleft lip/palate in the future? *Medical Hypotheses.* 2009;73(4):601-3. DOI: 10.1016/j.mehy.2009.05.028. Epub 2009 Jun 25.
12. Mladina R, Ostojić D, Koželj V, Heinzel B, Bastaić LJ. Pathological septal deformities in cleft palate children. *L'Otorinolaryngologia Pediatrica.* 1997;2:3:75-80.
13. Mladina R, Šubarić M. Are some septal deformities inherited? Type 6 revisited. *Int J Pediatr Otorhinolaryngol.* 2003;67(12):1291-4.
14. Mladina R, Skitarelić N, Vuković K, Šubarić M, Carić T, Orihovac Z. Unilateral cleft lip/palate children: the incidence of type 6 septal deformities in their parents. *J Craniomaxillofac Surg.* 2008;36(6):335-40. DOI: 10.1016/j.jcms.2008.03.003. Epub 2008 May 2.