

CASE REPORT

Odontogenic suppurative rhinosinusitis with oculo-orbital and cerebral complications - case series

Daniela Vrinceanu¹, Mihai Dumitru², Ioana Eftime¹, Madalina Ilie¹, Adrian Stefan¹, Bogdan Banica¹, Daniel Mihai Teleanu³, Alina Popa-Cherecheanu⁴

¹ENT Department, Emergency University Hospital Bucharest, Bucharest, Romania

²Anatomy Department, "Carol Davila" University of Medicine and Pharmacy, Bucharest, Romania

³Neurosurgery Department, Emergency University Hospital Bucharest, "Carol Davila" University of Medicine and Pharmacy, Bucharest, Romania

⁴Ophthalmology Department, Emergency University Hospital Bucharest, "Carol Davila" University of Medicine and Pharmacy, Bucharest, Romania

ABSTRACT

BACKGROUND. Odontogenic rhinosinusal suppurations have a high potential for major ocular-orbital and cerebral complications because of the presence of anaerobic bacteria flora, with continuity, contiguity and haematogenous propagation mechanisms. This pathology is often diagnosed in other departments than ENT such as ophthalmology, neurosurgery or OMF surgery.

MATERIAL AND METHODS. We present three clinical cases of odontogenic rhinosinusal suppurations with major complications: a 36-year-old patient with odontogenic pansinusitis complicated with orbital phlegmon and cerebral frontal lobe abscess; a 19-year-old patient with complicated maxillary-ethmoidal-frontal sinusitis complicated with frontal subdural empyema and frontal bone osteomyelitis (with a history of craniofacial trauma one year before); a 66-year-old patient with odontogenic maxillary-ethmoidal sinusitis complicated with orbital apex syndrome.

RESULTS. The treatment was surgical, by external approach, with endoscopic nasal control, in interdisciplinary teams. We have associated massive antibiotic therapy. Surgical drainage for complicated rhinosinusitis should be done in emergency, within the first 24 hours after admission, according to guidelines. The bacteriological examination for aerobic and anaerobic flora can guide the diagnosis - two cases associated maxillo-ethmoidal aspergilloma lesions. The evolution of the cases was favourable.

CONCLUSION. Interdisciplinary teams have successfully solved these complicated odontogenic rhinosinusal suppurations. Two of the cases were admitted and cured within 2 weeks, in the context of very hot weather, which exacerbated dormant dental infections.

KEYWORDS: odontogenic suppuration, surgery, complications, multidisciplinary team.

INTRODUCTION

Odontogenic suppurative rhinosinusitis (RS) has a high potential for major ocular-orbital and cerebral complications¹. One of the major factors leading to RS is aggression to the maxillo-ethmoidal contact zone². Another factor is prolongation of presence of anaerobic bacteria flora after acute RS³. Also the anaerobiosis favours the association with aspergilloma⁴. The spreading mecha-

nisms leading to major complications are through continuity, contiguity and haematogenous spreading⁵. There are three possible major complications of RS: endocranial, oculo-orbital and broncho-pulmonary⁶. Among major endocranial complications are meningitis, subdural empyema, cerebral abscess (frontal lobe), cavernous sinus thrombophlebitis and longitudinal sinus thrombophlebitis⁷. Major oculo-orbital complications are classified as: orbital preseptal cellulitis - white edema, the only one without surgical indication; orbital cellulitis - red

edema with visual acuity preserved; orbital periostitis; subperiosteal abscess; orbital phlegmon – amaurosis in high feverish context; orbital apex syndrome (Rollet) - affecting the vessels and nerves from upper orbital fissure and the optical channel; retrobulbar optic neuritis⁸.

CASE REPORT

CASE 1

A 34-year-old male patient with upper affected maxillary teeth (25 and 26) for at least 3 months, with fetid rhinorrhea for 6 months, was admitted with left maxillary pain, left temporal-parietal headache and fever. Subsequently he was transferred from the Ophthalmology Department with left red eye, followed 3 days after nose blowing by left painful exophthalmia. Visually, he perceived hand motion with the affected eye. Also, the patient presented: WBC (white blood cell count) = 20,400/mm³; fibrinogen = 971 mg%; ESR (erythrocyte sedimentation rate) = 94 mm/h; RCP (reactive C protein) = 56.57 mg/dl. The cranio-facial computed tomography revealed a cerebral abscess in the left frontal lobe, 13 mm in diameter, with a thin capsule (Figure 1).

In this case, the possible mechanisms of spreading for the suppurative process were through continuity (oro-antral fistula, ethmoidal ceiling) and contiguity (orbital ceiling fissure).

The surgical approach involved radical Caldwell-Luc maxillary sinus cure, with transantral ethmoidectomy under nasal endoscopic control. Further, the extraction of 26, 28 teeth with oro-antral fistula closure (via vestibuloplasty) were performed. A broad drainage of the upper left palpebral abscess was the next step. An upper orbitotomy associated with upper and internal orbital quadrants abscess drainage was made under the ophthalmologist's supervision. We also adopted a conservative attitude for the cerebral abscess, which was smaller than 1.5cm (Figure 2).

The bacteriology result confirmed the presence of an anaerobic flora (gram positive cocci), aerobic flora (coagulase-negative staphylococcus) and the histopathology demonstrated aspergilloma development.

Associated medical treatment was complex: Meropenem 3 g/day + Metronidazole 2 g/day (7 days); followed by Ceftriaxone 4 g/day + Vancomycin 2 g/day (2 weeks); Fluconazole 400 mg/d (7 days) with Corticotherapy IV (intravenous) Dexamethasone 2 amp/day (2 weeks), 1 amp/day (1 week), along with Group B vitamin therapy (3 weeks).

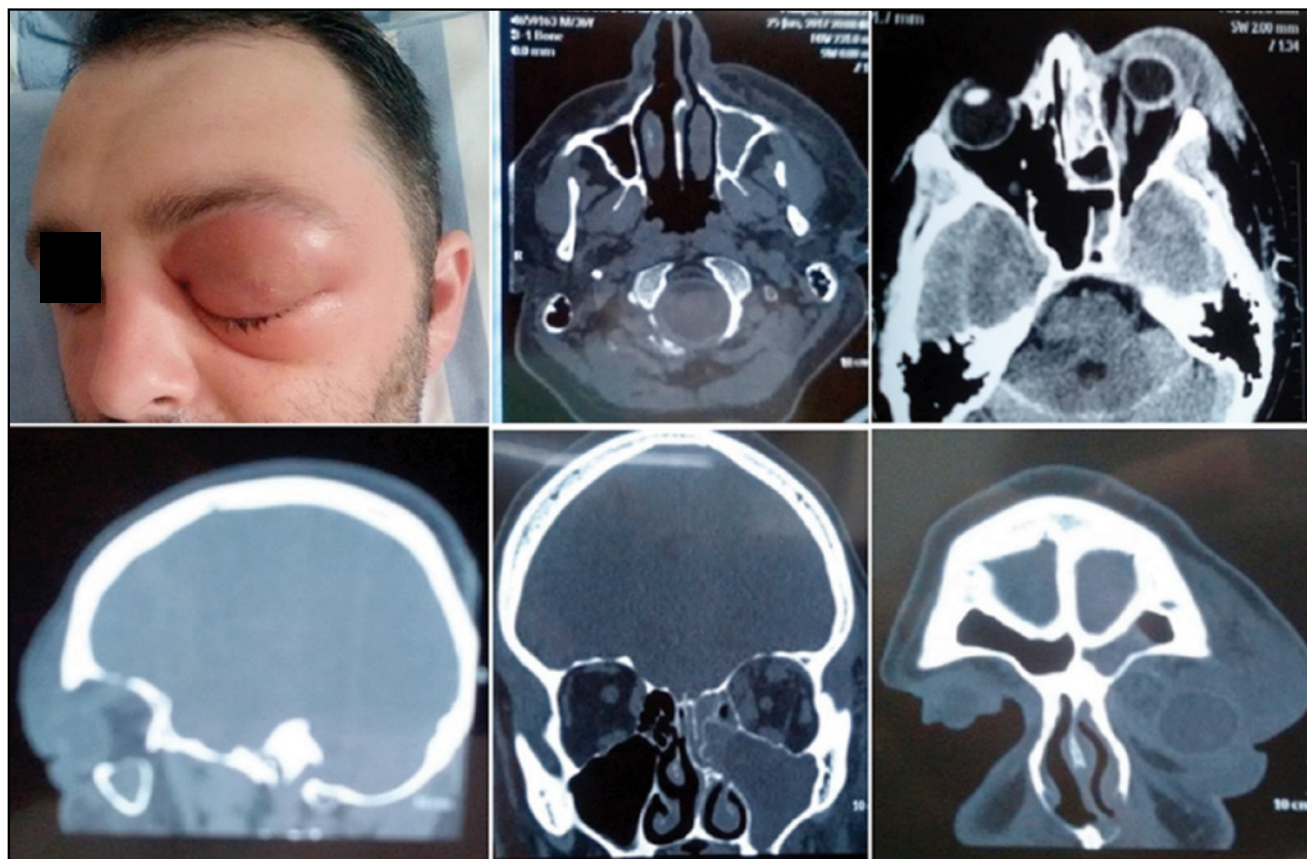


Figure 1 Clinical aspect and CT findings for Case 1.

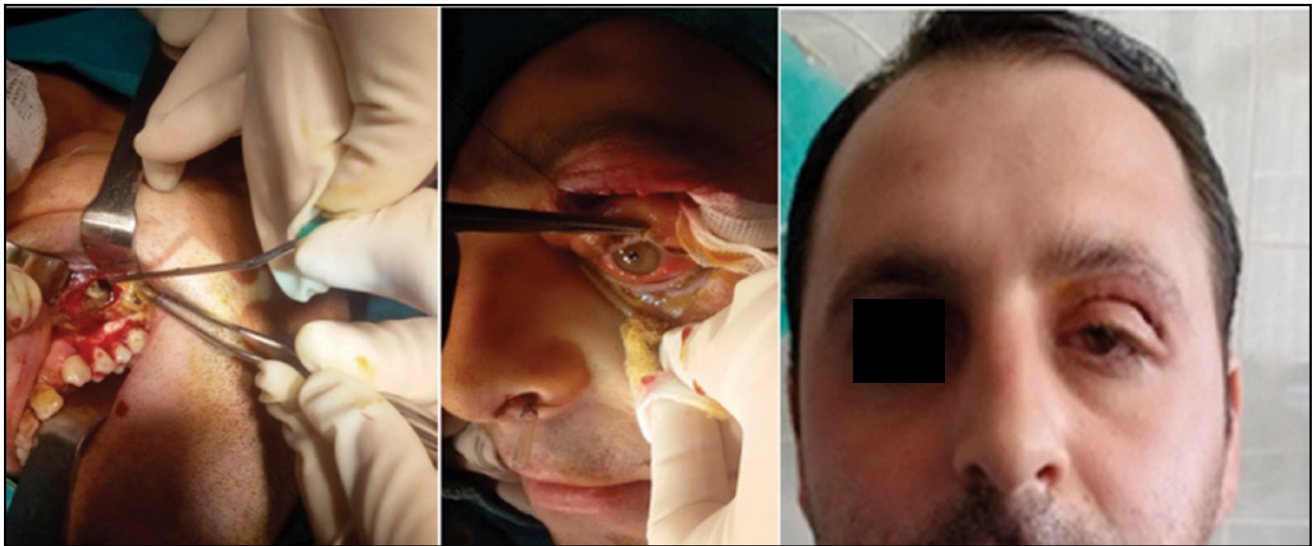

Figure 2 Surgical aspect and post recovery aspect for Case 1.

CASE 2

Male patient aged 19, with a history of cranio-facial trauma 1 year before, presented with suppurative left pansinusitis and affected teeth (24, 25, 26) leading to left eye preseptal orbital cellulitis and epicranial

fronto-temporal abscess. On the CT scan, a left frontal subdural empyema could be identified (Figure 3). The patient was transferred from the Neurosurgery Department with normal vision. Blood tests revealed: WBC = 16,400 / mm³; fibrinogen = 465.64mg%; ESR = 59 mm / h and RCP = 11mg%.

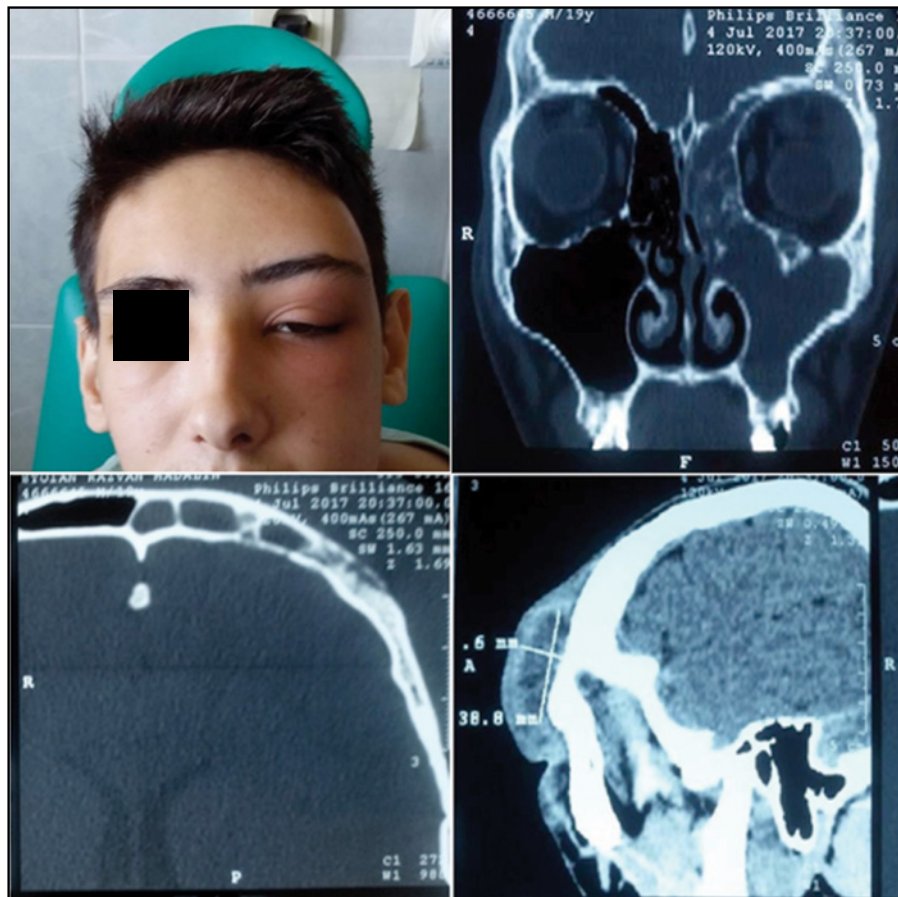


Figure 3 Clinical aspect and CT imaging for Case 2.

Bacteriology results showed anaerobic flora (gram-negative bacillus), aerobic flora (staphylococcus aureus). The mechanism of spreading for the suppurative process could be through continuity by oro-antral fistula, posterior and anterior wall of the frontal sinus.

The patient associated cerebrospinal fluid leak for a few days which required decompressive lumbar punctures.

On the CT scan there was no left subdural empyema and, apparently, the posterior wall of the frontal sinus was intact.

The surgical treatment consisted in radical Caldwell-Luc left maxillary sinus cure, with left transantral ethmoidectomy under nasal endoscopic control. Our OMF surgeon extracted 24-25-26 teeth with oro-antral fistula closure (vestibuloplasty). Moreover, for the drainage of the left fronto-temporal epicranial abscess we performed an Ogston-Luc incision (Figure 4).

Associated medical treatment used: Meropenem 6 g/day + Metronidazole 2 g/day preoperatively, Ceftriaxone 4 g/day + Vancomycin 2 g/day (3 weeks); with Corticotherapy IV Dexamethasone 2 amp/day (2 weeks), 1 amp/day (1 week) along with Group B vitamin therapy (3 weeks) with a total antibiotherapy for 3 weeks.

These first two cases were admitted and cured within 2 weeks, in the context of a very hot weather, which exacerbated dormant dental infections.

CASE 3

We present the case of a diabetic female, aged 66, with recent history of incisor 22 extraction and edentulous on the left hemimaxillary. Three hours after extraction the patient accused painful left exophthalmia, chemosis and fever. This patient also presented a history of left fetid rhinorrhea for 6 months. The case was transferred from the Ophthalmology Department with no light perception on the left eye, associated

ophthalmoplegia (III, IV, and VI), loss of pupillary reflex, neuralgia and hypoesthesia VI.

Blood workup showed: WBC = 14.400/mm³, fibrinogen = 553 mg%, ESR = 50 mm/h. Therefore, the patient developed left eye orbital cellulitis and orbital apex syndrome with imminent cavernous sinus thrombosis. Imaging underlined the presence of a left suppurative maxillo-ethmoidal rhinosinusitis (Figure 5).

The most probable mechanism of the suppurative process spreading was hematogenous, after traumatic teeth extraction. Emergency lateral orbitotomy revealed no pus and thus we maintained the anticoagulant therapy with LMWH (Low Molecular Weight Heparin). We continued with radical Caldwell-Luc left maxillary sinus surgical cure associated with left transantral ethmoidectomy under nasal endoscopic control (Figure 6). Bacteriology exam revealed anaerobic flora with gram-positive cocci and the histopathologic diagnosis of aspergilloma.

Associated medical treatment implied Ceftriaxone 2 g /day plus Aminoglycoside 160 mg /day plus Metronidazole 2 g/day (3 weeks), Fluconazole 400 mg/day (1 week), IV corticotherapy -Dexamethasone 2 amp/day (2 weeks), 1 amp/day (1 week), with supplementary Group B vitamin therapy (3 weeks) and LMWH anticoagulant treatment. Antibiotherapy was maintained 3 weeks and anticoagulant therapy for 3 months at the neurologist's indication.

DISCUSSIONS

Surgical drainage for complicated rhinosinusitis should be done in emergency, within the first 24 hours after admission, after the initiation of antibiotherapy. Moreover, surgical treatment should be initiated in less than 6 hours if visual impairment is associated⁹.

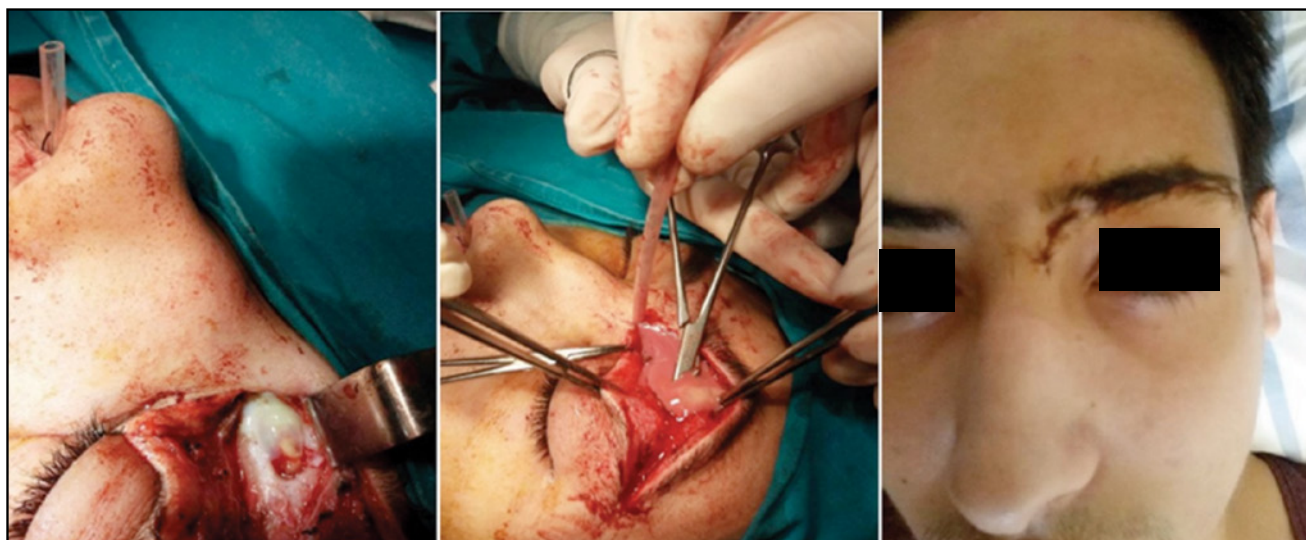


Figure 4 Surgical approach and recovery aspect for Case 2.

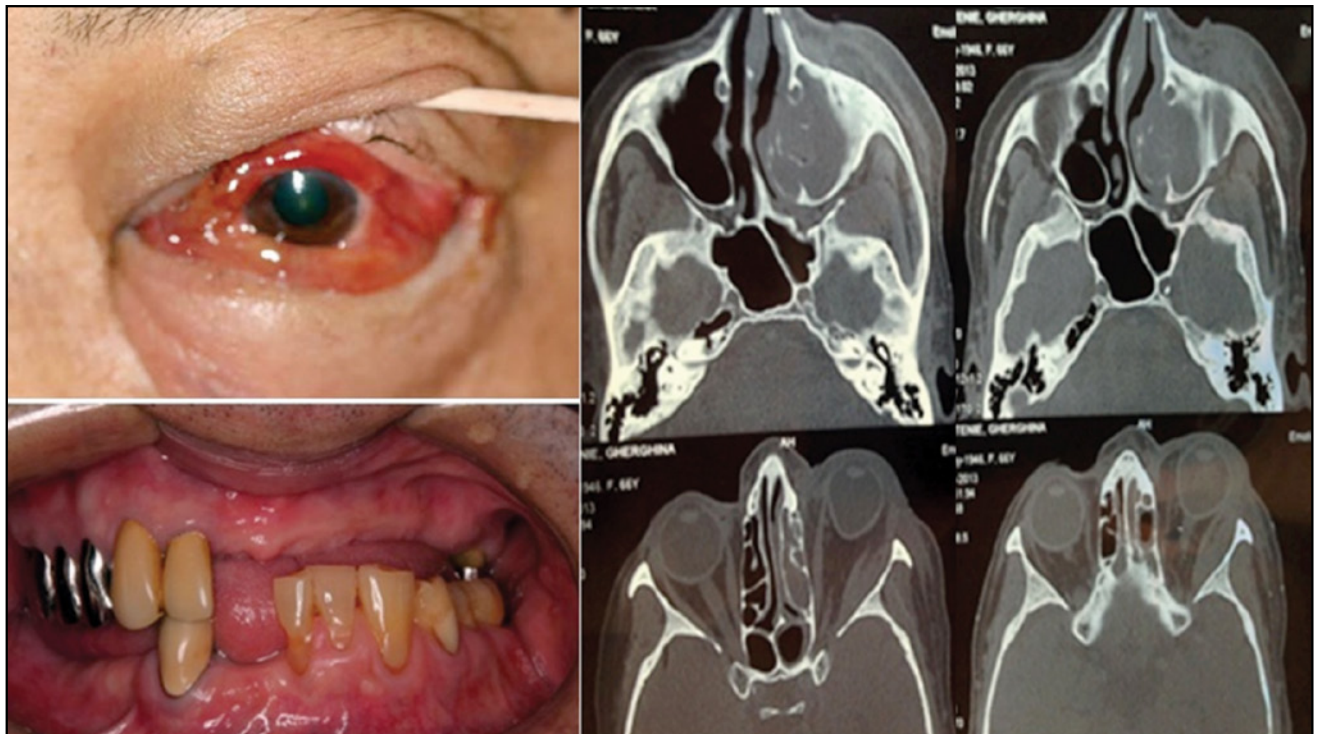


Figure 5 Clinical aspect and CT findings in Case 3.

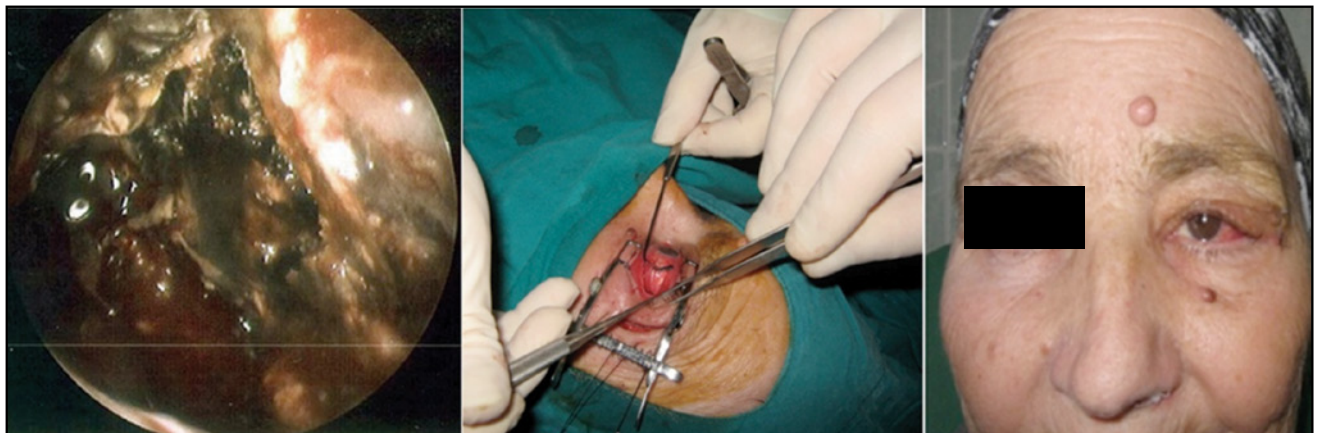


Figure 6 Endoscopic intraoperative view, surgical approach and clinical recovery for Case 3.

We propose an interdisciplinary team therapeutic protocol - ENT surgeon, OMF surgeon, neurosurgeon, ophthalmologist and anaesthesiologist. It is mandatory to eradicate the affected sinus and teeth¹⁰. Massive antibiotherapy penetrating the hematoencephalic barrier according to guidelines should be maintained for 3-4 weeks with a preoperative mandatory dose¹¹. Another major indication is for corticotherapy, pre and postoperatively, as aggressive as possible¹².

External Caldwell-Luc approach allows complete lesion control with oroantral fistula closure via vestibuloplasty¹³. During these procedures, the use of atraumatic burr bone approach will avoid additional septic dissemination and haemostasis needs to be very rigorous¹⁴.

CONCLUSIONS

An interdisciplinary team joining the ophthalmology surgeon and the neurosurgeon, depending on complications, is a requisite for successfully managing these complex cases. All three cases were transferred from other departments (Ophthalmology, Neurosurgery).

Surgery has as main objectives the drainage of the affected sinus and extraction of the affected teeth. Ethmoidal lesions should be approached with the aim of surgical radicality putting pressure on inexperienced ENT surgeons.

The bacteriological examination for aerobic and anaerobic flora should be done intraoperatively. An-

aerobic flora is always present in odontogenic RS and the associated antibiotherapy must include the anaerobic flora. Proof to this aspect is the fact that two of the presented cases associated maxillo-ethmoidal aspergilloma lesions.

Conflict of interest: The authors have no conflict of interest.

Contribution of authors: All authors have equally contributed to this work.

REFERENCES

1. Barshak MB, Durand ML. The role of infection and antibiotics in chronic rhinosinusitis. *Laryngoscope Investig Otolaryngol*. 2017;2(1):36-42. DOI: 10.1002/liv.2.61. eCollection 2017 Feb.
2. Jiam NT, Goldberg AN, Murr AH, Pletcher SD. Surgical treatment of chronic rhinosinusitis after sinus lift. *Am J Rhinol Allergy*. 2017;31(4):271-5. DOI: 10.2500/ajra.2017.31.4451.
3. Aring AM, Chan MM. Current concepts in adult acute rhinosinusitis. *Am Fam Physician*. 2016;94(2):97-105.
4. Gavito-Higuera J, Mullins CB, Ramos-Duran L, Sandoval H, Akle N, Figueroa R. Sinonasal Fungal Infections and Complications: A Pictorial Review. *J Clin Imaging Sci*. 2016;6:23. DOI: 10.4103/2156-7514.184010. eCollection 2016.
5. Vashishth A. Extensive allergic fungal rhinosinusitis: ophthalmic and skull base complications. *Indian J Otolaryngol Head Neck Surg*. 2015;67(3):227-33. DOI: 10.1007/s12070-014-0771-x. Epub 2014 Aug 26.
6. Guan WJ, Gao YH, Li HM, Yuan JJ, Chen RC, Zhong NS. Impacts of co-existing chronic rhinosinusitis on disease severity and risks of exacerbations in chinese adults with bronchiectasis. *PLoS One*. 2015;10(9):e0137348. DOI: 10.1371/journal.pone.0137348. eCollection 2015.
7. Dankbaar JW, van Bommel AJM, Pameijer FA. Imaging findings of the orbital and intracranial complications of acute bacterial rhinosinusitis. *Insights Imaging*. 2015;6(5):509-18. DOI: 10.1007/s13244-015-0424-y. Epub 2015 Aug 8.
8. Singh SK, James E, Sabarigirish K, Swami H, Sood T. Bilateral orbital complications of paediatric rhinosinusitis. *Med J Armed Forces India*. 2014;70(1):68-72. DOI: 10.1016/j.mjafi.2012.11.015. Epub 2013 Feb 23.
9. Torretta S, Marchisio P, Gaffuri M, Capaccio P, Esposito S, Pignataro L. Step-by-step iconographic description of a prolonged but still favourable course of orbital cellulitis in a child with acute rhinosinusitis: an iconographic case study. *Ital J Pediatr*. 2014;40:25. DOI: 10.1186/1824-7288-40-25.
10. Noleto JW, Prado R, Rocha JF, DaCosta MA, Barbosa CU, Toscano MD. Intranasal inverted tooth: a rare cause of a persistent rhinosinusitis. *Indian J Dent Res*. 2013;24(6):762-4. DOI: 10.4103/0970-9290.127630.
11. Lee JT, Brunworth J, Garg R, Shibuya T, Keschner DB, Vanefsky M, et al. Intracranial mucocoele formation in the context of longstanding chronic rhinosinusitis: A clinicopathologic series and literature review. *Allergy Rhinol (Providence)*. 2013;4(3):e166-75. DOI: 10.2500/ar.2013.4.0064.
12. Dutta M, Ghatak S. Acute Exacerbation of Chronic Rhinosinusitis (AECRS) with Orbital Complications in an Atrophic Rhinitis Patient: A Mere Co-incidence? *J Clin Diagn Res*. 2013;7(12):2973-5. DOI: 10.7860/JCDR/2013/6461.3814. Epub 2013 Dec 15.
13. Piroonchai P, Thanaviratananich S. Invasive fungal rhinosinusitis versus bacterial rhinosinusitis with orbital complications: a case-control study. *Scientific World Journal*. 2013;2013:453297. DOI: 10.1155/2013/453297. eCollection 2013.
14. Hosemann W, Draf C. Danger points, complications and medico-legal aspects in endoscopic sinus surgery. *GMS Curr Top Otorhinolaryngol Head Neck Surg*. 2013;12:Doc06. DOI: 10.3205/cto000098.