

## ORIGINAL STUDY

# Crista galli sinusitis – a radiological impression or a real clinical entity

**Claudiu Manea<sup>1,2</sup>, Ranko Mladina<sup>3</sup>**<sup>1</sup>CESITO Centre, “Sfanta Maria” Hospital, Bucharest, Romania<sup>2</sup>“Carol Davila” University of Medicine and Pharmacy, Bucharest, Romania<sup>3</sup>ENT Department, Clinical Hospital Center Zagreb, Croatia**ABSTRACT**

**BACKGROUND.** Crista galli is an anatomical structure localized in the midline, that derives from the ethmoid bone, with a compact bone structure, sometimes pneumatized. The connection between the pneumatized crista galli and the adjacent paranasal structures is usually performed through an opening similar with a sinus ostium.

**MATERIAL AND METHODS.** We performed a retrospective clinical study about the incidence of the pneumatization of crista galli in 196 patients with chronic sinusitis. We evaluated the degree of pneumatization and the drainage pathways of crista galli, trying to correlate the radiological findings with the symptomatology of the patients with crista galli “sinusitis”.

**RESULTS.** Pneumatization of crista galli was found in 30.1% of cases. From 59 patients with chronic rhinosinusitis and pneumatized crista galli, 66.4% had no opacification, 23.7% various degrees of opacification and 11.9% showed complete opacification. The presence of an opening of the pneumatized crista galli into surrounding air-cells was found in 16.98% of the patients. Headache was encountered in 76.2% of the patients with CRS and pneumatized crista galli sinusitis.

**CONCLUSION.** When analyzing a CT scan of a patient with CRS, we should also take into consideration the pneumatization of crista galli, which has a high variability. Most of the patients included in our study had also a certain degree of opacification of the pneumatized crista galli. Headache had a higher incidence in patients with crista galli inflammation than in CRS patients who showed no pneumatization or opacification of the crista galli (76.2% versus 60.5% in “simple” CRS patients).

**KEYWORDS:** crista galli, pneumatization, sinusitis

**INTRODUCTION**

Crista galli is an anatomical structure localized in the midline above the cribriform plate, having a posterior border, thin and slightly curved, with the falx cerebri attached to it, and a much thicker and shorter anterior border, attaching to the frontal bone by two small alae, taking part of the formation of the foramen caecum<sup>1</sup>. From the embryological point of view, it derives from the ethmoid bone<sup>2</sup>.

Crista galli usually is a compact bone, but it can be pneumatized as well. The reported incidence of pneumatized crista galli varies a lot according to different authors, from 3-37.5%<sup>3-6</sup>. There are several theories explaining the pneumatization of crista galli, but the most widely accepted are two: the first that advocates pneumatization from the ethmoid sinus and another one that advocates crista galli pneumatization from the frontal sinus<sup>7</sup>. The communication between the

pneumatized crista galli and the adjacent paranasal structures usually happens through an opening similar to other sinus ostia, opened in most of the cases in the frontal sinus cavity<sup>6</sup>. In case of ostial blockage, an inflammatory – infectious response, similar to a regular rhinosinusitis, can occur. Socher et al.<sup>7</sup> reported 3 clinical cases in which chronic headache were attributed to the inflammatory process within the pneumatized crista galli. They succeeded to endoscopically remove the inflammatory changed mucosa within the pneumatized crista galli and the outcomes in all three patients have been excellent!

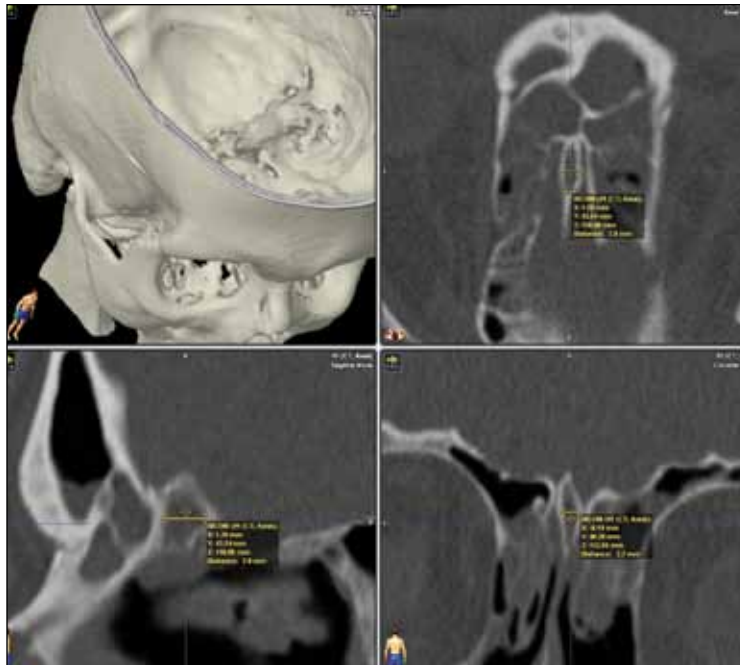In the present study, we analyzed the incidence of the pneumatization of crista galli in patients with chronic sinusitis, the degree of pneumatization and the drainage pathways of crista galli, trying to correlate the radiological findings with the symptomatology of the patients with crista galli “sinusitis”.

## MATERIAL AND METHODS

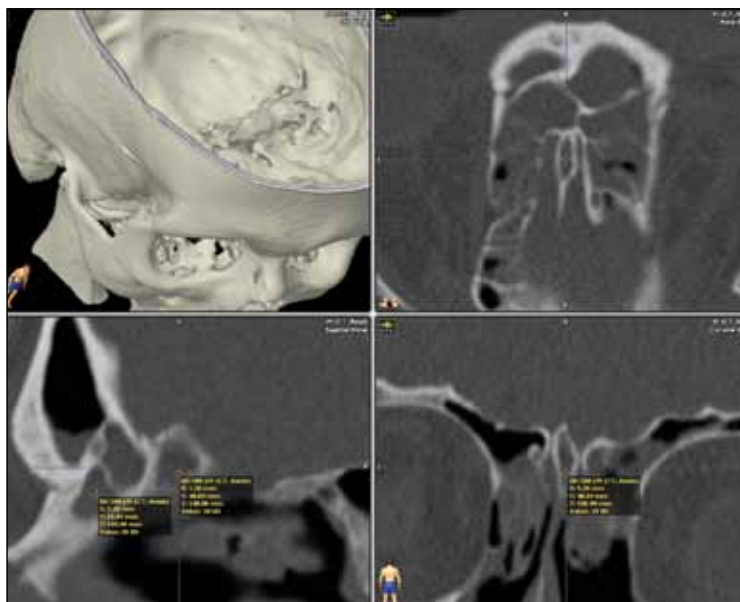We performed a retrospective clinical study on 196 CRS patients admitted in the ENT Department, "Sfanta Maria" Hospital, between January 2015 and July 2015. All patients underwent CT-scan in axial planes, with slice thickness under 1 mm, using a bone window of 2500-3400 rads. For the purpose of crista galli radiological measurements, the preoperative image guidance CT scans of the paranasal sinuses for each patient were loaded into BrainLab iPlan computer station

(BrainLab AG, Germany) using iPlan ENT 3.0.1 software. We reviewed the axial CT scan slices as well as sagittal and coronal reconstruction images, recording the maximal antero-posterior, cranio-caudal and latero-lateral dimensions of the crista galli (Figure 1).

In order to differentiate between spongy bone and edematous mucosa inside the pneumatized crista galli, we measured the radiological computer tomographic coefficient of tissue density using Hounsfield unit (HU) scale (Figure 2). All the measurements were performed by the same author for consistency of the results.



**Figure 1** Measurements of a pneumatized crista galli in axial, sagittal and coronal planes using iPlan ENT 3.0.1 software



**Figure 2** Measurement of tissue density using Hounsfield unit scale in a patient with an opacified pneumatized crista galli on sagittal and coronal planes CT scan

The degree of opacification of the pneumatized crista galli was measured. The results have been classified as follows: no opacification (Figure 3), partial opacification (mucosal thickening more than 1mm, Figure 4) and complete opacification (Figure 5).

We also did our best to identify the drainage pathway of the pneumatized crista galli. The presence of the headache was recorded from the patients' observational charts.

## RESULTS

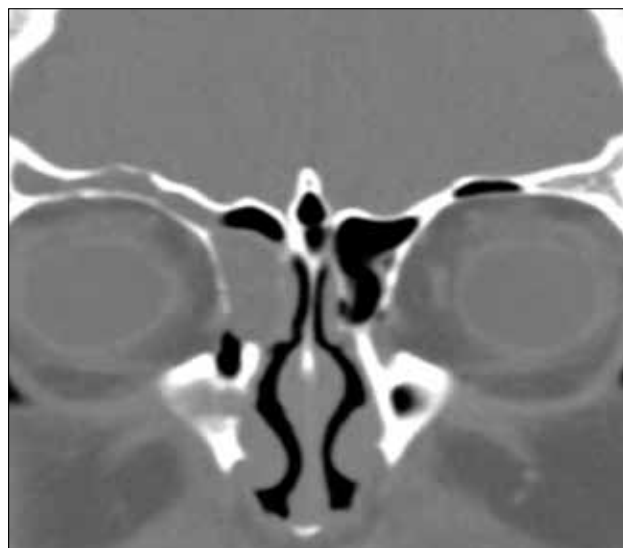
Pneumatization of crista galli was found in 59 out of 196 patients with chronic sinusitis, representing 30.1% of cases. 32 patients were females and 27 males (fe-

males/males ratio=1.18/1). The age ranged from 18 to 81 years, with a median of 39.6 years.

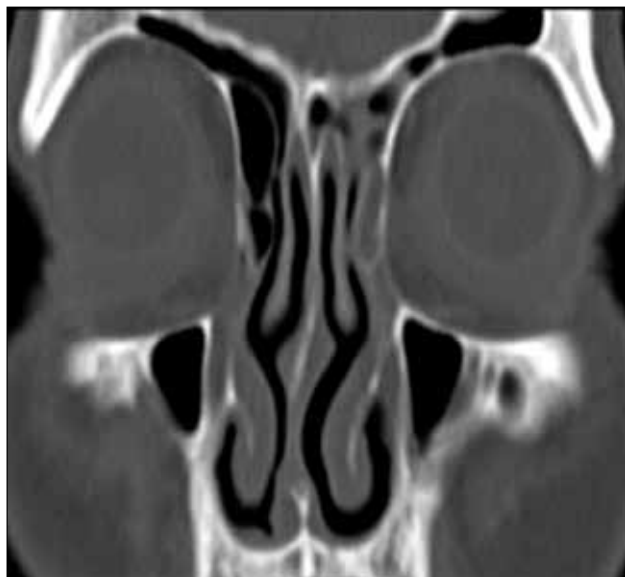
Regarding the dimensions of the pneumatized crista galli, the *antero-posterior diameter* length ranged from 5.0 up to 14.8 millimeters, with no statistically significant differences between males (5.3-13.8 mm) and females (5.0-12.4 mm). The cranio-caudal diameter length was also slightly shorter in females (ranging from 4.7 up to 11.2 mm) in comparison to males (5.1-12.7 mm). The latero-lateral diameter varied between 3.0 and 6.8 mm (3.0-5.7 mm in females and 3.3-6.8 mm in males).

As to the degree of opacification of the pneumatized crista galli in 59 CRS patients with CRS and concomitant pneumatized crista galli, 38 had no opacification (66.4%), whereas 21 had various degree of opacification: 14 CRS patients with partial (23.7%) and 7 CRS patients with complete opacification (11.9%) (Chart 1).

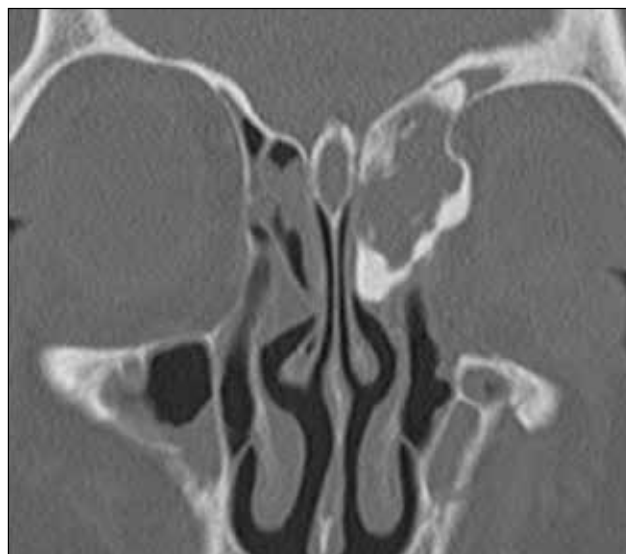The presence of a communication between crista galli and adjacent paranasal structures was rigorously searched in every patient. The presence of an open-



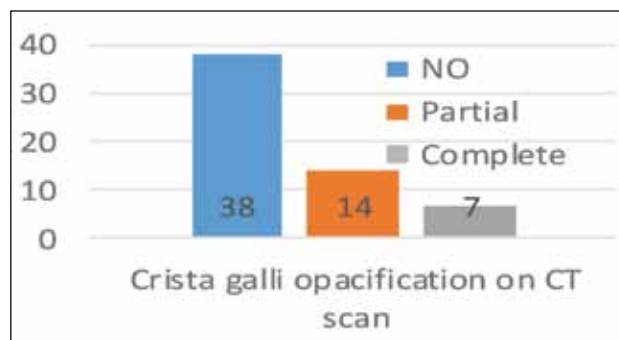
**Figure 3** Crista galli is pneumatized, but seems to be empty. Right ethmoid sinus is obviously occupied by dense content, most probably polypous tissue



**Figure 4** Incomplete opacification of the crista galli, located at its bottom. Left ostiomeatal complex seems to be diseased as well



**Figure 5** A complete opacification of the largely pneumatized crista galli. Both maxillary sinuses as well as the ethmoid and the left frontal sinus are occupied by pathologic substrat



**Chart 1.** Degree of crista galli opacification on CT scan

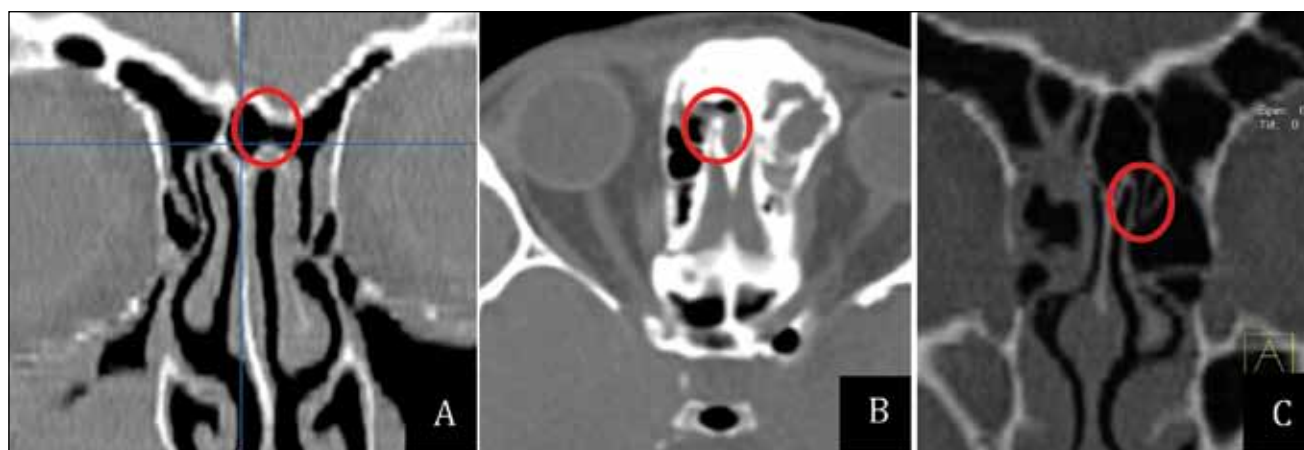
ing of the pneumatized crista galli into surrounding air-cells was found in 10 out of 59 CRS patients (16.98%). Nine of them had a communication with the frontal sinus and only one communicated with the suprabullar recess (Figure 6). Interesting is that from the patients with crista galli "sinusitis" (21 patients that had various degree of opacification on CT scan), the percentage of a so-called drainage pathway was a little higher (5 out of 21 patients, representing 23.8%).

We tried to compare the patients with crista galli sinusitis with the patients with chronic sinusitis (CRS) in what the presence of headache as a leading symptom is concerned. From 196 patients with CRS, headache was encountered in 113 patients, representing 57.6%. In contrast, the percentage was much higher in the group of patients with CRS and pneumatized crista galli sinusitis – 16 out of 21 patients, representing 76.2%. The incidence of headache is almost similar in patients with CRS and patients with pneumatized crista galli without inflammatory – infectious disease: 23 out of 38 patients, representing 60.5%. This may lead to the conclusion that crista galli sinusitis is a more frequent reason for chronic headache than CRS alone (Chart 2).

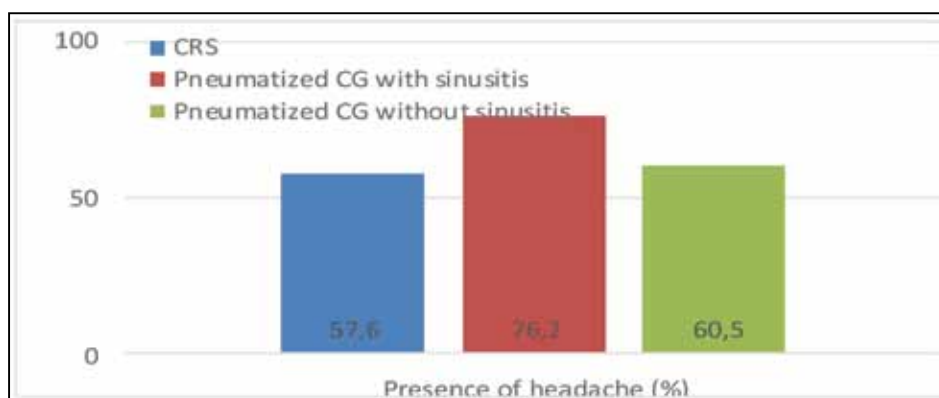
## DISCUSSIONS

There is a high variability in the crista galli pneumatization, prevalence depending on the study cited. In our study, the incidence of 30.1% of pneumatized crista galli in CRS patients is higher than in other reports, but similar to the one found by Mladina et al.<sup>6</sup>. In this regard, Som et al.<sup>2</sup> found, in a series of 200 CT scans of paranasal sinuses, crista galli pneumatization in 13% of patients. This result confirms the accuracy of the previous study, showing that using the same radiological and evaluation technique, the pneumatization of crista galli is higher than previously thought.

From the embryological point of view, crista galli derives from the ethmoid bone<sup>2</sup>. In adults, using CT scan studies, there is a debate regarding considering crista galli a compartment of the frontal sinus or if it is an individual sinus. To be an independent sinusal cavity, it has to have a drainage pathway, and according to our study, we found this feature only in 10 out of 59 patients, representing 16.98%. This result is in accordance with the data found in the literature<sup>2,4,6</sup>. We consider that sometimes it is difficult to detect small ostia, even when using extra fine slices computer tomography, so the results may be altered by these technical limitations.



**Figure 6** Drainage pathways of the crista galli – in the frontal sinus (A, B) and the suprabullar recess (C) – red circle



**Chart 2.** The presence of headache in patients with/without crista galli sinusitis

At the same time, the clinical behavior of the crista galli is similar to the paranasal sinus. One third of our patients had various degree of opacification of the pneumatized crista galli (21 patients, 33.6%, see Chart 2), with inflammatory characteristics similar to chronic rhinosinusitis. Also, the high incidence of headache in patients with pneumatized crista galli with radiological signs of inflammation (16 out of 21 patients, i.e. 76.2%), in contrast with 60.5% for the patients with CRS but with no opacification of the pneumatized crista galli, may lead to the conclusion that crista galli sinusitis is a real clinical entity, and a more frequent reason for chronic headache than CRS alone. Socher et al.<sup>7</sup> described 3 clinical cases of crista galli sinusitis, emphasizing that medical antibiotic treatment had little to no effect on crista galli inflammation. The crista galli pneumatization was successfully accessed through the trans-septal endoscopic approach, with the positive effect regarding the cessation of the headache.

## CONCLUSIONS

1. Crista galli is an anatomical structure with high morphological variations;
2. Pneumatization of crista galli was found in 30.1% of CRS patients, showing a higher incidence than previously thought;
3. The connection between crista galli and the surrounding air-cells structures was found in 16.98% of cases, all of them with the frontal sinus, excepting one connection with a suprabullar recess. We consider these connections as drainage pathways similar to those of the paranasal sinuses;
4. Partial or complete opacification on CT scan of the pneumatized crista galli was found in 33.6%

of cases, with inflammatory characteristics similar to chronic rhinosinusitis;

5. Headache had a higher incidence in patients with crista galli inflammation than in normal CRS patients (76.2% versus 60.5% in CRS patients).

**Conflicts of interests:** None

**Contribution of authors:** All authors have equally contributed to this work.

## REFERENCES

1. Lund V.J., Stammberger H., Fokkens W.J., Beale T., Bernal-Sprekelsen M., Eloy P., Georgalas C., et al. - European position paper on the anatomical terminology of the internal nose and paranasal sinuses. *Rhinol Suppl.*, 2014; (24):1-34.
2. Som P.M., Park E.E., Naidich T.P., Lawson W. - Crista Galli. Pneumatization Is an Extension of the Adjacent Frontal Sinuses. *AJNR Am J Neuroradiol.*, 2009;30(1):31-33. doi: 10.3174/ajnr.A1291. Epub 2008 Sep 3.
3. Hajjiannou J., Owens D., Whittet H.B. - Evaluation of anatomical variation of the crista galli using computed tomography. *Clin Anat.*, 2010;23(4):370-373. doi: 10.1002/ca.20957.
4. Dutra L.D., Marchiori E. - Tomografia computadorizada helicoidal dos seios paranasais na criança: avaliação das sinusopatias inflamatórias. *Radiol Bras.*, 2002;35(3):161-169.
5. Lee J.M., Ransom E., Lee J.Y., Palmer J.N., Chiu A.G. - Endoscopic Anterior Skull Base Surgery: Intraoperative Considerations of the Crista Galli. *Skull Base.*, 2011;21(2):83-86. doi: 10.1055/s-0030-1263282.
6. Poje G., Mladina R., Skitarelic N., Marjanovic Kavanagh M. - Some radiological and clinical aspects of the sinus crista galli. *Romanian Journal of Rhinology*, 2014;13(4):31-36.
7. Socher J.A., Santos P.G., Correa V.C., Silva L.C. de B. e. - Endoscopic surgery in the treatment of crista galli pneumatization evolving with localized frontal headaches. *Int Arch Otorhinolaryngol.*, 2013;17(3):246-250. doi:10.7162/S1809-97720130003000003.