

ORIGINAL STUDY

Evaluation of ostiomeatal complex pathology related to endoscopic sinus surgery – a retrospective analysis

Vlad Budu¹, Alexandra Schnaider¹, Maria Sabina Tache², Ioan Bulescu³

¹“Prof. Dr. Dorin Hociota” Institute of Phono-Audiology and Functional ENT Surgery, Bucharest, Romania

²Faculty of Medicine, “Carol Davila” University of Medicine and Pharmacy, Bucharest, Romania

³Department of Anatomy, “Carol Davila” University of Medicine and Pharmacy, Bucharest, Romania

ABSTRACT

BACKGROUND. The ostiomeatal complex (OMC) is the anatomical region situated between the middle turbinate and the lateral nasal wall, at the level of the middle meatus. Common anatomical variations of OMC are concha bullosa, hypertrophy of the uncinate process and of the bulla ethmoidalis and Haller’s cell. Our study was aimed to investigate the prevalence of these conditions and their relations to different symptoms.

MATERIAL AND METHODS. The study is a retrospective descriptive study based on 256 files of patients who were hospitalized and treated for OMC pathology in our clinic between January 2009 and January 2014. The data acquired were included into Excel Worksheets and statistically analyzed using GraphPad Software.

RESULTS. The most common finding was concha bullosa (63.67%), followed by hypertrophy of the bulla ethmoidalis (10.93%) and of the uncinate process (10.15%). Haller’s cell was found in only 3% of cases. The most common symptom for all patients was nasal obstruction, followed by nasal discharge. The majority of symptoms improved after functional endoscopic sinus surgery for OMC drainage.

CONCLUSION. OMC pathology is a frequent indication for functional endoscopic sinus surgery. The most common condition that determines blockage of OMC and need for surgical treatment is concha bullosa. The most common complaint of patients with OMC pathology is nasal obstruction.

KEYWORDS: ostiomeatal complex, Haller’s cell, concha bullosa, endoscopic sinus surgery

INTRODUCTION

The ostiomeatal complex (OMC) is the region of the anterior ethmoid situated between the middle turbinate and the lateral nasal wall in the middle meatus. It represents the region of drainage for the anterior ethmoid sinus system, frontal and maxillary sinuses^{1,2}. Obstruction of the OMC causes a vicious cycle of events, which lead to mucosal congestion, decrease of airflow and eventually could cause sinusitis². OMC comprises a series of anatomical structures, and their variations could cause OMC obstruction. Common anatomical variations of the OMC include concha bullosa, paradoxical middle turbinate, uncinate process hypertrophy and pneumatization, hypertrophy of the bulla ethmoidalis and the agger nasi cell, and the presence of the maxillo-ethmoidal cell (Haller’s cell)³. These anatomical variations could also be the cause of the so-called contact point rhinogenic headache. This usually appears when there

is contact between the nasal septum and the lateral nasal wall (could appear in septal deviations and concha bullosa) and it is mediated by the stimulation of trigeminal nerve fibers. The “P” substance has an important role in the occurrence of rhinogenic contact point headache. It is a neuropeptide found in the nasal mucosa. It is thought to produce vasodilatation and stimulates inflammation, determining headache⁴.

Symptoms of patients with OMC obstruction are variable and are somewhat related to the type of anatomical variation. Usually, they vary between frontal headache, facial and ocular pain or pressure, nasal obstruction and rhinorrhea.

Concha bullosa represents the pneumatization of one of the turbinates, most frequently the middle turbinate. It is one of the most frequent variations of the paranasal sinuses⁵. It can appear unilaterally or bilaterally, and it could be related to septal deviations. Common symptoms of concha bullosa include frontal and

temporal headaches, with or without rhinorrhea, determined by stimulation of trigeminal nerve fibers^{6,8}. Paradoxical middle turbinate is a variation of the middle turbinate in which it is bent sideways, with its convex part towards the middle meatus, thus blocking ventilation and drainage. It can appear as a unilateral or bilateral finding.

Variations of the uncinate process are less frequent than the ones of the middle turbinate. They include uncinate process hypertrophy, lateral or medial deviation and pneumatization. It can determine obstruction of the ethmoid infundibulum with blockage of the anterior ethmoid cells, the maxillary and frontal sinus⁹.

The bulla ethmoidalis is the largest cell of the anterior ethmoid^{10,11}. It is considered to be the most commonly pneumatized. Its development can be excessive into different degrees of pneumatization. Also, it can be filled with pus, cysts or polyps¹². Hypertrophy of the bulla ethmoidalis is associated with rhinosinusitis¹³. Extramural extension of the anterior ethmoid is pneumatization in neighbouring structures and bones. The agger nasi cell is developed at the level of the anterior ethmoid and the lacrimal bone¹⁴, just anterior to the insertion of the middle turbinate. It comes in important functional relations to the frontal recess and to the fossa of the lacrimal sac. Well-developed agger nasi cells are possibly involved in chronic or recurrent frontal sinusitis¹⁵. The maxillo-ethmoidal cell or Haller's cell is developed by pneumatization from the anterior ethmoid into the floor of the orbit. It can be variably developed and can obstruct the maxillary sinus ostium or the ethmoid infundibulum^{8,16}.

These structural abnormalities of OMC usually need surgical treatment, since they rarely respond to medical therapy¹⁷. Functional endoscopic sinus surgery (FESS) is the "gold-standard" type of surgery in the pathology of OMC. The main objectives of the surgery are to reopen the natural ways of drainage of paranasal cavities, using a minimally invasive approach. Pre-operative diagnosis of these variations can usually be made using computed tomography.

MATERIAL AND METHODS

The present study is a descriptive retrospective study, using data from a period of 5 years, between January 2009 and January 2014. The data were retrieved from the files of "Prof. Dr. Dorin Hociota" Institute of Phono-Audiology and Functional ENT Surgery, Bucharest. The study group is comprised of 256 patients (n=256), aged between 10 and 70 years old, patients hospitalized and treated in our clinic. The insertion condition was the presence of OMC pathology, identified through computed tomography and/or en-

doscopy. The variables used for the study were age, gender, smoker status, allergy status, imagistic evaluation, type of pathology, types of symptoms, mean hospitalization time. The data obtained were transcribed into Microsoft Excel Worksheets, and statistically analyzed using GraphPad Software Prism 6. The statistical analysis was made using variables like "gender", "smoking status", "imagistic evaluation", "type of OMC pathology". For these variables, we used a percent presentation. The "age" variable is a quantitative variable with normal distribution and was presented as a median and standard deviation. The "duration of hospitalization" is also a quantitative variable, but with a non-normal distribution. It was presented as median and extreme values (minimum and maximum).

The Fischer Exact test was used for analysis of the differences between nominal variables. Values considered statistically significant (p) were under 0.05 (p<0.05), confidence interval (IC) 95% (IC 95%).

RESULTS

Out of the 256 patients in the study group, 138 (53.90%) were female and 118 (46.09%) were male. They were distributed variably across age groups, which were divided between 10-70 years into 6 groups (10-19...60-70). Most patients were included into the 40-49 years group (35.16%) and the 30-39 years group (28.13%).

Regarding the "smoker" or "non-smoker" status, out of the 256 patients included, 135 (52.73%) were smokers and 121 (47.26%) were non-smokers. From the smokers group (n=135), 60% of patients were male and 40% were female. According to the age group, most of the smokers were between 30-49 years old (Figure 1).

Imagistic investigations for patients in the study were computed tomography (CT), magnetic resonance imaging (MRI) and plain radiography, which were usually made up to 3 months prior to admittance. Out of the 256 patients, 169 (66.01%) had at least one type of imagistic investigation. 135 patients (79.88%) were investigated using CT, 20 (11.83%) using MRI and only 14 (8.28%) using plain radiography (Figure 2).

Symptoms at admittance were evaluated using anamnesis, and at least one of the following was noted for each patient: rhinorrhea, facial pressure, sinus pain, rhinogenic headache, nasal obstruction. Most of the patients usually complained about more than one symptom. The presence of **nasal discharge** or rhinorrhea was the symptom affirmed by 160 patients (62.5%). From those, 93 (58.12%) were female and 67 (41.87%) were male. **Facial pressure** (frontal and/or maxillary) was noted for 94 patients (36.71%), from which 55 (58.51%) were female and 39 (41.48%) were male.

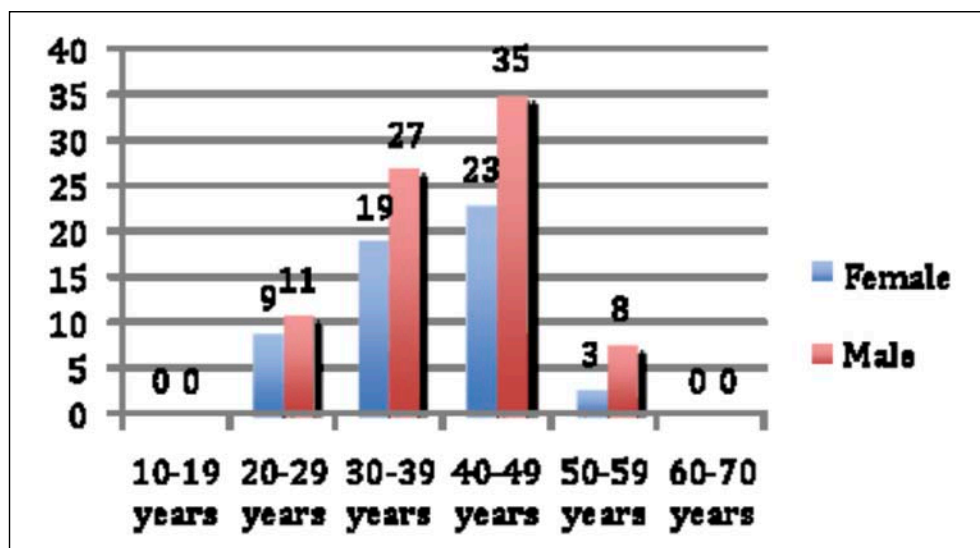


Figure 1 Distribution of smoker patients on age groups

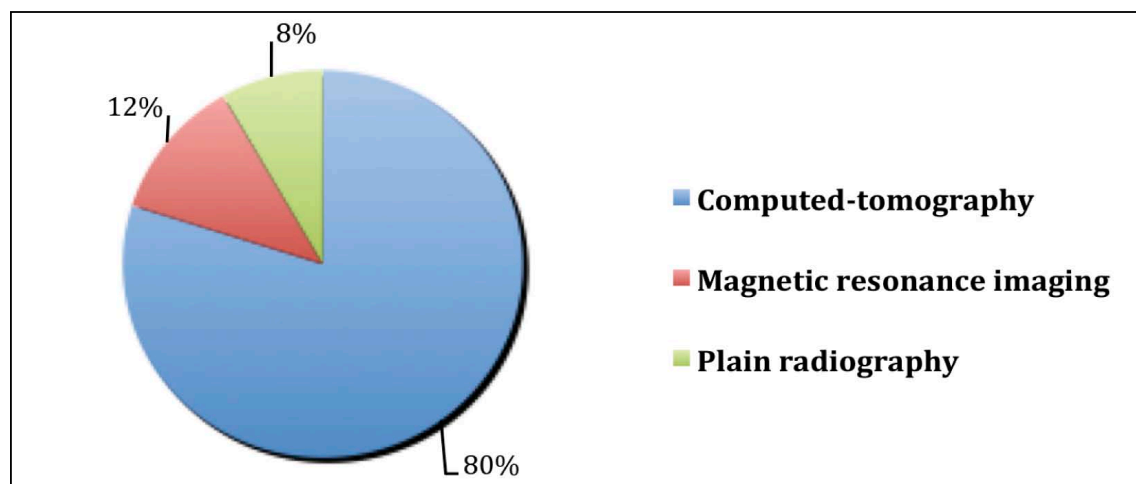


Figure 2 Imagistic evaluation of patients prior to admittance

Sinus pain was present for 89 patients (34.76%), 41 (46.07%) female and 48 (53.93%) male. 106 patients (41.40%) complained of **rhinogenic headache**, 68 (64.15%) being female and 38 (35.85%) male. The most common symptom in all patients was **nasal obstruction**, which was the main complaint for 192 patients (75%). From this group, 115 (59.89%) were female and 77 (40.10%) were male (Figure 3).

OMC pathology was examined considering the presence of at least one of the major pathologic conditions including concha bullosa, paradoxical middle turbinate, hypertrophy of the uncinate process, hypertrophy of the bulla ethmoidalis, hypertrophy of agger nasi cell and presence of Haller's cell. All 256 patients included into the study group suffered from at least one of these conditions. The diagnosis was made on imagistic studies (CT or MRI) or using nasal endoscopy. The data collected showed the following results in the

study group: **concha bullosa** was present in 163 patients (63.67%), **paradoxical middle turbinate** in 18 patients (7.03%), **Haller's cell** in 8 patients (3.12%) and **hypertrophy of agger nasi cell** in 13 patients (5.07%). Regarding the **hypertrophy of the uncinate process** and of the **bulla ethmoidalis**, they were discovered in 26 patients (10.15%) and 28 patients (10.93%) respectively (Figure 4).

Concha bullosa was one of the pathological findings in 163 patients (63.67%) from which 87 (53.37%) were female and 76 (46.62%) were male. Symptoms at admittance for concha bullosa were: nasal discharge for 71.16% of patients ($p=0.0003$), facial pressure for 23.92% ($p=0.0001$), sinus pain for 26.99% ($p=0.0007$), rhinogenic headache for 36.80% ($p=0.06$) and nasal obstruction for 83.43% ($p<0.0001$).

Paradoxical middle turbinate was found in 18 patients (7.03%), where 7 (38.88%) were female and 11

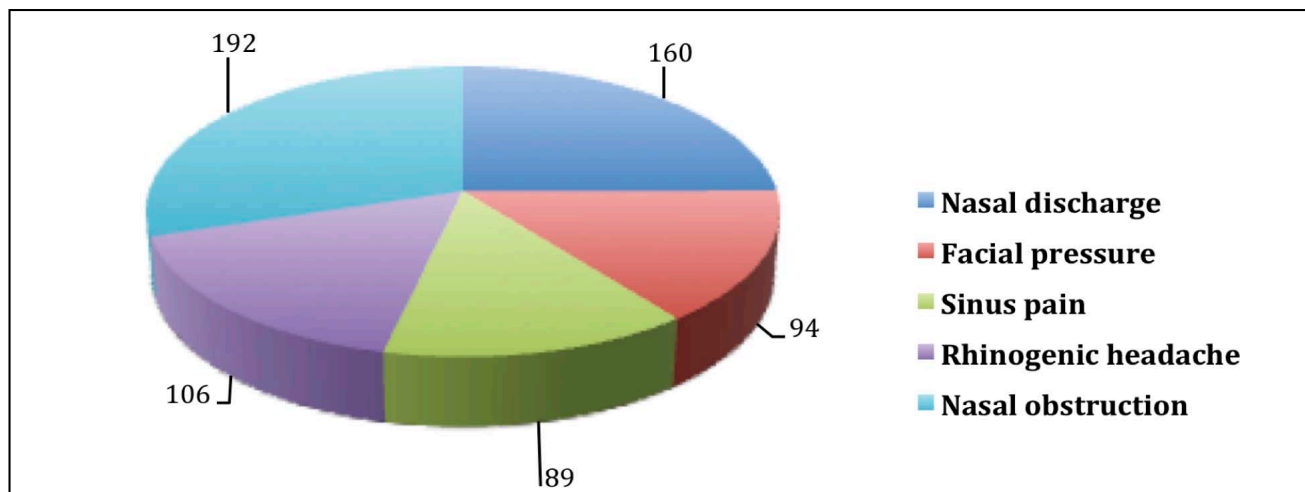


Figure 3 Major symptoms on admittance

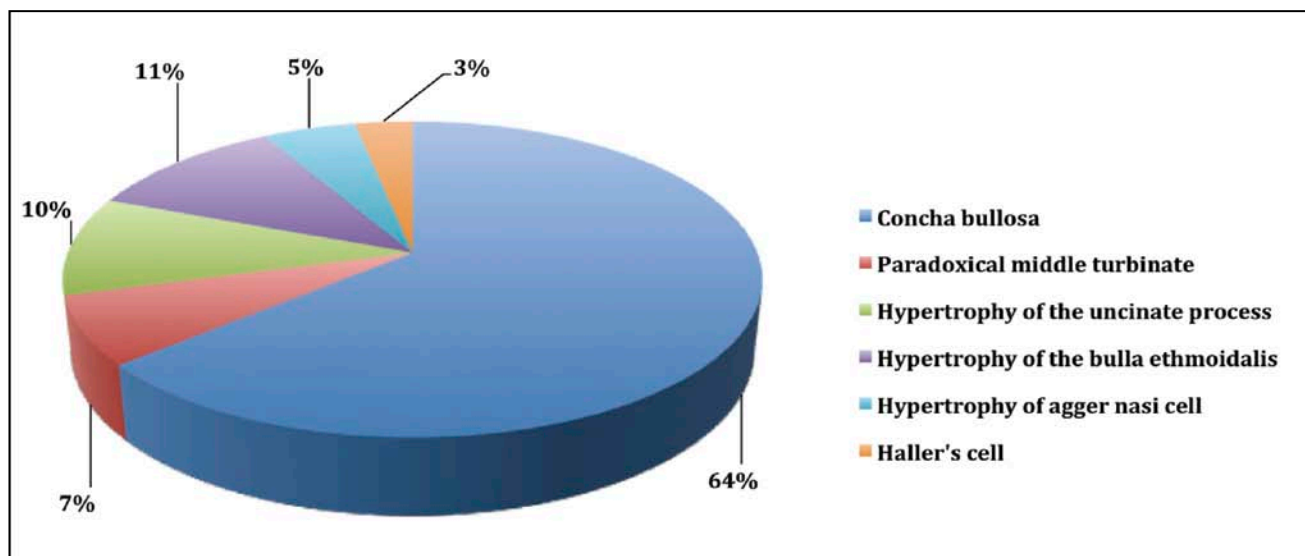


Figure 4 Distribution of patients according to OMC pathology

(61.11%) were male. Symptoms at admittance were: nasal discharge for 66.66% of patients ($p=0.80$), facial pressure for 94.44% ($p<0.0001$), sinus pain for 38.88% ($p=0.79$), rhinogenic headache for 44.44% ($p=0.80$) and nasal obstruction for 44.44% ($p=0.004$).

Hypertrophy of the uncinate process was discovered in 26 patients (10.15%) from which 17 (65.38%) were female and 9 (34.61%) were male. Symptoms for patients with this condition included: nasal discharge for 38.46% of patients ($p=0.01$), facial pressure for 26.92% ($p=0.39$), sinus pain for 30.76% ($p=0.82$), rhinogenic headache for 38.46% ($p=0.83$) and nasal obstruction for 92.30% ($p=0.03$).

Hypertrophy of the bulla ethmoidalis was discovered in 28 patients (10.93%) from which 16 (57.14%) were female and 12 (42.85%) were male. Symptoms for pa-

tients with this condition included: nasal discharge for 50% of patients ($p=0.15$), facial pressure for 89.28% ($p<0.0001$), sinus pain for 92.85% ($p<0.0001$), rhinogenic headache for 42.85% ($p=1$) and nasal obstruction for 75% ($p=1$).

Hypertrophy of the agger nasi cell was present in 13 patients (5.07%) and 7 (53.84%) were female and 6 (46.15%) were male. Symptoms at admittance were: nasal discharge for 38.46% of patients ($p=0.08$), facial pressure for 15.38% ($p=0.14$), sinus pain for 23.07% ($p=0.55$), rhinogenic headache for 100% ($p<0.0001$) and nasal obstruction for 15.38% ($p<0.0001$).

Haller's cell was found in only 8 patients (3.12%) from which 4 (50%) were male and 4 (50%) female. Common symptoms at admittance in these cases were nasal discharge in 37.50% of cases ($p=0.15$), facial pres-

sure in 50% of cases ($p=0.47$), sinus pain for 12.50% ($p=0.26$), rhinogenic headache for 37.50% of patients ($p=1$) and 12.50% had nasal obstruction ($p=0.0003$).

After endoscopic surgery, in most cases, symptoms were significantly improved. Nasal drainage was lowered in 66.25% ($n=106$) of patients; facial pressure was diminished in 88.29% ($n=83$), sinus pain and rhinogenic headache improved in 92.13% ($n=82$) and 71.69% ($n=76$) of patients respectively; nasal obstruction was improved in 89.06% ($n=171$) of patients.

The duration of hospitalization for these patients was between 2 to 5 days, with a median duration of 3 days.

DISCUSSIONS

Analyzing the results of this study, we observed that there was no significant difference between the distribution of patients according to age and gender groups ($p=1$) and the presence of OMC pathology. Regarding the repartition according to age groups, there was a preponderance of this pathology between 30 and 49 years, which accounted for 63.28% ($n=162$) of the patients.

Regarding the status of “smoker” or “non-smoker”, 52.73% of patients were smokers. The data resulted in the study could not conclude that the “smoker” status was a statistically significant criterion in the occurrence of OMC pathology, with the exception of uncinat process hypertrophy. 76.92% ($n=20$) of patients with uncinat process hypertrophy were smokers ($p=0.01$).

The most common finding in the study group was concha bullosa, which was found in 63.67% of the patients. From the symptoms associated with this condition, the most common was nasal obstruction in 83.43%, followed by nasal discharge in 71.16%.

Concha bullosa was followed in frequency by hypertrophy of the bulla ethmoidalis in 10.93% of patients and hypertrophy of the uncinat process in 10% of patients. Other conditions were rare findings, all of them accounting in less than 10.15% of patients (Figure 4). The condition found to be the rarest of all was Haller’s cell, which appeared in only 3.12% of cases.

Considering the literature that discussed the same topic, our results were comparable or slightly different to those of other authors. In their study, Aramani et al.², on a cohort of 54 patients ($n=54$), found the prevalence of concha bullosa as 33.3% in unilateral cases and 20.4% for bilateral cases, paradoxical middle turbinate in 14.8% cases, uncinat hypertrophy in 5.6% of cases, agger nasi cell and Haller’s cell in 1.9% of cases. On a 50-patient cohort, Biswas J et al.¹⁷ found the following variations in OMC pathology: concha bullosa in 36% of cases, agger nasi cell in 18%, paradoxical middle turbinate in 10%, Haller cell in 8% of cases, and pneumatized uncinat process in 6%. Larger studies, like the one of Bolger et al¹⁸, made on

202 patients, found concha bullosa in 53% of cases, agger nasi cell in 98.5%, paradoxical middle turbinate in 26.1%, Haller’s cell in 45.1% and pneumatized uncinat process in 2.5%.

Other studies, on different numbers of patients varying between 43 and 143 had various percentages for each of the findings, like concha bullosa (11.5% - 28%) or paradoxical middle turbinate (5.3% - 25.3%) and Haller’s cell (2% - 4.7%)¹⁹⁻²². We consider that these variations appear partly because of smaller study cohorts, different interpretation methods of pathology and population variation.

CONCLUSIONS

OMC pathology is a frequent indication for functional endoscopic sinus surgery (FESS). Various and multiple anatomical variations can determine pathological conditions of OMC. The most common anatomical variation, determining blockage of OMC and that needs surgical treatment is concha bullosa. Other findings include paradoxical middle turbinate, hypertrophy of the uncinat process and bulla ethmoidalis, Haller’s cell etc.

There were no significant relations between age group and the type of pathology, according to our study. Also, only hypertrophy of the uncinat process seems to be related to cigarette smoking.

Symptoms like nasal obstruction, nasal drainage, facial pressure, headache and sinus pain were the most common complaints of patients in this study. The most common complaint in all patients was nasal obstruction. All of the symptoms were significantly improved after FESS.

REFERENCES

1. Freitas A.P., Boasquevisque E.M. - Anatomical variants of the ostiomeatal complex: tomographic findings in 200 patients. *Radiol. Bras. J.*, 2008;41(3):149-154.
2. Aramani A., Karadi R.N., Kumar S. - A study of anatomical variations of osteomeatal complex in chronic rhinosinusitis patients – CT findings. *Journal of Clinical and Diagnostic Research*, 2014;8(10):1-4.
3. Kantarci M., Karasen R.M., Alper F., Onbas O., Okur A., Karaman A. - Remarkable anatomic variations in paranasal sinus region and their clinical importance. *Eur J Radiol.*, 2004 Jun;50(3):296-302.
4. Roozbahany N.A., Nasri S. - Nasal and paranasal sinus anatomical variations in patients with rhinogenic contact point headache. *Auris Nasus Larynx*, 2013;40(2):177-83. doi:10.1016/j.anl.2012.07.007. Epub 2012 Jul 31.
5. Bulescu I.A., Munteanu O., Sarbu A.E., Lupu G., Filipoiu F., Diaconescu B., Budu V. - Variability of pneumatization of ethmoid sinuses – concha bullosa – development, common misconceptions and relations to sinus pathology. *Revista Romana de Anatomie functionala si clinica, macro- si microscopica si de Antropologie*, 2014;8(1):63-66.

6. Aktas D., Kalcioğlu M.T., Kutlu R., Özturan O., Öncel S. - The relationship between the concha bullosa, nasal septal deviation and sinusitis. *Rhinology*, 2003;41(2):103-6.
7. Clark S.T., Babin R.W., Salazar J. - The incidence of concha bullosa and its relationship to chronic sinonasal disease. *Am J Rhinol*, 1989;3:11-12.
8. Huang H.H., Lee T.J., Huang C.C., Chang P.H., Huang S.F. - Non-sinusitis-related rhinogenous headache: a ten-year experience. *Am J Otolaryngol*, 2008 Sept-Oct;29(5):326-32. doi: 10.1016/j.amjoto.2007.10.001. Epub 2008 Jun 13.
9. Laine F.J., Smoker W.R. - The ostiomeatal unit and endoscopic surgery: anatomy, variations, and imaging findings in inflammatory diseases. *AJR Am J Roentgenol*, 1992;159(4):849-57.
10. Polavaram R., Devaiah A.K., Sakai O., Shapshay S.M. - Anatomic variants and pearls – functional endoscopic sinus surgery. *Otolaryngol Clin North Am*, 2004 Apr;32(2):221-42.
11. Wright E.D., Bolger W.E. - The bulla ethmoidalis: lamella or a true cell? *J Otolaryngol*, 2001;30(3):162-6.
12. Stammberger H., Wolf G. - Headaches and sinus disease: the endoscopic approach. *Ann Otol Rhinol Laryngol Suppl*, 1988;134:3-23.
13. Fadda G.L., Rosso S., Aversa S., Petrelli A., Ondolito C., Succo G. - Correlazione statistica multiparametrica tra variazioni anatomiche rinossinusal e rinosinusite cronica. *Acta Otorhinolaryngol Ital*, 2012;32(4):244-51.
14. Marquez S., Tessema B., Clement P., Schaeffer S. - Development of the ethmoid sinus and extramural migration: The anatomical basis of the paranasal sinus. *Anat Rec (Hoboken)*, 2008;291(11):1535-1553.
15. Orhan M., Saylam C.Y. - Anatomical analysis of the prevalence of agger nasi cell in Turkish population. *Kulak Burun Bogaz Ihtis Derg*, 2009;19(2):82-86.
16. Gupta A.K., Bansal S., Sahini D. - Anatomy and its variations for endoscopic sinus surgery. *Clin Rhinol An Int J*, 2012;5(2):55-62.
17. Biswas J., Patil C.Y., Prasad Y., Desmukh T., Kharat R., Nahata V. - Tomographic evaluation of structural variations of nasal cavity in various nasal pathologies. *International Journal of Otolaryngology and Head and Neck Surgery*, 2013;2:129-134.
18. Bolger W.E., Butzin C.A., Parsons D.S. - Paranasal sinus bony anatomical variations and mucosal abnormalities: CT analysis for endoscopic sinus surgery. *Laryngoscope*, 1991;101(1): 56-64.
19. Tonai A., Baba S. - Anatomic variations of the bone in sinonasal CT. *Acta Otolaryngologica Supplement*, 1996;525:9-13.
20. Talaiepour A.R., Sazgar A., Bagheri A. - Anatomic variations of the paranasal sinuses on CT scan images. *Journal of Dentistry, Tehran University of Medical Sciences*, 2005;2(4):142-146.
21. Badia L., Lund V.J., Wei W., Ho W.K. - Ethnic variation in sinonasal anatomy on CT-scanning. *Rhinology*, 2005;43:210-214.
22. Lerdum S., Vachiranubhap B. - Prevalence of anatomic variation demonstrated on screening sinus computed tomography and clinical correlation. *Journal of the Medical Association of Thailand*, 2005; 88(suppl.4):S110-S115.