

**EFFECT OF ADDING DEXAMETHASONE AS A ROPIVACAINE ADJUVANT
IN ULTRASOUND-GUIDED TRANSVERSUS ABDOMINIS PLANE BLOCK
FOR INGUINAL HERNIA REPAIR**

**Andrijan Kartalov¹, Nikola Jankulovski³, Biljana Kuzmanovska¹, Milka Zdravkovska²,
Mirjana Shosholcheva⁵, Tatjana Spirovska¹, Aleksandra Panovska Petrusheva¹, Marija
Tolevska¹, Marija Srceva¹, Vesna Durnev¹, Gjorgji Jota³, Redzep Selmani³, Atanas Sivevski⁴**

¹ Clinic for Anesthesiology, Reanimatology and Intensive Care Unit – KARIL, Skopje, R. Macedonia

² Faculty of Medical Sciences, "Goce Delchev University", Shtip, R. Macedonia

³ Clinic for Abdominal surgery, Skopje, R. Macedonia

⁴ University Clinic for Gynecology and Obstetric, Skopje, R. Macedonia

Medical faculty, "St. Cyril & Methodius", Skopje, R. Macedonia

⁵ University Clinic, "St. Naum Ohridski", Medical Faculty, Skopje, R. Macedonia

Corresponding Author: Andrijan Kartalov, MD, PhD, Clinic for Anesthesia, Reanimation and Intensive Care,
Faculty of Medicine, University St. "Cyril and Methodius" – Skopje; Tel: 00 +389 (0)2 76 60 68 03;
E-mail: andrijan_kartalov@yahoo.com

Abstract

Background: The transversus abdominis plane block (TAP) is a regional anesthesia technique that provided analgesia to the parietal peritoneum, skin and muscles of the anterior abdominal wall. The aim of this randomized double-blind study was to evaluate postoperative analgesia on patients undergoing open inguinal hernia repair under general anesthesia (GA), (GA + TAP) block preformed with ropivacaine and (GA + TAP-D) block preformed with ropivacaine and 4 mg dexamethasone.

Methods: 90 (ASA I–II) adult patients for unilateral open inguinal hernia repair were included in this study. In group I (n = 30) patients received only general anesthesia (GA). Patients in group II (n = 30) received GA and unilateral TAP block with 25 ml of 0.5% ropivacaine and the patients in group III (n = 30) received GA and unilateral TAP-D block with 25 ml of 0.5% ropivacaine + 4 mg Dexamethasone. In this study we assessed the pain score – VAS at rest at 2, 4, 6, 12 and 24 hours after the operation and the total analgesic consumption of morphine over 24 hours.

Results: There were statistically significant differences in the VAS scores between group I, group II and group III at all postoperative time points – 2^{hr}, 4^{hr}, 6^{hr}, 12^{hr} and 24^{hr}. ($p < 0.00001$). The cumulative 24 hours morphine consumption after the operation was significantly lower in group III (5.53 ± 1.21 mg) than in group II (6.16 ± 2.41 mg) and group I (9.26 ± 2.41 mg). This difference is statistically significant ($p < 0.00001$).

Conclusion: Concerning the inguinal hernia repair we found better postoperative pain scores and 24 hours reduction of the morphine consumption in group III (GA and TAP-D block) compared with group I (GA) and group II (GA + TAP block).

Keywords: Unilateral open inguinal herniotomy, US-TAP block, Ropivacaine, Dexamethasone

Introduction

The transversus abdominis plane block (TAP block) is a new regional anesthesia technique that provides analgesia following abdominal surgery [1]. The TAP block significantly

reduces pain after open inguinal hernia repair, regardless of whether it is used as a primary anesthesia technique or as a complement to general anesthesia, spinal or local anesthesia [1]. The TAP block can provide excellent analgesia

to the skin and muscles of the anterior abdominal wall following the inguinal hernia repair, appendectomy, radical prostatectomy, abdominoplasty, renal transplantation, large bowel resection, cesarean section, laparoscopic cholecystectomy and iliac crest bone grafting [2, 3, 4, 5]. A lot of reports suggest that TAP blocks may also be a safe alternative to the neuroaxial blockade in patients who are on anti-coagulant therapy or in patients who would not tolerate the hemodynamic instability [6, 7].

An ultrasound-guided approach of the TAP block was first described in 2007 by Hebbard et al. [8]. The ultrasound technique was induced to improve the success rate of the TAP block. This ultrasound procedure is performed with ultrasound high frequency (5–13 MHz) probe which is placed on the lateral abdominal wall between the costal margin and the iliac crest at the anterior axillary line. The technique involves injection of local anesthetic solution into a plane between internal oblique muscle (IO) and transversus abdominis (TA) muscle. This plane contains the thoracolumbar nerves originating from T6 to L1, ilioinguinal and iliohypogastric nerves. They supply sensory blockade to the skin, muscles and parietal peritoneum of the anterolateral abdominal wall. Real-time ultrasonography facilitates easy needle visualization and visualization of the local anesthetic spread in to the target "fascial plane" which is parallel to the ultrasound probe.

There is a new strategy to prolong analgesia beyond the pharmacological duration of the local anesthetics. They include introduction of perineural catheters to allow prolonged infusion of the local anesthetics or co-administration of adjuvants such as epinephrine, α_2 agonists (i.e. clonidine), midazolam or corticosteroids – dexamethasone [8, 9]. The perineural catheter techniques can be very effective and can provide analgesia for several days, but this technique is limited with difficulties in placement and removal of the catheter, or rarely, with infection [9, 10].

It is believed that dexamethasone as a supplement improves the quality and duration of the local anesthetics. This is thought to be mediated by attenuating the release of inflammatory mediators, reducing ectopic neuronal discharge, and inhibiting potassium channel-mediated discharge of nociceptive C-fibres [11, 12, 13].

The aim of this randomized controlled double-blind study was to evaluate the effect of the dexamethasone added to 0.5 % ropivacaine on the quality of the TAP block used as a supplement of general anesthesia on patients undergoing elective unilateral inguinal hernia repair.

Materials and methods

After obtaining the hospital ethics committee approval, 90 patients with physical status ASA I–II (by the American Society of Anesthesiologists), aged 18–70 years, scheduled for unilateral open inguinal hernia repair were included in this clinical trial. Exclusion criteria included age < 18, ASA class III–IV, scrotal hernias, recurrent hernia, history of peptic ulcer, severe bronchopulmonary disease, pregnancy or lactating, diabetes mellitus, known allergy to paracetamol or amino amide local anesthetics, chronic hepatic or renal failure, coagulation disorders and patients with body mass index (BMI) > 35 kg/m².

According to the type of anesthesia, the patients were divided in 3 groups. In group I (n = 30), the patients received only general anesthesia (GA), in group II (n = 30) the patients received GA and unilateral TAP block performed only with 25 ml of 0.5% ropivacaine and in group III (n = 30) the patients received GA and unilateral TAP-D block performed with 25 ml of 0.5% ropivacaine and 4 mg of Dexamethasone. The medication for the TAP block was prepared by a staff member who was not involved in the study and delivered in unidentifiable syringes.

The demographic and clinical characteristics of the patients were assessed, as well, the pain scores – VAS (visual analogue scale) at rest at 2, 4, 6, 12 and 24 hours after operation and the total analgesic consumption of the morphine dose over 24-hours.

The premedication was done with midazolam with a dose of 0.02 mg/kg intravenous (IV) before surgery. The induction of the general anesthesia to all 90 patients was performed with 2% of propofol – 1–2 mg/kg, and fentanyl at dose of 0.5–1 μ g /kg. The endotracheal intubation was facilitated with rocuronium 0.6 mg/kg, following 90 seconds of face mask ventilation. The pressure controlled ventilation was done by providing oxygen of 50% and air of 50% at the flow rate of 2 L / min. The

anesthesia maintaining was done with remifentanyl at the dose of 0.025–0.2 µg /kg/min and sevoflurane at 0.7–1 MAC.

After the induction in general anesthesia, the unilateral TAP block was performed with the Sonosite – Turbo, Ultrasound Mashine with a 5–13 MHz linear probe. At the operative side, the TAP block was made to the target of "fascial plane", under a direct vision with a 22G needle (Stimuplex D Plus 22G × 80 mm, B. Braun, Melsungen, Germany). All patients were operated by the same surgeon. Also the ASA classification, the type of hernia (indirect / direct) and the BMI (body mass index) were noted in both groups. During the surgery, in 15 minute intervals, we monitored: operation time, heart rate, ECG, noninvasive blood pressure and periphery oxygen saturation. Before the end of the surgery all patients received 1 g of paracetamol intravenously.

The postoperative pain assessment for all patients was done in recovery room and in the surgical ward by an anesthesiologist (independent observer) at 2, 4, 6, 12, and 24 hours after surgery. VAS (0: no pain to 10: worst imaginable pain) was used for pain assessment, for which all patients received instructions before surgery. The standard postoperative analgesia consisted of paracetamol 1gr i.v. on every 6 hours. During the first postoperative day a rescue analgesic – morphine IV 0.05 mg/kg was applied to the patients if their VAS score at rest was > 3 and if paracetamol had been administered less than 6 hours before. The total analgesic

consumption and morphine dose over the 24-h study period was documented. Rescue antiemetics were given to any patient who complained for nausea and vomiting.

The data was analyzed using the Statistical Package for Social Sciences (SPSS) version 17.0 software (IBM Corporation, Armonk, NY). They were expressed as mean ± standard deviation. The Kolmogorov Smirnov test and the Shapiro-Wilk's W test were used to identify the distribution of variables. Nonparametric statistical methods were used for the heterogeneous variables. The Mann –Whitney U test was used for nonparametric variables. A P-value less than 0.05 was considered statistically significant.

Results

The demographic variables and operative characteristics were similar between the groups. (Table 1) There were no statistically significant differences in age (years), sex (F/M), BMI (kg/m²), operative time (minutes) and discharge time after the surgery between the groups.

During the surgery, there were no statistically significant differences in mean blood pressure, heart rate and oxygen saturation among measurement times between groups.

There were statistically significant differences in the VAS scores between group I, group II and group III at all postoperative time points – 2^{hr}, 4^{hr}, 6^{hr}, 12^{hr}. and 24^{hr}. ($p < 0.00001$). The VAS scores in group III are significantly lower than in the other two groups (Table 2 and Figure 1).

Table 1

Demographic and clinical characteristics

Variable	Group I	Group II	Group III	P-value
Age, years	52.4 ± 14.7	51.3 ± 15.8	53 ± 11.4	p = 0.7811
Sex (F/M), number	4/26	5/25	4/25	p = 0.2210
BMI (kg/m ²)	24.9 ± 4.4	25.4 ± 4.1	22.8 ± 2.1	p = 0.6505
operative time (minutes)	55.6 ± 10	59.7 ± 15	59.9 ± 19	p = 0.2179
Discharge one day after surgery (%)	n = 30 (100%)	n = 30 (100%)	n = 30 (100%)	p = 1.0

Abbreviations: F, female; M, male; American Society of Anesthesiologists; BMI, body mass index.

Table 2

VAS scores at rest in group I and II at all postoperative time points

	VAS 2 h	VAS 4 h	VAS 6 h	VAS 12 h	VAS 24 h
GA – (group I)	3 0,94				
GA + TAP Block (group II)	2 0,2 $p < 00001$				
GA + D-TAP Block (group III)	1 0,3 $p < 00001$				
GA – (group I)		3 0,69			
GA + TAP Block (group II)		2 0,2 $p < 00001$			
GA + D-TAP Block (group III)		1 0,9 $p < 00001$			
GA – (group I)			4 0,78		
GA + TAP Block (group II)			2 0,69 $p < 00001$		
GA + D-TAP Block (group III)			1 0,9 $p < 00001$		
GA – (group I)				5 0,66	
GA + TAP Block (group II)				2 0,61 $p < 00001$	
GA + D-TAP Block (group III)				1 0,7 $p < 00001$	
GA – (group I)					3 0,78
GA + TAP Block (group II)					2 0,28 $p < 00001$
GA + D-TAP Block (group III)					1 0,6 $p < 00001$

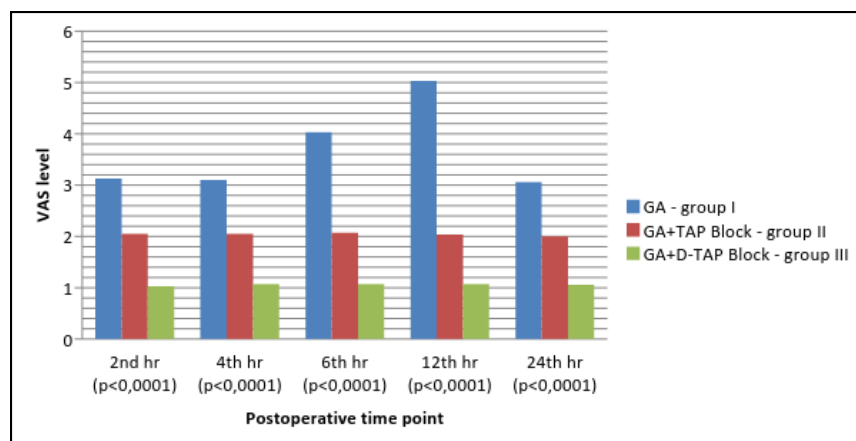


Figure 1 – VAS scores in group I, group II and III at all postoperative time points

The cumulative 24 hours morphine consumption after the operation (inguinal hernia repair) was significantly lower in group III, the patients who underwent general anesthesia GA and D-TAP block performed with 25 ml of 0.5% ropivacaine + 4 mg of Dexamethasone (group III – 5,53 1,21)

than the group of patients who underwent general anesthesia GA and TAP block performed with 25 ml of 0.5% ropivacaine (group II – 6,16 2,41) and group of patients who underwent only general anesthesia – GA (group I – 9,26 2,41). This difference was statistically significant ($p < 0.00001$). (Figure 2.)

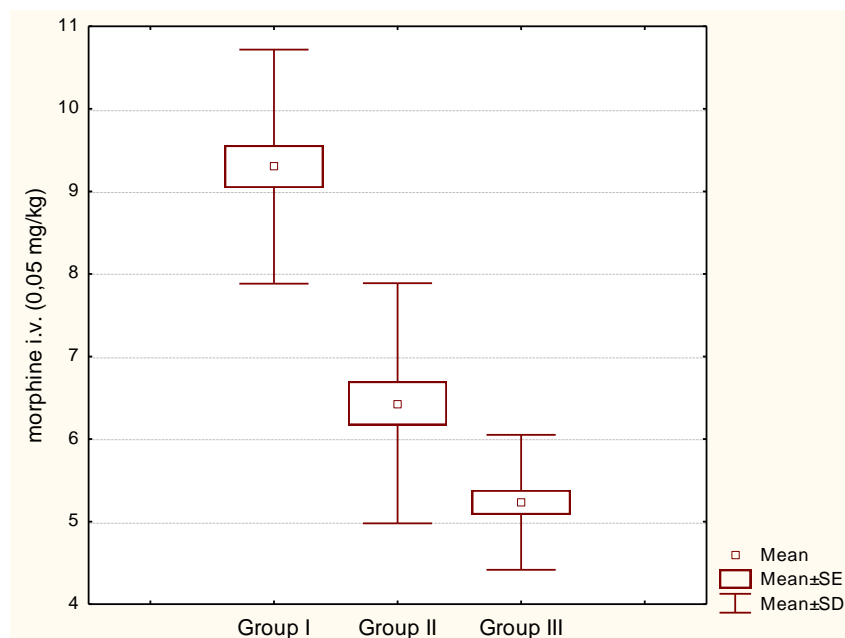


Figure 2 – Cumulative 24 hours morphine consumption after the operation in group I (GA), group II (GA + TAP Block) and group III (GA + D-TAP Block)

The patients were discharged one day after the surgery, highly satisfied with the anesthetic choice. There were no major intra or postoperative complications related to the TAP block and the local anesthetics and adjuvants (Dexamethasone) such as prolonged nerve palsy, hyperglycemia and infection.

Discussion

The TAP block has a number of advantages which include technical simplicity, high analgesic effectiveness, opioid sparing effect and minimal side effects in comparison to that associated with neuroaxial analgesia (e.g., hypotension, motor blockade) [3]. The precise local anesthetics diffusion range can be also checked by ultrasound. The duration of the application of the TAP block in this study was approximately 4–5 minutes. The TAP block has been shown to produce effective analgesia for 48 hours postoperatively.

Multiple studies have demonstrated the superiority of the TAP block over a standard medical therapy for postoperative pain control in abdominal surgery. McDonnell et al. Repor-

ted that bilateral TAP block performed in caesarean sections and large bowel resections reduced post-operative pain and decreased the dosage of morphine used by patient-controlled analgesia by more than 70% [10]. Carney et al. performed unilateral TAP block with the same method in an open appendectomy and they found reduction in postoperative morphine dosage by more than 50% [14].

Our study has several limitations. First of all, we did not assess the total dose of remifentanyl used during the operation and the pain scores and analgesic consumption after 24 hours due to our ward conditions. We did not assess pain on movement but we only assessed the pain at rest at the bed side.

The acute postoperative pain has different components (e.g. nociceptive, inflammatory, and neuropathic because of the direct nerve injury) and all of them are possible targets for postoperative analgesic strategies. The precise mechanism of extend analgetic action of dexamethasone added to the local anesthetics is still unknown. Some studies described a direct effect of glucocorticoids on the nerve conduction while

others reported that dexamethasone induced perineural vasoconstriction with concomitant slower absorption of the administered local anesthetics [15, 16]. After the intracellular uptake, glucocorticoids will activate cytoplasmic glucocorticoid receptors which will bind to glucocorticoid response elements in the DNA. This leads to both a decreased production of inflammatory proteins [COX-2, iNOS, cytoplasmic PLA2, interleukins (ILs), inflammatory chemokines, etc.], and an increased production of anti-inflammatory proteins [lipocortin-1 (IL-1) receptor antagonist] [17].

The anti-inflammatory properties of dexamethasone as a direct effect on the nerve are probably responsible for the prolonged analgesia after plexus brachialis block [17]. Choi S et al. observed that the perineural administration of dexamethasone at a dose of 4–10 mg with local anesthetic prolonged the analgesic duration for long-acting local anesthetic from 730 to 1306 min with 95% confidence interval at patients undergoing plexus brachialis block with no observed adverse events [18].

Perineural local steroid injection has been used for many years in the treatment of the carpal tunnel syndrome and is acknowledged to be an effective and safe therapy [19].

For shoulder surgery, M. Desmet et al. Demonstrates that perineural or i.v. application of dexamethasone in a dose of 10 mg significantly prolongs the duration of the postoperative analgesia resulting from a single-shot Interscalene block preformed with 20 ml of 0.5% ropivacaine [20].

In conclusion, the US-TAP-D block preformed with ropivacaine and 4 mg dexamethasone is an effective and safe adjunct to multimodal postoperative analgesia for unilateral open inguinal hernia. For this operation, the TAP-D block combined with general anesthesia provided better 24 hours analgesia according to the VAS scale and the amount of opioids consumption then analgesia achieved by general anesthesia and the TAP block performed with 25 ml of 0.5% ropivacaine and general anesthesia.

REFERENCES

1. Jankovic Z. Transversus abdominis plane block: The holy grail of anesthesia for (lower) abdominal surgery. *Periodicum biologicum* Vol. III, No 2; 2009: 203–208.
2. Bonnet F, Berger J, and Aveline C. Transversus abdominis plane block: what is its role in postoperative analgesia? *British Journal of Anaesthesia*. 2009; 103 (4): 468–70.
3. MC Donnell JG, Curlry G, Carney J, Benton A, Costello J, Maharaj CH, Laffey JG. The analgesic efficacy of transversus abdominis plane block after Caesarean delivery: A randomized controlled trial. *Anesth Analg*. 2008; 106: 186–191.
4. Carney J, MCDonnell JG, Ochana A, Bhinder R, Laffey JG. The transversus abdominis plane block provides effective postoperative analgesia in patients undergoing total abdominal hysterectomy. *Anesth Analg*. 2008; 107: 2056–2060.
5. O'Donnell BD. The transversus abdominis plane (TAP) block in open retropubic prostatectomy. *Reg Anesth Pain Med*. 2006; 31(1): 91.
6. E. Allcock, E. Spencer, R. Frazer, G. Applegate, and C. Buckenmaier III, "Continuous transversus abdominis plane (TAP) block catheters in a combat surgical environment", *Pain Medicine*, vol. 11, no. 9, 2010; pp. 1426–1429.
7. O'Connor K and Renfrew C, Subcostal transversus abdominis plane block, *Anaesthesia*, vol. 65, no. 1, 2010; 91–92.
8. Adhikary SD, Armstrong K, Chin KJ. Perineural entrapment of an interscalene stimulating catheter. *Anaesth Intensive Care*. 2012; 40: 527–30.
9. Aveline C, Le Hetet H, Le Roux A, et al. Perineural ultrasound-guided catheter bacterial colonization: a prospective evaluation in 747 cases. *Reg Anesth Pain Med*. 2011; 36: 579–84.
10. Bowens C Jr, Briggs ER, Malchow RJ. Brachial plexus entrapment of interscalene nerve catheter after uncomplicated ultrasoundguided placement. *Pain Med*. 2011; 12: 1117–20.
11. Attardi B, Takimoto K, Gealy R, Severns C, Levitan ES. Glucocorticoid induced up-regulation of a pituitary K⁺ channel mRNA in vitro and in vivo. *Receptors Channels*. 1993; 1: 287–93.
12. Eker HE, Cok OY, Aribogan A, Arslan G. Management of neuropathic pain with methylprednisolone at the site of nerve injury. *Pain Med*. 2012; 13: 443–51.
13. Johansson A, Hao J, Sjolund B. Local corticosteroid application blocks transmission in normal nociceptive C-fibres. *Acta Anaesthesiol Scand*. 1990; 34: 335–8.
14. Carney J, Finnerty O, Rauf J, Curley G, McDonnell JG, Laffey JG. Ipsilateral transversus abdominis plane block provides effective analgesia after appendectomy in children: a randomized controlled trial. *Anesth Analg*. 2010; 111: 998–1003.
15. Wang PH, Tsai CL, Lee JS, Wu KC, Cheng KI, Jou IM. Effects of topical corticosteroids on the sciatic nerve: an experimental study to adduce the safety in treating carpal tunnel syndrome, *J Hand Surg Eur*. 2011; Vol 36: 236–43.
16. Shishido H, Kikuchi S, Heckman H, Myers RR. Dexamethasone decreases blood flow in normal nerves and dorsal root ganglia. *Spine*. 2002; 27: 581–6.
17. Barnes PJ. Anti-inflammatory actions of glucocorticoids: molecular mechanisms. *Clin Sci*. 1998; 94: 557–72.
18. Choi S, Rodseth R, McCartney CJ. Effects of dexamethasone as a local anaesthetic adjuvant for brachial plexus block: a systematic review and meta-analysis of randomized trials. *Br J Anaesth*, Mar. 2014; 112(3): 427–39.
19. Marshall SC, Tardif G, Ashworth NL. Local corticosteroid injection for carpal tunnel syndrome. *Cochrane Database Syst Rev*. 2007; 18: CD001554.

20. M. Desmet, H. Braems, M. Reynvoet S. Plasschaert, J. Van Cauwelaert, H. Pottel, et al. I.V. and perineural dexamethasone are equivalent in increasing the analgesic duration of a single-shot interscalene block with ropivacaine for shoulder surgery: a prospective, randomized, placebo-controlled study. Br. J. Anaesth. 2013; 111 (3): 445–452.

Резиме

ЕФЕКТОТ НА ДОДАВАЊЕ ДЕКСАМЕТАЗОН КАКО АДЈУВАНС НА РОПИВАКАИН ПРИ ИЗВЕДУВАЊЕ УЛТРАЗВУЧНО ВОДЕН ТРАНСФЕРЗУС АБДОМИНИС ПЛЕИН БЛОК ПРИ ИНГВИНАЛНА ХЕРНИОПЛАСТИКА

Андрејан Карталов¹, Никола Јанкуловски³,
Билјана Кузмановска¹, Милка Здравковска²,
Мирјана Шошолчева⁵, Татјана Спировска¹,
Александра Пановска-Петрушева¹,
Марија Толевска¹, Марија Срцева¹,
Весна Дурнев¹, Ѓорѓи Јота³, Реџеп Селмани³,
Атанас Сивевски⁴

- ¹ Клиника за анестезија, реанимација и интензивно лекување – КАРИЛ, Медицински факултет, Универзитет „Св. Кирил и Методиј“, Скопје, Р. Македонија
² Факултет за медицински науки – Универзитет „Гоце Делчев“, Штип, Р. Македонија
³ Клиника за абдоминална хирургија, Универзитет „Св. Кирил и Методиј“, Скопје, Р. Македонија
⁴ Универзитетска клиника за гинекологија и акушерство, Медицински факултет, Универзитет „Св. Кирил и Методиј“, Скопје, Р. Македонија
⁵ Универзитетска клиника „Св. Наум Охридски“, Медицински факултет, Скопје, Р. Македонија

Вовед: Трансверзус абдоминас плеин блок (ТАП) е регионална анестезиолошка техника која обезбедува аналгезија на париеталниот пе-

ритонеум, на кожата и на мускулите на предниот абдомен

нален сид. Целта на оваа рандомизирана двојно слепа студија беше да се оцени постоперативната аналгезија на пациентите подложени на отворена ингвинална херниопластика под општа анестезија (ОА), (ОА + ТАП блок) и (ОА + ТАП-Д блок) при што како ајуванс на ропивакаин се користеше дексаметазон во доза од 4 mg.

Методи: 90 (АСА I–II) возрасни пациенти за отворена ингвинална херниопластика беа вклучени во оваа студија. Во групата I (n = 30), пациентите примија само општа анестезија (ОА). Пациентите од групата II (n = 30) примија ОА и ТАП блок изведен со 25 ml, 0,5% ропивакаин, и пациентите во групата III (n = 30) примија ОА и ТАП-Д блок изведен со 25 ml, 0,5% ропивакан + 4 mg дексаметазон. Во оваа студија се оценуваше степенот на болка според VAS-скалата при одмор на 2, 4, 6, 12 и 24 часа по оперативната интервенција и вкупната аналгетска потрошувачка на морфиум во текот на 24 часа.

Резултати: Постојат статистички значителни разлики во однос на VAS-резултатите помеѓу групата I, групата II и групата III во наведените постоперативни времиња – 2 часа, 4 часа, 6 часа, 12 часа и 24 часа (p < 0,00001). Кумулативниот 24-часовен потрошувачка на морфинот по операцијата беше значително помал во групата III (5,53 1,21 mg) во однос на групата II (6,16 2,41 mg) и групата I (9,26 2,41 mg). Оваа разлика е статистички значајна (p < 0,00001).

Заклучок: За ингвинална херниопластика добивме подобри постоперативни резултати за степенот на болка според VAS-скалата и 24-часовна помала потрошувачка на морфиум во групата III (ОА и ТАП-Д блок) во споредба со групата I (ОА) и групата II (ОА + ТАП блок).

Клучни зборови: отворена ингвинална херниопластика, ултразвучно изведен ТАП блок, ропивакаин, дексаметазон