

OVERDENTURES ON IMPLANTS FOR BETTER QUALITY OF LIFE AMONG THE FULLY EDENTULOUS PATIENTS – CASE REPORTS

Julijana Nikolovska¹, Dragan Petrovski¹, Nikola Petricevic², Biljana Kapusevska¹, Vesna Korunoska-Stevkovska¹

¹ Faculty of Dental Medicine, University of Ss. Cyril and Methodius, Skopje, R. Macedonia

² Faculty of Dental Medicine, University of Zagreb, Croatia

Corresponding Author: Julijana, Nikolovska Faculty of Dental Medicine, University of Ss. Cyril and Methodius, Skopje, R. Macedonia; E-mail: julijananiolovska2@gmail.com

Abstract

Global aging population has brought several challenges for their medical systems and total edentulism is one of them. The fabrication of removable acrylic dentures seems to be a simple and cheap treatment solution, but a majority of patients is not satisfied with their functional instability, causing limited diets, mouth soreness, speech and psycho-social problems etc. The results in many studies indicate an impact of oral conditions associated with the full denture wearing on oral-health related quality of life, especially in lower jaw. The reason for improper denture retention could be alveolar ridge bone resorption and numerous studies about this problem are plausible. Bone resorption in lower jaw may turn the alveolar ridge into a flabby soft tissue which is unable to sustain proper denture retention.

The implant-retained prosthesis is an alternative treatment option in these situations. Implants will provide retention, stability, function and aesthetics and they are not so expensive solution.

The aim of this article is to show solving of retention problems of a lower denture in two different clinical cases using implants and without any special technology.

Key words: overdentures, implants, quality of life

Introduction

Global aging population has brought several challenges for their medical systems and total edentulism is one of them. Removable dentures for elderly have to meet special requirements of the aged oral system, meaning reduced motor control in insertion and maintenance of denture and oral suprastructure. It has been documented that oral health disabilities should have an influence on peoples 'quality of life [1]. In everyday clinical practice, dental practitioners should take care of patients' ability for fulfilling their activities which means that the impact of oral disease, its treatment and its consequences on quality of life should be taken into account when assessing health status [2–3].

The fabrication of removable acrylic dentures seems to be a simple and cheap treatment solution, but a majority of patients are not satisfied with their functional instability, causing limited diets, mouth soreness, speech and psycho-social problems etc. The results in many studies indicate an impact of oral conditions associated with full denture wearing on oral-health related quality of life [4–8].

The reason for improper denture retention could be alveolar ridge bone resorption and numerous studies about this problem are plausible. This phenomenon is progressive and irreversible and booming sales of various denture adhesives are noted [9]. The amount and rate of alveolar bone resorption depend on age,

sex, facial anatomy, metabolism, oral hygiene, parafunctions, general health, nutritional status, systematic diseases, reduced motor control, osteoporosis, drug administration and time of edentulism [10, 11]. Especially, lower jaw bone resorption may turn the alveolar ridge into a flabby soft tissue which is unable to sustain proper denture retention. Nutritional intake of elderly patients could be improved by stabilizing their complete dentures with implants and improving the force and the efficiency of chewing. The implant-retained prosthesis has become an integral part of prosthodontic therapy. Implants will provide retention, stability, function and aesthetics especially in the mandible. Compromised conventional denture retention in cases of advanced bone ridge resorption, atrophy, is situation where implants should be discussed.

Modern implantology offers a wide range of solutions in such cases. These include very often a higher number of implants inserted, in combination with latest technological gadgets for the treatment planning, implant insertion and consecutive fixed or removable prostheses fabrication. Usually, fixed prosthetic appliance with superior aesthetics and function which is very expensive is fabricated. On the other side, a two-implant overdenture can also be reliable and cheap therapy for patients with an edentulous mandible [12]. It is a very attractive treatment option for two main reasons: a relatively uncomplicated and easy to insert implant placement in the desired intraforaminal part of the alveolar ridge (no nerves or vessels which could be harmed), combined with the fabrication of a common acrylic removable denture, which requires no special technology or know-how to fabricate. Comparative prospective studies have validated the benefit of two or four implants in the edentulous mandible [13–17]. Survival rates in the two-implant overdenture groups compared with four-implant overdenture groups appear to be equivalent for patient satisfaction.

Many studies reported that implant-supported dentures offer the possibility of overcoming some of the limitations of conventional removable dentures in terms of chewing efficiency. Subjects who received implant overdenture reported significant improvement in chewing what does not necessarily result in a satis-

factory food selection and diet, since half of them still avoid eating hard food [18].

It should be emphasized that special attention should be given to the selection of suprastructure, which stabilizes the denture and provides denture support. When the type of retention was analysed thorough the literature, it was observed that in the most of the publications a bar or a ball were used as an attachment connection to overdenture. The most used treatment option was two-implant-supported overdentures retained by ball attachments and single- or triple-bar. Bar attachments require a lot of vertical space and fabrication cost is high, while ball attachments require little space, but they wear. Telescopic crowns are also costly [19], while magnets are not used anymore, since they provide low retentive forces [20]. The attachment system that is widely used today and offers a reliable option beside implants is telescopic system.

Aim

The aim of this article is to present solving of retention problems of a lower denture in two different clinical cases using implants and without any special technology.

Case 1

A 70 years old edentulous patient with advanced alveolar ridge resorption had problems adopting the lower denture, complaining its instability in almost every situation (during speech, eating etc.). It was decided to insert 2 implants (Straumann) in the lower jaw applying the following procedure: In order to enable proper implant position in accordance to the existing denture, a replica is fabricated to serve as surgical stent (Figure 1). This replica can be made in different ways; we opted to use the Lang denture duplicator technique. The replica was cast in transparent acrylic and inserted into patient's mouth to adjust proper seating and occlusion. The most adequate implant position was suggested by the oral surgeon. Alternatively, on this stent grooves can be grinded, in which pieces of strait wire can be glued, to serve as an X-ray template for the consecutive OPG, as well (Figure 2). In our case this surgical stent simply serves as a frame, in which the oral surgeon can place the implants (Figure 1).

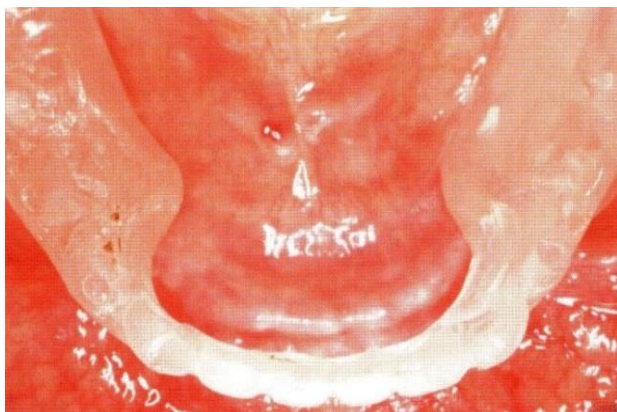

Figure 1 – Transparent acrylic replica

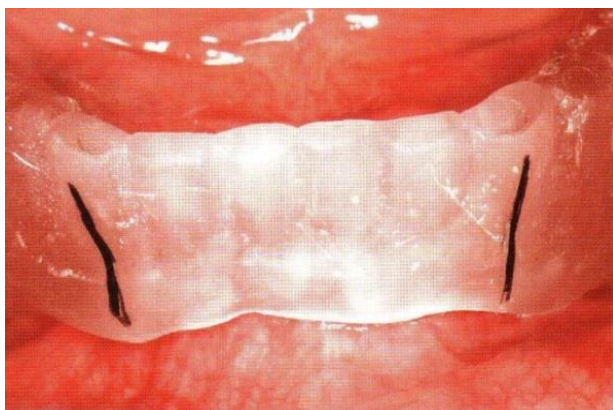


Figure 2 – Inserted wire pieces

When implants are placement the osseointegration healing period of 3–6 months begins, in which the patient can wear his old denture (Figure 3, 4). After the period of osseointegration, implants are exposed and the attachment pieces (Locator) are mounted (Figure 5, 6). On the denture base, where the female attachment parts need to be fixed, holes are drilled (Figure 7). The denture must be fitted, until it seats in the original position, together with the attachment parts. First a false plastic female part is attached, together with the female housing, and a plastic foil is put around the implant retention male suprastructure in the mouth (Figure 8, 9). This foil is important to block out acrylic resin, which could flow around the implant during the looting. This fitting should be loose, i.e. there should be enough space around the attachment for the fixating auto polymer acrylic. It is also possible to drill out the whole lingual part of the denture base to have a direct look at the available space. The implants together with the attachments, as well as the denture base are dried and the auto polymer acrylic is prepared. The acrylic is applied in the

denture base and the attachments, the denture is placed in patients' mouth, and he is asked to close in centric relation. The acrylic must set, and then the denture is detached from his mouth, together with the female attachment, which is now a part of the denture base. At the end, the denture is shaped to appropriate form by grinding off any acrylic residua and suffices, and polished (Figure 10). The plastic foil and the dummy attachment are removed, and the final plastic attachment is inserted. The patient is instructed how to use the denture and advised to take proper oral hygiene.

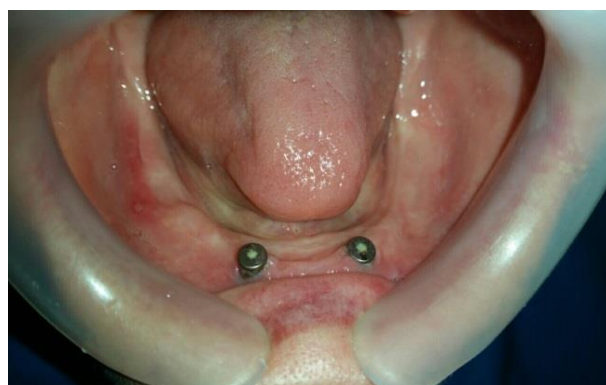


Figure 3 – Implants in situ (sulcus former)

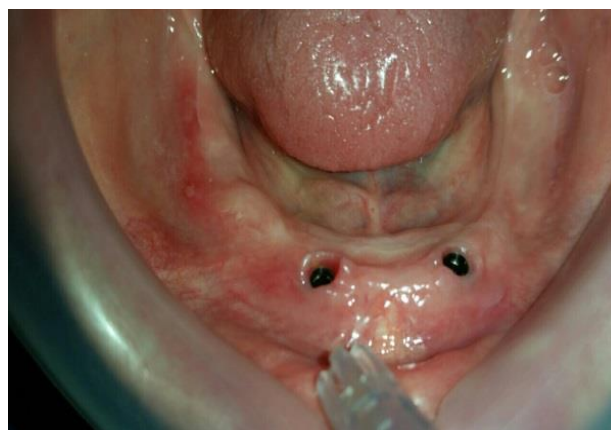


Figure 4 – Implants in situ

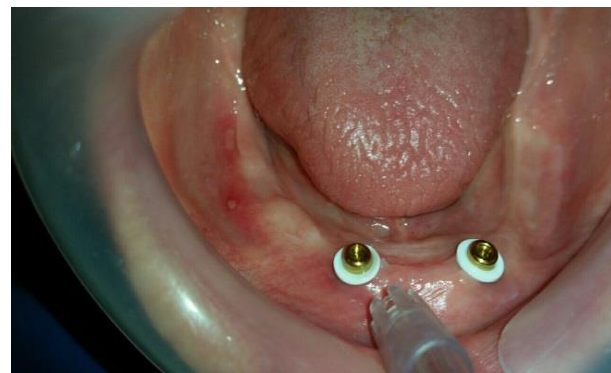

Figure 5 – Attachment pieces mounted (Locators)

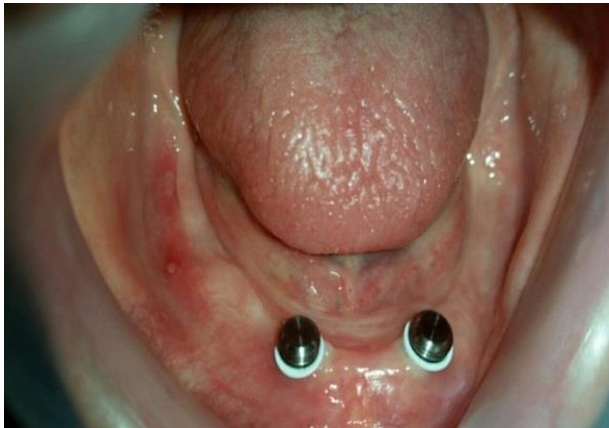

Figure 6 – Attachment pieces mounted (Locators)

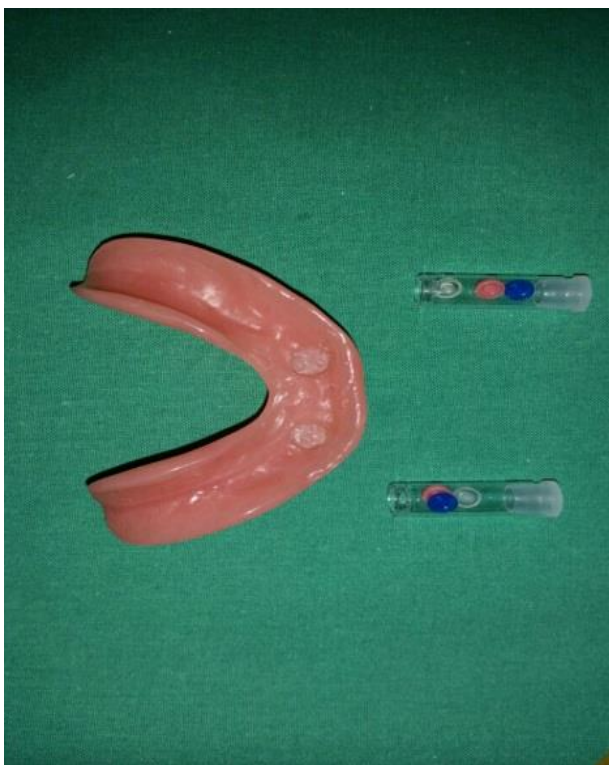

Figure 7 – Drilled holes in lower denture

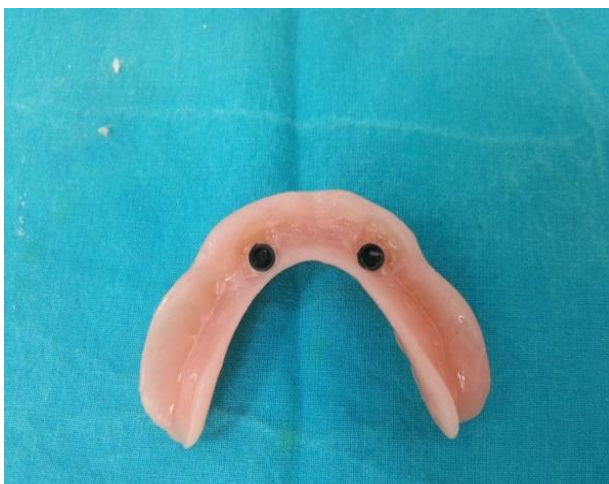

Figure 8 – Overdenture with black processing males

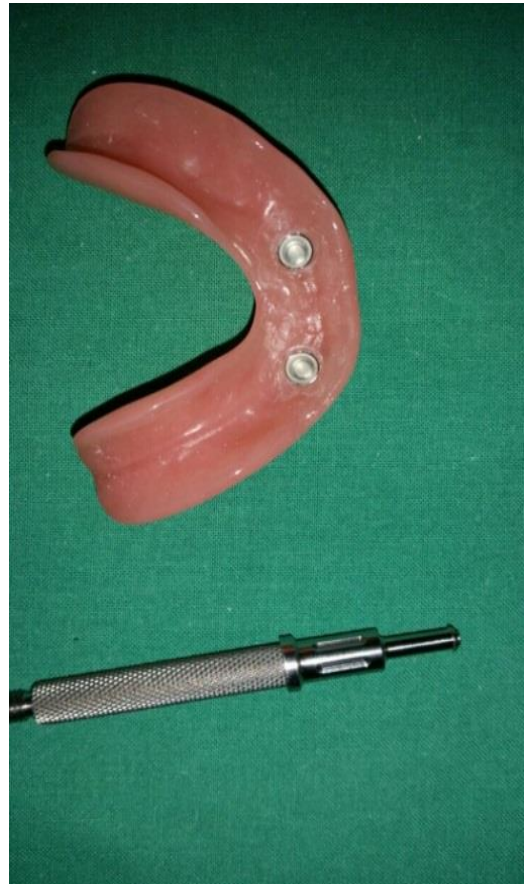

Figure 9 – Replacement male with the core tool

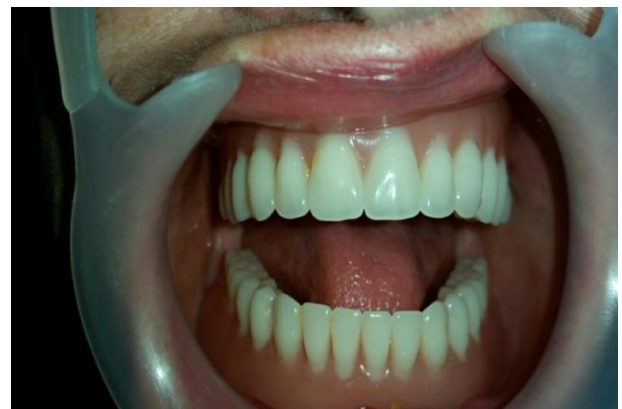

Figure 10 – Shaped denture by grinding off any acrylic residua and polished

Case 2

Fifty four year olds woman was complying on stability of lower denture. This case shows how simply a common acrylic lower denture can be transformed into a good integrated implant overdenture just by using 4 simple one piece ball attachment implants (Cortex SD) placed in the intraforaminal region of the mandible (Figure 11, 12). In healing period of 4 months she wore her old dentures with spaces around the ball-attachments. The dental technician was

instructed just to place spacers around the ball attachments. In the final stage the dentist must ensure that the denture fits into the final position with enough space around the mounted retention parts (Figure 13). For that purpose the

denture base can be drilled until it fits (Figure 14). At the end the retention pieces were glued separately into the denture base with self-curing denture acrylate, while the patient closes in centric relation (Figures 15, 16).

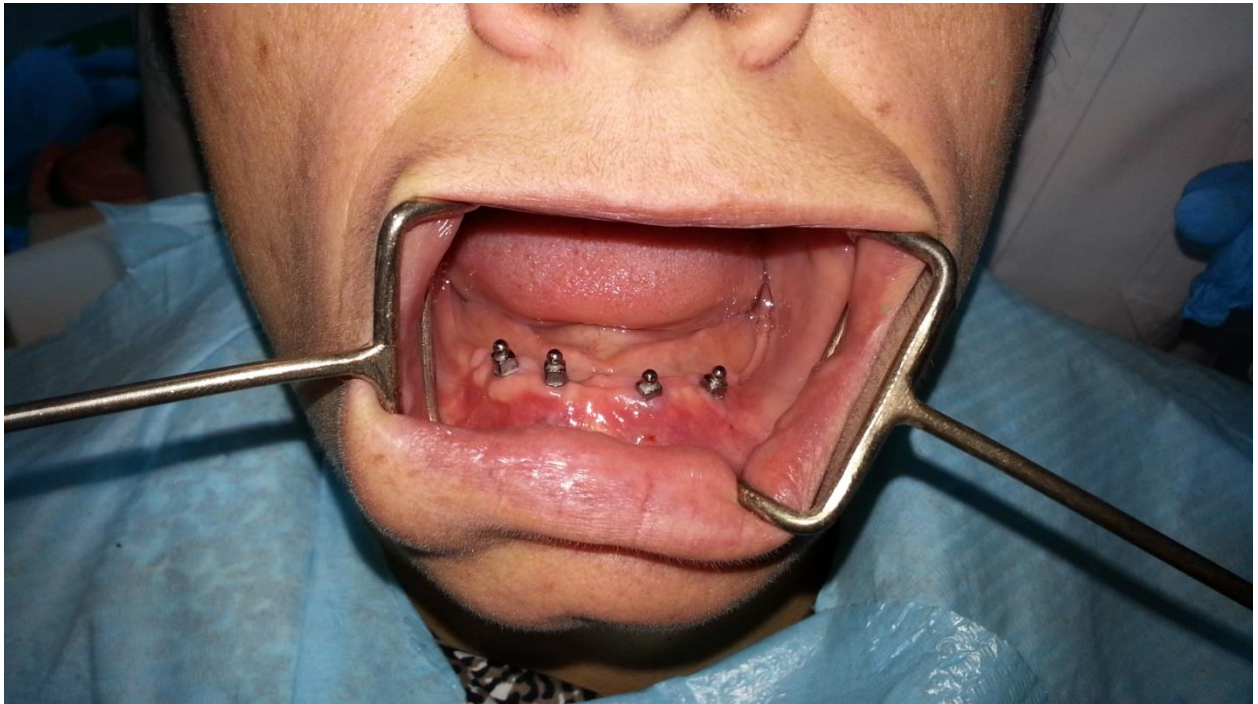

Figure 11 – One piece ball attachment implants

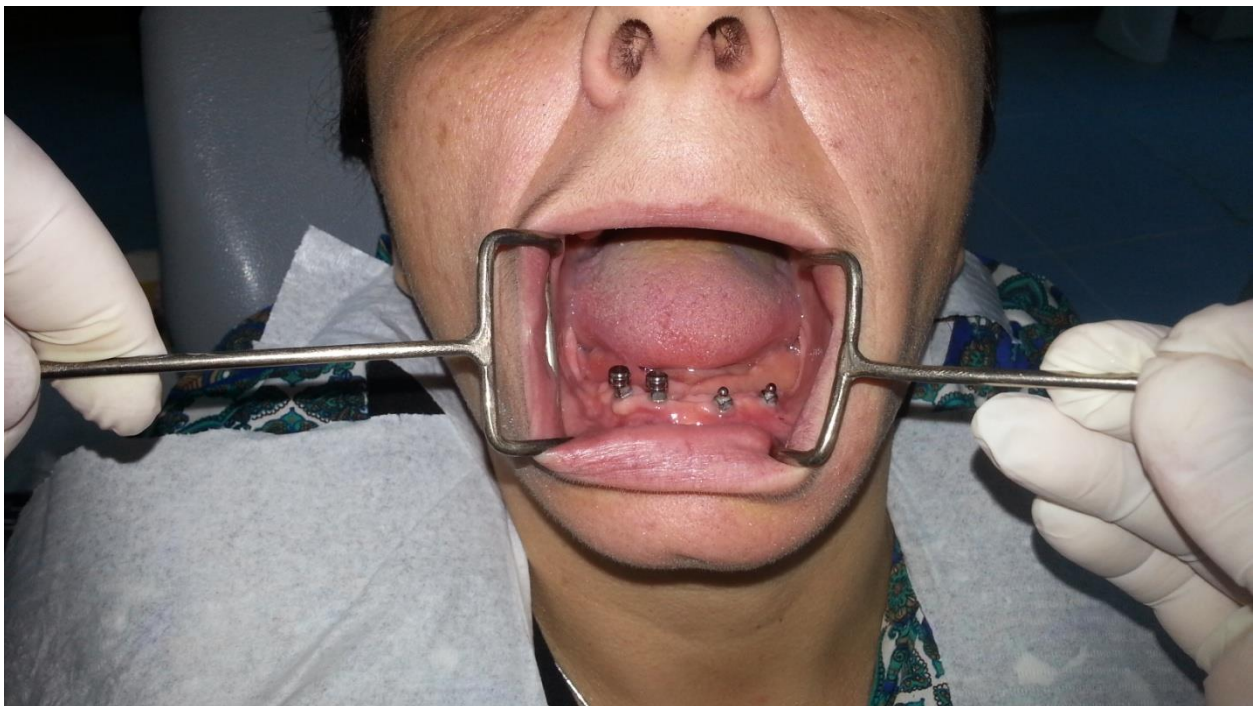


Figure 12 – One piece ball attachment implants

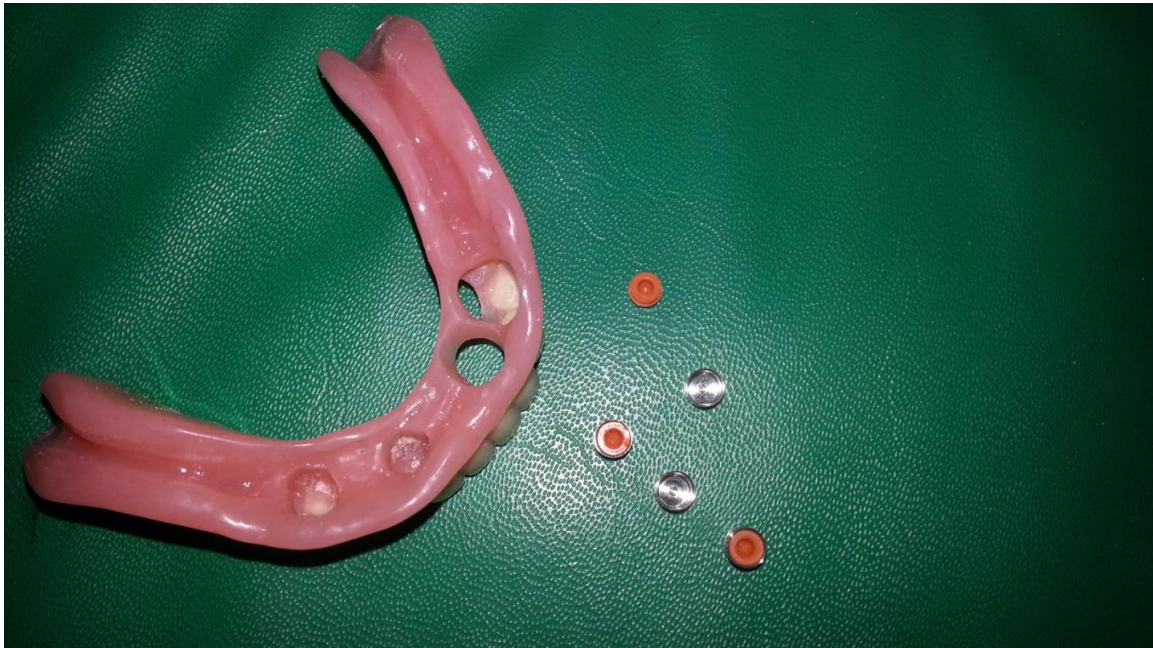

Figure 13 – Spacers for the ball attachments

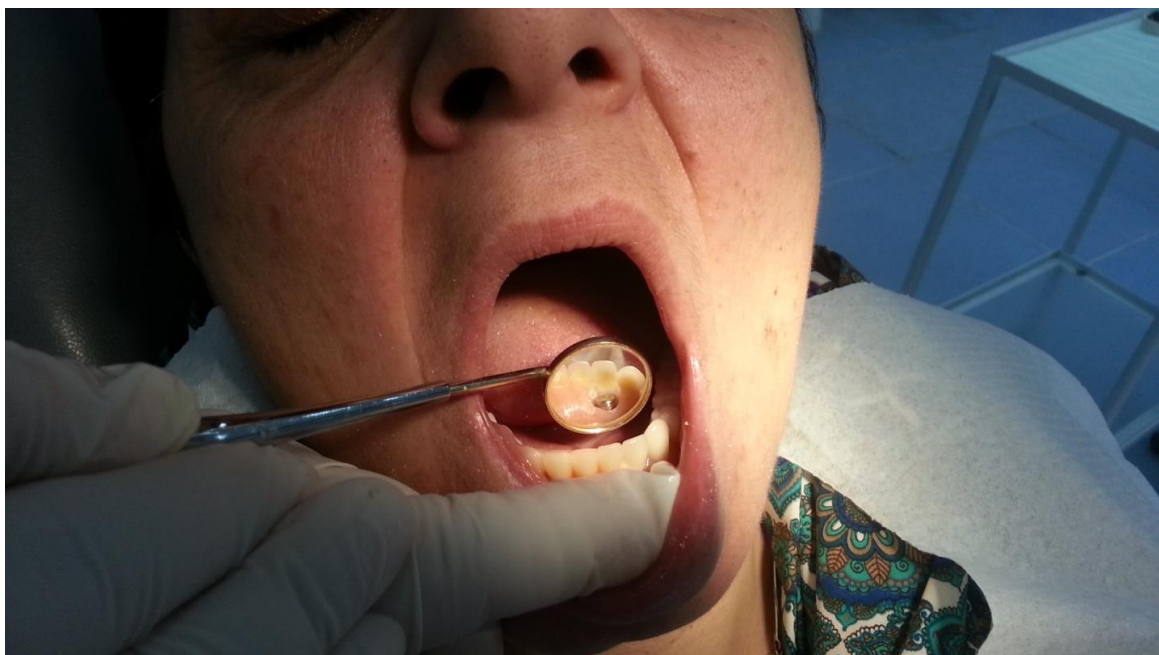


Figure 14 – Spacers for mounted retention parts

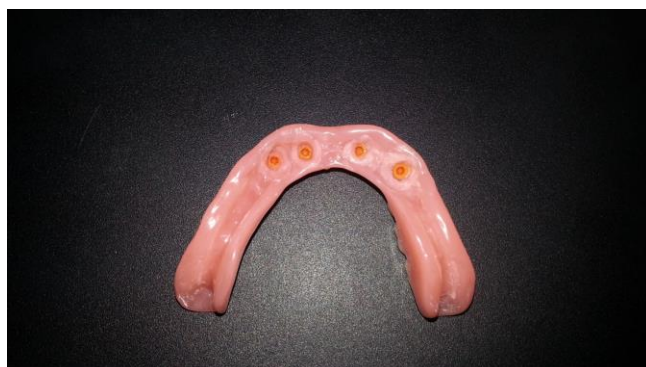

Figure 15 – Retention pieces glued into the denture base with self-curing acrylate

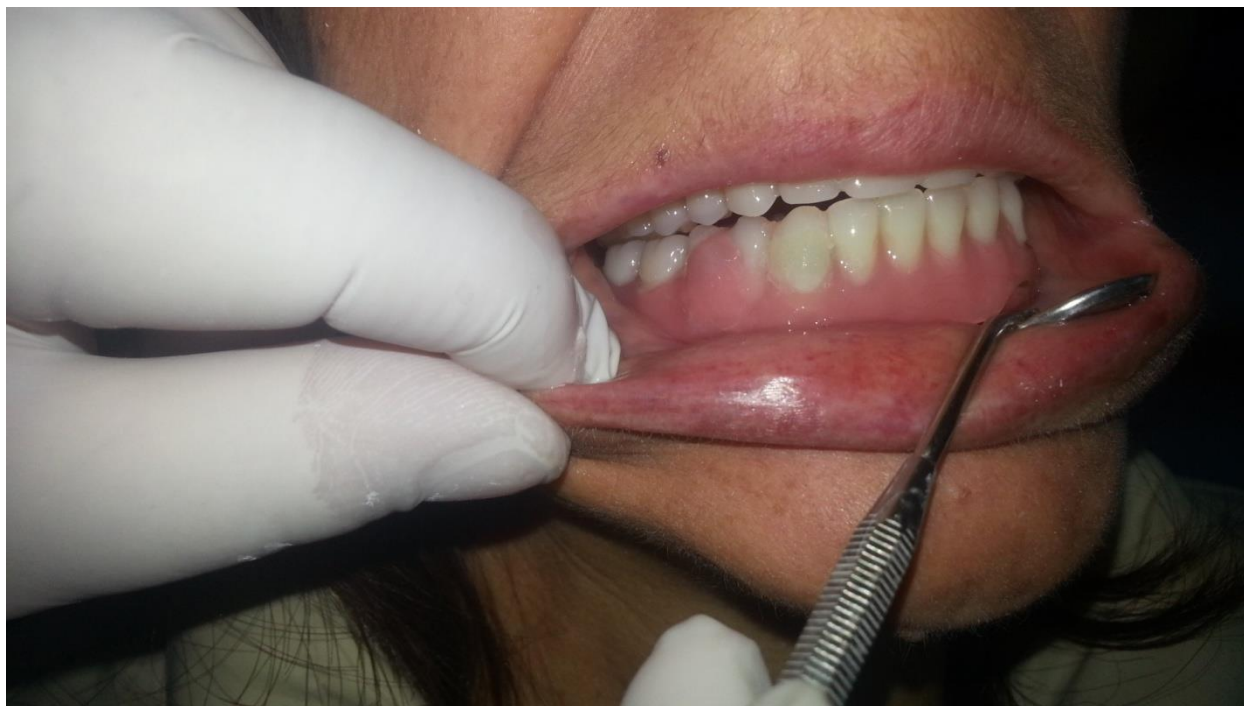

Figure 16 – Patient closes in centric relation

Discussion

There is an array of treatment possibilities for the fully edentulous patient, regarding number of implants and complexity of the prosthodontic superstructure.

Factors for individual treatments are:

- Patient-related factors: patient's expectations, subjective aesthetics, phonetics, financial commitment, comfort, compliance and maintenance of oral hygiene;

- Absence of signs and symptoms: persistent pain, infection, neuropathy, invasion of the mandibular channel or chronic sinusitis;

- Extra oral factors: patient's co-morbidities, objective aesthetics, facial profile, type of smile line, and lip support;

- Intraoral factors: local anatomy (fibromas, bands, muscle attachments, floor of mouth frenula), maxillo-mandibular relationship, presence or absence of buccal fold, keratinized attached mucosa and jaw bone quality and quantity, edentulous crestal morphology (shape, height and width) and prosthesis crown position in the sagittal plane [21].

The implant born removable denture with 2 implants is an efficient and quick way to solve retention problems, especially in the lower denture. As seen above, this technique is very simple, yet efficient. The oral surgery is mostly risk free, and there is no special equipment

needed for the prosthodontic part, so every prosthodontist is able to perform the working steps. Straumann's Locator abutment (Case 1) characteristics include divergence compensation up to 40° between two implants and minimum component height for limited occlusal space. Their reliability is dual retention for optimal abutment-denture connection and excellent long-term performance due to high wear resistance of components.

The implant-retained overdenture proves to be a predictable and effective treatment of edentulous patients. Biological (e.g. non-osseointegration, peri-implantitis, mucositis with or without inflammatory hyperplasia) and biomechanical complications (e.g. fracture or detachment of the clip anchorage fracture of the prosthesis or its parts, etc.) can occur, but the literature still reports years of success [22].

The implant-supported overdenture's biggest advantage is a better distribution of occlusal forces between implant and bone. This results in a reduction of alveolar ridge resorption; longitudinal clinical studies report a loss of bone height adjacent to the implants of approximately 1.2 mm at the end of the first-year and 0.2 mm annually. This resorption is lower compared to the reduction of 4 mm at the end of the first year and 0.4 mm annually after tooth extraction when fitting with conventional dentures [23].

Many options are available for retention of the prosthesis, including magnets, clips, bars and ball. The resultant implant-supported overdenture has good stability and retention. Most authors agree on a requirement of a passive fit between the prosthesis framework and osseointegrated dental implants.

Overdenture wearers show a masticatory performance and chewing cycles similar to those with natural teeth. They also document an increase of comfort and satisfaction in patients with their overdentures compared to patients wearing conventional dentures. A study addressing two mandibular implant-supported overdenture concludes that this significantly improves oral function. After ten years of function, values for maximum bite force and masticatory performance remain unaltered. Thus, the improved oral function lasts for a long period of time with high levels of satisfaction regarding various aspects of patients denture function. If similar oral functions problems exist, implant-supported patients report a greater level of satisfaction [24–29].

The literature indicates that the implant overdenture prosthesis provides predictable results – enhanced stability, function and a high-degree of satisfaction compared to conventional removable dentures. This is as a result of positive outcomes of long-term clinical studies, specifically using a conventional loading protocol. Further studies focusing on immediate and early loading in maxillary overdenture are necessary [30–33].

Conclusion

Patients with implant overdenture prosthesis in our both cases became satisfied with the functional stability of dentures and they didn't have any problems with dentures retention which consequently improved their quality of life.

REFERENCES

1. Locker D. Measuring oral health: a conceptual framework. *Community Dent Health*. 1988; 5(1): 3–18.
2. Gerritsen A, Allen P, Witter D, Bronkhorst E, Creugers N. Tooth loss and oral health-related quality of life: a systematic review and meta-analysis. *Health and Quality Life Outcomes*. 2010; 8: 126. DOI: 10.1186/1477-7525-8-126.
3. Nikolovska J, Kenig N. Oral Health Related Quality of Life (OHRQoL) in Patients Wearing Fixed Partial Dentures. *Coll. Antropol.* 2014; 38(3): 987–992.
4. Nikolovska J, Petrovski D. Oral Health-Related Quality of Life (OHRQoL) Before and After Prosthodontic Treatment with Full Removable Dentures. *Balk J Stom.* 2012; 16: 169–172.
5. John MT, et al. OHRQoL in patients treated with fixed, removable and complete dentures 1 month and 6 to 12 months after treatment. *Int J Prosthodont.* 2004; 17: 503–511.
6. Petricevic N, Celebic A, Papic M, Rener-Sitar K. The Croatian version of the Oral Health Impact Profile-questionnaire. *Collegium Antropologicum*. 2009; 3: 315–321.
7. Kenig N, Nikolovska J. Assessing the Psychometric Characteristics of the Macedonian Version of the Oral Health Impact Profile Questionnaire (OHIP-MAC49). *Oral Health Dental Management*. 2012; 11(1): 29–38.
8. Szentpetery A, John MT, Slade G, Setz J. Problems Reported by Patients before and after Prosthodontic Treatment. *Int J Prosthodont.* 2005; 18(2): 124–131.
9. Carlsson GE. Clinical morbidity and sequelae of treatment with complete dentures. *J Prosthet Dent*. 1998; 79: 17–23.
10. Kreisler M, Behneke N, Behneke A, D'Hoedt B. Residual ridge resorption in the edentulous maxilla in patients with implant-supported mandibular overdentures: an 8-years retrospective study. *Int J Prosthodont.* 2003; 16: 265–300.
11. Carlsson GE. Responses of jaw bone to pressure. *Gerodontology*. 2004; 21: 65–70.
12. Vercruyssen M, Marcelis K, Coucke W, Naert I, Quirynen M. Long-term, retrospective evaluation (implant and patient-centred outcome) of the two-implants-supported overdenture in the mandible. Part 1: survival rate. *Clin Oral Implants Res*. 2010 Apr 1; 21(4): 357–365.
13. Batenburg RHK, Raghoobar GM, Van Oort RP, Heijdenrijk K, Boering G. Mandibular overdentures supported by two or four endosteal implants. A prospective, comparative study. *Int J Oral Maxillofac Surgery*. 1998b; 27: 435–439.
14. Wismeijer D, Van Waas MAJ, Mulder J, Vermeeren JJ, Kalk W. Clinical and radiographical results of patients treated with three treatment modalities for overdentures on implants of ITI dental implant system. A randomized controlled clinical trial. *Clin Oral Implants Res*. 1999; 10: 297–306.
15. Mau J, Behneke A, Behneke N, Fritzemeier CU, Gomez-Roman G, D'Hoedt B, Spiekermann H, Strunz V, Yong M. Randomized multicenter comparison of 2 IMZ and 4 TPS screw implants supporting bar-retained overdentures in 425 edentulous mandibles. *Int J Oral Maxillofac Implants*. 2003; 18: 835–847.
16. Visser A, Raghoobar GM, Meijer HJA, Batenburg RHK, Vissink A. Mandibular overdentures supported by two or four endosseous implants. A 5-year prospective study. *Clin Oral Implants Res*. 2005; 16: 19–25.

17. Stoker GT, Wismeijer D, Van Waas MAJ. An eight-year follow-up to a randomized clinical trial of after-care and cost-analysis with three types of mandibular implant-retained overdentures. *J Dent Res.* 2007; 86: 276–280.
18. Petricevic N, Celebic A, Renner-Sitar K. Improvement of Patient's Satisfaction 3 and Oral Health Related Quality of Life by the 4 Implant and Prosthodontic Treatment. *Oral Health/ Book 2, 2012; In Tech:* 1–28.
19. Heckmann SM, Schrott A, Graef F, Wichmann MG, Weber HP. Mandibular two-implant telescopic overdentures. *Clin Oral Implants Res.* 2004 Oct; 15(5): 560–9.
20. Andreiotelli M, Att W, Strub JR. Prosthodontic complications with implant overdentures: a systematic literature review. *Int J Prosthodont.* 2010 May-Jun; 23(3): 195–203.
21. Laurito D, Lamazza L, Spink MJ, De Biase A. Tissue-supported dental implant prosthesis (overdenture): the search for the ideal protocol. A literature review. *Ann Stomatol (Roma).* 2012 Jan; 3(1): 2–10. Epub 2012 May 3.
22. Murphy WM. Clinical and experimental bone changes after intraosseous implantation. *J Prosthet Dent.* 1995; 73: 31–35.
23. Von Wowern N, Gotfredsen K. Implant-supported overdentures, a prevention of bone loss in edentulous mandibles? A 5-year follow-up study. *Clin Oral Implants Res.* 2001; 12: 19–25.
24. Van der Bilt A, Burgers M, van Kampen FM, Cune MS. Mandibular implant-supported overdentures and oral function. *Clin Oral Implants Res.* 2010; 21: 1209–1213.
25. Balaguer J, García B, Peñarrocha M, Peñarrocha M. Satisfaction of patients fitted with implant-retained overdentures. *Med Oral Patol Oral Cir Bucal.* 2011; 16: 204–209.
26. Naert I, Alsaadi G, Van Steenberghe D, Quirynen M. A 10-year randomized clinical trial on the influence of splinted and unsplinted oral implants retaining mandibular overdentures: peri-implant outcome. *Int J Oral Maxillofac Implants.* 2004 Sep-Oct; 19(5): 695–702.
27. Naert I, Quirynen M, Hooghe M, Van Steenberghe D. A comparative prospective study of splinted and unsplinted Branemark implants in mandibular overdenture therapy: a preliminary report. *J Prosthet Dent.* 1994; 71: 486–492.
28. Mericske-Stern R. Treatment outcomes with implant-supported overdentures: clinical considerations. *J Prosthet Dent.* 1998; 79: 66–73.
29. Meijer HJ, Raghoobar GM, Batenburg RH, Visser A, Vissink A. Mandibular overdentures supported by two or four endosseous implants: a 10-year clinical trial. *Clin Oral Implants Res.* 2009 Jul; 20(7): 722–728.
30. Takeshita S, Kanazawa M, Minakuchi S. Stress analysis of mandibular two-implant overdenture with different attachment systems. *Dent. Mater. J.* 2011; 30: 928–934.
31. Tokuhisa M, Matsushita Y, Koyano K. In vitro study of a mandibular implant overdenture retained with ball, magnet, or bar attachments: Comparison of load transfer and denture stability. *Int J Prosthodont.* 2003; 16: 128–134.
32. Aglietta M, Siciliano VI, Zwahlen M, Bragger U, Pjetursson BE, Lang NP, Salvi GE. A systematic review of the survival and complication rates of implant supported fixed dental prostheses with cantilever extensions after an observation period of at least 5 years. *Clin. Oral Impl. Res.* 20, 2009; 441–451.
33. Pjetursson BE, Bragger U, Lang NP, Zwahlen M. Comparison of survival and complication rates of tooth-supported fixed dental prostheses (FDPs) and implant-supported FDPs and single crowns (SCs). *Clin. Oral Impl. Res.* 18 (Suppl. 3), 2007; 97–113.

Резиме

ПОКРОВНИ ПРОТЕЗИ НАД ИМПЛАНТИ ЗА ПОДОБАР КВАЛИТЕТ НА ЖИВЕЕЊЕ КАЈ БЕЗЗАБНИ ПАЦИЕНТИ – ПРИКАЗ НА СЛУЧАЈ

Јулијана Николовска¹, Драган Петровски¹,
Никола Петричевиќ², Билјана Капушевска¹,
Весна Коруноска-Стевковска¹

¹ Стоматолошки факултет, Универзитет
„Св. Кирил и Методиј“, Скопје, Р. Македонија
² Стоматолошки факултет,
Универзитет во Загреб, Хрватска

Старењето на глобалната популација донесе бројни предизвици за здравствените системи и тоталната беззабост е една од нив. Изработката на мобилни акрилатни протези се чини дека е едноставна и евтина третманска солучија, но повеќето пациенти не се задоволни со нивната функционална стабилност, што доведува до ограничувања во исхраната, болки во устата, проблеми со говорот, психосоцијални проблеми итн. Резултатите во многу студии покажуваат промени во квалитетот на живеење кај пациентите што се носители на тотални протези, особено кај оние што имаат тотална протеза во долната вилица. Причината за ваквата состојба е несоодветната ретенција на протезите како резултат на ресорпцијата на коската на алвеоларниот гребен. Коскената ресорпција на долната вилица може да го претвори алвеоларниот гребен во млитаво меко ткиво, кое не е во состојба да поддржува соодветна ретенција на протезата.

Покровни протези ретинирани над импланти е алтернативно третманско решение во овие случаи. Имплантите ќе обезбедат ретенција, ста-

билност, функција и естетика и претставуваат мошне атрактивна третманска солуција, која поголем број пациенти можат финансиски да ја поднесат.

Целта на овој труд е да се прикаже протетското решавање на проблемите со ретенци-

јата на долна протеза во два различни клинички случаи, со употреба на импланти без примена на комплицирана технологија.

Клучни зборови: покровни протези, импланти, квалитет на живеење.