

Jeavons syndrome – updated review

Athanasios Covanis

Former director of Neurology Department
The Children's Hospital Agia Sophia, Athens

Received August 12, 2015
Accepted for publication on-line October 10, 2015
Published on-line October 19, 2015

Correspondence

Dr Athanasios Covanis, MD
5 Riga Fereou, 17455, Alimos
Athens, Greece
Fax: 00 302 109 844 998
e-mail: acovanis@otenet.gr

SUMMARY

Introduction. Eyelid myoclonia and absences (ELMA) was first described by Jeavons in 1977 as a separate type of photosensitive epilepsy.

Aim and method. The aim is to consider the updated electro-clinical pathophysiology and to discuss terminology, classification and differential diagnosis. The review includes our own research and relevant papers on the subject of Jeavons syndrome (JS).

Review and differential diagnosis. Definition: Jeavons syndrome is a generalized idiopathic (genetic) epilepsy syndrome (IGE) characterized by eyelid myoclonia, other seizures (absences, myoclonic and or generalized tonic-clonic) and EEG paroxysms induced by voluntary or on command eye closure, in the light and photosensitivity. **Demographical data:** The prevalence of JS has been reported to vary from 7.3% to 12.9% among idiopathic generalized epilepsies and 2.5% to 2.7% among all patients with epileptic disorders.

Etiology: JS, as is the case for all idiopathic generalized epilepsies, is genetic and the familial preponderance and concordance is high. **Pathophysiology:** Three factors are important in order for JS to manifest clinically; the genetic predisposition, the voluntary or on command eye closure and the light input. **Clinical forms of JS:** we have identified four forms of JS; early onset (<4 years), mild form, classical form and an ELMA-JME form. **Diagnosis:** the diagnosis of JS is based on the history, clinical observation and provocation and the confirmation with an EEG. **Differential diagnosis:** is easily made from tics, other idiopathic generalized or focal cryptogenic/symptomatic epilepsies.

Conclusion. JS is characterized by unique electro-clinical features evoked by voluntary or on command eye closure in the light and photosensitivity.

Key words: epilepsy • eyelid myoclonia • absences • epilepsy with myoclonic absences • eyelid myoclonia and absences • myoclonic seizures

INTRODUCTION

History of Jeavons syndrome

In 1977 Jeavons described eyelid myoclonia and absences as a separate type of photosensitive epilepsy with this quotation: *Eyelid myoclonia and absences show a marked jerking of the eyelids immediately after eye closure and there is an associated brief spike and wave activity. The eyelid movement is like rapid blinking and the eyes*

deviate upwards, in contrast to the very slight flicker of eyelids which may be seen in a typical absence in which the eyes look straight ahead. Brief absences may occur spontaneously and are accompanied by 3 cycles per second spike and wave discharges. The spike and wave discharge seen immediately after eye closure does not oc-

cur in the dark. Their presence in the routine EEG is a very reliable warning that abnormality will be evoked by photic stimulation.

In 1982 Jeavons changed the term from eyelid myoclonia and absences to eyelid myoclonia with absences (Jeavons, 1982); which was a mistake, as he later admitted (Jeavons, 1996). The fact that absences in Jeavons syndrome may occur independently to eye closure e.g. during hyperventilation and intermittent photic stimulation (IPS), makes the term eyelid myoclonia and absences more appropriate than the term eyelid myoclonia with absences.

Since the initial description by Jeavons (1977), numerous reports have supported the existence of this characteristic electro-clinical syndrome (Binnie et al., 1980; Covanis et al., 1982; Panayiotopoulos, 1987; DeMarco, 1989; Binnie and Jeavons, 1992; Appleton et al., 1993; Covanis et al., 1994; Giannakodimos and Panayiotopoulos, 1996; Kent et al., 1998; Striano et al., 2002; Harsono, 2003; Ferrie, 2004; Covanis, 2005; Panayiotopoulos, 2006; Caraballo et al., 2009; Panayiotopoulos, 2010; Covanis, 2010; Kim et al., 2012; Vaudano et al., 2014).

There are three characteristic syndromes where absence and myoclonic seizures predominate in the phenotype: Epilepsy with myoclonic absences (EMA; Tassinari syndrome), facial myoclonic epilepsy with absences and eyelid myoclonia and absences (ELMA; Jeavons syndrome).

In the 2010 ILAE classification of seizures and epilepsies (Berg et al., 2010) eyelid myoclonia is recognized as a unique seizure type and only very recently the ILAE Task Force on classification recognized Jeavons syndrome (Fisher et al., 2015).

AIM

Jeavons syndrome is often underdiagnosed, misdiagnosed and misclassified. The aim of this review is to consider the updated electro-clinical pathophysiology, to discuss terminology, classification and differential diagnosis.

METHOD

This review includes our own research and relevant papers on the subject of Jeavons syndrome. Search for the publications was performed using PubMed and MEDLINE databases up to 2015.

REVIEW AND DIFFERENTIAL DIAGNOSIS

Definition

Jeavons syndrome is a generalized idiopathic (genetic) epilepsy, characterized by unique clinical and EEG features, which follow eye closure (voluntary or on command) and are pathognomonic of this syndrome. Eye closure in the light, induces eyelid flicker, flutter or jerking in association with generalized polyspike-wave or spike-wave EEG discharges 3–6 Hz, and these discharges and clinical phenomena are invariably evoked during IPS, not only on eye closure but also with the eyes opened (Jeavons, 1977; Covanis, 2005; Covanis, 2010). The eyes may open and stare or the eyelids may open, retract and jerk with an upward deviation of gaze (never to the side). Besides eyelid myoclonia, eye closure may also induce concomitant conspicuous or inconspicuous absence seizures, relevant to the duration of the generalized discharge. Myoclonic jerks, other than eyelid involving other areas and generalized tonic-clonic seizures, do occur. The generalized paroxysmal discharges that follow eye-closure, disappear when the eyes open and remain opened, and are enhanced or evoked even with eyes opened during photic stimulation and hyperventilation, constitute the most characteristic EEG finding of Jeavons syndrome. This type of electro-clinical events, do not occur in total darkness. Females predominate (Covanis, 2005).

Demographical data

The prevalence of Jeavons syndrome among idiopathic (genetic) generalized epilepsies has been reported to vary from 7.3% to 12.9% (Covanis et al., 1982; Giannakodimos and Panayiotopoulos, 1996; Covanis, 2005; Covanis, 2010) and 2.5% to 2.7% among all patients with epileptic disorders (Covanis et al., 1982; Giannakodimos and Panayiotopoulos, 1996; Covanis, 2005). Eyelid myoclonia and absences (ELMA) appears to be as common as juvenile myoclonic epilepsy (JME), but is under-diagnosed and the mild forms are misdiagnosed as tics and under-reported. The age of onset for ELMA, as in childhood absence epilepsy, varies from 2 to 14 years (mean 6.5 ± 2.5 years) (Covanis, 2010) and the female to male ratio varies from 1.25 to 3.2 to 4.1:1 (Covanis et al., 1982; Appleton et al., 1993; Caraballo et al., 2009; Covanis, 2010; Striano et al., 2008; Capovilla et al., 2009). In one study 82% were males (Harsono, 2003) and in another study 92% were females (Viravan et al., 2011).

Etiology

Jeavons syndrome is genetically determined and the familial preponderance and concordance rate is high (Bianchi, 1995). In our own cohort of 50 ELMA patients, the family history was positive for epilepsy in 28%. Among them there were nine families of probands with Jeavons syndrome and first degree relatives with ELMA or IGE. The concordance rate was 78%. From these families it is difficult to be specific about the mode of inheritance, although some dominant alleles is suggested (Covanis, 2005). In another study, the family history for epilepsy was 39.5%, the majority with IGE and that of febrile seizures 9.5% (Caraballo et al., 2009). Jeavons syndrome has also been reported by others, in families (De Marco, 1989; Parker et al., 1996), and in monozygotic male twins (Adachi et al., 2005; Yang et al., 2008).

Pathophysiology

Three factors are important in order for Jeavons syndrome to manifest clinically:

- A. The genetic predisposition
- B. The voluntary or on command slow eye closure
- C. The light input

In order for the genetic predisposition to be expressed with electro-clinical phenomena, it needs to be provoked by the voluntary or on command slow eye closure in bright light. Eye closure is a brief, less than 3 msec phase during which the upper and lower eyelids touch.

The genetic predisposition and the light input during IPS can induce generalized discharges associated with clinical phenomena such as conspicuous or inconspicuous absence seizures, with eyes open without eye closure. The genetic predisposition and the voluntary or on command slow eye closure do not induce generalized and irregular spike wave discharges (GSWDs) in total darkness. Passive eye closure does not induce discharges and or clinical phenomena. The hyperexcitable cortical area, genetically predisposed, can induce generalized discharges during sleep in certain cases, without clinical phenomena.

The eyelid movements are under voluntary, automatic, reflex, autonomic and emotional control. The cortical area representing eye closure lies in the pre central gyrus adjacent to the hand area (Leyton and Sherrington, 1917) which is involved in self-induced epilepsy. The 'cortical factor' involved in voluntary or on

command eye closure seems to be important, as passive slow eye closure in the presence of light does not induce discharges or eyelid myoclonia in a predisposed person, except in some cases of early onset. Similar phenomena are observed in self-induced epilepsy where the cortical hand area is involved. The electro-clinical events are induced by a hand waving, voluntary or on command in the presence of light. Passive hand waving, or waving the examiners hand in front of the patient's eye(s) in the presence of light, does not induce discharges and clinical phenomena in a predisposed person.

It seems that in Jeavons syndrome the frontal eye field area, the occipital cortex and subcortical circuits involving the thalamus play an important role in the genesis and spreading of electro-clinical paroxysms in bright light. The frontal eye field area plays a critical role in voluntary eye closure (Van Koningsbruggen et al., 2012), triggering the occipital cortex and subcortical circuit involving the thalamus in generating and spreading the EEG paroxysms. A similar pathway is probably involved in self-induced epilepsy where the patient, waving his preferred hand with fingers apart in front of his eyes, triggers, via hand area, the occipital cortex to generate discharges and a subcortical circuit involving the thalamus to spread them. These systems are not triggered when the examiner, in bright light, closes passively the patient eyes or waves his hand in front of the patient's eyes, in self-induced epilepsy, but the occipital lobe can be triggered directly by flashing lights. The background of genetic variation, unique to each individual's genome, contributes to the clinical variation (Meisler, 2010). In contrast to eye closure, during photic blink (a brainstem reflex), the cerebral cortex is not involved in its generation, as experimental ablation of the occipital cortex does not influence the response (Weiskrantz et al., 1974). During blinking a positive wave is recorded in the frontal areas (fig. 1a). The downward (eye closing) and the upward (eye opening) deflection of the positive blink wave lasts about 100 msec each, while the eye closure phase is very brief with no plateau and no clinical and EEG phenomena (Covanis, 2005; Covanis, 2010). In our population of children with Jeavons syndrome, we have observed three abnormal slow eye closure patterns, either during voluntary or on command order to close the eyes (Covanis, 2005; Covanis, 2010).

Pattern I. Eyes close freely with no initial contraction. At eye closure (plateau phase) a slight flicker or flutter is observed associated with generalized alpha-

theta rhythm with or without spikes. Occasionally the upper lid will fling open and jerk with synchronous slight upward gaze and brief irregular GSWD.

Pattern II. The command to close the eyes is associated with an initial mild eyelid contraction of 30 to 70 msec duration before the eyelids begin to close (fig. 1b). The closing phase lasts for 100 to 200 msec. At the end of eye closure phase, an eyelid contraction is observed, which lasts 100 to 350 msec (plateau) before the eyes attempt to open. At the end of eye closure and during the upward deflection of the positive wave, the opening phase (upward phase of which lasts 150 to 500 msec), the eyelid flicker, flutter, or jerk in association either with a generalized alpha-beta rhythm of 10 to 30 μ V or higher-amplitude irregular spike-wave respectively (fig. 1c). The central posterior spread of the discharge occurs with a delay of less than 100 msec. The stronger the contraction at eye closure, the stronger the jerking during the process of eye opening and the more precise the GSWDs. These discharges become more precise during IPS and maybe associated with jerks other than eyelid (fig. 1d) and during IPS and pattern could be provoked even with the eyes open (fig. 2). The lon-

ger the duration of GSWD, the more likely the process to be repeated, as the child tries to follow the command "close your eyes" and brief absences are observed more clearly. After a few repeats of the clinical and EEG phenomena the eyes remain open. The child gives up the attempt to follow the command to close his eyes, with a sigh of relief.

Pattern III. The command to close the eyes provokes a stronger initial eyelid contraction or jerking which prevent the eyes from closing. The eyes finally close after 500 to 700 msec after the command to close the eyes and then open quickly and stare. The closing of the eyelids is associated with the slow wave and the opening with the spike of the spike-wave complex (Covanis, 2005; Striano et al., 2008).

Some authors believe that in ELMA there is a malfunction of alpha-rhythm generator or a malfunction of the magnocellular and parvocellular system (Wilkins, 1995).

Clinical manifestations

"...There is a marked jerking of the eyelids associated with 3 c/s spike-wave discharges (SWDs) or poly-spike-wave discharges (PSWDs) often irregular, immediately after eye closure..." (Jeavons, 1977).

Eyelid myoclonia is the hallmark of Jeavons syndrome and is only observed during the voluntary or on command slow eye closure in the presence of light. Absence and myoclonic seizures, other than eyelid myoclonia, as well as generalized tonic-clonic seizures, may participate in the clinical expression, as in any other idiopathic generalized epilepsy syndrome recognized by the International Community.

Eyelid myoclonia

Eyelid myoclonia by definition is always present and is expressed by eyelid trembling, flickering, fluttering or myoclonia with a concomitant upward deviation of the eyes and head, associated with a brief conspicuous or inconspicuous absence seizures and simultaneous with generalized paroxysmal EEG activity. The eyes never deviate to the side as in some cases with complex absence seizures. This phenomenon is only produced following slow eye closure, voluntary or on command, in the presence of light. The eyelid movements are rhythmic, single or multiple, slight or marked even in the same patient (Covanis, 2005). The mild eyelid movements on eye closure are associated with beta/alpha/delta rhythm occasionally intermixed with a brief

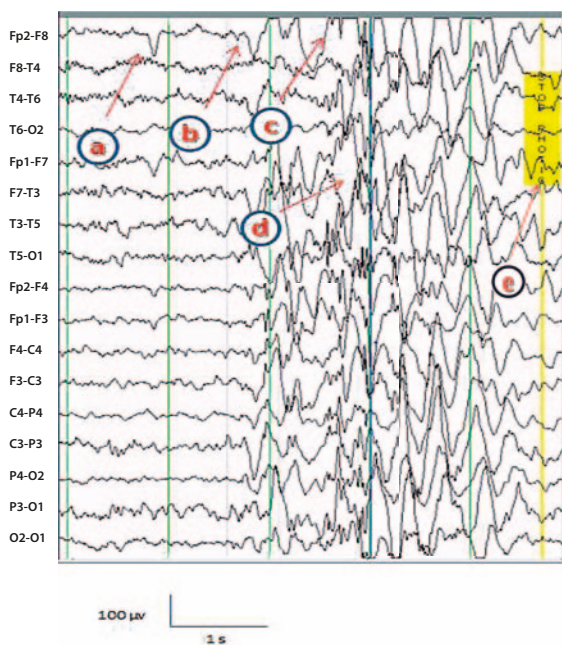


Figure 1. Stellate video-EEG recording and electrodes' placement according to "10-20" international system.

a – eye blink, no discharge; **b, c, d** – On command to close the eyes during IPS: the initial attempt is associated with a brief spasm and failure (**b**), followed by a second attempt where immediately after eye closure, the eyes open and jerk (**c**) with a subsequent brief jerk involving head and shoulders (**d**). Stop photic stimulation (**e**).

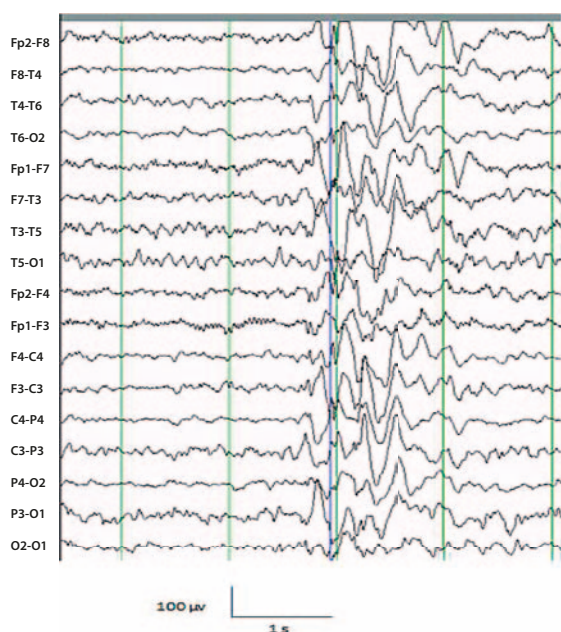


Figure 2. During pattern stimulation generalized EEG discharges are evoked with eyes opened associated with a very brief inconspicuous absence.

spike-wave discharge when a stronger jerk interferes with the mild eyelid movements. The marked jerking of the eyelids is associated with polyspike and slow-wave discharges 3–6 Hz, often irregular and fragmented due to the inability of the patient to open and keep the eyes opened for a few seconds. When the patient finally succeeds in keeping the eyes open and the electroclinical phenomena disappear, the person often demonstrates a sigh of relief.

In the classical type of Jeavons syndrome, close video observation may disclose the brief *tonic spasm* observed either in the preseptal palpebral portion of the orbicularis oculi muscle, which prevents the closing movement for a few milliseconds, or in the pretarsal portion at eye closure (plateau phase) that may last up to 500 msec before the eyelids open and jerk (Covanis, 2005). The sudden exposure to bright sun-light induces marked jerking of the eyelids following slow eye closure, and is often misdiagnosed as a self-induced phenomenon or facial tics.

In untreated mild cases eyelid myoclonia on eye closure may continue as a habitual life-long phenomenon, with no concomitant EEG discharges.

Absence seizures

Absence seizures, usually inconspicuous, appear in almost all cases with Jeavons syndrome and are difficult

to distinguish when they appear simultaneously with the eyelid movements and are very brief, less than a second. In order to identify the transient eye glare, as a hesitation or a gap in counting, it is necessary to study the video-EEG very carefully. Absence seizures in association with generalized spike-wave discharges, occurring independently of eye closure with the eyes open, can be seen in a few cases, during hyperventilation and intermittent photic stimulation. Typical absence seizures are not seen or are very infrequent (Ferrie et al., 1996).

Myoclonic seizures other than eyelid

Myoclonic jerks other than eyelid are rarely reported by the children or observed by their parents. In adults and in children myoclonic jerks have been reported to occur in 54.5% and 34%, respectively (Giannakodimos and Panayiotopoulos, 1996; Covanis, 2010) and in the majority of cases occur either independently or in association with eyelid jerking on eye closure (Jeavons, 1997; Covanis et al., 1994; Covanis, 2005; Covanis, 2010; Panayiotopoulos, 2005). The jerks usually involve the head and upper part of the body and their intensity varies from a subjective feeling to marked jerking. The head may jerk to one side or be drawn to one side like a magnet (nodding, shaking). Myoclonic jerks that follow eye closure are usually preceded or followed by a brief absence (Covanis, 2010), and are commonly evoked during IPS.

Generalized tonic-clonic seizures

GTCS occurred in about 50% of our reported cases and are usually the referral symptom in the mild or the classical form of ELMA, either untreated or treated unsuccessfully or with inappropriate AED (Covanis, 2005). The usual precipitating factors are sleep deprivation, fatigue, flashing lights or alcohol abuse associated with sleep deprivation in the older population.

The history, the observation of the patient, and the detailed sleep-awake EEG (video-EEG), with correct technique and assessment during photic stimulation (Kasteleijn-Nolst Trenite et al., 2012), will confirm the diagnosis of Jeavons syndrome.

CLASSIFICATION OF CLINICAL FORMS OF JEAVONS SYNDROME (Covanis, 2005, 2010)

ELMA of early-onset: under the age of 4 years old

A. Typical form. The characteristic and diagnostic electroclinical phenomena easily differentiate Jeavons

syndrome from any other epilepsy appearing early in life. The repeated eye closure phenomena in bright light are unavoidable and characteristic. The child often puts his arm in front of his eyes or rubs the eyelids to show the uncomfortable and very disturbing feeling. In contrast to the other forms of ELMA, blinking by confrontation and passive eye closure may occasionally induce clinical and EEG paroxysmal discharges reflecting a stronger genetic expression. The response to treatment and prognosis of early onset Jeavons syndrome is worse compared to the mild and classical forms, but comparable to absence epilepsies of early onset, with almost 75% of the cases having moderate to severe educational problems. The MRI is normal. In some of these children the electroclinical phenomena, including the response to IPS, gradually disappear before puberty and the child starts showing signs of educational improvement.

- B. Atypical form.* The presentation is with frequent GTCS in the first year of life. Giving sodium channel blocker drugs will provoke absence and myoclonic seizures. Eyelid jerking and other myoclonic jerks usually become apparent during infancy. The EEG shows frequent brief and irregular generalized 2 to 3-Hz spike-wave and polyspike-wave discharges particularly on eye closure with concomitant eyelid jerking and occasional jerks of the upper limbs. Photosensitivity is usually marked. Focal spike or spike-slow wave complexes are also seen. MRI is normal. The children show moderate mental retardation.

Mild form ELMA

In these patients eyelid fluttering, after eye closure, is observed for months or years before seeking medical advice for an occasional GTCS or be discovered by an expert in the field. The EEG shows abnormalities on eye closure and some positive response to IPS. Having no more than a few GTCS in their life time and discovered late, these patients usually refuse treatment. However, they continue eyelid fluttering on eye closure even after the phenomenon has regressed, as a habit, with no associated EEG discharges on eye closure.

Classical ELMA

In the classical ELMA there is marked jerking of the eyelids, often with upward deviation of the eyes and retropulsive movements of the head, immediately after eye closure, associated with generalized polyspike-

wave discharges in the EEG. In all cases, eyelid myoclonia is associated with absences and the positive response to IPS is usually marked. In some cases during IPS, the head, instead of jerking, is drawn towards the light, as if by a magnet. The command “close your eyes” fails due to eyelid jerking and synchronous eye opening. The patient may try on a few occasions to obey the command repeating the electroclinical phenomena until he stops with the eyes open and a sigh of relief, accepting failure to obey the command. When asked about their feelings, during the events, the patients are unable to explain, though the majority will admit that it is a pleasant feeling.

This form of ELMA, if left untreated, may lead to a habitual urge for eye closure during periods of inactivity and boredom.

ELMA and Juvenile myoclonic epilepsy

Some patients present with a history suggesting juvenile myoclonic epilepsy (JME) and during the EEG (preferably video-polygraphic EEG) show typical eyelid myoclonia associated with myoclonic jerks and EEG generalized paroxysms on eye closure. All cases are photosensitive and, as in JS, hyperventilation and IPS provoke clinical and generalized EEG discharges. GTCS do occur.

Non-convulsive status epilepticus (NCSE) in ELMA

Exceptionally, Jeavons syndrome may present as NCSE. The main presenting symptoms are prolonged confusion states. Routine electro clinical assessment reveals the typical characteristics of ELMA. Photosensitivity is usually marked and may lead to GTCS.

Diagnostic procedures

The diagnosis of Jeavons syndrome is easy based on the history, the clinical observation, the provocation by on command eye closure and the confirmation with an EEG. This will be followed by a more detailed sleep-awake video polygraphy-EEG after sleep deprivation using correct IPS methodology (Kasteleijn-Nolst Trenite et al., 2012). In ELMA the clinical and EEG discharges are recorded immediately after eye closure. During drowsiness, hyperventilation and IPS an exacerbation of the clinical and EEG events are seen. All patients, who are assessed with correct IPS and pattern technique, will show photosensitivity (Covanis, 2005; Covanis, 2010). The sleep EEG may be either normal or may show GSWDs or focal spikes or spike and wave

complexes in the frontal regions. The generalized discharges during sleep tend to be of longer duration and fragmented and in a few cases a slight tremor of the eyelids or an opening and closing of the eyes is observed during the discharge.

The diagnosis of Jeavons syndrome is easy for those who have experienced or have seen a typical case. The typical electroclinical features as described, combined with photosensitivity, are unique and pathognomonic of this syndrome (Covanis, 2010).

Differential diagnosis

The unique electro-clinical characteristics of JS include eyelid myoclonia with conspicuous or inconspicuous absences on eye closure associated with generalized EEG paroxysms and photosensitivity. Myoclonic seizures and GTCS do occur.

In our cohort of 50 children, all assessed by sleep-awake video-EEG and IPS following sleep deprivation, myoclonic jerks from the upper part of the body were recorded in 34% of the cases (Covanis, 2005; Covanis, 2010). In an adult cohort myoclonic jerks were recorded in 54.5% (Giannakodimos and Panayiotopoulos, 1996). In a more recent study (Kim et al., 2012) even massive myoclonias were recorded among cases with ELMA having sporadic GTCS, while in another study, myoclonic jerks were wrongly, in the present author's view, considered an exclusion criterion (Striano et al., 2002). Myoclonic jerks, other than eyelid, even massive, are mainly recorded during IPS and, in rare cases persistent photic stimulation may lead to a GTCS (Covanis, 2005; Covanis, 2010).

In certain cases, an overlapping between ELMA and JME exists where myoclonic jerks appear as the presenting symptom and during a video-EEG recording jerks are recorded immediately after eye closure, simultaneously with eyelid myoclonia, particularly during IPS (Covanis, 2005; Covanis, 2010). Similar cases have also been reported by other investigators (Yalçın et al., 2006; Güveli et al., 2013). In 2011 a 15-year-old boy with learning difficulties and eyelid myoclonia with absences was reported (Ohya et al., 2012), diagnosed at the age of six as "cryptogenic myoclonic epilepsy of childhood". However, the EEG recorded at the age of six shows generalized SW/PSWDs evoked immediately after eye closure, typical of Jeavons syndrome (see fig. 1).

The eye closure period starts immediately after closing the eyes and only lasts up to 3 sec, while the eye-closed period lasts more than 3 sec and persists as long

as the eyes remain closed (Yang et al., 2008). The eye closure sensitivity seen in Jeavons syndrome, should be differentiated from fixation-off sensitivity characterized by posterior or generalized paroxysms that occur after closing the eyes and last as long as the eyes are closed (Brigo et al., 2013). Jeavons syndrome is an eye closure and not an eye closed phenomenon. The clinical and the EEG generalized discharges of mixed frequencies or GSW/PSWDs 3–6 Hz, immediately after eye closure usually last less than three seconds and vanish when the eyes open and kept opened. Drowsiness after sleep deprivation, hyperventilation and IPS enhance the electroclinical phenomena and may provoke spontaneous brief absence seizures with eyes opened. Few focal abnormalities, frontal or occipital, were reported in a recent study (Senol et al., 2015) and in another study frontal predominance was seen in males and occipital in females with Jeavons syndrome (Wang et al., 2014). Jeavons syndrome of early onset (Covanis, 2005; Caraballo et al., 2009; Covanis, 2010), as absence epilepsies of early onset (Covanis, 2007), has a worse prognosis regarding response to treatment and cognitive functions.

Eyelid flickering, or fluttering, has been reported in other types of IGEs with absences (Ferrie et al., 1996; Panayiotopoulos et al., 1989), symptomatic absence epilepsy (Panayiotopoulos et al., 1992), fixation-off sensitive epilepsy (Panayiotopoulos, 1987), and even benign myoclonic epilepsy of infancy (Dravet and Bureau, 1981). In idiopathic childhood absence epilepsy, the absence seizures are not an eye closure or eye closed phenomenon; the absence seizures usually last longer than three seconds; rhythmic or random closing of the eyes or some eyelid jerking may be seen at the eye opening or at the initial stage of a GSWD, the eyes may deviate to the side (this never occurs in ELMA); and the electroclinical events do not appear on eye closure and do not disappear on eye opening (Covanis, 2005). In certain myoclonic epilepsies, where the predominant type of seizures is myoclonic jerks, the eyes may open and stare, or even the eyelids may blink, but do not retract and jerk like in ELMA (Covanis, 2005), though ELMA and JME may co-exist in the same patient (Caraballo et al., 2009; Covanis, 2010; Yalçın et al., 2006).

In idiopathic occipital epilepsies, some forced eyelid closure or blinking may occur as an ictal event or herald a secondary generalized seizure (Panayiotopoulos, 1999; Williamson et al., 1992). In these cases, slow spike and wave complexes appear on eye closure in the posterior regions and continue in long runs, for as long as

the eyes remain closed. Eyelid flutter may be observed, but never eyelid contraction and jerking, and on eye opening a partial or complete attenuation of the discharges is observed. Generalized polyspike and wave discharges do not characterize occipital epilepsies and the spike of the spike-wave component is smoother as in all forms of benign focal epilepsies (Covanis, 2005). Eyelid myoclonia alone can also be observed in certain symptomatic/cryptogenic epilepsies. However, the characteristic electroclinical events of JS do not exist and the associated developmental delay, neurological deficit, abnormal MRI and slow background EEG can easily differentiate them (Ferrie et al., 1996). In JS the characteristic eyelid myoclonia and EEG related discharges following eye closure combined with photosensitivity, leave no room for diagnostic error (Panayiotopoulos, 2005, 2010).

The prevalence of Jeavons syndrome among IGEs has been reported to vary from 7.3% to 12.9% (Covanis et al., 1982; Giannakodimos and Panayiotopoulos, 1996; Covanis, 2005; Covanis, 2010) and from 2.5% to 2.7% among all patients with epileptic disorders (Covanis et al., 1982; Giannakodimos and Panayiotopoulos, 1996; Covanis, 2005). In a study of 63 patients with ELMA, the prevalence was found to be 2.7% in IGE and 0.56% in all epilepsies (Caraballo et al., 2009). The authors attributed the low prevalence figures to more symptomatic cases in their population of epilepsy patients and to underdiagnoses.

Misdiagnosis and underdiagnosis is common among the general population and among physicians that have not seen a Jeavons syndrome case. Patients with eyelid myoclonia and those who make grimaces to avoid eye closure phenomena are usually referred to psychologists for tics or mannerisms. Tics, transient or chronic, are common in childhood, particularly in males (Covanis, 2005). Some authors believed that eye ball' roll, eye closure and eye blinking are tic-like symptoms that cause the brief absences and discharges in those cases that are photosensitive (Kent et al., 1998). These authors do not explain the spontaneous discharges seen in children with ELMA, particularly during sleep, the vanishing of the electroclinical symptoms with successful response to AED, or even why generalized SWDs are not seen in typical Gilles de la Tourette syndrome.

Blinking, which is a brain stem reflex, does not induce electro-clinical events in patients with Jeavons syndrome (Covanis, 2005; Covanis, 2010).

Eyelid myoclonia is an ictal event and self-induction

is a rare phenomenon observed in some untreated, or in inappropriately treated cases of early onset where the genetic predisposition is "marked". Eyelid myoclonia and self-induced epilepsy are separate entities with some overlapping (Covanis, 2005; Covanis, 2010). In both conditions electrical activity is generated from the frontal eye field and hand area, respectively. The two areas are adjacent and photosensitivity is the common path for self-induction (Covanis, 2010). In ELMA, females predominate and in self-induced epilepsy males predominate. In a few cases with Jeavons syndrome and marked photosensitivity, that have boarder-line or low IQ, seizures may be self-induced (Covanis, 2005; Covanis, 2010). This is also seen in untreated, inappropriately treated, or resistant to treatment cases, where the "rather pleasant feeling" felt on eye closure predisposes to repetition from curiosity that gradually becomes a habit, particularly during periods of boredom and anxiety (Covanis, 2010).

In Jeavons syndrome three factors are important: the genetic predisposition, the voluntary or on command slow eye closure and the bright light input. The genetic variation, as in any other genetic epilepsy, is expressed by clinical variation (Meisler, 2010).

It seems that in ELMA and generally in photosensitive epilepsies, the role of the occipital cortex (OC) is of crucial importance (Striano et al., 2009). This genetic sensitivity of the OC is triggered directly by the light stimulus or from the eye closure precentral eye field area in bright light. The eyelid myoclonia often coincides with bi-occipital polyspike and wave epileptiform discharges with or without generalized polyspike and wave discharges (Viravan et al., 2011). The spreading of the generalized discharges to the frontal area seems to involve the thalamus (Liu et al., 2008) most likely through a subcortical circuit. A recent study, using EEG-correlated functional MRI and voxel brain morphometry (Vaudano et al., 2014), demonstrated altered anatomofunctional properties in ELMA compared with controls and IGE patients. These abnormalities involved the OC and cortical/subcortical systems physiologically involved in the motor control of eye closure and eye movements, indicating that Jeavons syndrome is a separate syndrome with distinctive features (Vaudano et al., 2014). The important role of the thalamus and OC was also suggested in a patient with Jeavons syndrome using fMRI and EEG (Kim et al., 2012).

The genetic predisposition to eye closure in Jeavons syndrome involves the frontal eye closure area and the

OC, while in photosensitive patients only the OC is involved. Similarly in self-induced epilepsy the specific hand waving precentral cortex area is involved together with the OC. According to some authors (Tenney and Glauser, 2013), it is unclear whether Jeavons syndrome should be classified as a type of absence epilepsy or as a myoclonic epilepsy, given its prominent eyelid myoclonia. However, among IGE there are three syndromes where myoclonic and absence seizures predominate in their phenotype: Jeavons and Tassinari syndromes and facial (perioral) myoclonia with absences.

Jeavons syndrome is not uncommon, has specific electroclinical phenomena, and the diagnosis can easily be made by those who have seen and studied the syndrome before.

The response to treatment, as well as cognitive performance, is better if diagnosed and treated appropriately very early. In our experience the initial 53% complete response to valproic acid (Covanis et al., 1982) improved to 74% in the study of 50 ELMA cases diagnosed and treated early with the same drug (Covanis et al., 2004; Covanis, 2005; Covanis, 2010). Levetiracetam is an alternative choice for patients with IGE and photosensitivity (Covanis and Katsalouli, 2004) and should be tried first in female patients, taking into consideration that Jeavons syndrome as with JME, is a life-long disorder. During pregnancy daily doses of valproic acid exceeding 1000 mg per day are particularly teratogenic. However, complete control on levetiracetam was reported in 17% of cases (Striano et al., 2008) compared with 74% with valproic acid (Covanis et al., 2004; Covanis, 2005; Covanis, 2010). Other choices could be lamotrigine, benzodiazepines and ethosuximide, usually as combined therapy. More monotherapy studies are needed with AEDs other than valproic acid in patients with Jeavons syndrome, particularly for the female population.

CONCLUSION

Jeavons syndrome is an idiopathic (genetic) epilepsy syndrome that shows electroclinical heterogeneity relevant to the genetic heterogeneity. It is characterized by eyelid myoclonia induced immediately after eye closure, associated with generalized EEG paroxysms, brief conspicuous or inconspicuous absence seizures in almost all cases, myoclonic and GTCS in some and photosensitivity. Recently the ILAE Task Force on Classification of seizures has recognized Jeavons syndrome as a separate seizure entity (Fisher et al., 2015).

CONFLICT OF INTEREST DISCLOSURE

The author has no conflict of interest to declare

REFERENCES

- Adachi M., Inoue T., Tsuneishi S., Takada S., Nakamura H.: *Eyelid myoclonia with absences in monozygotic twins*. *Pediatr. Int.*, 2005, 47: 343–347.
- Appleton R.E., Panayiotopoulos C.P., Acomb B.A., Beirne M.: *Eyelid myoclonia with absences: an epilepsy syndrome*. *J. Neurol. Neurosurg. Psychiatr.*, 1993, 56: 1312–1316.
- Berg A.T., Berkovic S.F., Brodie M.J., Buchhalter J., Cross J.H., van Emde Boas W. et al.: *Revised terminology and concepts for organization of seizures and epilepsies: Report of the ILAE Commission on Classification and Terminology, 2005–2009*. *Epilepsia*, 2010, 51: 676–685.
- Bianchi A. and the Italian LAE Collaborative Group: *Study of concordance of symptoms in families with absence epilepsies*. In: J.S. Duncan, C.P. Panayiotopoulos (eds), *Typical absences and related epilepsy syndromes*. Churchill Communication Europe, London, 1995, 328–337.
- Binnie C.D., Darby C.E., de Korte R.A., Wilkins A.J.: *Self-induction of epileptic seizures by eye closure: incidence and recognition*. *J. Neurol. Neurosurg. Psychiatry*, 1980, 43: 386–389.
- Binnie C.D., Jeavons P.M.: *“Photosensitive epilepsies” in epileptic syndromes of infancy, childhood and adolescence*. In: J. Roger, M. Bureau, C. Dravet, F.E. Dreifuss, A. Perret, P. Wolf (eds), 2nd ed. John Libbey Eurotext, London, 1992, 299–305.
- Brigo F., Rossini F., Stefani A., Nardone R., Tezzon F., Fiaschi A. et al.: *Fixation-off sensitivity*. 2013, 124: 221–227.
- Capovilla G., Striano P., Gabardella A., Beccaria F., Hirsh E., Casellato S. et al.: *Eyelid fluttering, typical EEG pattern and impaired intellectual function: A homogeneous epileptic condition among the patients presenting with eyelid myoclonia*. *Epilepsia*, 2009, 50: 1536–1541.
- Caraballo R.H., Fontana E., Darra F., Chacon S., Ross N., Fiorini E., Fejerman N. et al.: *A study of 63 cases with eyelid myoclonia with or without absences: Type of seizure or an epileptic syndrome?* *Seizure*, 2009, 18: 440–445.
- Covanis A.: *Eyelid myoclonia and absences*. In: A.V. Delgado-Escuata, R. Guerrini, M.T. Medina, P. Genton, M. Bureau, C. Dravet (eds). *Myoclonic epilepsies, Advances in neurology*. 2005, 95: 183–194.
- Covanis A.: *Absence epilepsy of early onset with myoclonic seizures*. In: C.P. Panayiotopoulos (eds). *Idiopathic generalized epilepsies*. Medicine/UCB S.A, 2007, vol. 2, 94–98.
- Covanis A.: *Jeavons syndrome*. In: C.P. Panayiotopoulos (ed), *Atlas of Epilepsies*. Springer-Verlag, London Ltd, 2010, vol 2: 1081–1091.

- Covanis A., Jeavons P.M., Gupta A.K.: *Sodium valproate: monotherapy and polytherapy*. Epilepsia, 1982, 23: 693–720.
- Covanis A., Katsalouli M.: *Levetiracetam Monotherapy in Generalized Epilepsy and Photosensitivity in Children and Young Adults*. Epilepsia, 2004, 45 (Suppl.): 139.
- Covanis A., Skiadas K., Loli N., Ioannidou A., Lada Ch., Theodorou V.: *Eyelid myoclonia with absences*. Epilepsia, 1994, 35: 13.
- Covanis A., Stodieck S.R.G., Wilkins A.J.: *Treatment of Photosensitivity*. Epilepsia, 2004, 45 (Suppl. 1): 40–45.
- De Marco P.: *Eyelid myoclonia with absences (EMA) in two monovular twins*. Clin. Electroencephalogr., 1989, 20: 193–195.
- Dravet C., Bureau M.: *L'épilepsie myoclonique benigne du nourisson*. Rev. Electroencephalogr. Neurophysiol. Clin., 1981, 11: 438–444.
- Ferrie C.D.: *Eyelid myoclonia with absences*. In: S.J. Wallace, K. Farrell (eds), *Epilepsy in children*, 2nd ed. Edward Arnold, London, 2004, 195–198.
- Ferrie C.D., Agathonikou A., Parker A., Robinson R.O., Panayiotopoulos C.: *The spectrum of childhood epilepsies with eyelid myoclonia*. In: J.S. Duncan, C.P. Panayiotopoulos (eds), *Eyelid myoclonia with absences*. John Libbey, London 1996, 39–48.
- Fisher R., Cross H., French J., Higurashi N., Hirsh E., Jansen F.: *Classification of seizure types by the International League Against Epilepsy*, 2015. Draft notes 8/16/15, on consensus from London 2/16–2/17/2015 Task Force meeting.
- Giannakodimos S., Panayiotopoulos C.P.: *Eyelid myoclonia with absences in adults: a clinical and video-EEG study*. Epilepsia, 1996, 37: 36–44.
- Güveli B.T., Baykan B., Dörtcan N., Bebek N., Gürses C., Gökyiğit A.: *Eye closure sensitivity in juvenile myoclonic epilepsy and its effect on prognosis*. Seizure, 2013, 22: 867–871.
- Harsono M.D.: *A study of 72 children with eyelid myoclonia precipitated by eye closure in Yogyakarta*. Neurol. J. Southeast Asia, 2003, 8: 15–23.
- Jeavons P.M.: *Nosological problems of myoclonic epilepsies in childhood and adolescence*. Dev. Med. Child. Neurol., 1977, 19: 3–8.
- Jeavons P.M.: *Myoclonic epilepsies: therapy and prognosis*. In: H. Akimoto, H. Kasamatsuri, M. Seino, A. Ward (eds), *Advances in Epileptology*. Raven Press, New York 1982, 141–144.
- Jeavons P.M.: *Eyelid myoclonia and absences: the history of the syndrome*. In: J.S. Duncan, C.P. Panayiotopoulos (eds), *Eyelid myoclonia with absences*. John Libbey & Company Ltd 1996, 13–15.
- Kasteleijn-Nolst Trenite D., Rubboli G., Hirsch E., Martins da Silva A., Seri S., Wilkins A. et al.: *Methodology of photic stimulation revisited: Updated European algorithm for visual stimulation in the EEG laboratory*. Epilepsia, 2012, 53: 16–24.
- Kent L., Blake A., Whitehouse W.: *Eyelid myoclonia with absences: phenomenology in children*. Seizure, 1998, 7: 193–199.
- Kim J., Chang J.W., Kim J.H.: *SPECT Findings in Association with Interictal and Ictal Discharges in a Patient with Jeavons Syndrome*. Journal of Korean Epilepsy Society, 2012, 16: 26–29.
- Leyton A.S.F., Sherrington C.S.: *Observations of the excitable cortex of the chimpanzee orangutan and gorilla*. Q. J. Exp. Physiol., 1917, 11: 135–222.
- Liu Y., Yang T., Liao W., Yang X., Liu L., Yan B. et al.: *EEG-fMRI study of the ictal and interictal epileptic activity in patients with eyelid myoclonia with absences*. Epilepsia, 2008, 49: 2078–2086.
- Meisler M.H.: *Gene interactions and modifiers in epilepsy*. Epilepsia, 2010, 51(Suppl. 5): 66. doi: 10.1111/j.1528-1167.2010.02852.x.
- Ohya T., Yamashita Y., Shibuya I., Hara M., Nagamitsu S., Matsuishi T.: *Eyelid myoclonia with absences occurring during the clinical course of cryptogenic myoclonic epilepsy of early childhood*. European Journal Paediatric Neurology, 2012, 16: 399–401.
- Panayiotopoulos C.P.: *Fixation-off-sensitive epilepsy in eyelid myoclonia with absence seizures*. Ann. Neurol., 1987, 22: 87–89.
- Panayiotopoulos C.P., Obeid T., Waheed G.: *Differentiation of typical absence seizures in epileptic syndromes*. Brain, 1989, 112: 1039–1056.
- Panayiotopoulos C.P., Chroni E., Daskalopoulos C., Baker A., Rowlinson S., Walsh P.: *Typical absence seizures in adults: clinical, EEG, video-EEG findings and diagnostic/syndromic considerations*. Neurol. Neurosurg. Psychiatry, 1992, 55: 1002–1008.
- Panayiotopoulos C.P.: *Benign childhood partial seizures and related syndromes*. John Libbey, London 1999.
- Panayiotopoulos C.P.: *Reflex seizures and reflex epilepsies*. In: C.P. Panayiotopoulos (ed), *The epilepsy seizures, syndromes and management*. Bladon Medical Publishing, Oxford 2005, 449–496.
- Panayiotopoulos C.P.: *Eyelid myoclonia with and without absences*, 2006. www.ilae-epilepsy.org/ctf/over_frame.html.
- Panayiotopoulos C.P.: *Jeavons syndrome*. In: C.P. Panayiotopoulos (ed), *A clinical guide to Epileptic Syndromes and their Treatment*. Springer Healthcare Ltd 2010, 513–517.
- Parker A., Gardiner R.M., Panayiotopoulos C.P., Agathonikou A., Ferrie C.: *Observations on families of patients with eyelid myoclonia with absences*. In: J.S. Duncan, C.P. Panayiotopoulos (eds), *Eyelid myoclonia with absences*. John Libbey, London 1996, 107–114.
- Senol P.N., Tezer F.I., Saygi S.: *Eyelid myoclonia seizures in adults: An alternate look at the syndrome paradox*. Epilepsy & Behavior, 2015, 45: 265–270.
- Striano S., Capovilla G., Sofia V., Romeo A., Rubboli G.,

- Striano P.**: *Eyelid myoclonia with absences (Jeavons syndrome): A well-defined idiopathic generalized epilepsy syndrome or a spectrum of photosensitive conditions?* *Epilepsia*, 2009, 50 (Suppl. 5): 15–19.
- Striano P., Sofia V., Capovilla G., Rubboli G., Di Bonaventura C., Coppola A. et al.**: *A pilot study of levetiracetam in eyelid myoclonia with absences (Jeavons syndrome)*. *Epilepsia*, 2008, 49: 425–430.
- Striano S., Striano P., Nocerino C., Boccella P., Bilo L., Meo R. et al.**: *Eyelid myoclonia with absences: an overlooked epileptic syndrome*. *Neurophysiol. Clin.*, 2002, 32: 287–296.
- Tenney J.R., Glauser T.A.**: *The Current State of Absence Epilepsy: Can We Have Your Attention?* *Epilepsy Currents*, 2013, 13: 135–140.
- Van Koningsbruggen M.G., Peelen M.V., Davies E., Rafal R.D.**: *Neural control of voluntary eye closure: a study and an fMRI investigation of blinking and winking*. *Behav. Neurol.*, 2012, 25: 103–109.
- Vaudano A.E., Ruggieri A., Tondelli M., Avanzini P., Benuzzi F., Gessaroli G. et al.**: *The Visual System in Eyelid Myoclonia with Absences*. *Ann. Neurol.*, 2014, 76: 412–427.
- Viravan S., Go C., Ochi A., Akiyama M., Carter Snead III O., Otsubo H.**: *Jeavons syndrome existing as occipital cortex initiating generalized epilepsy*. *Epilepsia*, 2011, 52: 1273–1279.
- Wang X., Bao J., Liang-Shi., Tie-Ma, Deng Y., Zhao G. et al.**: *Jeavons syndrome in China*. *Epilepsy & Behavior*, 2014, (32C): 64–71.
- Weiskrantz L., Wanington E.K., Sanders M.D., Marshall J.**: *Visual capacity in the hemianoptic field following a restricted occipital ablation*. *Brain*, 1974, 97: 700–728.
- Williamson P.D., Thadani V.M., Darcey T.M., Spencer D.D., Spencer S.S., Mattson R.H.**: *Occipital lobe epilepsy: Clinical characteristics, seizure spread patterns and results of surgery (review)*. *Ann. Neurol.*, 1992, 31: 3–13.
- Wilkins A.**: *Towards an understanding of reflex epilepsy and absence*. In: J.S. Duncan, C.P. Panayiotopoulos (eds), *Typical absences and related epileptic syndromes*. Churchill Communications Europe, London 1995, 196–205.
- Yalçın A.D., Forta H., Kılıç E.**: *Overlap cases of eyelid myoclonia with absences and juvenile myoclonic epilepsy*. *Seizure*, 2006, 15: 359–365.
- Yang T., Liu Y., Liu L., Yan B., Xhang Q., Zhou D.**: *Absences status epilepticus in monozygotic twins with Jeavons syndrome*. *Epileptic Disord.*, 2008, 10: 227–230.