

# New Imaging-derived Biomarkers Based on Tridimensional CTA/MRI Hybrid Models for Complex Assessment of Myocardial Viability after Myocardial Infarction – the HYBRIDHEART Study

Alexandra Stănescu<sup>1,2</sup>, Imre Benedek<sup>1,2</sup>, Mirabela Morariu<sup>1,2</sup>, Mihaela Rațiu<sup>1,2</sup>, Ramona Zavate<sup>1</sup>, András Mester<sup>1,2</sup>, Theodora Benedek<sup>1,2</sup>

<sup>1</sup> Clinic of Cardiology, University of Medicine and Pharmacy, Tîrgu Mureș, Romania

<sup>2</sup> Center of Advanced Research in Multimodality Cardiac Imaging, Cardio Med Medical Center, Tîrgu Mureș, Romania

## CORRESPONDENCE

### Imre Benedek

Str. Gheorghe Marinescu nr. 38  
540139 Tîrgu Mureș, Romania  
Tel: +40 265 215 551  
E-mail: imrebenedek@yahoo.com

## ARTICLE HISTORY

Received: January 15, 2018  
Accepted: February 9, 2018

**Alexandra Stănescu** • Str. Gheorghe Marinescu nr. 38,  
540139 Tîrgu Mureș, Romania. Tel: +40 265 215 551.  
E-mail: alexandrastanescu90@gmail.com

**Mirabela Morariu** • Str. Gheorghe Marinescu nr. 38,  
540139 Tîrgu Mureș, Romania. Tel: +40 265 215 551.  
E-mail: mirabela.morariu@yahoo.com

**Mihaela Rațiu** • Str. Gheorghe Marinescu nr. 38,  
540139 Tîrgu Mureș, Romania. Tel: +40 265 215 551.  
E-mail: d\_a\_mihaela@yahoo.com

**Ramona Zavate** • Str. 22 Decembrie 1989 nr. 76,  
540124 Tîrgu Mureș, Romania. Tel: +40 265 217 333.  
E-mail: ramona.zavate@gmail.com

**András Mester** • Str. Gheorghe Marinescu nr. 38,  
540139 Tîrgu Mureș, Romania. Tel: +40 265 215 551.  
E-mail: andras.mester@yahoo.com

**Theodora Benedek** • Str. Gheorghe Marinescu nr. 38,  
540139 Tîrgu Mureș, Romania. Tel: +40 265 215 551.  
E-mail: theodora.benedek@gmail.com

## ABSTRACT

Hybrid imaging represents a combination of two different imaging techniques resulting in a single image that contains all the information provided by the two investigations. Hybrid imaging tends to improve the accuracy of the diagnosis in many diseases. Coronary computed tomography angiography (CCTA) has unquestionable abilities in highlighting coronary artery diseases (CAD). Cardiac magnetic resonance imaging (MRI) also has a powerful predictive role in assessing the functionality of the myocardial tissue. The **aim** of the study is to develop new imaging markers for a complex evaluation of myocardial viability (MV) after an acute myocardial infarction (AMI), using hybrid technology. **Material and methods:** This study will enroll 100 patients at one month after an AMI. CCTA, MRI, 3D echocardiography, and blood tests will be performed in all patients. All the acquisitions will be processed using a supercomputer, and MV and other parameters will be assessed on hybrid images. A secondary objective will be to correlate the level of inflammatory markers with the outcome of patients, left ventricular function, ischemic time, and the rate of major adverse cardiovascular events.

**Keywords:** hybrid imaging, myocardial infarction, myocardial viability, CTA/MRI, inflammation

## BACKGROUND

Despite the increasing knowledge on coronary artery diseases (CAD) and the high awareness regarding cardiovascular risk factors, myocardial infarction remains the main cause of mortality worldwide.<sup>1</sup>

CAD causes a negative impact in the healthcare system but also at an individual level, leading to an important decrease in the quality of life, especially in relatively

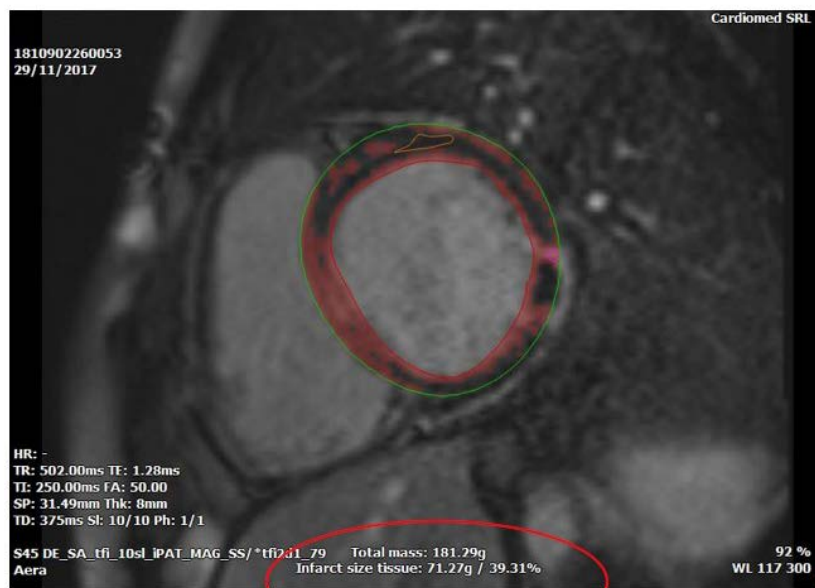
young adults.<sup>2</sup> Acute myocardial infarction (AMI) represents the sudden occlusion of one of the coronary arteries, usually produced by a thrombotic material that causes cessation of blood flow in the territory irrigated by the obstructed artery.<sup>3</sup> Functionally, CAD triggers myocardial fibrosis and left ventricle dilatation with a contractile dysfunction that can finally result in heart failure, a disease with significantly worse prognosis than other non-ischemic cardiomyopathies.<sup>4-7</sup> The outcomes of patients with CAD after an acute coronary syndrome can be significantly improved by performing immediate revascularization, which represents the gold standard therapy.<sup>8,9</sup> Restoring the blood flow in the affected territories by performing percutaneous angioplasty, coronary artery bypass grafting, or with medical therapy can prevent the irreversible death of cardiac myocytes.

An exacerbated inflammatory status is considered a trigger for the extension of myocardial injury.<sup>10</sup> San *et al.* concluded in their study that the elevated level of hs-CRP, an inflammatory marker, is related to the existence of a ruptured coronary plaque.<sup>11,12</sup> In 1985, Kohchi *et al.* reported that inflammation can be a trigger for acute coronary syndromes (ACS).<sup>13</sup> An exacerbated inflammatory status should be considered an important parameter in the evaluation of these patients; hence, serial determinations of inflammatory markers in patients with myocardial infarction became an important step in evaluation and predicting outcomes. Cardiac remodeling, which develops after an AMI, consists of dilation, hypertrophy, and formation of a

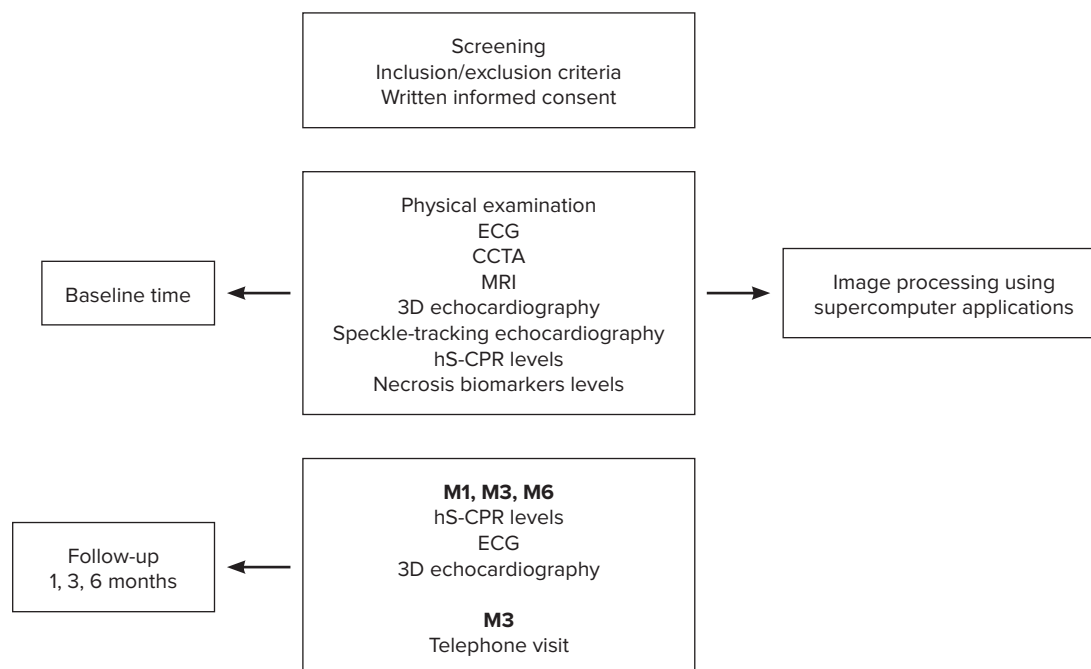
collagen scar. It occurs in two phases: an early phase (<72 h) and a late phase (>72 h), during which many histological changes occur that lead to dilatation and impairment of the contractile function of the heart.<sup>14</sup>

The importance of investigating myocardial viability (MV) came from its usefulness in determining the benefits associated with the revascularization of coronary stenoses. At the same time, MV can represent a relevant marker for the evaluation of ventricular function following a myocardial infarction. The concept of MV and the need for its assessment in ischemic lesions has been previously described in 1970, when it was first mentioned that a viable myocardial tissue will recover its function after revascularization.<sup>15</sup> A viable myocardium is a dysfunctional tissue with contractile impairment, classified into hibernating or stunned myocardium. Both can partially or completely recover their contractile function after restoration of blood flow, thus significantly improving patient outcomes.<sup>11</sup>

Magnetic resonance imaging (MRI) has been proved as a reliable method for quantification of the infarct size and its degree of transmural. There are several imaging-based methods for assessing MV, some being more accessible than others, such as the widely spread dobutamine echocardiography and the less available nuclear tomography. All of them are used to best identify the viable myocardial tissue, but also have disadvantages regarding costs or side effects. The best imaging method to differentiate viable tissue from necrosis should be safe for the patient,



**FIGURE 1.** SI Analysis using Qmass software – infarct size tissue; percentage of myocardial fibrosis for a patient with anterior myocardial infarction



**FIGURE 2.** HIBRIDHEART clinical study design

with limited side effects, easily reproducible, highly available, and with low costs.<sup>16</sup> One imaging method used alone cannot offer the clinician a wide perspective over the functionality of the myocardial tissue and the anatomy of the coronary arteries. Therefore, a combination of different imaging methods has been proposed, resulting in a single fused image that can offer specific information and provide a higher accuracy compared to isolated images. This combined technique can also be used for identifying the viable myocardium, the location of coronary obstructions, as well as for assessing the impairment of myocardial contractile properties.<sup>17–21</sup> The use of hybrid imaging has been proven by several studies as being able to increase diagnostic specificity from 63% to 95% in detecting flow-limiting coronary stenoses in comparison with coronary computed tomography angiography (CCTA) alone.<sup>22</sup>

The HYBRIDHEART study is a prospective observational study that aims to analyze imaging markers associated with MV, using hybrid imaging technologies, correlated with biochemical parameters associated with increased systemic inflammation, in patients suffering an acute myocardial infarction. The HYBRIDHEART study will offer the clinician a different view on MV, providing complex spatial details on the evolution of left ventricular function after MI. At the same time, it aims to assess the correlation between the level of systemic inflammation and the outcome of the patients following an AMI.

## OBJECTIVES

The aim of the HYBRIDHEART study is to develop new imaging markers for a complex evaluation of myocardial viability, by superposing computed tomography angiography (CTA) polar maps of the myocardium with MRI contractile maps, in patients who suffered an AMI. The secondary objectives of the HYBRIDHEART study are: (1) to evaluate the association of MV with the level of inflammatory markers; (2) to correlate the imaging-derived parameters with the inflammatory status of the patients, left ventricular function, ischemic time, and the rate of major adverse cardiovascular events (MACE).

## STUDY DESIGN

The HYBRIDHEART study is a prospective observational study that will be conducted in the Laboratory of Advanced Research in Cardiac Multimodal Imaging of Cardio Med Medical Center Țirgu Mureș, Romania.

The follow-up of patients will be performed at 1, 3, and 6 months after inclusion.

One hundred patients with documented myocardial infarction within 1 month who underwent successful percutaneous revascularization will be included in the study. They will be investigated within 1 month after the coronary intervention, undergoing CTA, MRI, three-dimensional

contrast-enhanced echocardiography, and speckle-tracking echocardiography. The level of inflammatory biomarkers will be expressed using hs-CPR levels at day 1 and day 5 post myocardial infarction.

The inclusion criteria are:

- patients aged above 18 years;
- patients with documented revascularized AMI in the last 30 days;
- patients who signed the written consent.

The exclusion criteria:

- subjects with renal impairment or contrast intolerance;
- pregnant women;
- patients known with malignancy in the last year;
- non-compliant patients.

## STUDY ENDPOINTS

The primary endpoint of the study is represented by the development of the new imaging markers for MV using hybrid CTA-MRI maps.

The secondary endpoints include: the level of hs-CPR at 1, 3, 6 months in relation with MACE rate, time of ischemia, MV, the percent of myocardial fibrotic tissue, and left ventricular function.

## STUDY PROCEDURES

The procedures that will be assessed in the study are as follows (Figure 2):

1. Imaging procedures, including CCTA, MRI, 3D echocardiography, speckle-tracking echocardiography, that will be performed during the first week after the inclusion period;
2. Laboratory assessment consisting in cardiovascular biomarkers: hs-CPR and myocardial necrosis biomarkers that will be determined at baseline and during follow-up;
3. ECG, blood pressure recordings, telephone visits that will be performed at baseline and during the follow-up period.
4. A dedicated database will be created, including all the demographical data and information regarding the AMI, such as infarct location, time of ischemia, ECG changes, levels of the necrosis markers, hs-

CPR, MRI findings, CCTA findings, and speckle-tracking parameters.

## ETHICS APPROVAL

Approval for this study has been obtained from the Ethics Committee of the Cardio Med Medical Center Tîrgu Mureş, Romania, and from the University of Medicine and Pharmacy of Tîrgu Mureş, Romania. All patients will sign an informed consent and will be exempt from costs. All study procedures are in line with the principles in the Declaration of Helsinki.

## CONCLUSIONS

The HYBRIDHEART study will develop new imaging-based biomarkers with the use of hybrid CCTA-MRI maps that will assess myocardial viability in patients suffering from an acute myocardial infarction within 1 month prior to the imaging evaluation. Also, MV will be correlated with the inflammation biomarkers in a dynamic profile. At the same time, the HYBRIDHEART study will assess the association between serum levels of hs-CPR and the percent of fibrotic myocardial tissue, MACE rate, ischemic time, and left ventricular function.

## CONFLICT OF INTEREST

Nothing to declare.

## ACKNOWLEDGEMENT

This research is funded by the grant entitled “High performance multimodal MRI/CT imaging platform, for applications in computational medicine, nanoparticles and hybrid imaging for the research of atherothrombotic disorders – CARDIO IMAGE” financed by the National Authority of Scientific Research and Innovation and the Romanian Ministry of European Funds, the Romanian Government and the European Union, grant no. 103545/2016, contract number 43/05.09.2016.

At the same time, this research is partially financed by the University of Medicine and Pharmacy of Tîrgu Mureş through PhD Postgraduate Scholarship contract number 12898/32/19.01.2017.

## REFERENCES

1. WHO. The global burden of disease: 2004 update. Geneva: World Health Organization; 2008b. Available at: [http://www.who.int/healthinfo/global\\_burden\\_disease/2004\\_report\\_update/en/](http://www.who.int/healthinfo/global_burden_disease/2004_report_update/en/)

2. Saeed M, Van TA, Krug R, Hetts SW, Wilson MW. Cardiac MR Imaging: Current Status and Future Direction. *Cardiovasc Diagn Ther.* 2015;5:290-310.
3. Dreyer RP, Wang Y, Strait KM, et al. Gender differences in the trajectory of recovery in health status among young patients with acute myocardial infarction: results from the variation in recovery: role of gender on outcomes of young AMI patients (VIRGO) study. *Circulation.* 2015;131:1971.
4. Thygesen K, Alpert JS, Jaffe AS, et al. Third universal definition of myocardial infarction. *J Am Coll Cardiol.* 2012;60:1581-98.
5. Lloyd-Jones DM, Larson MG, Leip EP, et al. Lifetime risk for developing congestive heart failure: the Framingham Heart Study. *Circulation.* 2002;106:3068-3072.
6. Smith SC Jr, Blair SN, Bonow RO, et al. AHA/ACC Scientific Statement: AHA/ACC guidelines for preventing heart attack and death in patients with atherosclerotic cardiovascular disease: 2001 update: a statement for healthcare professionals from the American Heart Association and the American College of Cardiology. *Circulation.* 2001;104:1577-1579.
7. Steg PG, Dabbous OH, Feldman LJ, et al. Determinants and prognostic impact of heart failure complicating acute coronary syndromes: observations from the Global Registry of Acute Coronary Events (GRACE). *Circulation.* 2004;109:494-499.
8. Sutton MG, Sharpe N. Left ventricular remodeling after myocardial infarction: pathophysiology and therapy. *Circulation.* 2000;101:2981-2988.
9. Jernberg T, Johanson P, Held C, et al. Association between adoption of evidence-based treatment and survival for patients with ST-elevation myocardial infarction. *JAMA.* 2011;305:1677-1684.
10. Gale CP, Allan V, Cattle BA, et al. Trends in hospital treatments, including revascularisation, following acute myocardial infarction, 2003–2010: a multilevel and relative survival analysis for the National Institute for Cardiovascular Outcomes Research (NICOR). *Heart.* 2014;100:582-589.
11. Koukkunen H, Penttilä K, Kemppainen A, Halinen M, Penttilä I, Rantanen T, Pyörälä K. C-reactive protein, fibrinogen, interleukin-6 and tumour necrosis factor- $\alpha$  in the prognostic classification of unstable angina pectoris. *Ann Med.* 2001;1;33:37-47.
12. Sano T, Tanaka A, Namba M, et al. C-reactive protein and lesion morphology in patients with acute myocardial infarction. *Circulation.* 2003;108:282-285.
13. Kohchi K, Takebayashi S, Hiroki T, et al. Significance of adventitial inflammation of the coronary artery in patients with unstable angina: results at autopsy. *Circulation.* 1985;71:709-716.
14. Pfeffer MA, Braunwald E. Ventricular remodeling after myocardial infarction: experimental observations and clinical implications. *Circulation.* 1990;81:1161-1172.
15. Chatterjee K, Swan HJ, Parmley WW, Sustaita H, Marcus HS, Matloff J. Influence of direct myocardial revascularization on left ventricular asynergy and function in patient with coronary heart disease with and without previous myocardial infarction. *Circulation.* 1973;47:276-286.
16. Wijns W, Vatner SF, Camici PG. Hibernating myocardium. *N Engl J Med.* 1998;339:173-181.
17. Partington SL, Kwong RY, Dorbala S. Multimodality imaging in the assessment of myocardial viability. *Heart Fail Rev.* 2011;16:381.
18. Stănescu A, Opincariu D, Rat N, et al. Hybrid Imaging in the Assessment of Myocardial Ischemia and Viability. *Journal of Interdisciplinary Medicine.* 2016;3:242-246.
19. Masuda A, Yamaki T, Kunii H, et al. Simultaneous Assessment of Myocardial Viability With  $^{18}\text{F}$ -fluorodeoxyglucose Uptake and Late Gadolinium Enhancement by PET/MRI. *Circulation.* 2016;134:A11929.
20. Danad I, Rajmakers PG, Appelman YE, et al. Hybrid imaging using quantitative  $\text{H}_2$   $^{15}\text{O}$  PET and CT-based coronary angiography for the detection of coronary artery disease. *J Nucl Med.* 2013;54:55-63.
21. Kajander S, Joutsiniemi E, Saraste M, et al. Cardiac positron emission tomography/computed tomography imaging accurately detects anatomically and functionally significant coronary artery disease. *Circulation.* 2010;122:603-613.
22. Rispler S, Keidar Z, Ghersin E, et al. Integrated single-photon emission computed tomography and computed tomography coronary angiography for the assessment of hemodynamically significant coronary artery lesions. *J Am Coll Cardiol.* 2007;49:1059-1067.