

# Screening for Cognitive Dysfunction Helped to Unmask Silent Cerebrovascular Disease in a Hypertensive Diabetic Patient — Case Report

Márta Germán-Salló<sup>1</sup>, Enikő Nemes-Nagy<sup>2</sup>, Beáta Baróti<sup>3</sup>, Robert Gabriel Tripon<sup>2</sup>, Zoltán Preg<sup>1</sup>

<sup>1</sup> Cardiovascular Rehabilitation Clinic, University of Medicine and Pharmacy, Tîrgu Mureş, Romania

<sup>2</sup> Department of Biochemistry and Chemistry of Environmental Factors, University of Medicine and Pharmacy, Tîrgu Mureş, Romania

<sup>3</sup> Clinic of Radiology, University of Medicine and Pharmacy, Tîrgu Mureş, Romania

## CORRESPONDENCE

### Enikő Nemes-Nagy

Str. Gheorghe Marinescu nr. 38  
540139 Tîrgu Mureş, Romania  
Tel: +40 742 273 661  
E-mail: nemesneniko@gmail.com,  
nemesnagy.eniko@umftgm.ro

## ARTICLE HISTORY

Received: 10 April, 2017

Accepted: 15 May, 2017

## ABSTRACT

The current guidelines for the diagnosis and treatment of hypertension recommend screening for cognitive impairment in all hypertensive patients as part of the clinical assessment. However, the implementation of this recommendation in clinical practice is still unsatisfactory. We present the case of an elderly hypertensive female patient in order to highlight the importance of screening for cognitive impairment. A patient with a history of poorly controlled hypertension for the last 12 years and recently diagnosed with type 2 diabetes mellitus is admitted complaining of asthenia, dizziness, visual acuity impairment, and difficulty to remember recent information. Cardiovascular imaging showed 70% internal carotid artery stenosis in a neurologically asymptomatic patient. Cognitive testing showed mild cognitive impairment. Retinal imaging identified stage III hypertensive retinopathy accompanied by irreversible end-organ damage due to microvascular changes. At this point brain MRI was performed, which identified both macro- and microvascular brain lesions in the periventricular white matter and sequelae of a former ischemic stroke in the territory of the left posterior cerebral artery. Cognitive testing helped to unmask silent cerebrovascular disease in an otherwise oligosymptomatic hypertensive diabetic patient. Cognitive function testing should be introduced in routine clinical practice in order to help unmask silent cerebrovascular disease.

**Keywords:** cognitive dysfunction, cerebrovascular disease, retinopathy, hypertension, diabetes mellitus, retinal imaging

## INTRODUCTION

Dementia is becoming a public health problem as the population ages. Thus, screening for cognitive deterioration may become important in high-risk groups. Hypertension is proven to be an important risk factor for vascular dementia in elderly patients.<sup>1</sup> According to the results of numerous longitudinal studies, a significant link was found between midlife or later-life hyperten-

Márta Germán-Salló • Str. Revoluției nr. 35, 540042  
Tîrgu Mureş, Romania. Tel: +40 265 218 739

Beáta Baróti • Str. Gheorghe Marinescu nr. 50,  
540139 Tîrgu Mureş, Romania. Tel: +40 265 212 111

Robert Gabriel Tripon • Str. Gheorghe Marinescu  
nr. 38, 540139 Tîrgu Mureş, Romania. Tel: +40 265  
215 551

Zoltán Preg • Str. Revoluției nr. 35, 540042 Tîrgu  
Mureş, Romania. Tel: +40 265 218 739

sion and cognitive decline.<sup>2-4</sup> The current guidelines for the diagnosis and treatment of hypertension recommend screening for cognitive impairment in all hypertensive patients as part of the clinical assessment.<sup>5</sup> However, the implementation of these recommendations in clinical practice is still lacking. We present a case of an elderly hypertensive patient in order to demonstrate the impact of multiple cardiovascular risk factors on cognitive decline and to underline the importance of risk factor control and targeted screening for cognitive impairment in subjects with high blood pressure.

## CASE PRESENTATION

We present the case of a 67-year-old Caucasian female patient admitted to our department complaining of asthenia and dizziness. Patient symptoms also included visual acuity impairment and difficulty to remember recent information that did not affect the normal activities of daily living. The patient was a former smoker with a smoking load of 3 pack years and had a sedentary lifestyle. Family history included several family members with hypertension, no diabetes and no neurodegenerative disease running in the family, and no history of dementia or other forms of cognitive impairment. She had a history of poorly controlled hypertension for the last 12 years, with blood pressure values varying between 260/110 mmHg and 105/60 mmHg. Mean blood pressure values were 160–170/90 mmHg despite antihypertensive treatment that included angiotensin-converting enzyme inhibitor (ACEI) and loop-diuretic prescribed by the general practitioner, with poor patient compliance and adherence, and no regular check-ups. Diabetes was diagnosed based on suggestive symptoms, such as polyuria and polydipsia, 6 months prior to admission. At that time, her fasting blood glucose level was 256 mg/dL, her glycated haemoglobin (HbA1c) was 10.9%, and her total cholesterol level was 250 mg/dL. Adequate diet and metformin were initiated, along with the adjustment of antihypertensive treatment. ACEI are considered first-line therapy in patients with diabetes and hypertension because of their well-established renal protective effects. To achieve optimal blood pressure control and also to increase the patient's adherence to treatment, a fixed combination of ACEI (perindopril) and calcium channel blocker (amlodipine) was prescribed, and atorvastatin was added for the treatment of hypercholesterolemia. As a result, mean home blood pressure values were reduced to 120/70 mmHg, a good glycaemia control was obtained, and the patient lost 10 kilograms in weight.

## CLINICAL FINDINGS

The patient had an asthenic body type (body mass index 18.6 kg/m<sup>2</sup>) and was slightly anxious during the physical examination. On cardiac examination she had a regular heart rhythm, with a rate of 82 beats/minute, with no heart murmurs. There was a right carotid artery bruit, with no other signs of target organ damage. Blood pressure measured at admission in sitting position was 145/90 mmHg, symmetrical. The Schellong test revealed no orthostatic hypertension. A complete and thorough neurological examination conducted by the neurologist found no clinical signs of nervous system impairment.

## DIAGNOSTIC ASSESSMENT

Due to the patient's subjective memory complaints, a series of cognitive tests preceded by the shortened 13 items of Beck depression inventory (BDI-13) were performed. The patient scored 3 points at the BDI-13 test, ruling out depression as a confounding factor in cognitive impairment.

Screening for cognitive dysfunction was made with three different tools. At the gold standard Mini Mental State Examination (MMSE) questionnaire the patient scored 23 points, borderline normal if we consider normal values adjusted for education level (in patients with high school education, <23 points is considered abnormal).<sup>6</sup> At the higher sensitivity Montreal Cognition Assessment (MOCA) questionnaire she scored 24 points (considered abnormal <26 points), showing mild cognitive impairment.<sup>7</sup> Last, at the General Practitioner Assessment of Cognition (GPCOG) questionnaire the patient scored 3 points, interpreted as "cognitive impairment is indicated, conduct standard investigations".<sup>8</sup>

Laboratory testing evidenced elevated fasting glucose levels 146–143–140 mg/dL, glycated hemoglobin 6.4%, total cholesterol 139 mg/dL, normal triglyceride level of 83 mg/dL, normal renal function (MDRD 66 mL/min/1.73 m<sup>2</sup>), serum cystatin C 0.82 mg/L (GFR determined by CKD-EPI cystatin C equation 92 mL/min/1.73 m<sup>2</sup>) with no microalbuminuria (2.4 mg/24 h), and high levels of fibrinogen, 4.3 g/L, but normal HsCRP, 1.96 mg/L. In order to rule out treatable causes of cognitive impairment, screening for vitamin B12 deficiency and hypothyroidism was carried out. The serum free thyroxine (FT4) concentration was 2.1 ng/dL, slightly over the normal range of 0.8–2.0 ng/dL, with a normal serum thyroid stimulating hormone (TSH) concentration of 1.45  $\mu$ UI/mL (reference range 0.39–6.16  $\mu$ UI/mL) and above normal anti-thyroid

peroxidase antibodies (ATPO), 59.9 IU/mL (normal value <35 IU/mL). Close follow-up, but no medical treatment was indicated for the subclinical hyperthyroidism. Her serum vitamin B12 concentration (452 pg/mL) was in the normal range (193–982 pg/mL). Serum homocysteine concentration (8.01  $\mu$ mol/L) was in the ideal range, under 10  $\mu$ mol/L. Homocysteine, an independent risk factor for cardiovascular diseases, often shows increased values in patients with vitamin B12 deficiency, which might occur after long-term metformin treatment, therefore it was necessary to monitor these laboratory parameters in case of our patient.

Ambulatory blood pressure monitoring on current treatment showed slightly elevated systolic values, with an overall mean of 137/71 mmHg, daytime mean of 138/74 mmHg, and high night-time mean of 135/64 mmHg, with the absence of nocturnal dipping for systolic values (diurnal index 2/13%).

Resting ECG was normal. ECG Holter monitoring excluded the presence of complex arrhythmias, medium heart rate was 70/min, with few (41) supraventricular extra beats/day. No ventricular ectopic beats, no ST segment deviation, and no long RR intervals were found.

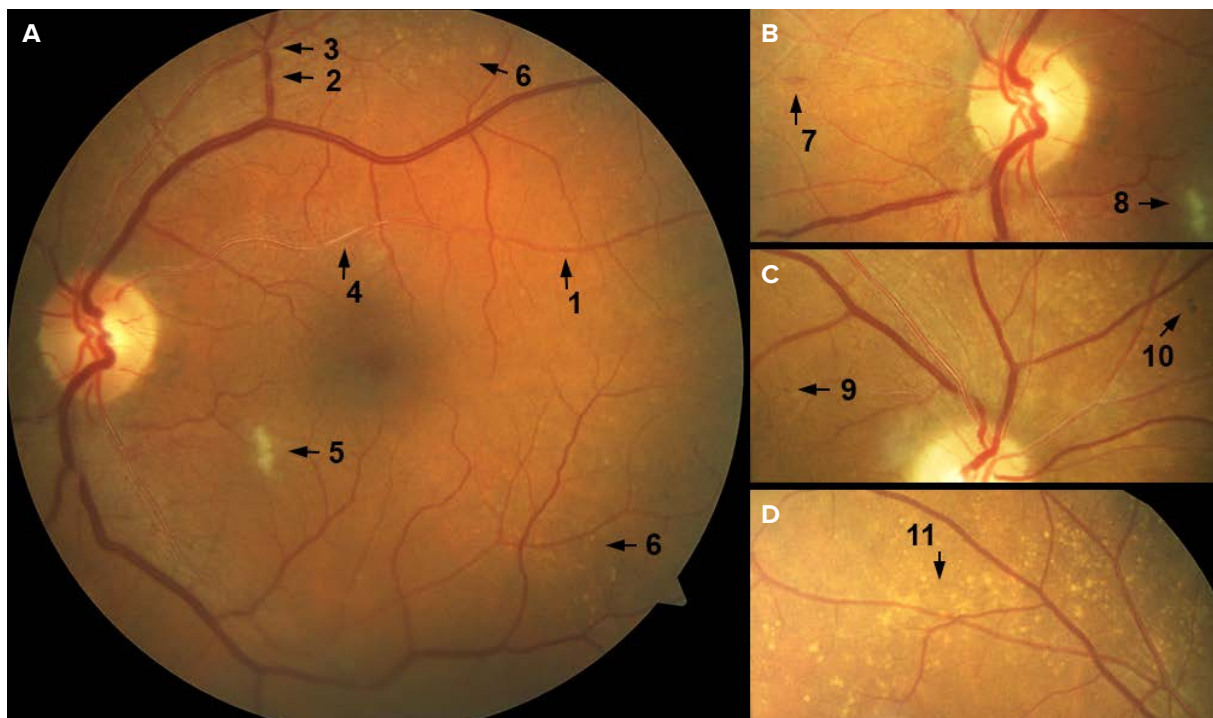
## CARDIOVASCULAR IMAGING

As a target organ damage in the context of hypertension, echocardiography revealed left ventricular hypertrophy with a left ventricular mass index of 114 g/m<sup>2</sup> (considered moderately abnormal), diastolic dysfunction of the left ventricle with impaired relaxation pattern, and no dilatation of the left atrium (left atrial volume index 23 mL/m<sup>2</sup> in the reference range and preserved ventricular systolic function).<sup>9,10</sup>

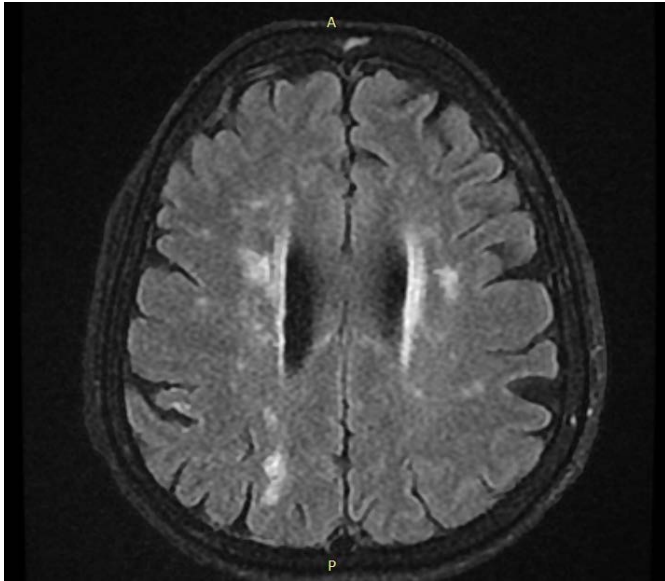
The ultrasound assessment of carotid arteries revealed diffuse intima-media thickening and 70% stenosis of the right internal carotid artery, with non-stenotic atherosclerotic plaques of the left internal carotid artery and normal anterograde flow in both vertebral arteries.

## RETINAL IMAGING

Due to visual acuity complaints, the patient was referred to the Ophthalmology department for further evaluation of hypertensive and diabetic end-organ damage. Retinal photography and ocular coherence tomography (OCT) were performed using a Carl Zeiss Visucam 500 fundus camera



**FIGURE 1.** Retinal changes of grade 3 hypertensive retinopathy and associated end-organ damage. Image A. Fundus photograph of the macular region showing 1. generalized arteriolar narrowing and 2. venular caliber changes; 3. arterio-venous nicking; 4. copper wiring reflex and 5. cotton wool spot; 6. Drusen deposits were visualized along the superior and inferior vascular arcades. Close-up photograph B. presents damage in the retinal nerve fiber layer – 7. flame-shaped hemorrhage and 8. cotton wool spot. Image C. shows 9. a micro-aneurysm and presumably 10. an Elschnig spot. Close-up photograph D. reveals abundant Drusen deposits along the superior vascular arcade in the left eye.

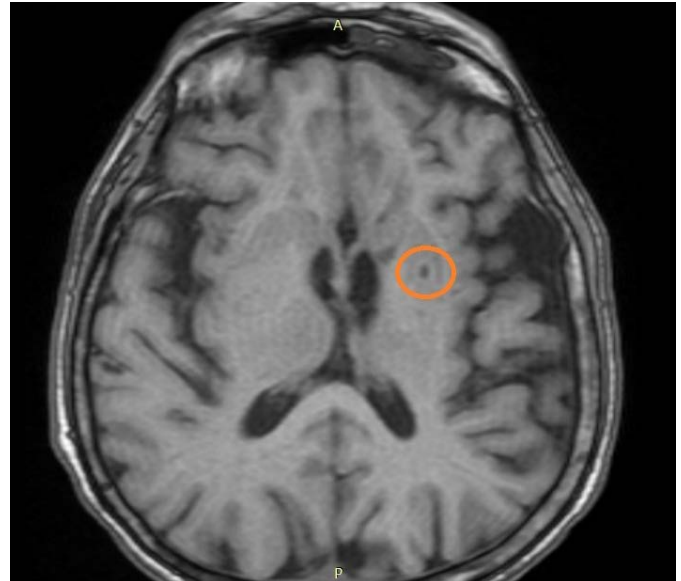


**FIGURE 2.** Periventricular white matter hyperintensities and deep white matter lesions (FLAIR MRI sequence), periventricular white matter lesions (WML) Fazakas grade 3 (irregular periventricular WML extending into the deep white matter), and subcortical deep WML Fazakas grade 2 (beginning confluence of foci).

and Topcon Triton OCT. Retinal microvascular changes characteristic to hypertensive retinopathy were observed, including vascular caliber changes, nipping, copper wiring of the arteriolar walls, flame hemorrhages, hard exudates, and cotton wool spots (Figure 1). Macular region OCT ruled out macular edema in both eyes. Considering the Keith-Wagner-Barker classification, the patient presented grade 3 hypertensive retinopathy alongside signs of chorioidopathy with focal choroidal infarct areas (Elschnigs spots). Microaneurysms, hemorrhages, hard exudate, and cotton wool spot were indicators for moderate non-proliferative diabetic retinopathy (ETDRS classification). The pathological features of retinal microvasculature caused by the association of hypertension and diabetes were aggravated by the presence of Drusen deposits in the equatorial region of the retina. Further eye examination identified early stage cataract in both eyes, responsible for the patient's visual acuity complaints.

### DIAGNOSTIC CHALLENGES

In this context, with an oligosymptomatic 70% carotid artery stenosis that needed medical therapy and aggressive cardiovascular risk factor control and mild cognitive dysfunction, the question was whether there is an indication to perform a brain imaging study. The patient underwent brain magnetic resonance imaging (MRI), which revealed



**FIGURE 3.** Lacunar infarction (T2 weighted MRI sequence)

both macro- and microvascular lesions, such as multiple vascular lesions in the periventricular white matter and sequelae of a former ischemic stroke in the territory of the left posterior cerebral artery (Figures 2 and 3).

### THERAPEUTIC INTERVENTION

The patient needed effective control of risk factors, hypertension, diabetes, and hypercholesterolemia, including dietary changes and increase of physical activity level. Pharmacologic intervention included adding a low-dose beta-blocker with vasodilator activity (carvedilol) to her former antihypertensive therapy in order to obtain an optimal rate and blood pressure control. She stayed on metformin and atorvastatin, with a good glycaemia control and lipid parameters in normal range. Antiplatelet therapy was added to her therapeutic regimen for secondary stroke prevention. Clopidogrel has been prescribed, as the patient was known with intolerance to aspirin. Given the WML, lacunar infarction, and silent stroke in this hypertensive patient with mild cognitive impairment and the high risk of stroke increased by the presence of these lesions in association with the 70% carotid stenosis, we considered that the patient had an indication for carotid revascularization.<sup>11</sup> However, the patient did not accept to proceed with carotid angiography and carotid percutaneous intervention.

### DISCUSSIONS

Chronic hypertension leads to concomitant remodeling of the cardiac and vascular systems and various organs, espe-



cially the brain, kidney, and retina. The brain is an early target for organ damage due to high blood pressure (BP), which is the major modifiable risk factor of ischemic and hemorrhagic stroke in men and women, as well as small vessel disease predisposing to lacunar infarction, WML, and cerebral microbleeds, which are frequently silent. The clinical significance and pathological substrate of WML are incompletely understood, but it is known that WML are an important prognostic factor for stroke, cognitive impairment, dementia, and death.<sup>12</sup>

The presence of silent brain infarcts is not uncommon in elderly patients; their prevalence (both lacunar infarcts and larger subcortical infarcts) in Framingham study participants aged  $62 \pm 9$  years was 10.7%.<sup>3</sup> Risk factors for silent brain infarcts evidenced by a systematic review are advanced age, hypertension, diabetes mellitus, and smoking.<sup>13</sup> In our case, all these factors were present.

Several studies have shown that certain ambulatory blood pressure monitoring parameters are associated with cognitive function. High nocturnal systolic blood pressure level, non-dipper status, and exaggerated blood pressure variability, are all suggested to be significant determinants of cognitive impairment, which was also the case in our patient.<sup>12</sup>

The aspect of the patient's retina indicated several irreversible features of microvascular damage. The most important therapeutic target in order to preserve sight is blood pressure and glycaemia control. Furthermore, retinal evaluation for microvascular integrity provides key information for interdisciplinary assessment in the appropriate context. A population-based case-control study found that retinal microvascular changes are independently associated with cardiovascular mortality.<sup>14</sup> The National Health Examination Survey reported a stronger association between fundus microvascular changes and ischemic heart disease in women, suggesting the necessity of a vigilant follow-up.<sup>15</sup> Several studies investigated cerebrovascular pathologies through the retina. The Atherosclerosis Risk in Community Study suggested cerebrovascular risk stratification according to microvascular retinopathy, showing that several retinal abnormalities were predictive for lacunar stroke incidence.<sup>16,17</sup> Vice-versa, Lindley *et al.* reported that patients with acute lacunar stroke were more likely to present microvascular retinopathy, suggesting once more that microvascular changes are concomitant both in the retina and the brain. Retinal imaging was used in a series of studies where retinal vascular changes were correlated with dementia as a result of cerebrovascular disease outcome, but inconsistent findings were reported.<sup>18,19</sup> However, Drusen deposits of the retina could be in relationship with reduced cognitive function, as described in the Tromsø

Study.<sup>20</sup> These findings suggest that retinal evaluation should be considered for better understanding of the consequences of hypertension and associated comorbidities and accordingly, it should be followed by an interdisciplinary health-care management and a comprehensive prevention plan.

## CONCLUSIONS

Our case illustrated that even behind a mild cognitive impairment detected with sensitive cognitive tests, extensive anatomic cerebral lesions can be found. Severe retinal changes in this patient further increased the probability of the presence of cerebrovascular lesions. Cognitive function testing should be more frequently used in clinical practice in order to unmask silent cerebrovascular disease.

## ACKNOWLEDGEMENT

Funding was provided by the Hungarian Academy of Science, contract nr. 0346/26.02.2016. Special thanks to the Studium Prospero Foundation.

## CONFLICT OF INTEREST

Nothing to declare.

## REFERENCES

1. Ninomiya T, Ohara T, Hirakawa Y, et al. Midlife and late-life blood pressure and dementia in Japanese elderly: the Hisayama study. *Hypertension*. 2011;58:22-28.
2. Gelber RP, Launer LJ, White LR. The Honolulu-Asia Aging Study: epidemiologic and neuropathologic research on cognitive impairment. *Curr Alzheimer Res*. 2012;9:664-672.
3. Das RR, Seshadri S, Beiser AS, et al. Prevalence and Correlates of Silent Cerebral Infarcts in the Framingham Offspring Study. *Stroke*. 2008;39:2929-2935.
4. Muela HCS, Costa Hong VA, Yassuda MS, Moraes NC, Memória CM, Machado MF, et al. Hypertension Severity Is Associated With Impaired Cognitive Performance. *J Am Heart Assoc*. 2017;6:e004579.
5. Mancia G, Fagard R, Narkiewicz K, et al. 2013 ESH/ESC guidelines for the management of arterial hypertension: the Task Force for the Management of Arterial Hypertension of the European Society of Hypertension (ESH) and of the European Society of Cardiology (ESC). *Eur Heart J*. 2013;34(28):2159-2219.
6. Folstein MF, Folstein SE, McHugh PR. "Mini-mental state". A practical method for grading the cognitive state of patients for the clinician. *J Psychiatr Res*. 1975;12:189-198.
7. Nasreddine ZS, Phillips NA, Bédirian V, et al. The Montreal Cognitive Assessment, MoCA: a brief screening tool for mild cognitive impairment. *J Am Geriatr Soc*. 2005;53:695-699.
8. Brodaty H, Pond D, Kemp NM, et al. The GPCOG: a new screening test for dementia designed for general practice. *J Am Geriatr Soc*. 2002;50:530-534.
9. Lang RM, Bierig M, Devereux RB, et al. Recommendations for chamber quantification: a report from the American Society of Echocardiography's Guidelines and Standards Committee and the Chamber Quantification Writing Group, developed in conjunction with the European Association of Echocardiography, a branch of the European Society of Cardiology. *J Am Soc Echocardiogr*. 2005;18:1440-1463.

10. Pritchett AM, Jacobsen SJ, Mahoney DW, Rodeheffer RJ, Bailey KR, Redfield MM. Left atrial volume as an index of left atrial size: a population-based study. *J Am Coll Cardiol*. 2003;41:1036-1043.
11. Brott TG, Halperin JL, Abbara S, Bacharach JM, Barr JD, Bush RL, et al. 2011 ASA/ACCF/AHA/AANN/AANS/ACR/ASNR/CNS/SAIP/SCAI/SIR/SNIS/SVM/SVS Guideline on the Management of Patients With Extracranial Carotid and Vertebral Artery Disease: Executive Summary. *J Am Coll Cardiol*. 2011;57:1002-1044.
12. Sierra C, Doménech M, Camafort M, Coca A. Hypertension and Mild Cognitive Impairment. *Curr Hypertens Rep*. 2012;14:548-555.
13. Fanning JP, Wong AA, Fraser JF. The epidemiology of silent brain infarction: a systematic review of population-based cohorts. *BMC Med*. 2014;12:119.
14. Wong TY, Klein R, Nieto FJ, et al. Retinal microvascular abnormalities and 10-year cardiovascular mortality. *Ophthalmology*. 2003;110:933-940.
15. Gillum RF. Retinal arteriolar findings and coronary heart disease. *Am Heart J*. 1991;122:262-263.
16. Yatsuya H, Folsom AR, Wong TY, et al. Retinal Microvascular Abnormalities and Risk of Lacunar Stroke: Atherosclerosis Risk in Communities Study. *Stroke*. 2010;41:1349-1355.
17. Wong TY, Klein R, Sharrett AR, et al. Cerebral white matter lesions, retinopathy, and incident clinical stroke. *JAMA*. 2002;288:67-74.
18. Lindley RI, Wang JJ, Wong M-C, et al. Retinal microvasculature in acute lacunar stroke: a cross-sectional study. *Lancet Neurol*. 2009;8:628-634.
19. McGrory S, Cameron JR, Pellegrini E, et al. The application of retinal fundus camera imaging in dementia: A systematic review. *Alzheimers Dement (Amst)*. 2016;6:91-107.
20. Lindekleiv H, Erke MG, Bertelsen G, et al. Cognitive function, drusen, and age-related macular degeneration: a cross-sectional study. *Eye (Lond)*. 2013;27:1281-1287.