

# Unrelated Allogeneic Stem Cell Transplantation in a Patient with Chronic Myeloid Leukemia in Blast Crisis

István Benedek<sup>1,2</sup>, Erzsébet Lázár<sup>1,2</sup>, Judit Beáta Köpeczi<sup>1</sup>, István Benedek Jr<sup>1,2</sup>, Aliz Beáta Tunyogi<sup>1,2</sup>, Szende Jakab<sup>1,2</sup>, Annamária Pakucs<sup>1</sup>

<sup>1</sup> Clinic of Hematology and Bone Marrow Transplantation Unit, Tîrgu Mureş, Romania

<sup>2</sup> University of Medicine and Pharmacy, Tîrgu Mureş, Romania

## CORRESPONDENCE

### Erzsébet Lázár

Str. Revoluției nr. 35  
540042 Tîrgu Mureş, Romania  
Tel: +40 265 218 739  
E-mail: erzsebetlazarbenedek@gmail.com

## ARTICLE HISTORY

Received: 19 November, 2016  
Accepted: 29 December, 2016

## ABSTRACT

Chronic myeloid leukemia (CML) is a clonal myeloproliferative disorder, which can involve the hematopoietic stem cell or early progenitor cells, without the loss of their capacity to differentiate. Typically, CML has three clinical phases: a chronic phase, an accelerated phase, and an aggressive transformation in blast crisis, analogous to acute leukemia. The following article presents the case of a 49-year-old patient diagnosed with Philadelphia-negative CML in blastic transformation, where after multiple conventional acute leukemia induction chemotherapy regimens an unrelated allogeneic hematopoietic stem cell transplant was performed.

**Keywords:** unrelated allogeneic stem cell transplantation, chronic myeloid leukemia, blast crisis

## INTRODUCTION

Chronic myeloid leukemia (CML) is a clonal myeloproliferative disorder, which can involve the hematopoietic stem cell or early progenitor cells, without the loss of their capacity to differentiate.<sup>1</sup>

This disease is associated with the Philadelphia chromosome t(9;22)(q34;q11) and the BCR-ABL fusion gene, which causes a permanently active tyrosine kinase. This is the target of tyrosine kinase inhibitor (TKI) therapies used in the treatment of CML.<sup>2</sup>

Approximately 10% of CML patients do not have the Philadelphia chromosome on cytogenetic analysis. BCR-ABL-negative CML is reported to have a lower risk for blastic transformation; however, it presents a shorter survival than BCR-ABL-positive CML.

Typically, CML has three clinical phases: a chronic phase, an accelerated phase, and an aggressive transformation in blast crisis, analogous to acute leukemia.

The rhythm of CML progression varies, depending on the time between disease onset and diagnosis, on the efficacy of the treatment, and also on the

István Benedek • Str. Gheorghe Marinesu nr. 38, 540139 Tîrgu Mureş, Romania, Tel: +40265215551.

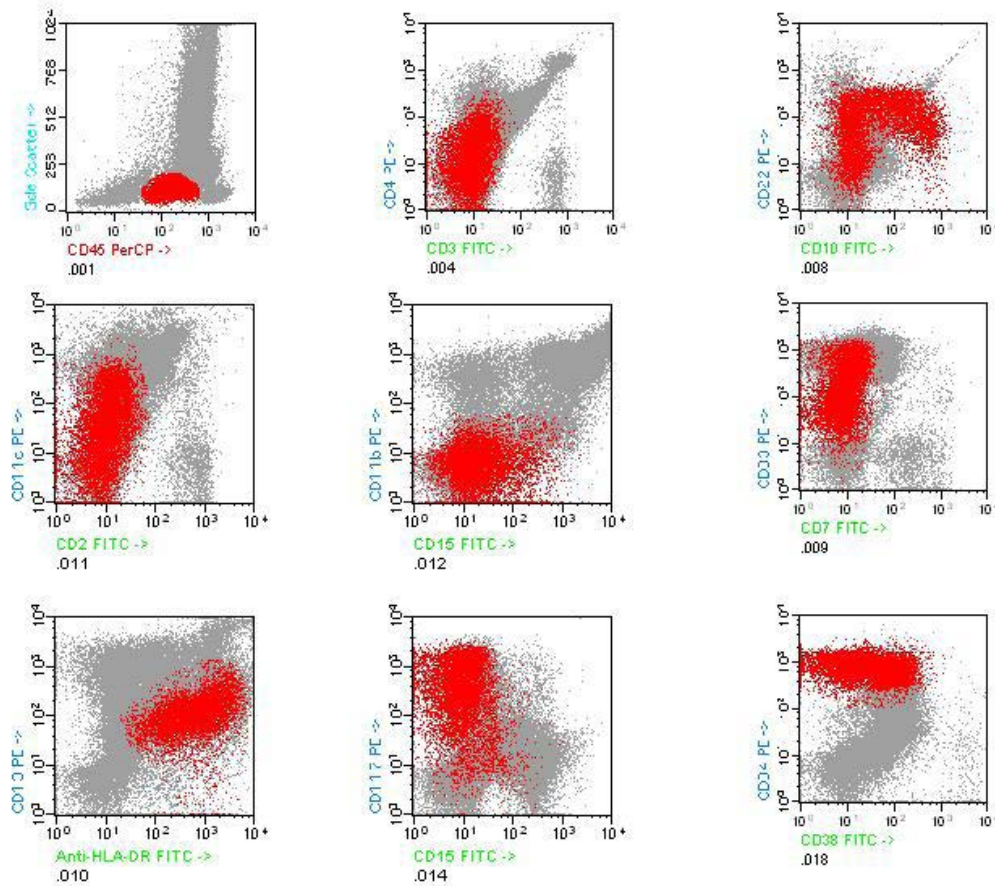
Judit Beáta Köpeczi • Str. Revoluției nr. 35, 540042 Tîrgu Mureş, Romania, Tel: +40 265 218 739

István Benedek Jr • Str. Gheorghe Marinesu nr. 38, 540139 Tîrgu Mureş, Romania, Tel: +40 265 215 551

Aliz Beáta Tunyogi • Str. Gheorghe Marinesu nr. 38, 540139 Tîrgu Mureş, Romania, Tel: +40 265 215 551

Szende Jakab • Str. Gheorghe Marinesu nr. 38, 540139 Tîrgu Mureş, Romania, Tel: +40 265 215 551

Annamária Pakucs • Str. Revoluției nr. 35, 540042 Tîrgu Mureş, Romania, Tel: +40 265 218 739



**FIGURE 1.** Immunophenotype of the blast cells (red) detected by flowcytometry in the bone marrow sample. Data were analyzed with Paint-A-Gate software (BD Biosciences, San Jose, CA, USA).

individual genetic characteristics of the disease.<sup>3</sup> Despite of the fast evolution and wide use of new-generation TKI therapies in Philadelphia (Ph)-positive cases, BCR-ABL-negative CML still does not have any newly introduced efficient treatment.

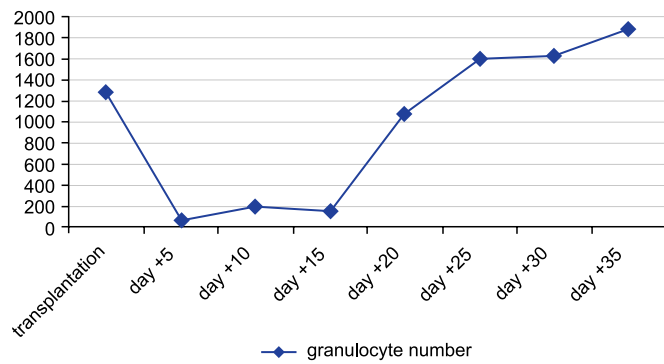
In approximately 30% of the cases, the blast crisis is of the lymphoid line rather than the myeloid phenotype. According to the World Health Organization (WHO), the diagnostic criteria of blast-phase CML require the presence of >20% blasts in bone marrow aspirate or in peripheral blood.

Despite the high mortality and high risk of post-transplantation complications, such as infections, graft rejection, or graft versus host disease, allogeneic stem cell transplantation is still the only curative treatment of Ph-negative blast-phase CML.

In our article we describe the case of a patient with initial presentation in blast-phase (BP) CML, which, besides conventional chemotherapy, also represents an indication for allogeneic hematopoietic stem cell transplantation (HSCT).

## CASE PRESENTATION

A 49-year-old male patient with rural provenience, without prior personal pathological history, appears in September 2015 at the Hematology Clinic with the following symptoms: asthenia, fatigue, weight loss, and abdominal discomfort. The clinical examination revealed multiple bilateral submandibular adenopathies with an average size of 2 cm and a splenomegaly of 2 cm under the left costal margin. Paraclinical examinations showed leukocytosis (WBC: 41,240/ $\mu$ L) with anemia (Hb: 6.4 g/dL) and thrombocytopenia (PLT: 81,000/ $\mu$ L). The flowcytometric analysis of the bone marrow aspirate evidenced the presence of 25% of myeloblasts and aberrant lymphoid markers with the following phenotype: CD13+, CD33+, CD15+ (18%); CD11b-, CD11c+ (52%); CD64+ (11.45%); CD14-, CD16-, CD36-, CD22+ (72%); CD10+ (35%); CD19-, CD20-, HLA-DR+, CD34+, CD38+ (23%); CD117, CD123+ (42%); CD2-, CD3-, CD4+ (25.3%); CD5-, CD7-, CD8-, CD56- (Figure 1).



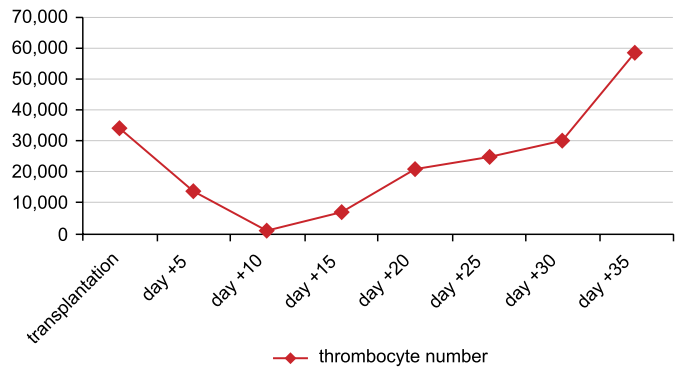
**FIGURE 2.** The evolution of granulocyte number after the transplantation

All the clinical and paraclinical examinations confirmed the diagnosis of a Ph-negative CML in blastic transformation. Induction chemotherapy courses were been initiated, according to the national acute myeloid leukemia protocol. After the first “2+7” scheme induction course (Ara-C + Anthracycline), the bone marrow aspirate examination showed the presence of 7.5% myeloblasts; this was followed by a second induction course, without obtaining remission.

After three inductions and three courses of second-line Sierra scheme (Idarubicin + Ara-C + Etoposide) treatments, we discovered a residual disease consisting of 22% of myeloblasts in the bone marrow aspirate. In July 2016, after three courses of induction, three courses of Sierra protocol therapy and one Flag-Eto scheme (Fludarabine + Ara-C + Etoposide) treatment, the bone marrow aspirate contained 19% myeloblasts. During these seven courses of chemotherapy treatment the patient’s hematological values showed medium anemia (Hb range: 6.4–10.7 g/dL) with severe thrombocytopenia (PLT range: 2,000–84,000/ $\mu$ L).

**TABLE 1.** Paraclinical analyses at the diagnosis of graft versus host disease

Analysis	Value	Reference value
Leukocytes ( $\mu$ L)	32,430	4,000–9,000
Hemoglobin (g/dL)	11.0	13.0–17.0
Thrombocytes ( $\mu$ L)	4,000	150,000–400,000
Total bilirubin (mg/dL)	19.2	0.0–1.2
Direct bilirubin (mg/dL)	17.06	0.0–0.41
Alkaline phosphatase (U/L)	1860	98–279
GGT (U/L)	402	7–52
LDH (U/L)	544	220–460
GOT (U/L)	100	0–46
GPT (U/L)	177	0–49



**FIGURE 3.** The evolution of thrombocyte number after the transplantation

Given the aggressive character of the disease and its resistance to conventional chemotherapy, stem cell donor search has been initiated in order to perform an allogeneic transplantation.

In order to maintain and to keep under control the patient’s hematological status waiting for stem cell donor match, we continued the Flag-Eto courses in 28-day cycles. A total of four Flag-Eto courses were administered.

In November 2016, a 100% compatible donor has been found, and on November 23, 2016, we started the pre-transplant conditioning according to the BuCy (Busulfan + Cyclophosphamide) scheme protocol. On November 30, 2016, the patient underwent the allogeneic nonrelated hematopoietic stem cell transplantation. On day -3 before transplantation, immunosuppression has been started with cyclosporine, which was later changed to tacrolimus due to a lack of optimal drug absorption and insufficient levels of cyclosporine. Additional immunosuppressive treatment has been administered with Methotrexate (days +1, +3, +6) and Methylprednisolone. The engraftment period was 21 days for granulocytes (PMN  $>500/\mu$ L) and 31 days for thrombocytes (PLT  $>50,000/\mu$ L) (Figure 2 and Figure 3).

During post-transplant aplasia, preventive wide-spectrum antibiotic, antimycotic, and antiviral treatment was administered. The hydroelectrolytic imbalance that occurred was treated with repolarizing solutions. During aplasia, the patient benefited of substitutive and supportive treatment with human albumin and immunoglobulin. After 43 days of hospitalization, the patient was released from hospital with preventive anti-infectious therapy and tacrolimus immunosuppression. The patient presented on weekly controls for hematological and immunosuppression status monitoring.

Ninety-five days after the transplantation, the patient presented in the emergency unit with the following symptoms: diffuse cutaneous erythematous eruptions, fever,

productive cough, icterus, and diarrhea. The laboratory analysis showed leukocytosis, thrombocytopenia, anemia, and increased hepatic marker levels (Table 1). The clinical examination revealed hepatosplenomegaly and basal bilateral crepitations. The clinical and paraclinical examinations confirmed the diagnosis of a cutaneous, hepatic, and intestinal graft versus host disease and the presence of a bilateral pneumonia. In order to stabilize the patient's hematological and biological status, corticotherapeutic and immunosuppressive treatment has been initiated with wide spectrum anti-infectious and substitutive (erythrocyte and thrombocyte concentrate) therapy. Despite the perfect engraftment analyzed with a chimerism test on day +90 after transplantation, the complications that appeared conferred an unpredictable evolution to the case – chronic hepatic graft versus host disease, with the possible and probable infectious complications.

The patient agreed to the publication of his data, and the institution where the patient had been admitted, approved the publication of the case.

## DISCUSSION

In patients who progress to the terminal blast phase of CML, survival is typically measured in months, unless allogeneic transplant is an option. The management of a CML patient in blast phase depends on the previous treatment and the type of transformation (myeloid, lymphoid).<sup>4,5</sup> The objective of treatment is to obtain clinical remission or to pass back to chronic phase until a suitable donor is found in order to perform an allogeneic stem cell transplantation.<sup>6,7</sup> If a CML patient is resistant to TKI therapy or the BCR-ABL gene is negative, then conventional acute leukemia regimen induction chemotherapy should be administered to achieve remission.

Although nowadays more than 80% of patients are diagnosed in the chronic phase of CML, in our case above the patient was already in blast crisis at the time of diagnosis.<sup>8</sup> The disease's resistance to conventional chemotherapy underlined the very aggressive nature of leukemia. The impossibility of obtaining clinical remission represented a big challenge in improving the patient's survival.

## CONCLUSIONS

Despite the increased mortality and morbidity and the fact that acute graft versus host disease is a hardly controllable process, the allogeneic stem cell transplantation remains the only therapeutic solution in case of a treatment-resistant, BCR-ABL-negative blast-phase CML.

## CONFLICT OF INTEREST

Nothing to declare.

## REFERENCES

1. Baccarani M, Deininger MW, Rosti G, et al. European LeukemiaNet recommendations for the management of chronic myeloid leukemia. *Blood*. 2013;122:872-884.
2. Powers B, Kambhampati S. Blast Phase Chronic Myelogenous Leukemia. *Fed Pract*. 2014;31:44-48.
3. Szántó A, Pap Zs, Lázár E. Leucemia mieloidă cronică. Tehnici moderne de diagnostic și monitorizare. Tîrgu Mureș: University Press Petru Maior; 2015.
4. Hehlmann R, Saussele S. Treatment of chronic myeloid leukemia in blast crisis. *Haematologica*. 2008;93:1765-1769.
5. Karbasian Esfahani M, Morris EL, Dutcher JP, et al. Blastic phase of chronic myelogenous leukemia. *Curr Treat Options Oncol*. 2006;7:189-199.
6. Pavlu J, Szydlo RM, Goldman JM, Apperley JF. Three decades of transplantation for chronic myeloid leukemia: what have we learned? *Blood*. 2011;117:755-763.
7. Tunyogi AB, Benedek I, Benedek Lázár E, et al. The results of allogeneic stem cell transplantation in CML – the experience of BMT Unit Tîrgu Mureș. *Acta Medica Marisiensis*. 2011;57:371-374.
8. Gupta A, Khattry N. Current status of hematopoietic stem cell transplant in chronic myeloid leukemia. *Indian J Med Paediatr Oncol*. 2014;35:207-210.