

# Myocardial Fibrosis and the Risk of Recurrence in Atrial Fibrillation

István Kovács<sup>1</sup>, András Mester<sup>2</sup>, Lehel Bördi<sup>2</sup>, Alexandra Stănescu<sup>2</sup>, Sebastian Condrea<sup>2</sup>, Monica Chițu<sup>1</sup>, Annabell Benedek<sup>2</sup>, Imre Benedek<sup>1,2</sup>

<sup>1</sup> University of Medicine and Pharmacy, Tîrgu Mureș, Romania

<sup>2</sup> Center of Advanced Research in Multimodality Cardiac Imaging, Cardio Med Medical Center, Tîrgu Mureș, Romania

## CORRESPONDENCE

**András Mester**

Str. 22 Decembrie 1989 nr. 76  
540124 Tîrgu Mureș, Romania  
Tel: +40 265 217 333  
E-mail: andras.mester@yahoo.com

## ARTICLE HISTORY

Received: 13 October, 2016  
Accepted: 8 November, 2016

**István Kovács** • Str. Gheorghe Marinescu nr. 38,  
540139 Tîrgu Mureș, Romania. Tel: +40 265 215 551.  
E-mail: kov\_istvan@yahoo.com

**Lehel Bördi** • Str. 22 Decembrie 1989 nr. 76, 540124  
Tîrgu Mureș, Romania. Tel: +40 265 217 333. E-mail:  
bordi\_lehel@yahoo.com

**Alexandra Stănescu** • Str. 22 Decembrie 1989 nr. 76,  
540124 Tîrgu Mureș, Romania. Tel: +40 265 217 333.  
E-mail: alexandra.stanescu90@gmail.com

**Sebastian Condrea** • Str. 22 Decembrie 1989 nr. 76,  
540139 Tîrgu Mureș, Romania. Tel: +40 265 217 333.  
E-mail: sebastian.condrea@yahoo.com

**Monica Chițu** • Str. Gheorghe Marinescu nr. 38  
540139 Tîrgu Mureș, Romania. Tel: +40 265 215 551.  
E-mail: iuliacitu@yahoo.com

**Annabell Benedek** • Str. 22 Decembrie 1989 nr. 76,  
540124 Tîrgu Mureș, Romania. Tel: +40 265 217 333.  
E-mail: annabell.benedek@yahoo.com

**Imre Benedek** • Str. Gheorghe Marinescu nr. 38,  
540139 Tîrgu Mureș, Romania. Tel: +40 265 215 551.  
E-mail: imrebenedek@yahoo.com

## ABSTRACT

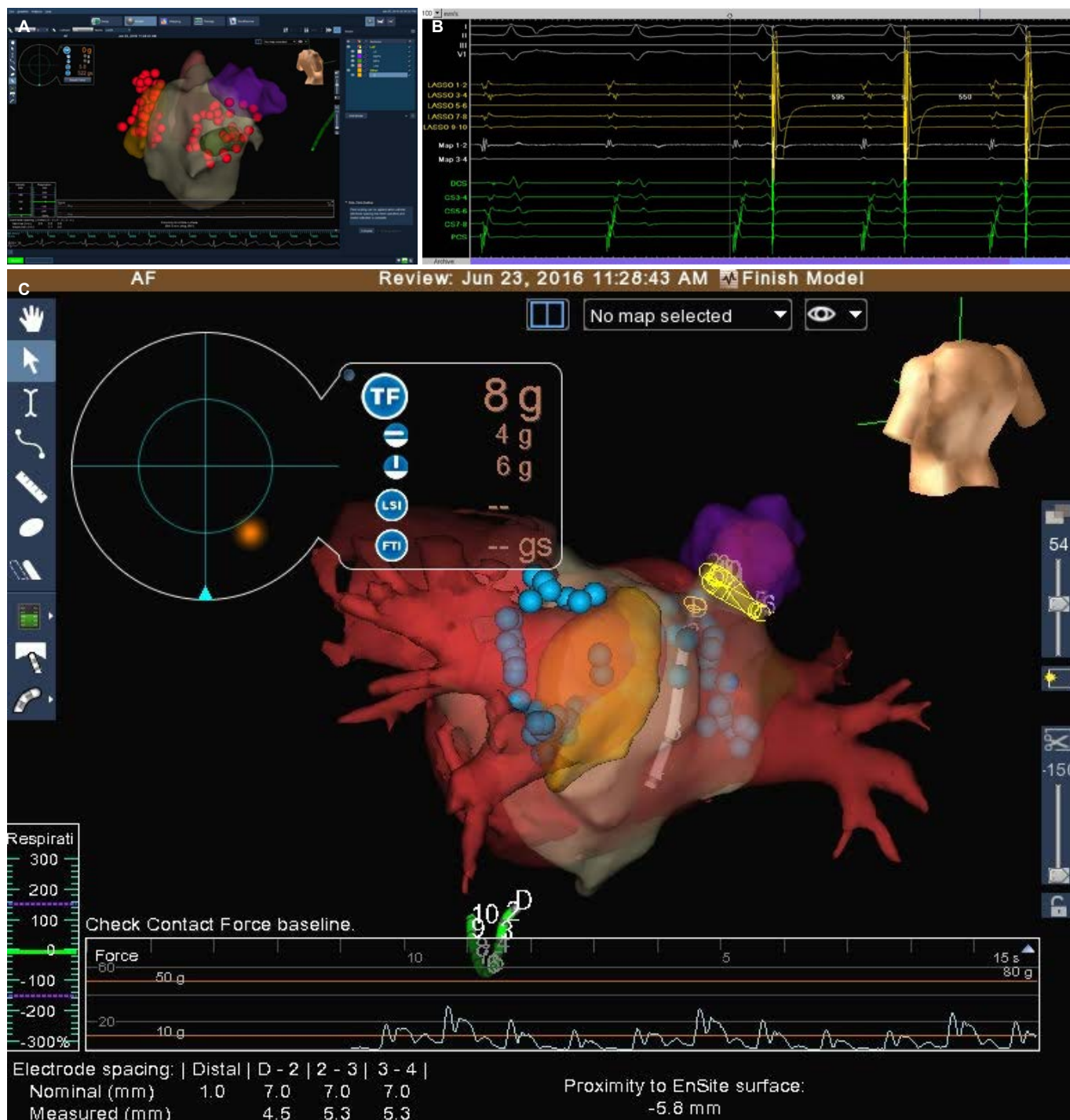
Atrial fibrillation (AF) is the most frequent cardiac arrhythmia increasing the risk of stroke and mortality from heart failure. Magnetic resonance imaging was used by several authors for assessment of atrial fibrosis and to predict the rate of recurrence following AF ablation. The aim of this manuscript was to summarize the new data in the literature regarding the role of atrial fibrosis in AF imaging and the role of cardiac fibrosis in predicting AF recurrence after radiofrequency ablation.

**Keywords:** atrial fibrillation, cardiac MRI, atrial fibrosis, catheter ablation

## INTRODUCTION

Atrial fibrillation (AF) is the most common cardiac arrhythmia, with a prevalence of 0.4–1% in the general population. AF increases the risk of stroke, approximately 15% of all strokes being caused by AF. AF also significantly increases the risk of mortality from heart failure.<sup>1</sup> Rhythm control therapy, including pharmacological therapy and direct electrical cardioversion, was not found to be as effective as catheter ablation in maintaining sinus rhythm and symptom management.<sup>2,3</sup> Catheter ablation of AF consisting especially in pulmonary vein (PV) isolation (with electro-anatomic mapping) has provided better outcomes when applied in patients with paroxysmal AF.<sup>4,5</sup> However, the long-term efficacy, despite significant technological improvements, remains controversial.

The degree of atrial fibrosis influences the outcome of pulmonary vein isolation performed by various ablation techniques (cryo or radiofrequency). There are several methods for the evaluation of left atrial anatomy, pulmonary veins or left appendage, but only late gadolinium-enhanced cardiac magnetic resonance (LGE-CMR) can evaluate the degree of atrial fibrosis. To predict the outcome of AF ablation, several parameters should be analyzed: the type of atrial fibrillation (paroxysmal, persistent, long-standing persistent), the coronary status and anatomy, associated pathologies, the type of ablation (cryo, radiofrequency), the le-



**FIGURE 1.** 3D anatomico-electrical mapping used during the complex navigation procedures for AF ablation in the catheterization laboratory. **A, B** – isolation of pulmonary veins; **C** – intracardiac ECG tracing during an EP study for AF ablation

sion formation (contact force catheter), and the ablation site (only pulmonary vein isolation, other ablation lines). It is also important to define AF recurrence and what methods are used to demonstrate complete isolation of the pulmonary veins: Holter monitoring, loop recorder, electrophysiological study for complete vein isolation. There are no available large studies in the literature demonstrat-

ing strong correlations between various parameters and long-term success rate. Later studies, especially after MRI was introduced as an evaluation method for atrial function, found significant correlations between the degree of atrial fibrosis and long-term outcome after AF ablation, and showed the role of electroanatomic guided pulmonary vein isolation.<sup>6,7</sup>

The aim of this manuscript was to summarize the new data in the literature regarding the role of atrial fibrosis in AF imaging and the role of cardiac fibrosis in predicting AF recurrence after radiofrequency ablation.

## CATHETER ABLATION IN AF

Catheter ablation of AF has continuously improved as a treatment option (both in procedure time and safety terms) in the last ten years. Figure 1 presents an exemplification of the 3D anatomic-electrical mapping used during the complex navigation procedures for catheter AF ablation in the catheterization laboratory.

Despite the significant progress encountered in recent years in ablation techniques, the success rate is currently ranging between 50% and 70%.<sup>8,9</sup> Recent developments in ablation techniques did not lead to an increase in the procedure's success rate. In many patients, only repeated procedures can suppress the arrhythmia.<sup>10</sup> A prospective multicenter study that included 167 patients with paroxysmal atrial fibrillation, comparing PVI with antiarrhythmic medication, showed that 66% of subjects had better results following ablation during the 9 months of follow-up, compared to patients that had received antiarrhythmic drugs.<sup>11</sup>

Currently the most challenging task is to parallelly improve ablation techniques, as well as to find new arrhythmia substrates and to reduce the recurrence rates of atrial fibrillation. Fibrotic atrial regions are thought to contribute not only to the initiation, but also to the maintenance of AF. The best imaging method to evaluate left atrial fibrosis is magnetic resonance imaging, and late gadolinium-enhancement MRI is able to quantify the degree of atrial fibrosis, which is linked to the degree of left atrium (LA) remodeling, as well as to the rates of recurrence of atrial fibrillation following the ablation.

It has been shown that arrhythmia recurrence is significantly higher when  $\geq 30\%$  fibrosis is present on preprocedural MRI scans, while fibrosis  $< 30\%$  shows better results after catheter ablation procedures. Noninvasive evaluation of the myocardial tissue using LGE-MRI is a powerful tool for finding and quantifying atrial tissue changes resulting from the fibrosis. The extent of LA fibrosis is positively correlated with the amount of time the patients had been in atrial fibrillation, and persistent AF was linked with a more increased LA volume and fibrosis.<sup>12</sup> Nowadays, the selection of candidates for catheter ablation remains subjective, usually including patients with failed antiarrhythmic drug therapy. We can improve ablation outcomes with better and more objective selection criteria of patients with AF who undergo this procedure.

Bisbal *et al.*, in a study on 102 patients with atrial fibrillation, observed that PVI led to a spherical reverse left atrial remodeling in 42.2% of patients and a reduction in LA volume in 69% of patients following the procedure. However, LA reverse spherical remodeling is suggested to be a sensitive marker of favorable remodeling after PV isolation compared to volumetric remodeling.<sup>13</sup>

CMR image acquisition, image post-processing and procedural technique is very important when using LGE-MRI to identify gaps within the lines of ablation. This has raised controversies in the literature regarding the usefulness of LGE-MRI. Harrison *et al.* reported the inefficacy of LGE-CMR to provide information about electrical conduction following pulmonary vein isolation. The density of ablation points is significant when the electro-anatomical maps are recreated with the help of MRI, and gap re-isolation during repeated procedures leads to a significant decrease in the rate of AF recurrence.<sup>14,15</sup>

## INTEGRATION OF CMR INTO THE ELECTROPHYSIOLOGICAL LABORATORY

Integrating CMR into the electrophysiology (EP) laboratory has recently been accepted and is expected to lead to important improvements in increasing the efficacy of PVI, with no conditions of exposure to radiation of neither the patient nor the operator. The possibility to provide reconstruction of complex navigation scar and fibrosis assessment, visualization of catheter placement and the ability to monitor the efficiency of radiofrequency ablation makes the on-site MRI very attractive. Initial experiences suggest that the method is feasible and safe.<sup>16,17</sup> Radiation exposure has been significantly reduced with the new electroanatomic mapping equipment (NAVX, Carto). However, the use of interventional MRI would fully eliminate exposure to radiation. Identifying the areas with incomplete isolation detection of gaps during the procedure can lead to a better long-term outcome following AF ablation. Temporary limitations are represented by the compatible apparatus (electrocardiograph, catheters and ablation equipment) and a signal filter for better interpretation, and also a guaranteed patient safety (current defibrillators are not safe to be used inside the MRI equipment).

## CONCLUSIONS

In conclusion, the analysis of left atrial wall fibrosis using MRI can lead to an appropriate patient selection for pulmonary vein isolation in atrial fibrillation. The post-abla-

tion assessment of lesion formation and gap identification, as well as intraprocedural magnetic resonance imaging can improve the long-term outcome after ablation and can reduce the recurrence rates of AF.

## CONFLICT OF INTEREST

Nothing to declare.

## ACKNOWLEDGEMENT

This research was supported via the research grant no. 103545/2016, contract number 43/05.09.2016, entitled “High performance multimodal MRI/CT imaging platform, for applications in computational medicine, nanoparticles and hybrid imaging for the research of ather-thrombotic disorders – CARDIO IMAGE”, financed by the Romanian Ministry of European Funds, the Romanian Government and the European Union.

## ABBREVIATIONS

AF	atrial fibrillation
CA	catheter ablation
LA	left atrium
LGE-CMR	late-gadolinium-enhancement cardiac magnetic resonance
PVI	pulmonary vein isolation

## REFERENCES

1. Feinberg WM, Blackshear JL, Laupacis A, Kronmal R, Hart RG. Prevalence, age distribution, and gender of patients with atrial fibrillation. Analysis and implications. *Arch Intern Med*. 1995;155:469-473.
2. Jaïs P, Cauchemez B, Macle L, et al. Catheter ablation versus antiarrhythmic drugs for atrial fibrillation: the A4 study. *Circulation*. 2008;118:2498-2505.
3. Pappone C, Augello G, Sala S, et al. A randomized trial of circumferential pulmonary vein ablation versus antiarrhythmic drug therapy in paroxysmal atrial fibrillation: the APAF Study. *J Am Coll Cardiol*. 2006;48:2340-2347.
4. Casaclang-Verzosa G, Gersh BJ, Tsang TS. Structural and functional remodeling of the left atrium: clinical and therapeutic implications for atrial fibrillation. *J Am Coll Cardiol*. 2008;51:1-11.
5. Pappone C, Santinelli V, Manguso F, et al. Pulmonary vein denervation enhances long-term benefit after circumferential ablation for paroxysmal atrial fibrillation. *Circulation*. 2004;109:327-334.
6. Ganesan AN, Shipp NJ, Brooks AG, et al. Long-term outcomes of catheter ablation of atrial fibrillation: a systematic review and meta-analysis. *J Am Heart Assoc*. 2013;2:e004549.
7. Ausma J, Wijffels M, Thone F, Wouters L, Allesie M, Borgers M. Structural changes of atrial myocardium due to sustained atrial fibrillation in the goat. *Circulation*. 1997;96:3157-3163.
8. Calkins H, Kuck KH, Cappato R, et al. 2012 HRS/EHRA/ECAS expert consensus statement on catheter and surgical ablation of atrial fibrillation: recommendations for patient selection, procedural techniques, patient management and follow-up, definitions, endpoints and research trial design. *J Interv Card Electrophysiol*. 2012;33:171-257.
9. Cosedis Nielsen J, Johannessen A, Raatikainen P, et al. Radiofrequency ablation as initial therapy in paroxysmal atrial fibrillation. *N Engl J Med*. 2012;367:1587-1595.
10. Badger TJ, Daccarett M, Akoum NW, et al. Evaluation of Left Atrial Lesions after Initial and Repeat Atrial Fibrillation Ablation: Lessons learned from Delayed-Enhancement MRI in Repeat Ablation Procedures. *Circulation Arrhythmia and Electrophysiology*. 2010;3:249-259.
11. Wilber DJ, Pappone C, Neuzil P, et al. Comparison of antiarrhythmic drug therapy and radiofrequency catheter ablation in patients with paroxysmal atrial fibrillation: a randomized controlled trial. *JAMA*. 2010;303:333-340.
12. Dewire J, Khurram IM, Pashakhanloo F, et al. The Association of Pre-Existing Left Atrial Fibrosis with Clinical Variables in Patients Referred for Catheter Ablation of Atrial Fibrillation. *Clinical Medicine Insights Cardiology*. 2014;8(Suppl1):25-30.
13. Bisbal F, Guiu E, Cabanas P, et al. Reversal of spherical remodelling of the left atrium after pulmonary vein isolation: incidence and predictors. *Europace*. 2014;16(6):840-7.
14. Narayan SM, Krummen DE, Clopton P, Shivkumar K, Miller JM. Direct or coincidental elimination of stable rotors or focal sources may explain successful atrial fibrillation ablation: on-treatment analysis of the CONFIRM trial (Conventional ablation for AF with or without focal impulse and rotor modulation). *J Am Coll Cardiol*. 2013;62:138-147.
15. Harrison JL, Sohns C, Linton NW, et al. Repeat left atrial catheter ablation: cardiac magnetic resonance prediction of endocardial voltage and gaps in ablation lesion sets. *Circ Arrhythm Electrophysiol*. 2015;8:270-278.
16. Nazarian S, Kollandaivelu A, Zviman MM, et al. Feasibility of real-time magnetic resonance imaging for catheter guidance in electrophysiology studies. *Circulation*. 2008;118:223-229.
17. Sommer P, Grothoff M, Eitel C, et al. Feasibility of real-time magnetic resonance imaging-guided electrophysiology studies in humans. *Europace*. 2013;15:101-108.