

ORIGINAL RESEARCH

Correlation Between Acute Impairment of Regional Contractility and Left Ventricular Remodeling after Revascularized Acute Myocardial Infarction

Tiberiu Nyulas¹, Theodora Benedek¹, Claudia Matei¹, István Kovács¹, Monica Chițu¹, Szillamér Korodi², Imre Benedek¹

¹ University of Medicine and Pharmacy of Tîrgu Mureș, Clinic of Cardiology, Tîrgu Mureș, Romania

² Cardio Med Medical Center, Department of Advanced Multimodal Imaging, Tîrgu Mureș, Romania

ABSTRACT

Introduction: The present study aims to demonstrate the role of acute impairment of regional contractility, as assessed by 3D echocardiography, in predicting LV remodeling in post acute myocardial infarction (AMI) patients.

Methods: We enrolled in the study a number of 48 subjects with AMI who underwent primary PCI followed by optimum medical therapy. In all these cases we followed the correlation between the amplitude of ventricular remodeling at 6 months postinfarction and regional contractility in the immediate postinfarction period, as assessed by 3D echo parameters at baseline: regional index of contraction amplitude (RICA) and the index of contraction amplitude (ICA). Positive remodeling (PR) was defined as an increase in LV end-diastolic global volume with >15% compared with baseline.

Results: Patients with positive remodeling (PR) presented at baseline a significantly lower ejection fraction (44.75% versus 49.95%, $p = 0.009$), associated with a higher end-systolic volume (80.34 ml vs. 70.63 ml, $p = 0.02$) and lower values for index of contraction amplitude — ICA (3.05 vs. 3.53, $p = 0.01$) and for regional index of contraction amplitude — RICA (1.38 vs. 2.78, $p < 0.0001$), in comparison with the patients who did not experience ventricular remodeling. RICA achieved the best statistical significance for predicting the development of LV remodeling during the evolution of the disease. For RICA, the ROC curve using logistic analysis showed an area under the curve (AUC) of 0.88, highly significant ($p = 0.0001$).

Conclusions: Impairment of regional contractility is associated with development of LV remodeling to a more significant extent than the global impairment of ventricular contractility.

Keywords: remodeling, 3D echocardiography, acute myocardial infarction, ventricular dysfunction

CORRESPONDENCE

Szillamér Korodi

University of Medicine and Pharmacy of Tîrgu Mureș, Clinic of Cardiology
50 Gheorghe Marinescu St, Tîrgu Mureș, Romania

Tel/Fax: +40-265-211595

Email: cardiotgm@yahoo.com

INTRODUCTION

Loss of myocardial tissue following an acute myocardial infarction (AMI) is one of the triggers for deleterious ventricular remodeling and development of heart failure, the degree of ventricular remodeling being one of the most

important predictor for worse outcomes in the post-infarction period [1,2].

The amplitude of the left ventricular remodeling process following an acute myocardial infarction depends on many variables including infarct size, treatment administered in the acute phase or during the post-acute phase,

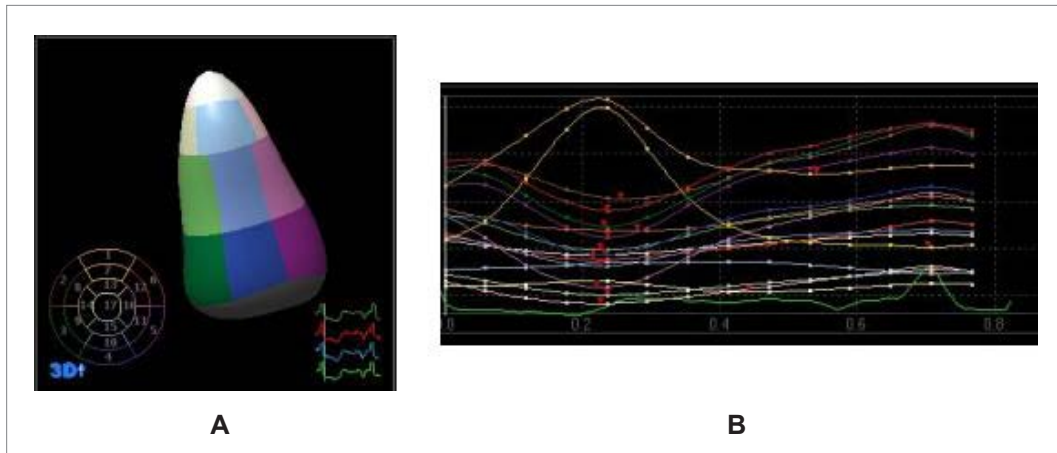


FIGURE 1. 3D echocardiography – segmentation of the left ventricle (a) and wall motion analysis (b) using contractility curves for each of the 17 segments

severity of co-existing lesions in other coronary arteries or the pre-existing left ventricular dysfunction and dilatation [3,4,5]. Another powerful stimulus for the development of ventricular remodeling is wall stress, a direct determinant of oxygen consumption. It has been proved that the stress concentration around an infarcted region depends more on the inotropic status of the non-infarcted border zone than on other parameters like infarct size [6].

The assessment of regional contractility is nowadays possible due to the new echocardiographic techniques which allow the precise quantification of wall motion based on the semi-automated determination of endocardial systolic excursion or wall thickening. Many limitations of 2D echocardiography (such as the high degree of interobserver variability or the lack of feasibility of Simpson technique, based on a geometrical assumption, in patients with remodeled ventricles) have been eliminated by the new 3D echocardiographic techniques, that provide a more objective and reliable basis for evaluation of ventricular volumes and regional wall motion, using quantitative assessment of volume and contractility for all ventricular segments during the cardiac cycle [7,8].

In this study we aimed to demonstrate the role of regional contractility evaluated with 3D echocardiography immediately after infarction, in the area surrounding the infarcted myocardium, in predicting development and progression of left ventricular remodeling following a revascularized myocardial infarction.

MATERIAL AND METHODS

PATIENTS

In total, 48 subjects with acute myocardial infarction who

underwent primary PCI within the first 12 hours from the onset of symptoms followed by optimum medical therapy (ACE inhibitors, beta blockers, aspirin, clopidogrel, statins) were enrolled in the study.

The demographic data, history and risk factors (age, gender, smoking status, presence of diabetes, hyperlipidemia, obesity and hypertension) were recorded for every patient.

3D ECHOCARDIOGRAPHIC ANALYSIS

All echocardiographic examinations were carried out at the baseline (day 2 ± 3 postinfarction) and during follow-up at 3 months postinfarction, using a Philips Sonos 7500 equipment. All acquired images were transferred to the QLab workstation for data processing, measurements and interpretation.

3D echocardiographic analysis started with delineation of the endocardial border followed by definition of ventricular segments. Based on recommendations by the American Heart Association, the left ventricle was divided into 17 segments. Therefore, in the 48 patients, 816 ventricular segments were analyzed and for each segment a contractility curve was obtained (Figure 1). For each segment the following parameters were determined: maximum contraction amplitude (endocardial excursion), maximum and minimum volume during the cardiac cycle and segmental ejection fraction. After summation of these data from all the 17 segments, we obtained the 3D-determined ejection fraction, global left ventricular end-diastolic and end-systolic volume.

Remodeling was assessed by measuring serial changes in global LV volume using 3D echocardiography at baseline and after 3 months follow-up.

TABLE 1. Comparison of 3D echo characteristics at baseline in patients with PR versus non-PR

	Group 1 – positive remodeling	Group 2 – no remodeling	p value
LV end-diastolic volume (ml)			0.5
Mean \pm SD	146.34 \pm 28.92	140.82 \pm 20.20	
95% confidence interval	134.66–158.03	131.86–149.78	
LV end-systolic volume (ml)			0.02
Mean \pm SD	80.34 \pm 14.58	70.63 \pm 13.32	
95% confidence interval	74.45–86.23	64.72–76.54	
Ejection fraction (%)			0.009
Mean \pm SD	44.75 \pm 4.3	49.95 \pm 5.43	
95% confidence interval	43.01–46.49	47.54–52.36	
ICA			0.01
Mean \pm SD	3.05 \pm 0.60	3.53 \pm 0.47	
95% confidence interval	2.80–3.30	3.32–3.74	
RICA			<0.0001
Mean \pm SD	1.38 \pm 0.45	2.78 \pm 0.88	
95% confidence interval	1.20–1.57	2.39–3.17	

DEFINITIONS

Index of contraction amplitude (ICA) was defined as the sum of maximum contraction amplitude for all segments divided by the number of segments.

Regional index of contraction amplitude (RICA) was defined as the sum of maximum contraction amplitude for those segments irrigated by the infarct-related artery divided by the number of these segments.

Positive remodeling (PR) was defined as an increase in LV end-diastolic global volume with >15% compared with baseline.

We followed the correlation between these 3D-echo derived parameters and the extent of remodeling process following myocardial infarction, which was assessed by measuring serial changes in global LV volume using 3D echocardiography at baseline and after 3 months of follow-up.

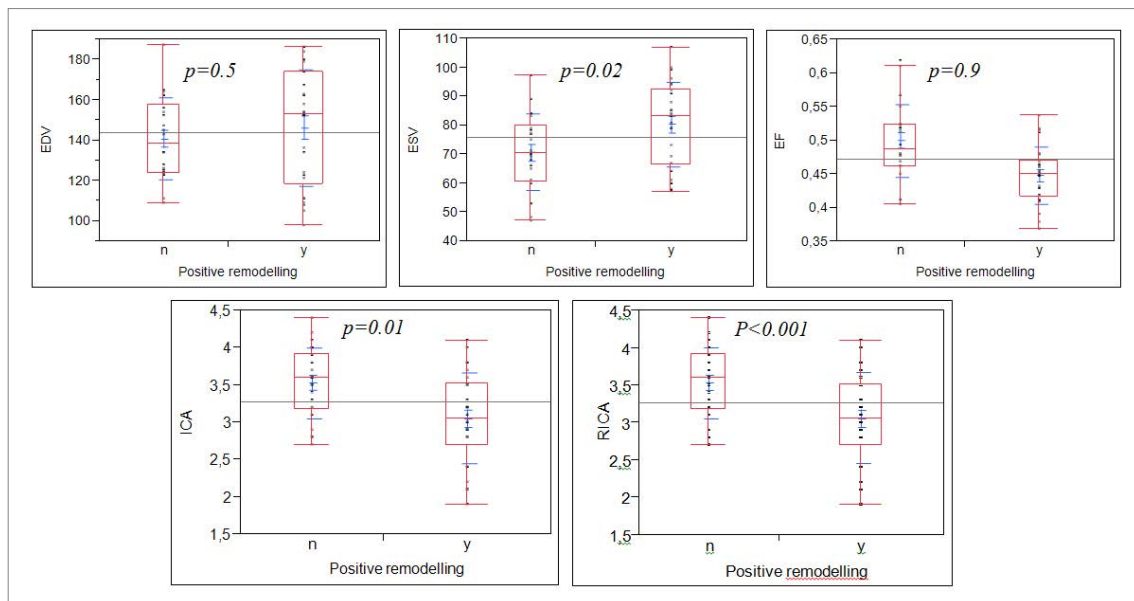
**FIGURE 2.** 3D echocardiographic characteristics at baseline in the PR vs. non-PR group

TABLE 2. Sensitivity, specificity and predictive values for parameters expressing ventricular function

	AUC	Cut-off value	Specificity (%)	Sensitivity (%)	PPV (%)	NPV (%)
RICA	0.88	1.80	26.00	92.00	90.00	79.31
ICA	0.71	3.20	73.00	65.00	73.91	64.00
FE	0.78	46%	87.00	61.00	84.21	65.52
VED	0.55	167.00	95.50	30.00	88.89	53.85
VES	0.68	79.00	78.00	65.00	73.91	64.00

STATISTICAL ANALYSIS

Statistical analysis was performed using the JMP 10 statistical software (SAS Institute Inc., Cary, North Carolina). We used Fisher's exact test (or Student's t-test for age) for comparing the baseline characteristics of patients between the PR and non-PR population. Continuous values are expressed as the mean and standard deviation, and statistical significance was determined using the Mann-Whitney test. Categorical variables are expressed as percentages. Statistical significance was considered for a p value <0.05, and all p values were 2-sided. For those variables with p<0.05, we performed logistic regression analysis to test their reliability in predicting the development of ventricular remodeling.

RESULTS

Twenty-seven patients experienced positive remodeling (PR group) following the infarction and 21 patients showed no signs of remodeling (non-PR group).

The clinical baseline characteristics of the study population showed no significant differences between the PR and non-PR group in respect to age (p = 0.5), gender (p = 0.2), the presence of diabetes (p = 0.7), hypertension (p = 0.7), hyperlipidemia (p = 0.4), obesity (p = 0.4), smoking status (p = 0.2) or comorbidities (p = 0.3), as presented in Table 1.

3D ECHO ANALYSIS OF GLOBAL AND REGIONAL CONTRACTILITY AT BASELINE

The 3D echo analysis of left ventricular global and regional contractility demonstrated that patients who developed postinfarction LV remodeling tend to have at lower ejection fraction (44.75% vs. 49.95%, p = 0.009), larger end-systolic volumes (80.34 ml vs. 70.63 ml, p = 0.02), lower index of global contraction amplitude (3.05 vs. 3.53, p = 0.01), and lower index of regional contraction amplitude (1.38 vs. 2.78, p<0.0001) at baseline than patients who did not develop left ventricular remodeling (Figure 2).

However, the highest statistical significance to differentiate between the two groups was reached for the index of regional contraction amplitude (Table 2).

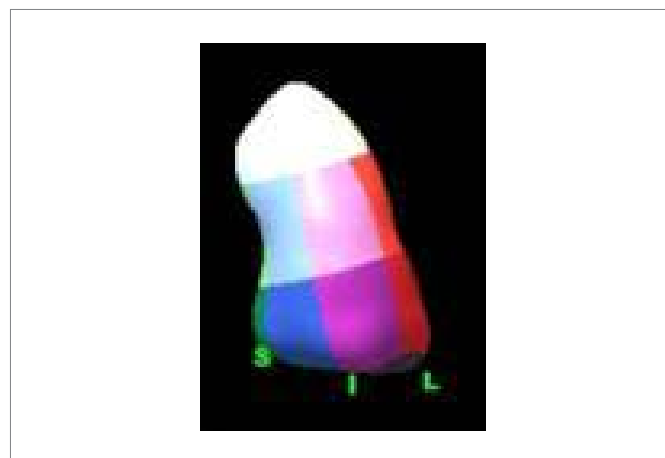
3D ECHO ANALYSIS OF LV REMODELING

A significant proportion of patients developed positive remodeling despite successful primary PCI. Remodeled ventricles were assessed by 3D echo, which revealed dilatation of the ventricular cavity in the area of the infarction (Figure 3).

Linear regression analysis of 3D echocardiography-derived parameters in correlation to the extent of remodeling at 3 months postinfarction showed that the amplitude of LV remodeling presented the highest correlation with the RICA, parameter expressing the regional contractility in the border zone of the infarction (Figure 4).

3D ECHO BASED PREDICTORS OF LV REMODELING

Logistic analysis based on receiver-operator characteristics (ROC) curves of the 3D echo derived parameters that signif-

**FIGURE 3.** Remodeled left ventricle following an AMI — 3D echo analysis indicating a pronounced dilatation in the apical area

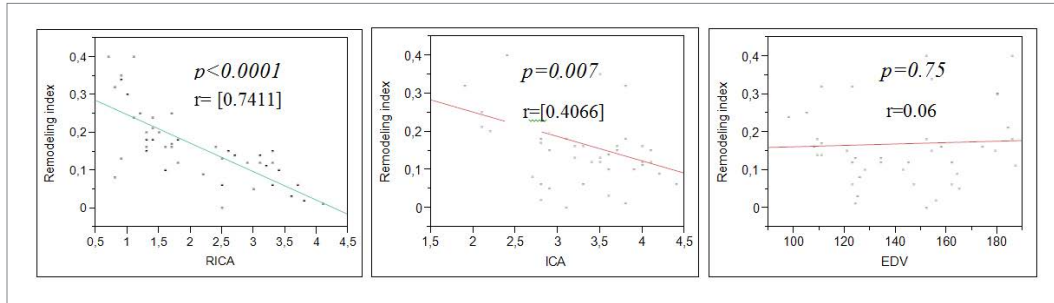


FIGURE 4. Correlation between remodeling index and 3D echo derived parameters of ventricular contraction and volume

icantly correlated with LV remodeling demonstrated that RICA was a good indicator for predicting the development of LV remodeling (area under the curve 0.88) (Figure 5).

A cut-off point of 1.8 regional index of contraction amplitude presented a high sensitivity (92%) and a positive predictive value of 90% in predicting development of LV remodeling in postinfarction period.

The accuracy of RICA in predicting LV remodeling was highly superior to the other parameters studied (AUC = 71 for ICA, 78 for EF, 55 for EDV, 68 for ESV). However, the specificity of this parameter for prediction of ventricular remodeling was only 26% (Table 2).

DISCUSSIONS

Successful revascularization of acute myocardial infarction should restore the function of damaged myocardium

when performed within the recommended timeframe. This restoration of circulation should prevent the development of ventricular remodeling, process with a powerful negative impact on the evolution of patients [9,10]. However, it is not clear in this moment what subset of patients is more prone to respond to this therapy. Based on the current knowledge a clear distinction between future "responders" or "non-responders" to revascularisation is not possible.

In this study we demonstrated that there is a strong correlation between alterations in regional contractility of the border zone areas adjacent to infarction, immediately after infarction, and the development of left ventricular remodeling. In our experience, the impairment of regional contractility was associated with the development of LV remodeling to a more significant extent than the global impairment of ventricular contractility.

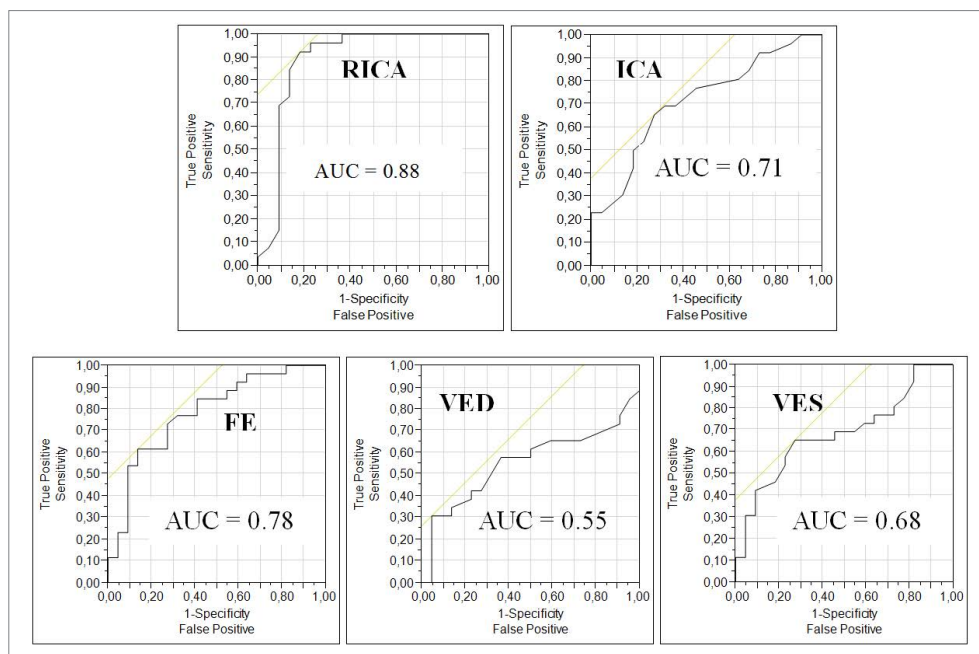


FIGURE 5. Linear regression analysis for echo based predictors of LV remodeling

Contractility in the border zone adjacent to myocardial infarction depends on many parameters, including the anatomy of coronary circulation, microcirculation, collaterals, and the degree of ischaemia in this territory [11]. All these contributors to regional contractility present various degrees of alterations or changes during the acute phase of myocardial infarction [12,13]. Therefore, in the setting of an acute coronary event, we should evaluate not only the size of the injury, but also the condition of the border zone as a major contributor to the ventricular function, either regional or global.

Even though the role of regional contractility in predicting future cardiac events after an acute coronary event has been recognized recently, no study evaluated so far the role of the changes in regional contractility on initiation and development of ventricular remodeling. In this study, 3D echocardiography quantification of regional wall motion identified new parameters useful for the prediction of development of left ventricular remodeling in patients with acute myocardial infarction treated by primary PCI. The index of regional contraction amplitude is a new parameter derived by 3D echocardiography, easy to determine, which provides an objective basis for the assessment of absolute regional contractility.

A low index of regional myocardial contraction in the area of the infarction, despite a successful repermeabilisation of the occluded coronary artery, had the strongest association with the presence and extent of the LV remodeling process in our study, showing a superior correlation compared with classical parameters like ventricular volumes or ejection fraction at baseline. This observation opens new perspectives regarding the need for more complete revascularization in acute myocardial infarction, as the revascularization of only infarct related artery, leaving in place a coronary artery stenosis in another, non-infarcted neighbor vessel, could lead to the decrease of regional contractility and may therefore contribute to the initiation or augmentation of the remodeling process.

Having demonstrated that regional contractility plays a major role in the initiation and perpetuation of the ventricular remodeling process, another open question raised by these results is whether this index of regional contraction could be used to predict the regression of remodeling following reopening of chronic total occlusions. However, a more complex approach would be necessary in this case, as the reversion of remodeling and regional contractility depend also on the preservation of myocardial viability.

CONCLUSIONS

In conclusion, using a 3D based objective assessment of ventricular volumes and quantification of regional wall motion, our study showed that impairment of regional contractility in the border area of the infarction was associated with development of LV remodeling to a more significant extent than the ventricular volumes or the global impairment of ventricular contractility. This underlines the role of regional contractility immediately after the infarction in predicting future evolution of these patients.

REFERENCES

1. Wenk JF, Klepach D, Lee LC, et al. First evidence of depressed contractility in the border zone of a human myocardial infarction. *Ann Thorac Surg.* 2012;93:1188-1193.
2. Lipiecki J, Durel N, Ernande L, Monzy S, Muliez A, Ponsonnaille J. Different patterns of left ventricular enlargement and long-term prognosis after reperfused acute myocardial infarction. *Arch Cardiovasc Dis.* 2009;102:599-605.
3. Ghanem A, Troatz C, Elhafi N, et al. Quantitation of myocardial borderzone using reconstructive 3-D echocardiography after chronic infarction in rats: incremental value of low-dose dobutamine. *Ultrasound Med Biol.* 2008;34:559-566.
4. Barletta G, Antoniucci D, Buonamici P, Toso A, Del Bene R, Fantini F. Left ventricular shape and function in primary coronary angioplasty. *Int J Cardiol.* 2008;125:364-375.
5. Carluccio E, Biagioli P, Alunni G, et al. Patients with hibernating myocardium show altered left ventricular volumes and shape, which revert after revascularization: evidence that dyssynergy might directly induce cardiac remodeling. *J Am Coll Cardiol.* 2006;47:969-977.
6. Silva JC, Rochitte CE, Júnior JS, et al. Late coronary artery recanalization effects on left ventricular remodelling and contractility by magnetic resonance imaging. *Eur Heart J.* 2005;26:36-43.
7. Danchin N, Angioi M, Marie PY, et al. Effect of late revascularization of the responsible artery after infarction on left ventricular function and remodeling. *Arch Mal Coeur Vaiss.* 1997;90:47-51.
8. Sutton MJ, Sharpe N. Left Ventricular Remodeling After Myocardial Infarction: Pathophysiology and Therapy. *Circulation.* 2000;101:2981-2988.
9. Bolognese L, Neskovic AN, Parodi G, et al. Left ventricular remodeling after primary coronary angioplasty: patterns of left ventricular dilation and long-term prognostic implications. *Circulation.* 2002;106:2351-2357.
10. Nijland F, Kamp O, Verhorst PM, de Voogt WG, Bosch HG, Visser CA. Myocardial viability: impact on left ventricular dilatation after acute myocardial infarction. *Heart.* 2002; 87:17-22.
11. Jenkins C, Bricknell K, Hanekom L, Marwick TH. Reproducibility and accuracy of echocardiographic measurements of left ventricular parameters using real-time threedimensional echocardiography. *J Am Coll Cardiol.* 2004;44:878-886.

12. Mannaerts H, van der Heide JA, Kamp O, Stoel MG, Twisk J, Visser CA. Early identification of left ventricular remodelling after myocardial infarction, assessed by transthoracic 3D echocardiography. *European Heart Journal*. 2004;25:680-687.
13. Udelson JE. The Occluded Artery Trial (OAT) Viability Ancillary Study (OATNUC): Influence of Infarct Zone Viability on Left Ventricular Remodeling After Percutaneous Coronary Intervention vs. Optimal Medical Therapy Alone. *Am Heart J*. 2011;161:611-621.