

RECURRENT MULTI-ORGAN CYSTIC ECHINOCOCCOSIS

Adriana Habor^{1,2}, Noémi Ecaterina Sidlovszky², Edina Török², Iunius Simu^{1,3},
Monica Copotoiu^{1,4}, Larisa Mureșan²

¹Târgu-Mureș University of Medicine and Pharmacy

²County Emergency Hospital in Târgu-Mureș, Internal Medicine Clinic 1

³County Emergency Hospital in Târgu-Mureș, Rheumatology Clinic,

⁴County Emergency Hospital in Târgu-Mureș, Radiology Clinic

Mail address:

Adriana Habor, Internal Medicine Clinic I, County Emergency Hospital in Târgu-Mureș, 50
Gheorghe Marinescu St., Târgu-Mureș.

e-mail: adrianahabor@yahoo.com

Abstract

Cystic echinococcosis is the disease that occupies, together with trichinosis, the first place in the zoonoses in Romania. We present the case of a 75-year-old urban patient known for echinococcosis, firstly operated for bone cysts in the right coxofemoral joint at the age of 24, then in 2000 she was operated for a lung hydatid cyst and in 2011 she underwent a surgery for recurrent bone echinococcosis.

After a 7-year lull, she returns due to the appearance of tumorous masses in the abdominal right flank, the right thigh, accompanied by pain in the right coxofemoral joint, functional impotence of the right lower limb, asthenia, anorexia. Based on clinical, immunological, imagistic examinations, the diagnosis of cystic echinococcosis localised in the liver, bone and muscle was established. Since the patient in association had ischaemic heart disease in NYHA III (New York Heart Association) congestive heart failure, surgical treatment was delayed and preoperative treatment with Albendazole 10-15mg / kg/day was started. Initially we will apply a conservative treatment, laparoscopic drainage and aspiration of the contents, saline instillation and aspiration.

Keywords: cystic echinococcosis, hydatid cyst, hydatidosis.

Rezumat

Echinococoza chistică este boala care ocupă, alături de trichineloză, primul loc în rândul zoonozelor din România. Prezentăm cazul unei paciente de 75 de ani, din mediul urban, cunoscută cu echinococoză, operată prima dată pentru chisturi osoase la nivelul articulației coxo-femorale drepte la vârsta de 24 de ani, apoi în anul 2000 a fost operată pentru chist hidatic pulmonar, iar în anul 2011 se reintervine chirurgical pentru recidiva echinococozelor osoase.



INTERNAL MEDICINE

Clinical cases

După o perioadă de acalmie de 7 ani, revine pentru apariția unor mase tumorale în flancul drept abdominal, coapsa dreaptă, însoțite de dureri la nivelul articulației coxo-femorale drepte, impotența funcțională a membrului inferior drept, astenie, inapetență. Pe baza examinărilor clinice, imunologice, imagistice s-a pus diagnosticul de echinococoză chistică cu localizare hepatică, osoasă și musculară. Deoarece pacienta asocia o boala cardiacă ischemică în stadiul de insuficiență cardiacă congestivă NYHA III (New York Heart Association), tratamentul chirurgical a fost temporizat și s-a început tratament medicamentos preoperator cu albendazol, 10-15mg/kg corp/zi. Se va aplica la început un tratament conservator, laparoscopic de drenaj și aspirarea conținutului, cu instilare de soluție salină și reaspirare.

Cuvinte cheie: echinococoză chistică, chist hidatic, hidatidoză.

Introduction

Echinococcus granulosus (EG) is a broad parasite worm (2-7 mm) of the cestoda class^(1,2,3). The adult parasite develops only in the definitive host, such as the dog and other representatives of the canine family (wolf, jackal, hyena etc.) and the intermediate host for the parasite are the domestic animals (sheep, goats, large horned cattle, pigs, camels, some rodents) and the man^(4,5,6). The definite hosts eliminate the eggs in the faeces. By ingesting the eggs forming a primary hydatidosis localised in various places: liver, lungs, heart, brain, bones, muscles, urinary tract, mediastinum, spleen, etc. The liver and the lungs are the most commonly infected organs. Another way of

producing hydatidosis is breaking a primary hydatid cyst in the intermediate host body to release the protoscoleces, which give rise to new hydatides, thus producing local secondary echinococcosis or if disseminates away from the primary focus - secondary systemic echinococcosis^(2,5). The pace of development of the hydatid cyst is very different, ranging from host and parasite tissue, being conditioned by tolerance of the body in which it is located. Once formed, the hydatid cyst which initially, is univesicular, in a few months it becomes fertile vesicle, forming proligerous vesicles with protoscoleces. The cuticle is then thickened, the cyst cavity increases, and after several years, thanks to compression of the cyst on the adjacent tissues, blood flow diminishes,

the cuticle separates from the adventitia, producing degeneration of germinative membrane. Gradually, the hydatid fluid is muddied and becomes a gelatinous caseous mass. In time, hydatid can die. But sometimes the hydatid can infect and turn into an abscess. Small cysts after death are calcified.

The diagnosis of cystic echinococcosis is based on clinical data and confirmed through immunological tests (ELISA) and/or by imaging (ultrasound-US, Computer Tomography-CT, x-ray, brain magnetic resonance - MRI), biopsy^(3,7,8,9).

Case presentation

We present the case of a 75-year-old urban patient F.I. known for echinococcosis since the age of 24, when she underwent a first surgery for bone cysts in the right coxofemoral joint. Then she underwent a treatment after and before the surgery with mitesol (period of treatment cannot be specified). In the year 2000 a lung hydatid cyst was discovered, a surgery was performed and in 2011 she underwent a cysts resection for recurrent bone echinococcosis.

After a lull of seven years, the patient finds within a period of 2-3 months a growth in volume of the right thigh, the emergence of tumour formations in the right abdominal flank, pain at mobilisation of right coxofemoral joint followed by functional impotence of the right lower limb, asthenia, anorexia. The patient has chronic ischaemic heart disease, essential hypertension, presented several overall cardiac decompensation episodes in recent years. She undergoes chronic treatment with conversion enzyme inhibitors, diuretics, cardiotonic agents.

The physical examination of the patient finds -dyspnoea with orthopnea, blood pressure -160/90mmHg, 90 bpm, extrasystolic arrhythmia; liver with lower edge 2 cm below the ribs, increased consistency; presence of the tumour masses in the right flank (8/ 4 cm), elastic consistency, increased diameter of right thigh, compared to the left thigh, palpable masses with different consistencies from elastic to fluctuant at this level, intense pain when mobilising the right coxofemoral joint, antalgic position, bilateral calf oedemas.

Laboratory tests- Haemoglobin - 7.10g/dl, Haematocrit - 27.2%, Leukocyte - $5.13 \times 10^3/\text{ul}$, Platelets - $200.00 \times 10^3/\text{ul}$, Syderemia - 4.41mcmol/l; Differential white cell count - severe hypochromia, poikilocytosis, microcytes, ovalocytes, rare schizocytes, platelets present; segmented neutrophils-70%; lymphocytes - 18%, monocytes - 9%, eosinophils 2%, basophils 1%. TGO- 31.2 U/l, TGP-18.5 U/l, GPT-169 U/l, LDH-211 U/l, glycemia -106mg/dl, Cholesterol - 224mg/dl, Triglycerides - 155mg/dl.

ELISA test - IgG antibodies against Echinococcus granulosus - 4.849 Index (positive over 1.1-index of the sample) reported a cross-reaction with Tenia Solium. EKG-irregular rhythm, ventricular extrasystoles below 4 / min, left ventricular hypertrophy, diffuse repolarization disorders.

Imaging examinations:

Computed tomography - thorax, abdomen, pelvis - native and after i.v. contrast dye - Liver with shape and dimensions within the normal limits; oval cystic formations of 12 and 13 mm, adjacent to the visceral face of the liver, near the gallbladder bed; minimal intrahepatic bile duct dilation; intraosseous masses of non-



INTERNAL MEDICINE

Clinical cases

iodophilic fluid and parafluid structure with fine calcified septa, located on the right ala of sacrum, right acetabular roof sclerosis, right femoral head and metaphysis, upper pubic ramus, right ischial tuberosity, cortical disruption and destruction, and similar lesion of 30 mm in size discontinuing the right femoral diaphysis; multiple cystic formations with septa and fine calcifications, without iodophilia, which are located in the right lumbar square, right gluteal muscles, most of the muscles of the right thigh having marked atrophy (figures 1-3).

Native CT scan of the brain - no heterodense lesions in the infra- and supratentorial region in the meaning of a recent ischaemic stroke, no cranial bone lesions

Ultrasound for soft parts of the right thigh - Multiple tumour formations, round-oval, with clearly defined edges, hypo- and hyperechogenic, with posterior enhancement at the rectus femoris, vastus lateralis and medialis level, with no Doppler signal. (Figures 4,5)

Surgery recommended for surgical intervention timing up to the compensation of the cardiac disease, and at least one month of anthelmintic treatment before the surgery. A surgical treatment is considered through percutaneous drainage of the cysts

under ultrasound or CT supervision and/or extension of procedures towards open surgery.

Positive diagnosis. Taking into account the previous pathological history of the patient, clinical, laboratory, imaging findings, we considered that it is a recurrent multi-organ cystic echinococcosis (liver, muscle, bones); iron deficiency anaemia, average form; NYHA II congestive heart failure, chronic ischaemic heart disease, essential hypertension of the third degree, high **risk**.

Considering the risks and benefits for the patient we began the anthelmintic treatment with Albendazol 10-15 mg/kg/day (no more than 800 mg/day in two doses), 28 days before the surgery, and where surgery can't be done because of the risk to which the patient is exposed, it can prolong the medication treatment, for a total of 3 therapies with the span of 14 days. We associated the chronic cardiovascular disease treatment with antihypertensives, diuretics, cardiotonic agents.

The differential diagnosis contemplated the liver abscess, malignant (or benign) tumours at liver, colon, kidney, right thigh haematoma.

The prognosis remains reserved, however, because the patient is elderly, has cardiovascular diseases with a risk for surgery and echinococcosis has multiple locations, with possibility of evolution

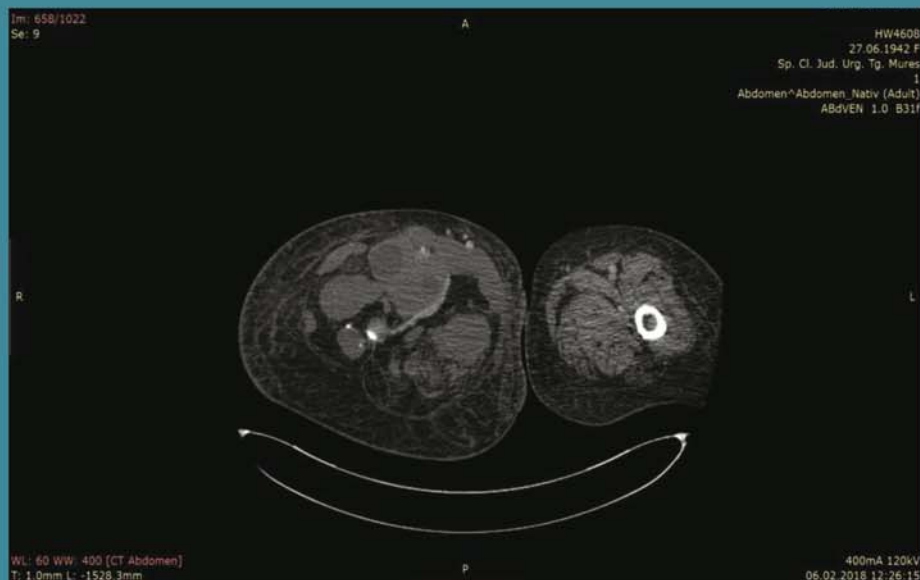


Figure no. 1. CT scan - cystic formation with daughter vesicles, fatty degeneration in the femoral right muscle (axial view)

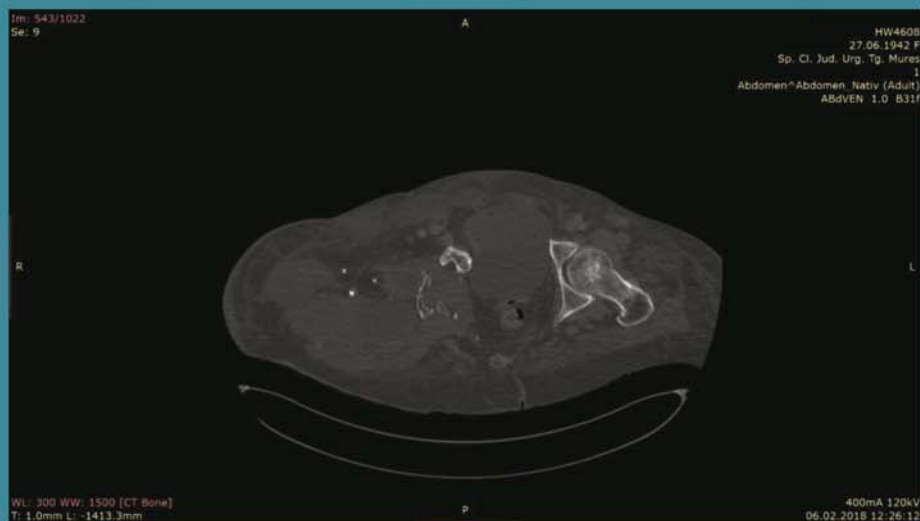


Figure no. 2. Pelvis CT scan -bone destruction carried out by cystic formations (axial views)

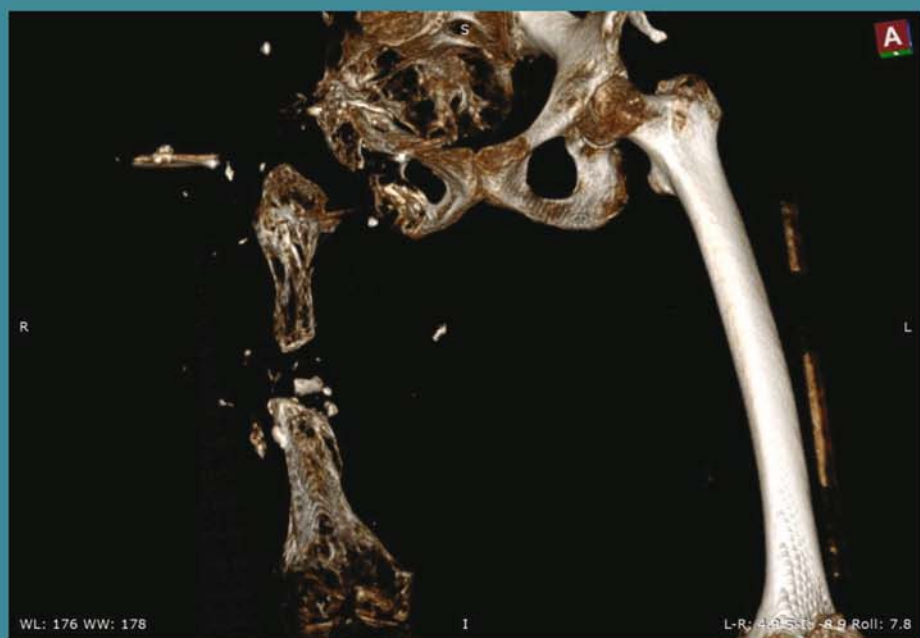


Figure no. 3. CT scan - Osteopenia and lytic bone lesions, ilium, ischium, femur (previous image)



INTERNAL MEDICINE

Clinical cases

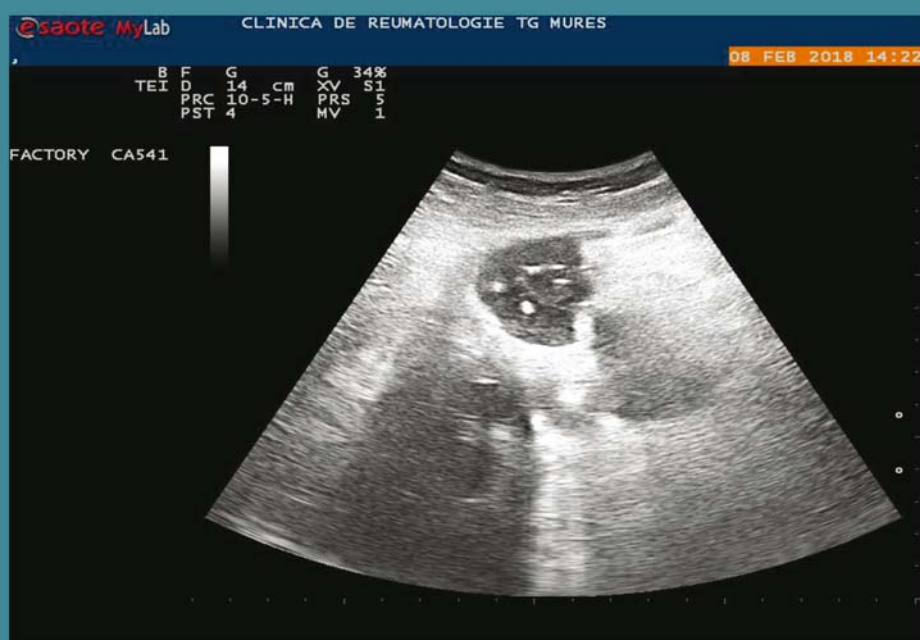

Figure no. 4.
Ultrasound for soft parts, right thigh
Multiple tumour formations, round-oval, with clearly defined edges, hypo- and hyperechogenic, with posterior enhancement at the rectus femoris level, with no Doppler signal

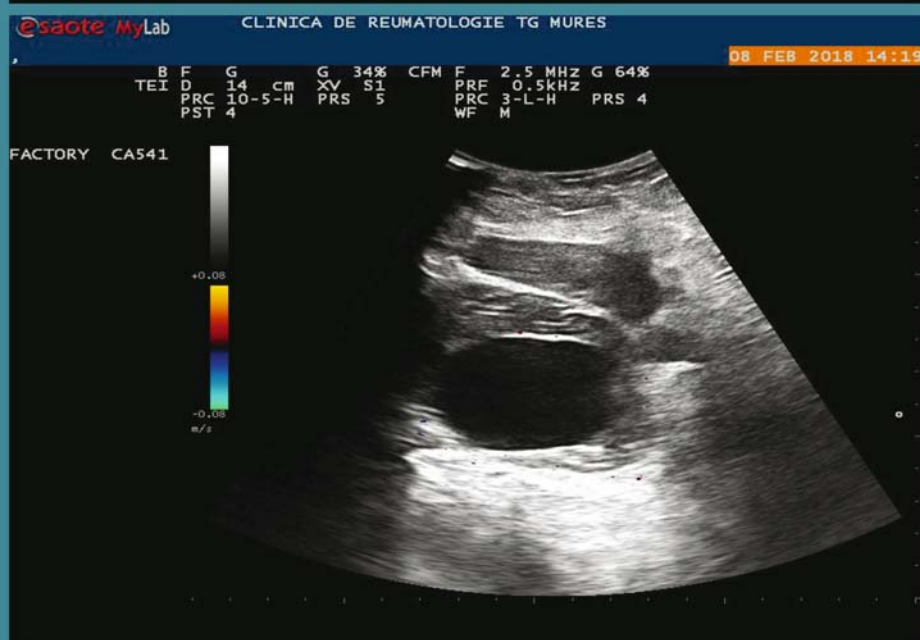

Figure no. 5.
Ultrasound for soft parts, right thigh
Multiple tumour formations, round-oval, with clearly defined edges, hypo- and hyperechogenic, with posterior enhancement at the vastus medialis level, with no Doppler signal

towards rupture and anaphylactic shock, suppuration, bone erosion, pathological fractures.

Discussions

The data from the literature shows that in about 65% of cases, *Echinococcus granulosus* forms cysts in the liver, about 23% in the lungs, the rest in the muscles (5%), bones (3%), kidneys (3%), human brain or spleen (1%)^(2,3,5). Because echinococcal cysts grow slowly, many people infected with this parasite, for a long time (perhaps even several years), do not complain of any symptoms⁽¹⁰⁾.

In some people, the first symptoms appear when the cyst reaches 5 cm in diameter, where there can be allergic reactions (especially when fluid fills the cysts). Symptoms can last for years. When the liver is damaged, the person can complain of abdominal pain, weight loss, jaundice. The disease reaching the lungs can cause chest pain, dyspnoea and cough. Cysts from the bones or muscles may cause severe pain and even spontaneous fractures.

For the diagnosis of echinococcosis we need in addition to clinical data, imaging examinations and immunological tests^(11,12). The tests for the disease immunological diagnosis are based on detection of anti-*Echinococcus granulosus* antibodies in the patient's blood. In recent years, ELISA enzyme-linked immunosorbent assay technique and Western Blot (WB) test have been preferred, with numerous studies demonstrating that maximal sensitivity belongs to the ELISA test, and the specificity to the WB test^(13,14). The immunoblotting technique is a strong confirmation and serological differential diagnosis test between the two major relevant infections:

cystic echinococcosis and alveolar echinococcosis^(13,15,16).

The serological reactions also contribute to the follow-up of patients after surgery. If the cyst excision was complete, it initially causes a rise in antibody titer, followed by a gradual decline and their complete disappearance in 12-14 months^(17,18).

In case of recurrent infection, no significant increase in the level of antibodies is determined^(16,18). Imaging methods allow a correlation of ultrasound appearance with the evolution of the cyst and with its viability, which would mean a better approach to surgical indications versus medication⁽¹⁹⁾.

Although the optimal treatment for patients with active viable hydatid cysts is the surgery and progress in the field of surgery through the use of modern technologies is obvious, though surgical treatment of echinococcosis has some shortcomings^(20,21). There are post-surgical complications (4.6-23% of the cases) and high frequency of relapses (8.5-22%), according to the data from the literature. The hydatid cyst rupture and dissemination of hydatid fluid is highly regarded as the most serious surgical accident. It should not be forgotten that the cysts death can initiate necrosis with evolution towards the abscess.

As with our patient, the inoperable hydatid cysts can be treated by the so-called PAIR procedure (puncture, aspiration, instillation and reassertion) and/or medical treatment^(22,23,24). Benzimidazoles (albendazole or mebendazole) are administered at a dose of 400 mg twice a day for 28 days: in total 3 therapies with 14 days interval^(19,25,26). WBC counts and transaminases will be carefully checked. To reduce the risk of dissemination of cyst, antiparasitic treatment is administered before the surgery.



INTERNAL MEDICINE

Clinical cases

Conclusions

Echinococcus granulosus is the parasite determining cystic echinococcosis, the disease part of those parasitoses which have the most severe and varied implications in both pathology and public health issues. The bone location of hydatidosis, although much rarer than the hepatic and pulmonary one, is characterised by semisolid cysts invading the spinal cord cavity, slowly eroding the bone, leading to pathological fractures.

The written consent of the patient for the publication of personal data in scientific purpose was obtained.

Conflicts of interest: none.

Bibliography:

1. Eckert J, Deplazes P. Biological, epidemiological, and clinical aspects of echinococcosis, a zoonosis of increasing concern. *Clin Microbiol Rev.* 2004 Jan;17(1):107-35
2. Rădulescu S. Cestode. *Echinococcus granulosus*. În: Rădulescu S, editor. *Parazitologie Medicală*. Ed. All Educational; 2000. p. 282-295.
3. Mandal S, Mandal M. Human cystic echinococcosis: epidemiologic, zoonotic, clinical, diagnostic. *Asian and therapeutic aspects Pacific Journal of Tropical Medicine*, Volume 5, Issue 4, April 2012, pp.. 253-260
4. Mirbadie SR, Kamyaby H, Mohammadi MA, et al. Copro-PCR prevalence of *Echinococcus granulosus* infection in dogs in Kerman, south-eastern Iran. *Journal of Helminthology*, Volume 92, Issue 1, January 2018, pp 17-21
5. Moro P, Schantz PM. Echinococcosis: a review. *Int J Infect Dis.* 2009;13:125-133
6. Siracusano A, Delunardo F, Teggi A, Ortona E. Host-parasite relationship in cystic echinococcosis: an evolving story. *Clin Dev Immunol.* 2012;2012:639362.
7. Vasilevska V, Zafirovski G, Kirjas N, Janevska V, Samardziski M, Kostadinova-Kunovska S, et al. Imaging diagnosis of musculoskeletal hydatid disease. *Prilozi.* 2007;28(2):199-209.
8. Iacobiciu I, Sefanoiu V, Siko Barabasi S, et al. *Imunodiagnosticul in boala hidatica*. in *Epidemiologia echinococozei-hidatidozei*. ECHINO-NEWS Romania ed. 2005, pp. 75-88.
9. Solomon N, Zeyhle E, Subramanian K, Fields PJ, Romig T, Kern P, Carter JY, Wachira J, Mengiste A, Macpherson CNL. Cystic echinococcosis in Turkana, Kenya: 30 years of imaging in an endemic region. *Acta Tropica*, Volum 178, February 2018, <https://doi.org/10.1016/j.actatropica.2017.11.006>
10. Budke CM, Carabin H, Ndimubanzi PC, et al. A systematic review of the literature on cystic echinococcosis frequency worldwide and its associated clinical manifestations. *Am J Trop Med Hyg.* 2013; 88:1011-1027.
11. Reiter-Owona I, Grüner B, Frosch M, Hoerauf A, Kern P, Tappe D. Serological confirmatory testing of alveolar and cystic echinococcosis in clinical practice: results of a comparative study with commercialized and in-house assays. *Clin Lab.* 2009;55(1-2):41-8.
12. Conchedda M, Antonelli A, Caddori A, Gabriele F. A retrospective analysis of human cystic echinococcosis in Sardinia (Italy), an endemic Mediterranean region, from 2001 to 2005. *Parasitol Int.* 2010; 59:454-459.
13. Liance M, Janin V, Bresson-Hadni S, Vuitton DA, Houin R, Piarroux R. Immunodiagnosis of *Echinococcus* infections: confirmatory testing and species differentiation by a new commercial Western Blot. *J Clin Microbiol*, 2000, 38(10):3718-3721
14. Mourglia-Ettlin G, Miles S, Hernández A, Dematteis S. Antibody profiling in ultrasound normal individuals with positive serology for cystic echinococcosis. *Parasite Immunol.* 2016; 38:93-100.
15. Brehm K, Koziol U. On the importance of targeting parasite stem cells in anti-echinococcosis drug

development, *Parasite*. 2014;21:72.

16. Diaz A. Immunology of cystic echinococcosis (hydatid disease), *British Medical Bulletin*, Volume 124, Issue 1, 1 December 2017, pp. 121–133

17. Craig PS, Hegglin D, Lightowlers MW, Torgerson PR. Echinococcosis: Control and Prevention, *Advances in Parasitology*, Volume 98, 2017, Pages 55–158.

18. Siles-Lucas M, Casulli A, Conraths FJ, Müller N. Laboratory Diagnosis of *Echinococcus* spp. in Human Patients and Infected Animals, *Advances in Parasitology* Volume 96, 2017, pp. 159–257

19. Opatrny L, Prichard R, Snell L, Maclean JD. Death related to albendazole-induced pancytopenia: case report and review. *Am J Trop Med Hyg*. 2005;72(3):291–4.

20. Monteiro KM, Lorenzatto KR, de Lima JC, Dos Santos GB, Förster S, Paludo G.P, Carvalho PC, Brehm K, Ferreira HB. Comparative proteomics of hydatid fluids from two *Echinococcus multilocularis* isolates. *J Proteomics*. 2017 Jun 6;162:40–5

21. Marinova I, Spiliotis M, Wang J, Muhtarov M. et al. Molecular characterization of *Echinococcus granulosus* isolates from Bulgarian human cystic echinococcosis

patients. *Parasitology Research*, March 2017, Volume 116, Issue 3, March 2017, pp 1043–1054.

22. Merkle EM, Schulte M, Vogel J, Tomczak R, Rieber A, Kern P, Goerich J, et al. Musculoskeletal involvement in cystic echinococcosis: report of eight cases and review of the literature. *AJR Am J Roentgenol*. 1997;168(6):1531–4.

23. Alexiadis G, Lambropoulou M, Deftereos S, Papadopoulos N, Manavis J. Primary muscular hydatidosis. US, CT and MR findings. *Acta Radiol*. 2002; 43(4):428–30.

24. Marwah S, Subramanian P, Marwah N, Rattan KN, Karwasra RK. Infected primary intramuscular echinococcosis of thigh. *Indian J Pediatr*. 2005; 72(9):799–800.

25. López-Bernus A, Belhassen-García M, Alonso-Sardón M, et al. Surveillance of Human Echinococcosis in Castilla-Leon (Spain) between 2000–2012. *PLoS Negl Trop Dis*. 2015; 9:e0004154.

26. Rezaian GR, Aslani A. Endocardial hydatid cyst: a rare presentation of echinococcal infection. *Eur J Echocardiogr*. 2008;9(2):342–3.