

Research Note

***Ithyoclinostomum dimorphum* Diesing, 1850 (Digenea, Clinostomidae)
in *Hoplias malabaricus* (Erythrinidae) with the first report of infection of the eyes**

D. CHAGAS DE SOUZA¹, L. LIMA CORREA^{1,2*}, M. TAVARES-DIAS³

¹Programa de Pós-graduação em Biodiversidade (PPGBEES), Universidade Federal do Oeste do Pará. Avenue Mendonça Furtado, nº 2946, Fátima, CEP 68040-470, Santarém, PA, Brazil. Instituto de Ciências e Tecnologia das Águas - ICTA, Santarém, PA, Brazil. E-mail: darlisoncds@hotmail.com, *lincorre@gmail.com; ²Universidade Federal do Oeste do Pará - UFOPA, Avenue Mendonça Furtado, nº 2946, Fátima, CEP 68040-470, Santarém, PA, Brazil. Instituto de Ciências e Tecnologia das Águas - ICTA, Santarém, PA, Brazil; ³Embrapa Amapá, Highway Juscelino Kubitschek, Km 5, nº 2600, University, CEP 68903-419, Macapá, AP, Brazil, E-mail: marcos.tavares@embrapa.br

Article info

Received April 24, 2018
Accepted July 16, 2018

Summary

The present study investigated the occurrence of metacercariae of *Ithyoclinostomum dimorphum* in *Hoplias malabaricus* in the basin of the São Francisco River in the state of Minas Gerais (Brazil). Twenty-nine fish were examined in June 2012 during a survey of fish and parasitic fauna. Of the fish examined, 34.5 % had infected eyes, intestine and musculature, with a mean intensity of 1.1 and an abundance of 0.4 per fish. The prevalence in the intestine was 31.0 %, with mean intensity of 1.1 and mean abundance of 0.3. In the eyes, the prevalence was 3.4 %, with a mean intensity of 1.0 and mean abundance of 1.0. The metacercaria found in the right eyeball was lodged between the cornea and iris. The low parasitism did not affect the condition factor (Kn) of the parasitized fish. This was the first report of *I. dimorphum* in the eyes of *Hoplias malabaricus*, a secondary intermediate host for this endoparasite

Keywords: Brazil; condition factor; eye parasite; Trematoda

Introduction

Hoplias malabaricus Bloch, 1794 (Trahira) is widely distributed in South America (Costa *et al.*, 2015), and is abundant in several environments of the Amazon, São Francisco and Paraná hydrographic basins. The dispersion of this piscivorous fish is associated with its capacity to survive for long periods without feeding and to remain in environments with a low concentration of dissolved oxygen (Malabarba, 2006). This Erythrinidae is of considerable economic importance for commercial artisanal fishing in several regions of Brazil (Rodrigues *et al.*, 2017).

A total of 662 species of Trematoda have been found among South American fish, of which 266 species are registered in Brazil (Luque *et al.*, 2017). Among these are the Digenea *Ithyoclinostomum dimorphum* Diesing, 1850 (Clinostomidae), an endoparasite found during adulthood in the esophagus of birds as such as *Ardea co-*

coi, *Nycticorax* sp. and *Tigrisoma brasiliense*. Various species of fish, including *H. malabaricus*, and mollusks act as intermediate hosts (Dias *et al.*, 2003; Gallio *et al.*, 2007; Benigno *et al.*, 2014). This species of Clinostomidae is the largest worm in this family (Dias *et al.*, 2003), and metacercariae are commonly found in the musculature, gills, pericardium, external wall and esophagus of fish (Gallio *et al.*, 2007; Belei *et al.*, 2013; Benigno *et al.*, 2014). However, there has been no record of ocular infection of fish by this digenea until now. Thus, the objective of this study was to describe the occurrence of *I. dimorphum* in *H. malabaricus* and the first record of infection in the eyes of this host from a tributary of the São Francisco River basin (Brazil).

Materials and Methods

In June 2012, twenty-nine specimens of *H. malabaricus* (19 fema-

* – corresponding author

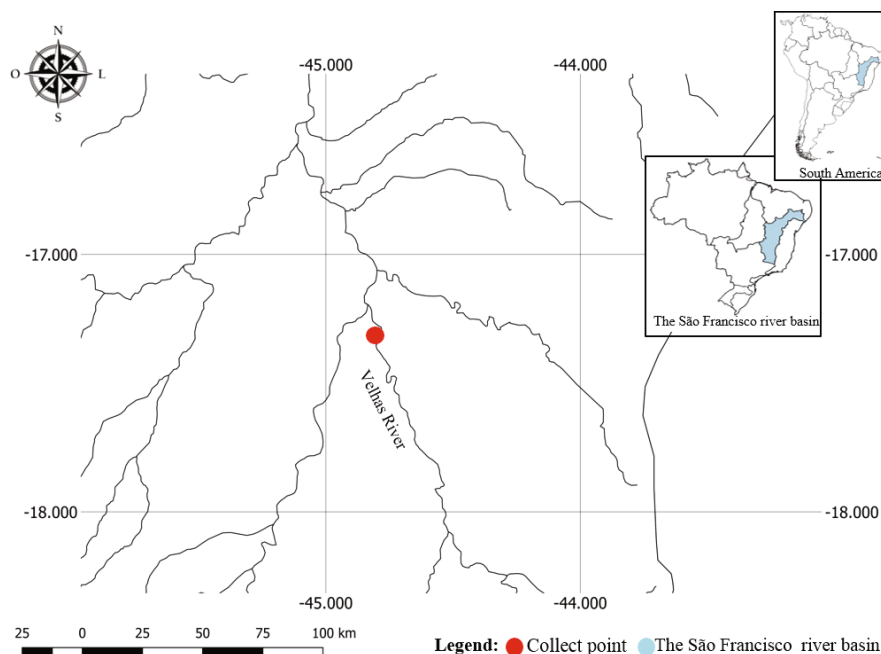


Fig. 1. Geographical location of the *Hoplias malabaricus* collection site in a tributary of the São Francisco River, Minas Gerais (Brazil).

les and 10 males) were captured in the upper part of the das Velhas River, a tributary of the São Francisco River, in the state of Minas Gerais, Brazil (44°49'11.20"W, 17°15'8.00"S) (Fig. 1) using gill nets of various mesh sizes. The fish were collected during a survey on the fish and parasitic fauna of the São Francisco River hydrographic basin by the Centro Nacional de Pesquisa e Conservação de Peixes Continentais (CEPTA). Following collection, all fish were weighed (g) and their standard length (SL, cm) was measured. They were then necropsied *in loco* to collect specimens of the Digenea parasites. All the parasites collected were quantified and stained with carmine acid of Langeron (Amato *et al.*, 1991) and identified in accordance with Travassos *et al.* (1969). The permanent slides of the parasites were assembled in Canadian balsam and used to determine the measurements of the reproductive structures in a stereomicroscope (Zeiss model STMI DV 4), with camera and ZEN software. The specimens of *H. malabaricus* were deposited in the fish collection of the Genetics Museum of the Universidade Estadual Paulista (Paulista State University) (UNESP), Botucatu, São Paulo. The ecological terms were those proposed by Bush *et al.* (1997). Specimens of *I. dimorphum* deposited on fixed glass slides were deposited at the "Adão José Cardoso" Zoology Museum, University of Campinas (UNICAMP), São Paulo, Brazil (N°. ZUEC PLA 155 - *I. dimorphum* in eyes; N°. ZUEC PLA 156 - *I. dimorphum* in intestine and N°. ZUEC PLA 157 - *I. dimorphum* in muscles).

The body weight (g) and total length (cm) data were used to calculate the relative condition factor (Kn) of the parasitized and non-parasitized fish, which was compared using the Mann-Whitney U-test (Zar, 2010). In addition, weight and length data were

used to calculate the length-to-weight ratio ($W = aL^b$) of parasitized and non-parasitic fish, after logarithmic transformation of length and weight, and later adjustment along two straight lines, thus obtaining $\ln y = \ln A + B \ln x$ (Le Cren, 1951).

Ethical Approval and/or Informed Consent

The study was carried out in accordance with the principles adopted by the Colégio Brasileiro de Experimento Animal (the Brazilian College of Animal Experimentation) (COBEA). All the fish were collected pursuant to a collection authorization granted by IBAMA/ICMBio - N° 27447-1/2011.

Results

Of the twenty-nine specimens of *H. malabaricus* examined, the eyes (Fig. 2A and B), gut and muscles of 34.5 % (n=10) of the fish were infected by *I. dimorphum* (Fig. 2C), with a mean intensity of 1.1 and mean abundance of 0.4 per host. The prevalence in the intestine was 31.0 % (n=9), with mean intensity of 1.1 and mean abundance of 0.3 per host. In the eyes of the hosts, the prevalence was 3.4 % (n=1), with a mean intensity of 1.0 and a mean abundance of 1.0 per host.

In the right eyeball the metacercaria of *I. dimorphum* was lodged between the cornea and the iris, occupying an area of 0.4 cm², corresponding to 78.0 % of the total organ (Fig. 2C and D).

In *H. malabaricus* analyzed, we found only one *I. dimorphum* infected one eye. Only this *I. dimorphum* we will describe:

Ithyoclinostominae Yamaguti, 1958

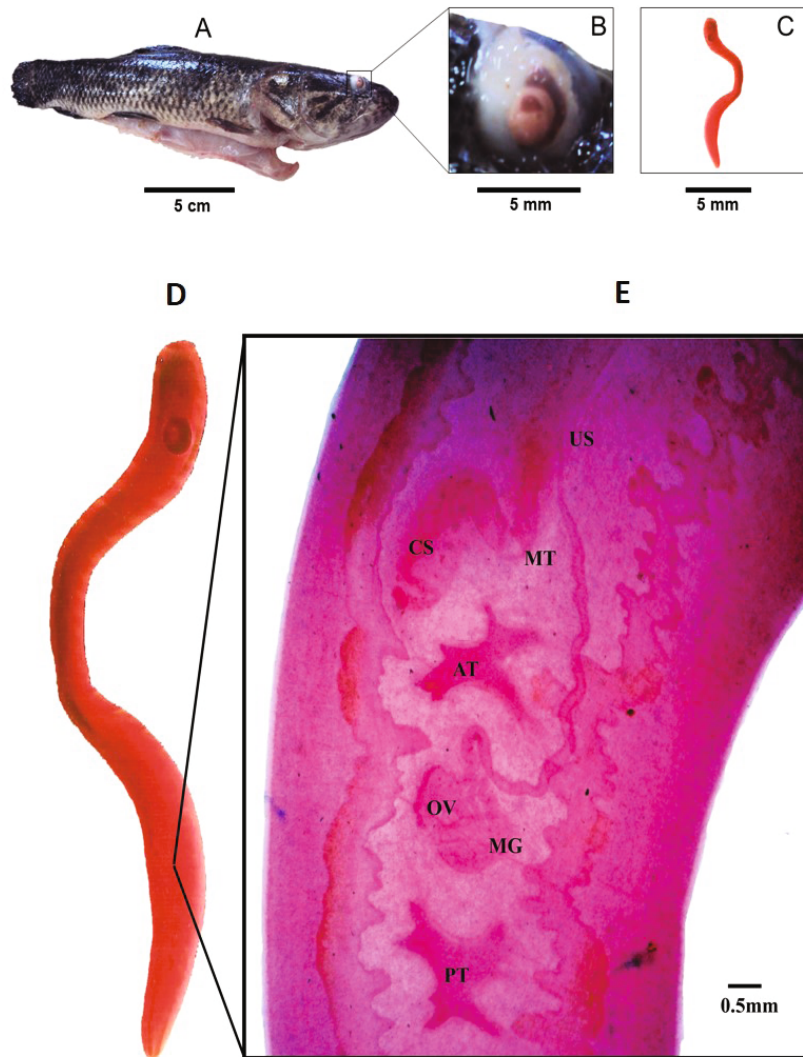


Fig. 2. *Hoplias malabaricus* from a tributary of the São Francisco River, Minas Gerais, Brazil (A). Eye infection of the right eye caused by *Ithyoclinostomum dimorphum* (B). *Ithyoclinostomum dimorphum* stained with Langeron acid carmine (C). *Ithyoclinostomum dimorphum* from *Hoplias malabaricus* (D). Internal organs of the reproductive system (E). US: Uterine sac, MT: Metaterm, CS: Cirrus sac, AT: Anterior Testis, PT: Posterior Testis, OV: Ovary, MG : Mehli's Gland.

Ithyoclinostomum Witenberg, 1925

Ithyoclinostomum dimorphum (Diesing, 1850) Witenberg, 1926 (Fig. 3a, b)

General description

Body elongated, flattened (Fig. 3a). Body surface with rounded sensory papillae, furrows and rings forming superficial annulations, dorsal and ventral. Oral sucker, terminal, triangular aperture, surrounded by an expansion of the body wall such as collar-like and radial furrows in the surface (Fig. 3a); pharynx present. Caeca simple, long, without lateral branches or diverticula. Ventral sucker, near anterior extremity of body, close to oral sucker, subtriangular aperture (Figs. 3a). Testes lobed, medians, intercaecals, in the posterior half of body; cirrus-sac, destro anterolateral to anterior

testis, intercaecal, internal seminal vesicle coiled (Fig. 3a, b). Genital pore, ventral to cirrus-sac, slightly prominent, surrounded by tegumental rugosities and papillae (Fig. 3b). Ovary, intertesticular (Fig. 3a, b). Uterus, intercecal, originating from the Mehli's gland, ascending sinistral to anterior testis reaching uterine sac (Fig. 3a-b). Uterine sac elongated, median, intercaecal. Metaterm, ventro-lateral to cirrus-sac, converging in a genital atrium (Fig. 3b). Vitelline follicles, caecals, extending from hindbody to the end of the first third of body, below cecal bifurcation, confluent on posterior end; vitelloduct anterior to ovary; considerable space free of internal organs between ventral sucker and anterior limit of vitellarium (Fig. 3a). Mehli's gland larger than ovary, median, between testis, latero-dorsal to ovary (Fig. 3a, b).

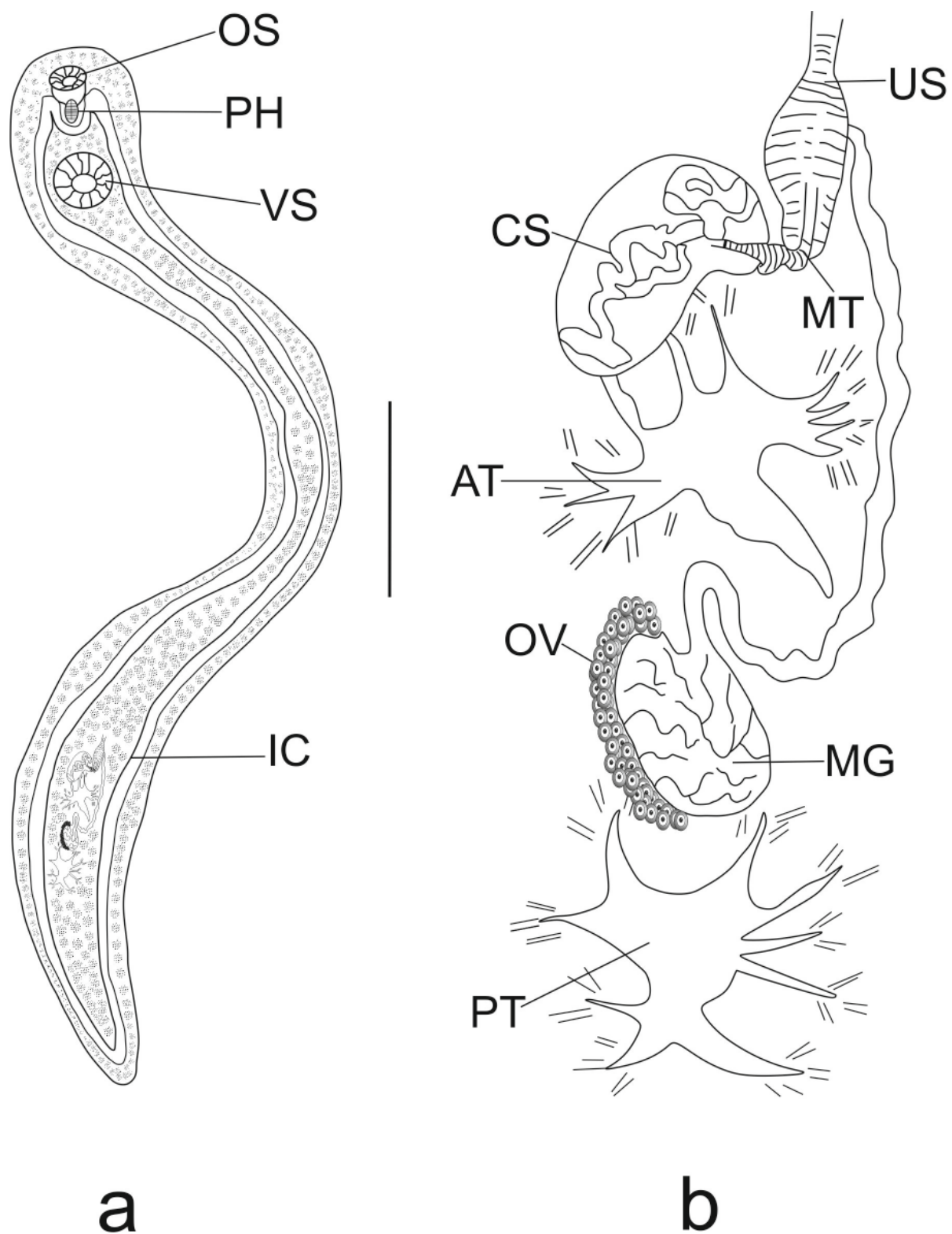


Fig. 3. Metacercaria of *Ithyoclinostomum dimorphum* from *Hoplias malabaricus* from a tributary of the São Francisco River, Minas Gerais, Brazil. a. Total, ventral view, oral sucker (OS), pharynx (PH), ventral sucker (VS) and intestinal cecum (IC). b. Detail of genital organs, anterior testis (AT), ovary (OV), Mehlis' gland (MG), uterine sac (US), metraterm (MT), cirrus-sac (CS) and posterior testis (PT). Scale bars in a = 5.0 mm and b = 0.5 mm.

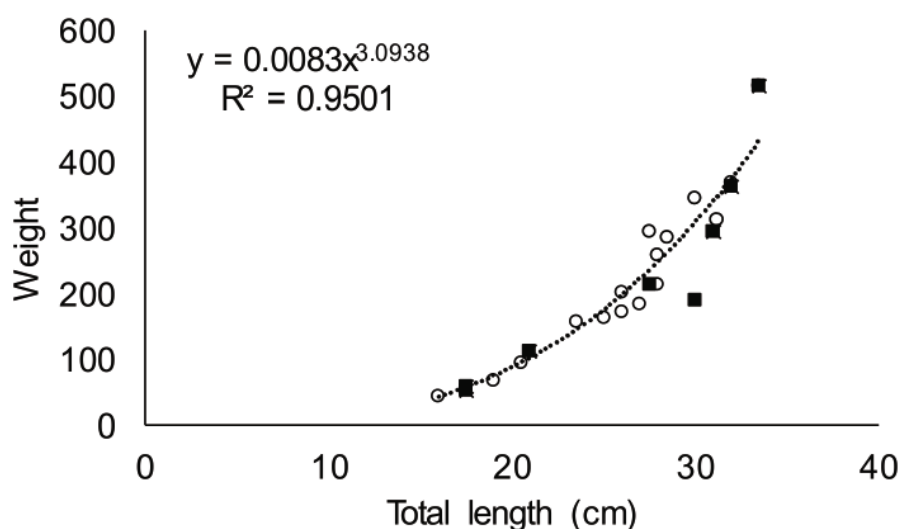


Fig. 4. Relationship between total length-weight of *Hoplias malabaricus* parasitized by *Ithyoclinostomum dimorphum* metacercariae (■) and non-parasitized (○) collected in a tributary of the São Francisco River, Minas Gerais (Brazil).

Measurements

Of one specimen from *H. malabaricus* in eye: Body 33.42 long, 3.01 maximum width. Oral sucker 0.62 long, 0.48 wide; Pharynx 0.48 long, 0.42 wide. Ventral sucker 1.34 long, 1.26 wide. Uterine sac 0.23 long, 0.18 wide. Anterior testicle 0.32 long, 0.48 wide. Posterior testicle 0.48 long, 0.63 wide. Ovary 0.30 long, 0.12 wide.

Taxonomic Summary

Hosts: *Hoplias malabaricus*.

Locality: São Francisco River in the state of Minas Gerais, Brazil.

Site of infection: Eye of *H. malabaricus*.

Numbers of collected specimens: 1 *I. dimorphum* from *H. malabaricus* in eye.

Table 1. Morphometry (mm) of reproductive structures of metacercariae of *Ithyoclinostomum dimorphum* of the intestine, muscles and right eye of *Hoplias malabaricus* from the tributary of the São Francisco River, Minas Gerais (Brazil).

Measured structures	Das Velhas River		Arari Lack, Pará*
	Cavity parasites (n = 4)	Eye parasite (n = 1)	Cavity parasites (n = 1)
	Mean (range) (mm)	(mm)	(mm)
Width of uterine sac	0.30 (0.24 – 0.37)	0.18	0.25
Length of uterine sac	–	–	2.5
Width of metraterm	0.24 (0.20 – 0.31)	0.11	–
Cirrus sac width	0.48 (0.43 – 0.52)	0.38	0.27
Length of cirrus sac	0.83 (0.71 – 1.10)	0.66	0.45
Width of anterior testicle	0.76 (0.50 – 0.95)	0.48	0.34
Length of anterior testicle	0.69 (0.45 – 1.00)	0.32	0.47
Width of posterior testicle	0.74 (0.55 – 0.91)	0.63	0.23
Length of posterior testicle	0.47 (0.34 – 0.56)	0.48	0.45
Width of ovary	0.18 (0.15 – 0.25)	0.12	0.12
Ovary length	0.36 (0.27 – 0.45)	0.30	0.18
Width of Mehlis Gland	0.59 (0.48 – 0.67)	0.22	–
Length of Mehlis Gland	0.53 (0.44 – 0.69)	0.41	–

* Benigno *et al.* (2014)

Prevalence: 3.4 %

Abundance: 0.3 per host

Material deposited: From *H. malabaricus* N°. ZUEC PLA 155 - *I. dimorphum* in eye.

The Kn of fish with eyes, intestine and muscles parasitized with *I. dimorphum* (Kn = 0.99) did not differ ($U = 86.0$, $p = 0.68$) from that of the non-parasitized fish (Kn = 1.00). The growth of parasitized and non-parasite hosts was allometrically positive (Fig. 4).

For the morphometric study of metacercariae of *I. dimorphum* the internal reproductive structures were measured (Fig. 2E). Measurements were taken in mm based on parasites of the eyeball (length 28.43 mm, width 2.54 mm), intestine and muscles (mean length 48.91 mm, mean width 3.35 mm) of the host (Table 1).

Discussion

In *H. malabaricus* from the upper das Velhas River, the total prevalence of *I. dimorphum* was similar to that reported for the same host (30.8 %) from the Lages Reservoir in the state of Rio de Janeiro (Paraguassu & Luque, 2007). However, it was higher than that reported for *H. malabaricus* from the São Francisco River (10.6 %) infected by *Ithyoclinostomum* sp. (Costa *et al.*, 2015) and from the Arari Lake, in the Ilha do Marajó in the state of Pará (0.9 %), infected by *I. dimorphum* (Benigno *et al.*, 2014). However, these last two studies examined a greater number of *H. malabaricus* specimens than the present study. Poulin (1993) reported that higher prevalence values are related to a more uniform distribution of parasites among hosts, as there is increasing exploitation of the available hosts.

While infection of *H. malabaricus* by metacercariae of *I. dimorphum* has been described in several regions of Brazil, this is the first report of this endoparasite in the ocular region of this host. As the presence of metacercariae of *I. dimorphum* was reported only in the mesentery, musculature, heart, esophagus, cloaca, gills and operculums of host fish (Belei *et al.*, 2013), eyeball parasitism is not fully known. This new site of infection may be due to the sporadic occurrence or behavior of this parasite. Due to the low parasitism of *I. dimorphum*, which occupied almost all of the eyeball, no damage to the prey capturing performance by the host was observed, and the body characteristics of the examined host population were not affected. However, when migrating to the host fish eyes other metacercariae may cause exophthalmos, retinal detachment, cataracts and blindness or even death (Zago *et al.*, 2013; Belei *et al.*, 2013; Ramos *et al.*, 2016) when at high levels of abundance.

The condition factor is based on the relationship between the individual's weight and length and is an important indicator of fish health, reflecting recent nutritional conditions and interactions between the fish and the biotic and abiotic factors (Le Cren, 1951; Zago *et al.*, 2013). No difference was observed in the Kn of *H. malabaricus* parasitized by *I. dimorphum* and non-parasitized fish due to the low parasite infection in the intestine, eyes and muscles.

Similarly, other studies have also shown that low parasitism by the metacercariae of digeneas did not affect the host condition factor (Paes *et al.*, 2010; Ramos *et al.*, 2016). On the other hand, an increased abundance of metacercariae of *Sphincterodiplostomum musculosum* in *Steindachnerina insculpta* caused a reduction in the condition factor of the hosts (Zago *et al.*, 2013), because digenean larvae can be highly pathogenic.

Metacercariae of *I. dimorphum* of the *H. malabaricus* musculature and intestine, the width of the uterine sac, the width and length of the cirrus sac, the anterior and posterior testis length were similar to those described by Benigno *et al.* (2014); while the values of the width of the anterior and posterior testes were lower. However, the metacercariae of *I. dimorphum* of the ocular region of *H. malabaricus* had smaller measurements to the specimens collected here in the intestine and muscles, as well as in relation to the measurements of the uterine sac and the testis length of the specimens reported by Benigno *et al.*, (2014); while the cirrus sac and width of the anterior and posterior testes had higher values, although the width of the ovary was similar. Such differences may be due to the different methods and measurement tools used in these studies, as well as the methodologies of the treatment of metacercariae for identification. Therefore, standardization of preparation techniques and morphometric measurements in morphometric studies of metacercariae of *I. dimorphum* is required, as this parasite has high body plasticity.

Conflict of Interest

Authors state no conflict of interest.

Acknowledgements

The authors would like to thank Ricardo Torres de Oliveira (CEPTA/ICMBio) for help with the dissection of fish, Dr. Paulo Sérgio Ceccarelli, the director of the Parasitology and Pathology department (CEPTA/ICMBio) and Dr. Laerte Batista de Oliveira Alves, manager of the National Center for Research and Conservation of Continental Fish (CEPTA/ICMBio), for support during field work. The authors would also like to thank the Coordenação de Aperfeiçoamento de Pessoal de Nível Superior (CAPES) for the scholarship of Darlison C. Souza and Conselho Nacional de Desenvolvimento Científico e Tecnológico - CNPq for the Research Productivity Grant (Proc: 303013/2015-0) awarded to Marcos Tavares-Dias.

References

- AMATO, J.F.R., BOEGER, W.A., AMATO, S.B. (1991): *Protocolos para laboratório, coleta e processamento de parasitos do pescado*. Rio de Janeiro: Universidade Federal Rural do Rio de Janeiro, Imprensa Universitária. 81pp.
- BELEI, F., FERREIRA, S.R., PERIN, L.M., BRAGA, F.R., SAMPAIO, W.M.S.,

- ARAÚJO, J.V., DERGAM, J.A., TAKEMOTO, R.M. (2013): First report of *Austrodiplostomum compactum* and *Ithyoclinostomum dimorphum* in trahira (*Hoplias malabaricus*) from the middle course of the Rio Doce, Minas Gerais, Brazil. *Arq. Inst. Biol.*, 80(2): 249 – 252. DOI: 10.1590/S1808-16572013000200017
- BENIGNO, R.N.M., KNOFF, M., MATOS, E.R., GOMES, D.C., PINTO R.M., CLEMENTE, S.C.S. (2014): Morphological aspects of Clinostomidae metacercariae (Trematoda: Digenea) in *Hopleryttrinus unitaeniatus* and *Hoplias malabaricus* (Pisces: Erythrinidae) of the Neotropical region, Brazil. *An. Acad. Bras. Cienc.*, 86(2): 733 – 744. DOI: 10.1590/0001-3765201420130025
- BUSH, A.O.; LAFFERTY, K.D.; LOTZ, J.M.; SHOSTAK, W. (1997): Parasitology meets ecology on its own terms: Margolis *et al.* revisited. *J. Parasitol.*, 83(4): 575 – 583. PMID: 9267395. DOI: 10.2307/3284227
- COSTA, D.P.C., MONTEIRO, C.M., BRASIL-SATO, M.C. (2015): Digenea of *Hoplias intermedius* and *Hoplias malabaricus* (Actinopterygii, Erythrinidae) from upper São Francisco River, Brazil. *Rev. Bras. Parasitol. Vet.*, 24(2): 129 – 135. DOI: 10.1590/S1984-29612015038
- DIAS, M.L.G.G., SANTOS, M.J., RANGEL, E., SOUZA, G.T., MACHADO, M.H., PAVANELLI G.C. (2003): Scanning electron microscopy of *Ithyoclinostomum dimorphum* (Trematoda: Clinostomidae), a parasite of *Ardea cocoi* (Aves: Ardeidae). *Parasitol. Res.*, 90(5): 355 – 358. DOI: 10.1007/s00436-003-0862-1
- GALLIO, M., SILVA, A.S., SOARES, J.F., SILVA, M.K., SALOMÃO, E.L., MONTEIRO, S.G. (2007): Ocorrência de metacercárias de *Ithyoclinostomum dimorphum* em traíras no Rio Grande do Sul, Brasil: relato de caso [Occurrence of metacercariae *Ithyoclinostomum dimorphum* in traíras in Rio Grande do Sul, Brazil: report of case.]. *Estud. Biol.* 29 (68/69): 337 – 339 (In Portuguese)
- LE CREN, E.D. (1951): The length-weight relationship and seasonal cycle in Gonad weight and condition in the perch (*Perca fluviatilis*). *J. Anim. Ecol.*, 20 (2): 201 – 219
- LUQUE, J.L., PEREIRA, F.B., ALVES, P.V., OLIVA, M.E., TIMI, J.T. (2017): Helminth parasites of South American fishes: current status and characterization as a model for studies of biodiversity. *J. Helminthol.*, 91:150 – 164. DOI: 10.1017/S0022149X16000717
- MALABARBA, L.R. (2006): Peixes de riachos da Mata Atlântica nas unidades de conservação do Vale do Rio Ribeira de Iguape no Estado de São Paulo [Fish from streams of the Atlantic Forest in the conservation units of the Ribeira de Iguape River Valley in the State of São Paulo.]. *Neotrop. Ichthyol.*, 4(3): 377 – 377. DOI: 10.1590/S1679-62252006000300012 (In Portuguese)
- PAES, J.V.K., CARVALHO, E.D., SILVA, R.J. (2010): Infection levels of *Austrodiplostomum compactum* (Digenea, Diplostomidae) metacercariae in *Plagioscion squamosissimus* (Teleostei, Sciaenidae) from the Nova Avanhandava reservoir, São Paulo State, Brazil. *J. Helminthol.*, 84: 284 – 291. DOI: 10.1017/S0022149X09990617
- PARAGUASSU, A.R., LUQUE, J.L. (2007): Metazoários parasitos de seis espécies de peixes do reservatório de Lajes, Estado do Rio de Janeiro, Brasil [Metazoan parasites of six species of fish from the Lajes reservoir, Rio State of January, Brazil.]. *Rev. Bras. Parasitol. Vet.*, 16(3): 121 – 128. DOI: 10.1590/S1984-29612007000300002 (In Portuguese)
- POULIN, R. (1993): The disparity between observed and uniform distributions: a new look at parasite aggregation. *Int. J. Parasitol.*, 23: 937 – 944
- RAMOS, I.P., ZAGO, A.C., FRANCESCHINI, L., RAMOS, I.P., ZICA, E.O.P., WUNDERLICH, A.C., LIMA, F.P., SILVA, R.J. (2016): *Austrodiplostomum compactum* metacercariae (Digenea: Diplostomidae) in *Schizodon intermedius* (Characiformes: Anostomidae) from Jurumirim reservoir, Brazil. *Braz. J. Vet. Parasitol.*, 25(2): 240 – 243. DOI: 10.1590/S1984-29612016035
- RODRIGUES, L.C., SANTOS, A.C.G., FERREIRA, E.M., TEÓFILO, T.S., PEREIRA, D.M., COSTA, F.N. (2017): Aspectos parasitológicos da traíra (*Hoplias malabaricus*) proveniente da cidade de São Bento, MA [Parasitological aspects of the trahira (*Hoplias malabaricus*) coming from the city of São Bento, MA]. *Arq. Bras. Med. Vet. Zootec.*, 1: 264 – 268. DOI: 10.1590/1678-4162-8798 (In Portuguese)
- TRAVASSOS, L., FREITAS, J.F.T., KOHN, A. (1969): Trematódeos do Brasil [Trematodeos in Brazil]. *Mem. Inst. Oswaldo Cruz*, 886 pp. (In Portuguese)
- ZAGO, A.C., FRANCESCHINI, L., RAMOS, I.P., ZICA, E.O.P., WUNDERLICH, A.C., CARVALHO, E.D., SILVA, R.J. (2013): *Sphincterodiplostomum musculosum* (Digenea, Diplostomidae) infecting *Steindachnerina insculpta* (Characiformes, Curimatidae) in the Chavantes Reservoir, Southeastern Brazil. *Rev. Bras. Parasitol. Vet.*, 22(1): 98 – 103. DOI: 10.1590/S1984-29612013000100018
- ZAR, J.H. (2010): *Biostatistical analysis*. 5th ed. New Jersey: Prentice Hall