

The role of Pazopanib in Soft Tissue Sarcoma: A comprehensive review of the literature

George Fotopoulos^{1*}, George Pentheroudakis²

¹*Oncology Unit, Third Department of Medicine, University of Athens,
Athens, Greece*

²*Department of Medical Oncology, Ioannina University Hospital, Greece*

Abstract: INTRODUCTION: Sarcomas are a rare and heterogeneous group of tumours of mesenchymal origin. Single agent pazopanib showed activity in a phase II clinical trial designed to screen various soft tissue sarcoma subtypes [10] and a phase III [11] clinical trial followed resulting in FDA approval in 2012 for use in metastatic soft tissue sarcoma exposed to prior chemotherapy.

METHODS: We conducted an independent computerised review of PubMed and ScienceDirect database up to May 2015 using combinations of terms such as *soft tissue sarcoma, pazopanib, STS, VEGFR2, TKIs, angiogenesis, advanced sarcoma treatment, targeted therapy for sarcoma*

AIM: Our aim was to explore the role of pazopanib in soft tissue sarcoma (STS) treatment, its mode of action, the clinical trials supporting its approval, safety and efficacy, how the product fits into the real world and its contribution to the development of targeted therapy for STS

CONCLUSION: Pazopanib is a valid, innovative and cost-effective approach in the treatment of advanced pre-treated STS

Keywords: *Soft tissue sarcoma • Pazopanib • STS • VEGFR2 • TKIs • Angiogenesis • Advanced sarcoma treatment • Targeted therapy for sarcoma*

© De Gruyter Open

Introduction

Sarcomas are a rare and heterogeneous group of tumours of mesenchymal origin. According to tumour type, they are classified into soft tissue sarcomas (STS) and primary sarcomas of the bone.

In adults, STS are about four times more common than sarcomas of the bone (11,000 cases compared with 2900 in 2012) [1]. STS can be further classified in 50 different entities in terms of genetic analysis, clinical behaviour and pathogenesis [2]. The more common histological subtypes of sarcoma include gastrointestinal stromal tumour (GIST), leiomyosarcoma, liposarcoma, pleomorphic sarcoma, synovial sarcoma and fibrosarcoma [2].

Sarcomas can arise almost everywhere in the body with the most common site being the extremities. About one-third arise in and around the retroperitoneum and 10% in the trunk [3]. The use of surgery and radiotherapy

is the mainstay of local treatment options, but in almost half of patients, the disease will recur at distant sites [4]. Doxorubicin, epirubicin and ifosfamide are the most commonly used agents in the management of metastatic STS and associated with a response rate (RR) of 20%. Even for these agents, among trials, activity varies, highlighting the variability in disease sensitivity (noted above) and the fact that STS histology is a confounding factor of drug efficacy [5–7], and combination chemotherapy has not shown a benefit in overall survival (OS) [8].

Recent advances such as the use of imatinib in GIST, gastrointestinal stromal tumor have refined our systemic treatment strategy [9]. Pazopanib has shown activity in a phase II clinical trial designed to screen various soft tissue sarcoma subtypes [10] and a phase III [11] clinical trial followed resulting in Food and Drug administration approval in 2012 for use in metastatic soft tissue sarcoma exposed to prior chemotherapy.

* E-mail: fotopoulos.george1@gmail.com

Material and methods

We conducted an independent computerised review of PubMed and ScienceDirect database up to May 2015 using combinations of terms such as *soft tissue sarcoma*, *pazopanib*, *STS*, *VEGFR2*, *TKIs*, *angiogenesis*, *advanced sarcoma treatment*, *targetted therapy for sarcoma*. We set no geographical restrictions. All case reports and non-English articles were excluded. Once all articles to be included were identified, the references of all included articles were reviewed to identify any additional applicable publications that may have been missed by the digital search. References from these articles were also obtained, and review articles are cited to provide readers with more details than this review has room. Our aim was to explore the role of pazopanib in STS treatment, its mode of action, the clinical trials supporting its approval, safety and efficacy, how the product fits into the real world and its contribution to the development of targetted therapy for STS.

Discussion

1. Current treatment strategies in soft tissue sarcoma

As single drugs or in combination, anthracyclines and the alkylating agent ifosfamide yield the best RR in various studies [12]. Most studies include a variety of histologic subtypes of STSs thus making it difficult to assess the clinical activity of any given treatment. The endpoints of these trials, such as RR, OS and progression-free survival (PFS) are influenced by the distribution of histologic subtypes. This, in turn, complicates the assessment of chemotherapy efficacy as it is widely accepted that different histologic subtypes exhibit variable patterns of chemosensitivity.

Doxorubicin, a sensitive chemotherapy agent for STS was established in the early 1970s [5]. The optimal dose is ≥ 60 mg/m² per cycle, administered every 21 days, with lower doses associated with inferior results in terms of RR [13]. A clinically meaningful dose–response relationship with single agent doxorubicin at doses beyond 75 mg/m² per cycle is hard to be established. Even in modern multi-institutional series using 70–80 mg/m² per cycle, the RRs vary and range between 10 and 25%, with the majority being partial responses [14].

Liposomal anthracyclines are active in STS, but it is unclear if they are as efficacious as unencapsulated doxorubicin. Some series report durable RRs up to 50% in many patients [15]. It is an agent used for metastatic

STS, most commonly in Europe and in patients older than 65 years.

Ifosfamide has similar antitumour activity as doxorubicin. RRs are in the range of 7–41% (average 25%) among patients pre-treated with doxorubicin [16]. A dose–response relationship has been shown for ifosfamide in metastatic STS; the threshold is approximately 6 g/m² per cycle [16]. In one trial, single agent doxorubicin (75 mg/m² every 3 weeks) was compared-head-to-head with two different doses of ifosfamide (3 g/m² over 4 hours daily for 3 days or 9 g/m² over 72 hours by continuous infusion) in patients with advanced STS [17]. While efficacy was similar in this trial, toxicity was worse regarding ifosfamide.

Taxanes are active only in the treatment of advanced angiosarcoma with paclitaxel showing the best results [18]. Other conventional cytotoxic drugs showing at least some antitumour activity with RRs less than 20% include vinorelbine, methotrexate, dacarbazine and temozolomide (particularly for leiomyosarcoma), cisplatin and carboplatin [19–27].

Regarding gemcitabine, there are conflicting data regarding its use as monotherapy. It is a well-validated option, confirmed in at least three studies [28–30] in combination with docetaxel, especially in leiomyosarcoma and undifferentiated pleomorphic sarcoma.

Another validated cytotoxic agent not approved in the US is trabectedin with the highest RRs observed in the myxoid/round cell liposarcoma and leiomyosarcoma subtypes [30,31].

Up until now, for patients with advanced or metastatic soft tissue sarcoma who progressed after an anthracycline-containing regimen and other validated treatment options, such as ifosfamide, gemcitabine or gemcitabine combinations, not many things could be done.

This changed in 2012 when pazopanib was approved for the treatment of advanced or metastatic STS for patients previously treated with standard chemotherapy and histology other than liposarcoma.

2. Mode of action

Pazopanib is a multikinase inhibitor. It limits tumour growth via inhibition of angiogenesis. In particular, it works by inhibiting cell surface vascular endothelial growth factor receptors (VEGFR-1, VEGFR-2, VEGFR-3), platelet-derived growth factor receptors (PDGFR-alpha and -beta), fibroblast growth factor receptor (FGFR-1 and -3), cytokine receptor (cKIT), interleukin-2 receptor inducible T-cell kinase, leukocyte-specific protein

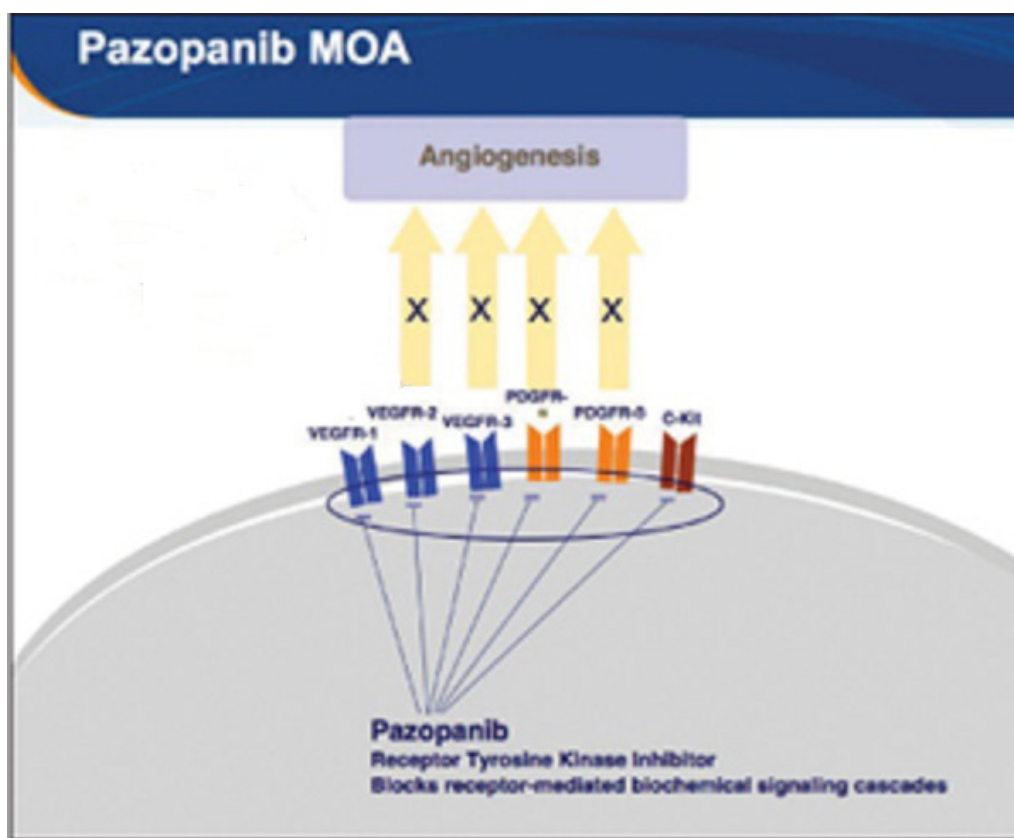


Figure 1. Online image gallery.

tyrosine kinase (Lck), and transmembrane glycoprotein receptor tyrosine kinase (c-Fms).[Figure 1]

In vivo preclinical studies about pazopanib pharmacokinetic and pharmacodynamic have been conducted demonstrating a significant dose-dependent tumour growth inhibition in a wide variety of tumour xenografts (i.e., colon, melanoma, prostate, renal, breast, lung and multiple myeloma)[33].The interaction between VEGF and its receptor VEGFR-2, controlling and modulating angiogenesis has been shown to play a major role in tumour progression in sarcomas [34]. Pazopanib has demonstrated activity and is approved for the treatment of renal cell carcinoma (RCC),also showing activity in other malignancies such as hepatocellular carcinoma (HCC), non-small cell lung cancer (NSCLC), ovarian cancer and multiple myeloma [35–43]

3. Clinical trials supporting pazopanib approval in STS (Table 1)

The first study evaluating pazopanib in solid tumours was performed by Hurwitz *et al* [37]. 63 patients with

advanced and refractory solid tumors received drug doses between 50 and 100 mg three times weekly or 50 and 2000 mg once daily and 300 or 400 mg twice daily. The adverse reactions reported were hypertension (33%), diarrhoea (33%), hair depigmentation (32%), nausea (32%), anorexia (25%) and fatigue (24%) with hypertension being the most frequent grade 3 reaction reported. A maximum tolerated dose (MTD) could not be determined in this trial. The dose for subsequent drug development was determined at 800 mg daily because of exposure to the drug plateauing at this dose.

Given the importance of angiogenesis in STS, pazopanib was explored in patients with advanced STS in a phase II study [10]. Patients with intermediate or high grade, advanced STS, not able to receive chemotherapy for whatever reason or who had received up to two prior regimens for advanced disease, had documented progression, had a good performance status with good organ function were eligible. Pazopanib 800 mg was given daily. Primary endpoint was progression-free rate (PFR) at 4 months. Secondary endpoints were RR, safety and OS. Liposarcomas, leiomyosarcomas, synovial sarcomas and other STS types were studied

Table 1. Girolamo Ranieri, Maria Mammib, Eugenio Donato Di Paola et al. Pazopanib, a tyrosine kinase inhibitor with strong anti-angiogenetic activity: A new treatment for metastatic soft tissue sarcoma *Critical Reviews in Oncology/Haematology* 89 (2014) 322–329

Completed clinical trials considering pazopanib.

Author, year	Phase	Disease/s	Patients (no.)	Pazopanib dose	Primary endpoint/s	Secondary endpoint/s	Main toxicity (all grade)
Hurwitz, 2009	I	Several malignancies	63	50–2000 mg three times weekly 50–2000 mg daily 600/800 mg daily	MTD ^a	Safety	Hypertension Diarrhea
Sleijfer, 2009	II	Sarcomas	142	800 mg daily	PFR ^b at 12 weeks	Response Safety OS ^c	Anemia
Van der Graaf, 2012	III	Sarcomas	369	800 mg daily	PFS ^d	RR ^e OS ^c Safety QOL ^f	Fatigue

^a Maximum tolerated dose.

^b Progression-free rate.

^c Overall survival.

^d Progression free survival.

^e Response rate.

^f Quality of life.

and 142 patients were enrolled. The liposarcoma cohort was closed after the first stage, given insufficient activity (PFR 12 weeks, 5 of 19). PFR was 44% in the leiomyosarcoma cohort, 49% in the synovial sarcomas and 39% in the other STS types. In the three cohorts in which the primary endpoint was reached, OS and PFS were prolonged compared with historical controls in this setting. The most frequent drug-related toxicities were hypertension, fatigue, hypopigmentation, nausea, liver enzyme elevations, myelosuppression and proteinuria, all of which were mostly grades 1–2. The most frequent grades 3–4 toxicities were hyperbilirubinemia (6.3%), hypertension (7.7%) and fatigue (7.7%).

A phase III trial (PALETTE trial) [11] was conducted in 72 institutions, across 13 countries. Patients with metastatic STS progressing despite previous standard chemotherapy and not having received angiogenesis inhibitors, were randomised in a 2:1 ratio to receive either pazopanib 800 mg once daily or placebo, with no subsequent cross-over. 372 patients were registered and 369 were randomly assigned to receive pazopanib (n = 246) or placebo (n = 123). Median PFS was 4.6 months (95% CI 3.7–4.8) for pazopanib compared with 1.6 months (0.9–1.8) for placebo (hazard ratio [HR] 0.31, 95% CI 0.24–0.40; $p < 0.0001$) and OS was 12.5 months (10.6–14.8) with pazopanib versus 10.7 months (8.7–12.8) with placebo (HR 0.86, 0.67–1.11; $p = 0.25$).

Adverse events reported were fatigue (65%), diarrhea (58%), nausea (54%), weight loss (48%) and

hypertension (41%). Based on favourable data from the PALETTE trial, on April 26th, 2012, the FDA and then European Medicines Agency approved pazopanib for the treatment of patients with advanced STS who have received prior chemotherapy [44].

4. Pazopanib in the real world

In 2014, a retrospective pooled analysis [45] was conducted on pooled data from two European Organisation for Research and Treatment of Cancer trials [10, 11] on pazopanib in STS. The point of this analysis was to characterise long-term responders and survivors. Combined PFS was 4.4 months and the median OS was 11.7 months. One-third of the patients had a PFS ≥ 6 months and were defined as long-term responders and one-third of the patients survived ≥ 18 months, defined as long-term survivors. Patient characteristics were studied for their association with long-term outcomes. Median follow-up was 2.3 years. Patient characteristics were compared among four subgroups based on short-/long-term PFS and OS, respectively. Seventy-six patients were both long-term responders and long-term survivors. The analysis confirmed the importance of known prognostic factors such as performance status and tumour grading in metastatic STS patients treated with systemic treatment. Haemoglobin at baseline was established as a new prognostic factor. Twelve patients were identified

remaining on pazopanib for more than 2 years, nine of them younger than 50 years, nine females, four with smooth muscle tumours and nine with low or intermediate grade tumours. The median time on pazopanib in these patients was 2.4 years with the longest duration of 3.7 years.

The analysis concluded that one-third of all patients receiving pazopanib in these studies had a long PFS and/or OS. Good performance status, low or intermediate grade of the tumour and a normal haemoglobin level at baseline were advantageous for long-term outcome while 3.5% of patients had a PFS for more than 2 years while on pazopanib.

In 2014, in Canada, a cost-effectiveness analysis of pazopanib in advanced STS was performed [46]. A multistate model to estimate PFS, OS, lifetime STS treatment costs and quality-adjusted life-years (QALYs) for patients receiving pazopanib or placebo as second-line therapy for advanced STS was done. Cost-effectiveness was calculated alternatively from the health care system and societal perspectives for Quebec. Estimated PFS, OS, incidence of adverse events and utilities values for pazopanib and placebo were derived from the PALETTE trial. Costs were obtained from published sources.

Pazopanib is estimated to increase QALYs by 0.128 versus placebo. The cost of pazopanib versus placebo is CA\$ 20,840 from the health care system perspective and CA\$ 15,821 from the societal perspective. The cost per QALY gained with pazopanib in that comparison is CA\$ 163,336 from the health care system perspective and CA\$ 124,001 from the societal perspective. Depending on the threshold value used by reimbursement authorities to assess novel cancer therapies in each country and taking into account the limited options of effective treatment of metastatic STS, pazopanib might be a good alternative in this regard. To our knowledge, this is the only such analysis that exists.

5. Targetted therapy beyond pazopanib

As illustrated by the recent approval of pazopanib, inhibition of tumour angiogenesis is a viable therapeutic option in the management of STS.

Sunitinib and sorafenib were evaluated in phase II trials in parallel when the initial pazopanib trial was conducted by the EORTC. In two phase II trials, a significant activity for sunitinib was not demonstrated [47, 48]. Maki and colleagues [49] conducted a phase II trial with sorafenib and the median PFS and the 3-month PFR were quite similar to those found with pazopanib. Sorafenib was not declared active as a single agent because there was a difference in the design of the

study. After that, in new phase II trials, similar PFS has been reported and a response range ranging from 0 to 15% attributable to disease heterogeneity [50, 51].

Sorafenib was also evaluated in the treatment of sarcomas combined with other treatment modalities such as chemotherapy, radiotherapy and/or surgery. A phase I trial led by the Grupo Espanol de Investigacion de Sarcomas reported the feasibility of ifosfamide with sorafenib with 5 out of 12 patients in this study achieved (stable disease) for more than 5 months. In a phase II trial, D'Adamo and colleagues [52] tested the combination of sorafenib and dacarbazine. In patients with leiomyosarcoma and synovial sarcoma, a 10% RR and a 29% clinical benefit rate were observed. The conclusion from these observations is that sorafenib has activity at least in a subset of patients with STS. However, the benefit of combining this agent with chemotherapy has yet to be proven.

Brivanib, a small tyrosine kinase inhibitor targeting VEGFR and FGFR kinases, was assessed in several tumour types in a large multicohort phase II trial, using an independent randomised design in each cohort [53]. Two hundred fifty-one patients with sarcomas of all types (leiomyosarcoma, liposarcoma, angiosarcoma and other were included) [54] Within the first 12 weeks, 168 patients came off study. Median PFS was 2.6 months for patients in the brivanib arm versus 1.4 months in the placebo arm. The primary endpoint for patients with FGFR2-positive tumours (median PFS 2.8 versus 1.4 months) was achieved.

Other approaches targetting the tumour angiogenesis are currently being evaluated. One such approach is the development of vascular targetted agents using NGR peptide, a human tumour necrosis factor, targetting the tumor vasculature. Several studies have shown promising activity of this agent in combination with various chemotherapy regimens, and a phase II trial of NGR-hTNF alone or combined with doxorubicin is currently under way in various STS subtypes.

Several studies are ongoing or have completed accrual. Inhibitors of angiogenesis, either alone (axitinib, angiotensin-(1–7), pomalidomide, tivozanib, MORAb-004) or combined with chemotherapy (cisplatin 1 AVE8062) are currently being tested and await reporting.[55].

Conclusion

In the last 20 years, many drugs have been tested in phase II studies in patients with metastatic STS and many agents are used in its treatment. Nowadays, imatinib is used for GIST, taxanes for angiosarcomas, trabectedin

has been approved outside US for leiomyosarcomas and liposarcomas and the combination of docetaxel plus gemcitabine for leiomyosarcomas. Still patients with advanced non-GIST have overall a poor prognosis.

The use of pazopanib in the treatment of pre-treated advanced sarcomas has been a new tool in the management of this disease, the only true progress in this matter in the last 5 years.

Also, it has given us an insight in the central role of angiogenesis in development and progression of sarcomas and that the inhibition of pro-angiogenic

tyrosine kinase receptors using novel tyrosine kinase inhibitors seems to be an intriguing therapeutic strategy.

Already numerous trials involving the PI3K-Akt-mTOR pathway [56–63] and mTOR inhibition [64–69] are on the way.

One could say that pazopanib showed the way for the use of targetted therapy in soft tissue sarcoma.

The authors declare no conflict of interests

References

- [1] Siegel R., Naishadham D., Jemal A. Cancer Statistics, 2012. *CA Cancer J Clin.* 2012;62:10-29
- [2] Helman LJ, Meltzer P. Mechanisms of sarcoma development. *Nature Reviews Cancer* 2003;3:685–94.
- [3] Brennan M, Singer S, Maki R, O'Sullivan B. Sarcomas of the soft tissue and bone. In: DeVita Jr VT, Hellman S, Rosenberg SA, editors. *Cancer: Principles and Practice of Oncology*, vol. 2, 7th edition Philadelphia: Lippincott Williams and Wilkins; 2004.
- [4] Clark MA, Fischer C, Judson I, Thomas JM. Soft-tissue sarcoma in adults. *New England Journal of Medicine* 2005;353:701–11.
- [5] Benjamin RS, Wiernik PH, Bachur NR. Adriamycin: a new effective agent in the therapy of disseminated sarcomas. *Med Pediatr Oncol* 1975; 1:63.
- [6] Borden EC, Amato DA, Rosenbaum C, et al. Randomized comparison of three adriamycin regimens for metastatic soft tissue sarcomas. *J Clin Oncol* 1987; 5:840.
- [7] Keohan ML, Taub RN. Chemotherapy for advanced sarcoma: therapeutic decisions and modalities. *Semin Oncol* 1997; 24:572.
- [8] Van Glabbeke M, Verweij J, Judson I, Nielsen OS. Progression-free rate as the primary endpoint for phase II study in soft tissue sarcoma. *European Journal of Cancer* 2002;38:543–9.
- [9] Verweij J, van Oosterom A, Blay JY, et al. Imatinib mesylate (STI-571 Glivec, Gleevec) is an active agent for gastrointestinal stromal tumours, but does not yield responses in other soft-tissue sarcomas that are unselected for a molecular target. Results from an EORTC Soft Tissue and Bone Sarcoma Group phase II study. *Eur J Cancer* 2003; 39:2006.
- [10] Sleijfer S, Ray-Coquard I, Papai Z, et al. Pazopanib, a multikinase angiogenesis inhibitor, in patients with relapsed or refractory advanced soft tissue sarcoma: a phase II study from the European organisation for research and treatment of cancer-soft tissue and bone sarcoma group (EORTC study 62043). *J Clin Oncol* 2009; 27:3126.
- [11] van der Graaf WT, Blay JY, Chawla SP, et al. Pazopanib for metastatic soft-tissue sarcoma (PALETTE): a randomised, double-blind, placebo-controlled phase 3 trial. *Lancet* 2012; 379:1879.
- [12] Santoro A. Advanced soft tissue sarcoma: How many more trials with anthracyclines and ifosfamide? *Ann Oncol.* 1999;10:151-154
- [13] Borden EC, Amato DA, Rosenbaum C, et al. Randomized comparison of three adriamycin regimens for metastatic soft tissue sarcomas. *J Clin Oncol* 1987; 5:840.
- [14] Demetri GD, Elias AD. Results of single-agent and combination chemotherapy for advanced soft tissue sarcomas. Implications for decision making in the clinic. *Hematol Oncol Clin North Am* 1995; 9:765.
- [15] Grenader T, Goldberg A, Hadas-Halperin I, Gabizon A. Long-term response to pegylated liposomal doxorubicin in patients with metastatic soft tissue sarcomas. *Anticancer Drugs* 2009; 20:15.
- [16] Patel SR, Vadhan-Raj S, Papadopolous N, et al. High-dose ifosfamide in bone and soft tissue sarcomas: results of phase II and pilot studies--dose-response and schedule dependence. *J Clin Oncol* 1997; 15:2378.
- [17] Lorigan P, Verweij J, Papai Z, et al. Phase III trial of two investigational schedules of ifosfamide compared with standard-dose doxorubicin in advanced or metastatic soft tissue sarcoma: a European Organisation for Research and Treatment of Cancer Soft Tissue and Bone Sarcoma Group Study. *J Clin Oncol* 2007; 25:3144.
- [18] Skubitz KM, Haddad PA. Paclitaxel and pegylated-liposomal doxorubicin are both active in angiosarcoma. *Cancer* 2005; 104:361.

- [19] Casanova M, Ferrari A, Spreafico F, et al. Vinorelbine in previously treated advanced childhood sarcomas: evidence of activity in rhabdomyosarcoma. *Cancer* 2002; 94:3263.
- [20] Anderson SE, Keohan ML, D'Adamo DR, Maki RG. A retrospective analysis of vinorelbine chemotherapy for patients with previously treated soft-tissue sarcomas. *Sarcoma* 2006; 2006:15947.
- [21] Omura GA, Major FJ, Blessing JA, et al. A randomized study of adriamycin with and without dimethyl triazenoimidazole carboxamide in advanced uterine sarcomas. *Cancer* 1983; 52:626.
- [22] Gottlieb JA, Benjamin RS, Baker LH, et al. Role of DTIC (NSC-45388) in the chemotherapy of sarcomas. *Cancer Treat Rep* 1976; 60:199.
- [23] Buesa JM, Mouridsen HT, van Oosterom AT, et al. High-dose DTIC in advanced soft-tissue sarcomas in the adult. A phase II study of the E.O.R.T.C. Soft Tissue and Bone Sarcoma Group. *Ann Oncol* 1991; 2:307.
- [24] Garcia del Muro X, Lopez-Pousa A, Martin J, et al. A phase II trial of temozolomide as a 6-week, continuous, oral schedule in patients with advanced soft tissue sarcoma: a study by the Spanish Group for Research on Sarcomas. *Cancer* 2005; 104:1706.
- [25] Zucali PA, Bertuzzi A, Parra HJ, et al. The «old drug» dacarbazine as a second/third line chemotherapy in advanced soft tissue sarcomas. *Invest New Drugs* 2008; 26:175.
- [26] Thigpen JT, Blessing JA, Beecham J, et al. Phase II trial of cisplatin as first-line chemotherapy in patients with advanced or recurrent uterine sarcomas: a Gynecologic Oncology Group study. *J Clin Oncol* 1991; 9:1962.
- [27] Goldstein D, Chevart B, Trump DL, et al. Phase II trial of carboplatin in soft-tissue sarcoma. *Am J Clin Oncol* 1990; 13:420.
- [28] Bay JO, Ray-Coquard I, Fayette J, et al. Docetaxel and gemcitabine combination in 133 advanced soft-tissue sarcomas: a retrospective analysis. *Int J Cancer* 2006; 119:706.
- [29] Maki RG, Wathen JK, Patel SR, et al. Randomized phase II study of gemcitabine and docetaxel compared with gemcitabine alone in patients with metastatic soft tissue sarcomas: results of sarcoma alliance for research through collaboration study 002 [corrected]. *J Clin Oncol* 2007; 25:2755.
- [30] Penel N, Glabbeke MV, Mathoulin-Pelissier S, et al. Performance status is the most powerful risk factor for early death among patients with advanced soft tissue sarcoma: the European Organisation for Research and Treatment of Cancer-Soft Tissue and Bone Sarcoma Group (STBSG) and French Sarcoma Group (FSG) study. *Br J Cancer* 2011; 104:1544.
- [31] Le Cesne A, Blay JY, Judson I, et al. Phase II study of ET-743 in advanced soft tissue sarcomas: a European Organisation for the Research and Treatment of Cancer (EORTC) soft tissue and bone sarcoma group trial. *J Clin Oncol* 2005; 23:576.
- [32] Garcia-Carbonero R, Supko JG, Manola J, et al. Phase II and pharmacokinetic study of ecteinascidin 743 in patients with progressive sarcomas of soft tissues refractory to chemotherapy. *J Clin Oncol* 2004; 22:1480.
- [33] Hamberg P, Verweij J, Sleijfer S. (Pre-)clinical pharmacology and activity of pazopanib, a novel multikinase angiogenesis inhibitor. *The Oncologist* 2010; 15(6):539–47.
- [34] Lammi J, Fan M, Rosenthal HG, et al. Expression of vascular endothelial growth factor correlates with the advance of clinical osteosarcoma. *International Orthopaedics* 2012; 36(11):2307–13.
- [35] Kumar R, Knick VB, Rudolph SK, et al. Pharmacokinetic–pharmacodynamic correlation from mouse to human with pazopanib, a multikinase angiogenesis inhibitor with potent antitumor and antiangiogenic activity. *Molecular Cancer Therapeutics* 2007; 6:2012–21.
- [36] Podar K, Tonon G, Sattler M, et al. The small-molecule VEGF receptor inhibitor pazopanib (GW786034B) targets both tumor and endothelial cells in multiple myeloma. *Proceedings of the National Academy of Science of the United States of America* 2006; 103:19478–83.
- [37] Hurwitz HI, Dowlat A, Saini S, et al. Phase I trial of pazopanib in patients with advanced cancer. *Clinical Cancer Research* 2009; 15:4220–7.
- [38] Sternberg CN, Davis ID, Mardiak J, et al. Pazopanib in locally advanced or metastatic renal cell carcinoma: results of a randomized phase III trial. *Journal of Clinical Oncology* 2010; 28:1061–8.
- [39] Hutson TE, Davis ID, Machiels JP, et al. Efficacy and safety of pazopanib in patients with metastatic renal cell carcinoma. *Journal of Clinical Oncology* 2010; 28: 475–80.
- [40] Yau CC, Chen PJ, Chan P, et al. Phase I study of pazopanib in hepatocellular carcinoma: evaluation of clinical activity, pharmacokinetics and dynamic contrast enhanced MRI (DCE MRI). *European Journal of Cancer* 2009; 7(Suppl 2):122.
- [41] Altorki N, Heymach J, Guarino M, et al. Phase II study of pazopanib (GW786034) given preoperatively in stage I–II non-small cell lung cancer (NSCLC): a proof-of-concept study. *Annals of Oncology* 2008; 19(Suppl 8):89.

- [42] Friedlander M, Hancock KC, Benigno B, et al. Pazopanib (GW786034) is active in women with advanced epithelial ovarian, fallopian tube and peritoneal cancers: final results of a phase II study. *Annals of Oncology* 2008;19(Suppl 8):211.
- [43] Prince HM, Hönemann, Spencer A, et al. Vascular endothelial growth factor inhibition is not an effective therapeutic strategy for relapsed or refractory multiple myeloma: a phase 2 study of pazopanib (GW786034). *Blood* 2009;113: 4819–20.
- [44] www.fda.gov. FDA approves Votrient for advanced soft tissue sarcoma.
- [45] B. Kasper, S. Sleijfer, S. Litière et al. Long-term responders and survivors on pazopanib for advanced soft tissue sarcomas: subanalysis of two European Organisation for Research and Treatment of Cancer (EORTC) clinical trials 62043 and 62072. *Annals of Oncology* 25: 719–724, 2014
- [46] T.E. Delea, J. Amdahl, H.R. Nakhaipour, S.C. Manso, A. Wang, N. Fedor, A. Chit. Cost effectiveness of pazopanib in advanced soft-tissue sarcoma in Canada. *Curr Oncol*, Vo21, 2014.748-759;
- [47] George S, Blay JY, Casali PG, et al. Clinical evaluation of continuous daily dosing of sunitinib malate in patients with advanced gastrointestinal stromal tumour after imatinib failure. *Eur J Cancer* 2009;45:1959–68.
- [48] Tariq MS, Agresta S, Vigil CE, et al. Phase II study of sunitinib malate, a multitargeted tyrosine kinase inhibitor in patients with relapsed or refractory soft tissue sarcomas. Focus on three prevalent histologies: leiomyosarcoma, liposarcoma and malignant fibrous histiocytoma. *Int J Cancer* 2011;129:1963–9.
- [49] Maki RG, D'Adamo DR, Keohan ML, et al. Phase II study of sorafenib in patients with metastatic or recurrent sarcomas. *J Clin Oncol* 2009;27:3133–40.
- [50] Bertuzzi A, Stroppa EM, Secondino S, et al. Efficacy and toxicity of sorafenib monotherapy in patients with advanced soft tissue sarcoma failing anthracycline-based chemotherapy. *J Clin Oncol* (Meeting Abstracts) 2010;28:10025.
- [51] Ryan CW, Von Mehren M, Rankin CJ, et al. Phase II intergroup study of sorafenib in advanced soft tissue sarcomas (STS): SWOG 0505. *J Clin Oncol* (Meeting Abstracts) 2008;26:10532.
- [52] D'Adamo DR, Keohan ML, Carvajal RD, et al. A phase II trial of sorafenib and dacarbazine in leiomyosarcoma, synovial sarcoma, and malignant peripheral nerve sheath tumor (MPNST). *J Clin Oncol* (Meeting Abstracts) 2011;29:10025.
- [53] Ratain MJ, Schwartz GK, Oza AM, et al. Brivanib (BMS-582664) in advanced solid tumors (AST): results of a phase II randomized discontinuation trial (RDT). *J Clin Oncol* (Meeting Abstracts) 2011;29:3079.
- [54] Schwartz GK, Maki RG, Ratain MJ, et al. Brivanib (BMS-582664) in advanced soft-tissue sarcoma (STS): biomarker and subset results of a phase II randomized discontinuation trial. *J Clin Oncol* (Meeting Abstracts) 2011;29:10000.
- [55] Alice Levar, Louis Tass, Philippe A. Cassier. Emerging Therapies for Soft-Tissue Sarcomas. *Hematol Oncol Clin N Am* 27 (2013) 1063–1078
- [56] Hernando E, Charytonowicz E, Dudas ME, et al. The AKT-mTOR pathway plays a critical role in the development of leiomyosarcomas. *Nat Med* 2007;13:748–53.
- [57] Gutierrez A, Snyder EL, Marino-Enriquez A, et al. Aberrant AKT activation drives well-differentiated liposarcoma. *Proc Natl Acad Sci U S A* 2011;108:16386–91.
- [58] Friedrichs N, Trautmann M, Endl E, et al. Phosphatidylinositol-30-kinase/AKT signaling is essential in synovial sarcoma. *Int J Cancer* 2011;129:1564–75.
- [59] Setsu N, Yamamoto H, Kohashi K, et al. The Akt/mammalian target of rapamycin pathway is activated and associated with adverse prognosis in soft tissue leiomyosarcomas. *Cancer* 2012;118:1637–48.
- [60] Barretina J, Taylor BS, Banerji S, et al. Subtype-specific genomic alterations define new targets for soft-tissue sarcoma therapy. *Nat Genet* 2010;42:715–21.
- [61] Schuetze SM, Zhao L, Chugh R, et al. Results of a phase II study of sirolimus and cyclophosphamide in patients with advanced sarcoma. *Eur J Cancer* 2012;48:1347–53.
- [62] Richter S, Pink D, Hohenberger P, et al. Multicenter, triple-arm, single-stage, phase II trial to determine the efficacy and safety of everolimus (RAD001) in patients with refractory bone or soft tissue sarcomas including GIST. *J Clin Oncol* (Meeting Abstracts) 2010;28:10038.
- [63] Quek R, Wang Q, Morgan JA, et al. Combination mTOR and IGF-1R inhibition: phase I trial of everolimus and figitumumab in patients with advanced sarcomas and other solid tumors. *Clin Cancer Res* 2011;17:871–9.
- [64] El-Hashemite N, Zhang H, Henske EP, et al. Mutation in TSC2 and activation of mammalian target of rapamycin signalling pathway in renal angiomyolipoma. *Lancet* 2003;361:1348–9.

- [65] Pan CC, Chung MY, Ng KF, et al. Constant allelic alteration on chromosome 16p (TSC2 gene) in perivascular epithelioid cell tumour (PEComa): genetic evidence for the relationship of PEComa with angiomyolipoma. *J Pathol* 2008;214:387–93.
- [66] Kenerson H, Folpe AL, Takayama TK, et al. Activation of the mTOR pathway in sporadic angiomyolipomas and other perivascular epithelioid cell neoplasms. *Hum Pathol* 2007;38:1361–71.
- [67] Wagner AJ, Malinowska-Kolodziej I, Morgan JA, et al. Clinical activity of mTOR inhibition with sirolimus in malignant perivascular epithelioid cell tumors: targeting the pathogenic activation of mTORC1 in tumors. *J Clin Oncol* 2010;28: 835–40.
- [68] Italiano A, Delcambre C, Hostein I, et al. Treatment with the mTOR inhibitor temsirolimus in patients with malignant PEComa. *Ann Oncol* 2010;21:1135–7.
- [69] Pedersen JV, Benson C, Tunariu N, et al. A retrospective study from the Royal Marsden Hospital (RMH) of patients with malignant perivascular epithelioid cell tumors (PEComa) receiving treatment with sirolimus (SI) or temsirolimus (TSI). *J Clin Oncol (Meeting Abstracts)* 2012;30:10038.