

A rare cause of hypophysitis: tuberculosis

ATES I, KATIPOGLU B, COPUR B, YILMAZ N

Numune Training and Research Hospital, Department of Internal Medicine, Ankara, Turkey
E-mail: dr.ihsanates@hotmail.com

Objectives. Hypophysitis is a heterogeneous inflammatory disease of pituitary gland. As it causes headache and visual defects, it mimics sellar tumors in clinical and radiological aspects. It may occur due to primary or secondary causes. Tuberculosis is one of the rare secondary causes of the hypophysitis.

Subject and Results. A 30-year-old male patient presented with fatigue and headache. Panhypopituitarism was considered due to the results and the diagnostic magnetic resonance (MR) imaging revealed sagittal section diameter of pituitary gland higher than normal. Biopsy of the pituitary gland was concordant with the granulomatous hypophysitis. Other possible diagnosis was excluded.

Conclusion. The tubercular hypophysitis, as a result of performed tests, is discussed hereby, in the case report.

Key words: hypopituitarism, hypophysitis, tuberculosis

The hypophysitis is a disease characterized by inflammation of pituitary gland with usually autoimmune origin, and cell infiltration. It may develop primarily or secondary to systemic diseases, such as tuberculosis, Wegener's granulomatosis syphilis (Ahmad et al. 2005). Hypophysitis developing secondary to tuberculosis is a very rare clinical entity. Only a limited number of cases are reported in the literature (Honegger et al. 1997; Bhardwaj et al. 2005). The hypophysitis case developing secondary to tuberculosis as a very rare entity is discussed in this case report.

Subject and Results

A 30-year-old male patient presented to our clinic with fatigue, malaise, somnolence, and headache. It was learned that the onset of the complaints was three months before and they gradually increased since then. There was no chronic disease, medication, herbal agent or alcohol use in the patient anamnesis. Overall medical condition of the patient was mod-

erate with 36.7°C body temperature, 80/50 mmHg arterial blood pressure and 50/min heart rate. Physical examination revealed no abnormal finding other than icteric sclera. Chemiluminescence immunoassays were used for measurement the hormone levels in same blood sample. Due to the pathologic findings of 0.05 ng/dl free thyroxine level (T₄; reference range 0.87–1.7 ng/dl), 2.04 pg/ml free triiodothyronine level (T₃; reference range 2.1–4.4 pg/ml) and 0.46 U/ml of thyroid-stimulating hormone (TSH; reference range 0.27–4.2 U/ml), further tests were performed on the patient for a pre-diagnosis of central hypothyroidism. Tests performed for etiology resulted in 0.82 µg/dl cortisol (reference range 7–28 µg/dl), 0.1 mIU/l luteinizing hormone (LH; reference range 1.8–12.0 mIU/l), 7.97 pg/ml adrenocorticotrophic hormone (ACTH; reference range 7–50 pg/ml) and 2.68 mIU/ml follicle stimulating hormone (FSH; reference range 1.3–19.3 mIU/ml). Panhypopituitarism was considered due to these results. Levothyroxine and prednisolone treatment was initiated.

The diagnostic magnetic resonance (MR) imaging was performed (Figure 1). Imaging revealed sagittal section diameter of pituitary gland 14 mm higher than normal. No heterogeneity was observed at pituitary gland level. Biopsy of pituitary gland was performed for establishing diagnosis and result was concordant with the granulomatous hypophysitis.

For differential diagnosis, viral panels were performed. TORCH panel, herpes simplex virus, Brucella, Epstein-Barr, parvovirus, varicella-zoster, T. pallidum tests were negative. Adenosine deaminase (ADA) level was 45, in the upper limit. Tuberculin skin test (PPD) resulted in 22 mm induration and QuantiFERON-TB gold test was positive.

Hypophysitis developed secondary to tuberculosis was considered. In addition to the current treatment, anti-tuberculosis (isoniazid, streptomycin, pyrazinamide, and rifampin) treatment was initiated. The dose of administered prednisolone was gradually (24 → 18 → 12 → 8 → 7.5 → 5 → 4 mg/day) decreased along the course of the treatment. The need for steroid was completely eliminated by month six of the tuberculosis treatment. He made good clinical response and there was seen a significant improvement after the treatment.

Discussion

Only a limited number of tubercular hypophysitis cases are reported in the literature (Bhardwaj et al. 2005). Its incidence is 0.5–4% of all the intracranial

lesions. It is particularly common among females in the age range of 50–65 years. It is manifested with headache as the first and most common symptom. It may be accompanied by the symptoms and findings of the panhypopituitarism (Honegger et al. 1997). Adenoma, craniopharyngioma, and metastatic tumors include the predominantly considered diagnoses in patients presenting with headache, loss in visual sharpness, and poor cognitive functioning (Pereira et al. 1995; Ahmad et al. 2005). Pituitary gland MR is required for distinctive diagnosis. In our case, the hypophysitis was prominently considered due to the increased size of pituitary gland and thickened sphenoid sinus observed on MR imaging (Figure 1). Granulomatous inflammation and necrosis were identified in specimen collected with transsphenoidal biopsy. Elevated level of ADA, positive tuberculin skin test and QuantiFERON test positivity of the case suggested tubercular hypophysitis.

While it was determined that 25–30% of tubercular hypophysitis cases reported in the literature had previous or active tuberculosis, the case in question has no such condition. Trabelsi et al. (2005) have reported that pituitary gland enlargement and nodular thickening were identified in a female case presented with amenorrhea, galactorrhea, polyuria and polydipsia, and a history of erythema nodosum. The result of biopsy was reported as granulomatous inflammation. Upon PPD (+) result, tuberculosis treatment was initiated. In the case reported by Husain et al. (2008), a 40-year-old female patient was referred with non-specific headache. An image concordant with mass was observed in pituitary MR imaging for advanced testing. Thereafter, meningitis and rhinorrhea were observed in the patient. *M. tuberculosis* polymerase chain reaction (PCR) test was positive upon transsphenoidal biopsy, and treatment was initiated. PCR testing for *M. tuberculosis* infection involves the use of nucleic amplification for the detection of *M. tuberculosis* DNA in tissue specimens. TBC PCR is a rapid and reliable test in the diagnosis and management of tuberculosis. The procedure can be performed in a few hours and confirmation of results obtained within one to three days. PCR tests can differentiate between *M. tuberculosis* and other species of mycobacteria.

Our case is a young male with good socioeconomic status which differentiates from the others in the literature.

In cases such as the tubercular hypophysitis developing due to secondary causes, early diagnosis is very important given that panhypopituitarism may be completely eliminated in clinical terms following an

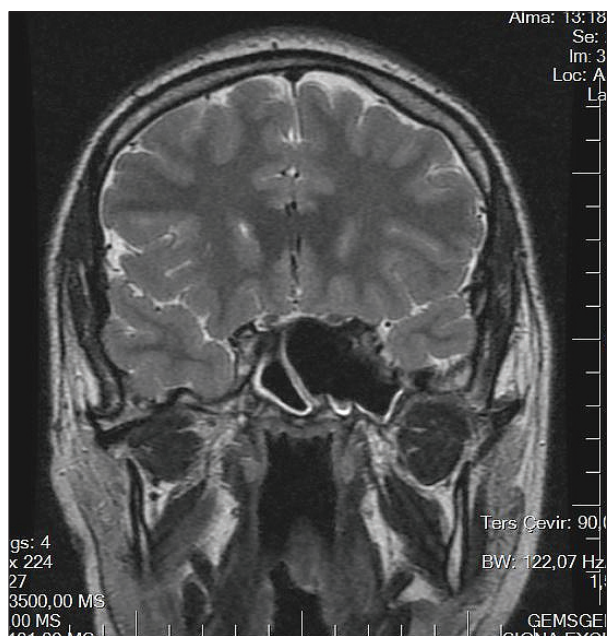


Figure 1. Magnetic resonance (MR) imaging.

effective anti-tuberculosis treatment. Therefore, the tubercular hypophysitis should be kept considered

for the cases referred with hypopituitarism clinic and suggesting secondary hypophysitis.

References

- Ahmad FU, Chandra PS, Sanyal S, Garg A, Mehta VS. Sellar tuberculoma an unusual infection. *Indian J Tuberc* 52, 215–217, 2005.
- Bhardwaj M, Sharma A, Pal HK. Granulomatous hypophysitis. *Neurol India* 53, 364–365, 2005.
- Honegger J, Fahlbusch R, Bornemann A, Hensen J, Buchfelder M, Muller M, Nomikos P. Lymphocytic and granulomatous hypophysitis: experience with nine cases. *Neurosurgery* 40, 713–723, 1997.
- Husain N, Husain M, Rao P. Pituitary tuberculosis mimicking idiopathic granulomatous hypophysitis. *Pituitary* 11, 313–315, 2008.
- Pereira J, Vaz R, Carvalho D, Cruz C. Thickening of the pituitary stalk: a finding suggestive of intrasellar tuberculoma? Case report. *Neurosurgery* 36, 1013–1016, 1995.
- Trabelsi L, Majdoub-Rekik N, Bouaziz H, Mnif-Feki M, Hammemi B, Maaloul I, Ben Jmaa M, Abid M. [Pituitary tuberculosis: a case report]. *Ann Endocrinol (Paris)*, 66, 340–346, 2005.