


DE GRUYTER  
OPEN**Current Issues in Pharmacy and Medical Sciences**

Formerly ANNALES UNIVERSITATIS MARIAE CURIE-SKŁODOWSKA, SECTIO DDD, PHARMACIA

journal homepage: <http://www.curipms.umlub.pl/>

# Hepatic stellate cells activation and liver fibrosis after chronic administration of ethanol

KATARZYNA KOT-BAKIERA, EWELINA WAWRYK-GAWDA, BEATA CICHACZ-KWIATKOWSKA,  
BARBARA JODLOWSKA-JEDRYCH

Chair and Department of Histology and Embryology with Experimental Cytology Unit, Medical University of Lublin, Radziwillowska 11, 20-080 Lublin, Poland

## ARTICLE INFO

Received 12 January 2016  
Accepted 02 March 2016

### Keywords:

hepatic stellate cells,  
liver,  
ethanol,  
fibrogenesis,  
desmin.

## ABSTRACT

Hepatic stellate cells (HSC) are a nonparenchymal population of liver cells. In normal conditions, they store vitamin A, control the turnover of the extracellular matrix, and regulate the contractility of the sinusoids. Acute and chronic damage such as that brought about by alcohol activates the stellate cells and they are then responsible for the liver's inflammatory fibrotic response. Hence, alcohol consumption leads to hepatitis, steatosis, fibrosis and cirrhosis of liver by way of different mechanisms depending on effect upon the nonparenchymal cells of the liver.

The aim of our study was to assess the histological changes in the liver of rats after chronic alcohol consumption. In our work, we evaluated the intensity of liver fibrosis and the number of Kupffer cells and active hepatic stellate cells present within a test population. In the experiment, we used 10 Wistar rats of 250 gram weight. The animals were placed within one of two groups: A (experimental) and C (control). Group A received alcohol for 4 weeks, while group C received just water. The rats of both groups were decapitated 24 hours after the end of the experiment. The samples of liver were then evaluated after H&E, Masson's trichrome staining and an immunohistochemical reaction to desmin (a marker of quiescent HSC) and  $\alpha$ -smooth muscle actin (marker of active HSC) antibody. In our work, we observed intensive fibrosis in the portal spaces and perivenular areas in group A samples. Moreover, Kupffer cells and stellate cells with positive  $\alpha$ -SMA expression were more numerous in group A than in the group C, and these correlate with the area of intensive fibrosis. The expression of desmin in the HSC was seen in both groups to a similar level.

Conclusion: Chronic alcohol consumption activates the transdifferentiation of hepatic stellate cells into the positive  $\alpha$ -SMA myofibroblast-like cells which are responsible for fibrogenesis.

## INTRODUCTION

Chronic intake of ethanol may result in alcoholic liver disease (ALD) on the part of the alcoholic. The catch-all term ALD includes simple steatosis, alcoholic hepatitis, fibrosis, cirrhosis and hepatocellular carcinoma [1,12]. Alcohol-related liver damage is mediated through different processes, for example, generation of harmful substances and reactive oxygen species (ROS) in the local milieu. Furthermore, alcohol abuse increases the multiplication of intestinal bacteria and changes the intestinal permeability

for macromolecules. The increase in bacterial toxins and endogenous mediators activates hepatic macrophages called Kupffer cells, and the pro-inflammatory M2 phenotype of Kupffer cells produces ROS and other pro-inflammatory cytokines [1,20,21,26]. Besides the Kupffer cells, hepatic stellate cells and sinusoidal endothelial cells (SEC) also contribute to ALD. SEC demonstrate endocytic capacity for many substances such as glycoproteins and components of extracellular matrix (ECM). They also secrete cytokines, eicosanoids, nitric oxide and components of ECM. Hepatic stellate cells (HSC) reside in the space of Disse between hepatocytes and sinusoidal endothelial cells [15,18]. They take part in the development, regeneration,

### \* Corresponding author

e-mail: ewelina.wawryk@wp.pl,  
tel. 508191144

xenobiotic responses and immunoregulation of the liver. HSC also regulate the vitamin A metabolism, and they uptake and release retinol depending on the body's retinol status [17]. Acute and chronic liver damage activates the transformation of HSC into myofibroblast-like cells which are responsible for the excess synthesis of ECM components [15,17]. Activated HSC lose their intracellular lipid droplets, forming multiple microfilaments that consist of  $\alpha$ -smooth muscle actin ( $\alpha$ -SMA). Trans-differentiated HSC intensively produce type I and type III collagen and show the low activity of matrix metalloproteinases that is the cause of liver fibrosis [11,14].

In our study, we assess the intensity of liver fibrosis after ethanol intoxication, as well as the correlation between localization of  $\alpha$ -SMA positive hepatic stellate cells and the area of intensive fibrosis.

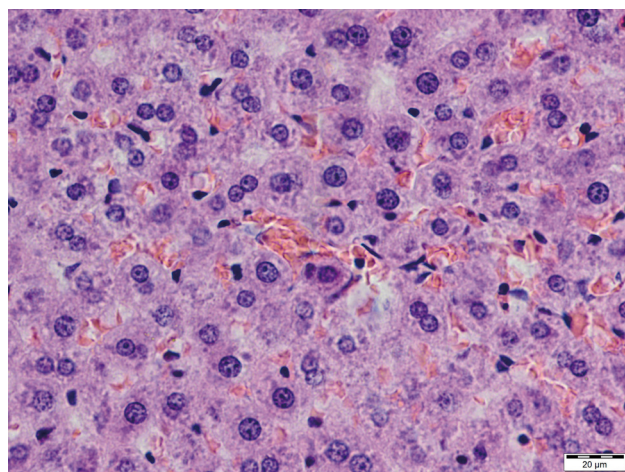
## MATERIAL AND METHODS

The study were carried out on male Wistar rats of 250g weight, and during the experiment, all animals received standard food. The animals were randomly assigned to either experimental (A) or the control (C) group. The animals of the control group received to drinking just water ad libitum, while the animals of the experimental group received to drinking 20% ethanol without restrictions. They drank about 2 ml of alcohol/animal/day. After four weeks of the study, the animals were decapitated and samples of liver were taken. This material was fixed in Baker solution and stained with hematoxylin and eosin, and by Masson's trichrome method. Immunohistochemical staining was undertaken utilizing monoclonal antibodies against desmin and alpha smooth muscle actin (of DAKO Company) by way of the peroxidase method. The exposure of the antigenic sites was performed thermally by incubation in citrate buffer solution with pH= 6, in a microwave oven at 800W, for 3 cycles lasting 5 minutes each. To inhibit endogenous peroxidase activity, 0.3% perhydrol (H2O2) in methanol was employed, and Normal Serum was utilized to block the nonspecific bindings of antigen. The slices were incubated in a primary antibody diluted as recommended by the manufacturer (1:100) overnight at 4°C. To visualize the reaction, DAB chromogen and hematoxylin staining was undertaken. In the negative control, staining was conducted in a similar manner, but this omitted the specific primary antibody. The material was evaluated with the use of a light microscope at 200x and 400x magnification by way of the BX4 image analysis system manufactured by Olympus, with a DP 25 digital camera and the CellSens Standard software. The experiment was carried out according to the National Institute of Health Guidelines for the care and use of laboratory animals and the European Council Directive on 24 November 1986 for Care and Use of Laboratory Animals (86/609/EEC), and was approved by The Ethical Commission of the Medical University of Lublin (No. 23/2000).

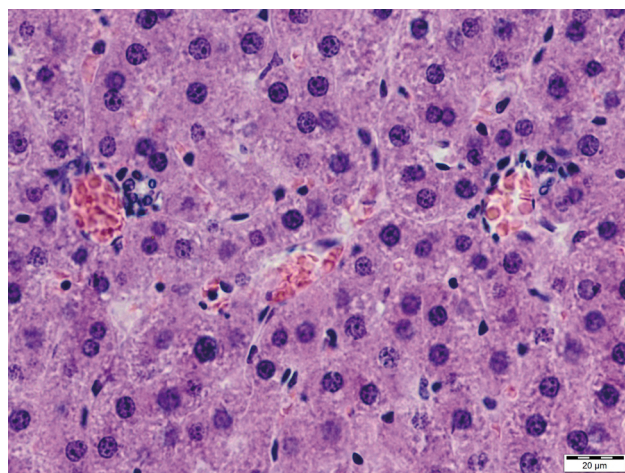
## RESULTS

### H&E staining

We observed normal liver architecture in both groups, but in the experimental group, we noticed that normal liver tissue was replaced with fibrosis. Herein, hepatocytes were located around the central veins and formed plates radiating from it. What is more, their cytoplasm showed an affinity for acidic dyes and contained an evenly-spaced granularity. These hepatocytes also contained one or two spherical nuclei with chromatin matrix and nucleoli. Between the hepatocytes, we saw sinusoids with small amounts of erythrocytes. In the experimental group, as well, in the wall of the sinusoids, we observed numerous Kupffer cells, whereas in the control group, just a few Kupffer cells were evident. Furthermore, in the liver samples from group A, we observed individual hepatocytes with very large nuclei and with inflammatory infiltrates. These are located around the central veins and the hepatic triad. Moreover, in some parts of the liver lobules, we noticed areas of hyperaemia and steatosis that were accompanied by biliary ducts proliferation [Fig. 1 and Fig. 2].



**Figure 1.** Experimental group (A). Hyperaemia. Numerous Kupffer cells. H&E staining (Magn. ca 400x)

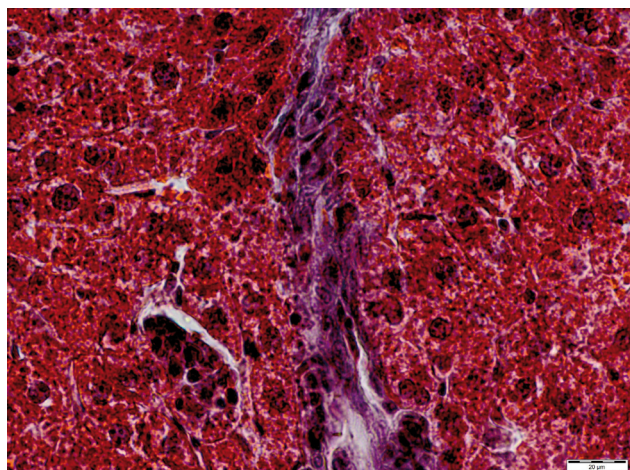


**Figure 2.** Experimental group (A). Hyperaemia. Biliary ducts proliferation. H&E staining (Magn. ca 400x)

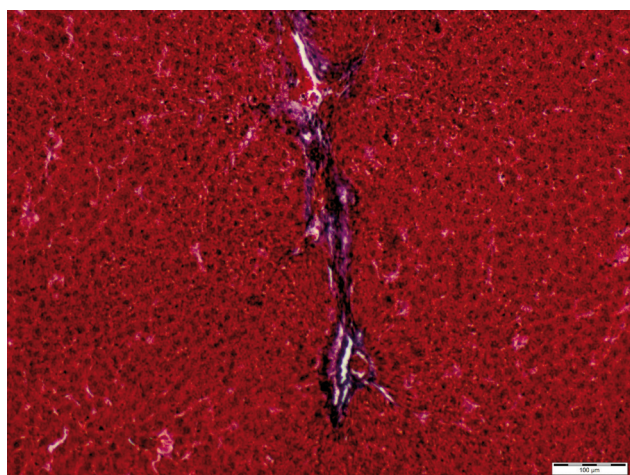


### Masson's trichrome and immunohistochemical staining

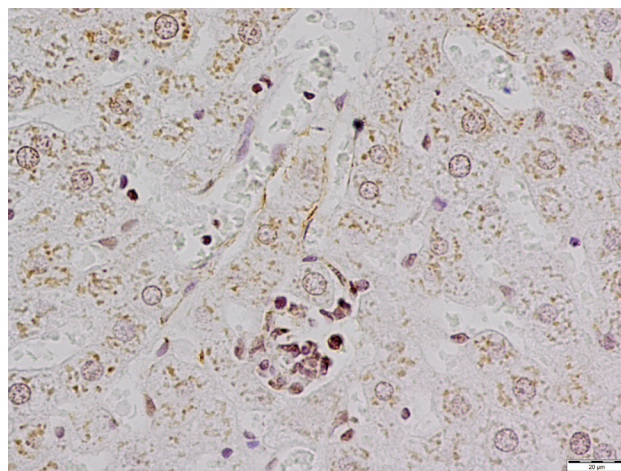
In this experiment, we observed intensive fibrosis in the portal spaces and in the perivenular areas within samples drawn from group A (Fig. 3 and Fig. 4). In addition, hepatic stellate cells with positive  $\alpha$ -SMA expression were more numerous in this group than in the control group, and these correlate with the areas of intensive fibrosis (Fig. 5 and Fig. 6). The expression of desmin in the HSC was positive in individual cells of liver of both groups, and this at a similar level (Fig. 7 and Fig. 8). Herein, cells with positive anti-desmin reaction were observed mainly in the perisinusoidal spaces.



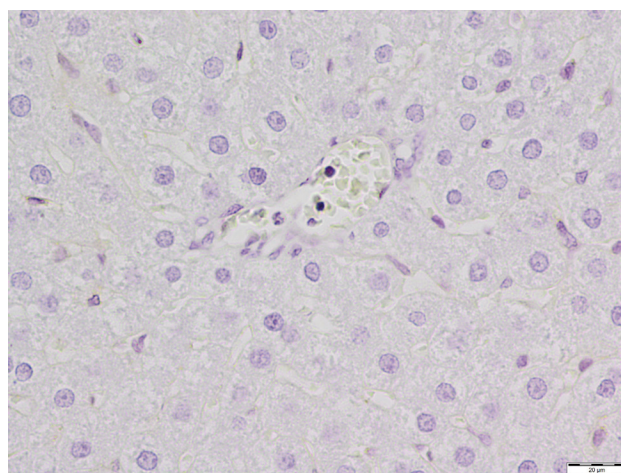
**Figure 3.** Experimental group (A). Fibrosis in the area of the portal space. Masson's trichrome staining (Magn. ca 400 $\times$ )



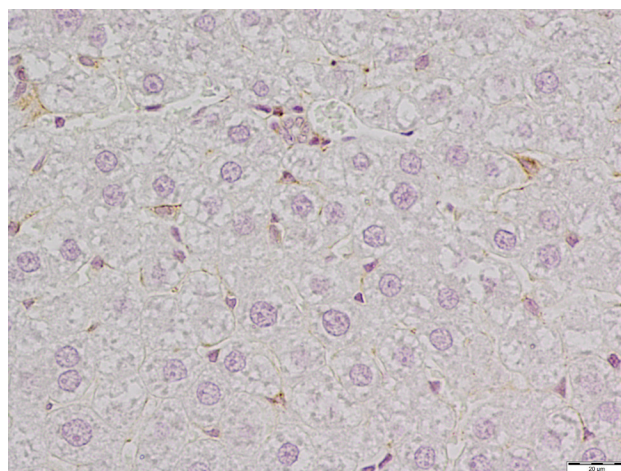
**Figure 4.** Experimental group (A). Fibrous septa formed bridges between central veins and portal spaces. Masson's trichrome staining (Magn. ca 200 $\times$ )



**Figure 5.** Experimental group (A). Anti- $\alpha$ -SMA positive reaction in the active stellate cells located in the area of the portal space. Immunohistochemical staining (Magn. ca 400 $\times$ )

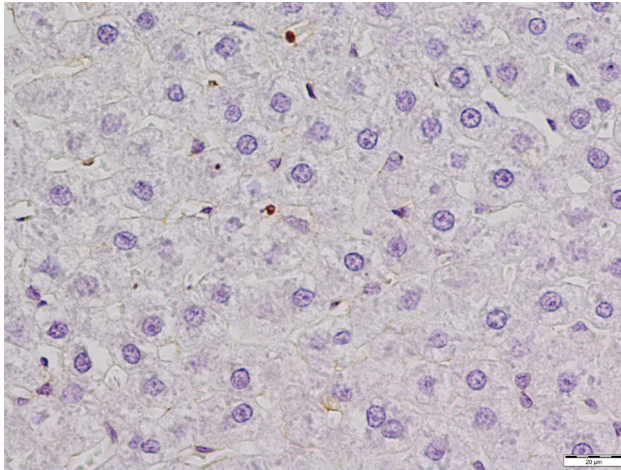


**Figure 6.** Control group (C). Anti- $\alpha$ -SMA slight immunoreactivity in normal liver tissue. Immunohistochemical staining (Magn. ca 400 $\times$ )



**Figure 7.** Experimental group (A). Anti-desmin immunoreactivity in the hepatic stellate cells. Immunohistochemical staining (Magn. ca 400 $\times$ )





**Figure 8.** Control group (C). Anti-desmin positive reaction in the hepatic stellate cells. Immunohistochemical staining (Magn. ca 400×)

## DISCUSSION

Fibrosis of the liver is the cellular response to chronic disease and to exposure to harmful factors. This effect can lead to irreparable changes in the liver structure [15]. The cells regulating the production and the degradation of the extracellular matrix components are responsible for this fibrogenesis, and the hepatic stellate cells play a main role in liver fibrosis. When the liver is damaged, these cells transdifferentiate from the resting vitamin A-rich cells into active, proliferating, fibrogenic and contractile cells. Yet, different pathways of HSC activation in alcoholic liver disease have been reported [12,18,19]. In the study of Page *et al.*, the authors demonstrated that ethanol intake directly stimulates global changes in the HSC chromatin structure. This, consequently, increases the expression of ECM proteins in the hepatic tissue [19]. However, there are numerous factors produced by damaged hepatocytes, Kupffer cells, sinusoidal endothelial cells and another cells migrating to the liver, and these are also responsible for HSC transdifferentiation [18, 19]. The hepatic ethanol metabolism, which is dependent upon cytochrome P450 isoform CYP2E1 induction, generates acetaldehyde and increases the concentrations of reactive oxygen species (ROS) which play key roles in the oxidative stress and the increase of lipid peroxidation [2,4,8,9,13,24,25] seen in ALD. It is known that oxidative stress is an important signal for the activation of Kupffer cells and of the stellate cells [24, 25]. Moreover, activated HSC lose their anti-oxidative activity, hence, this brings about a decrease in tissue protection. Tsukamoto *et al.* revealed that oxygen free radicals also have an effect on the fluidity of cell membranes by lipid peroxidation. As the result of this process, intermediate products such as malonyldialdehyde (MDA), and 4-hydroxynonenal (4HNE) are generated which directly affect the activation of Kupffer cells [24]. The end-product of ethanol degradation, namely acetaldehyde, is the key toxin in alcohol-mediated liver injury, as this chemical directly induces hepatocytes damage and apoptosis, hepatic inflammation response and ECM remodeling [12]. Moreover, this metabolite forms adducts with protein and with the DNA of hepatocytes,

impairs microtubules, decreases protein secretion and brings about ballooning of the hepatocytes [1]. Furthermore, active Kupffer cells phagocytose apoptotic bodies, and this effect can lead to the increase of serum levels of caspase-digested cytokeratin-18 fragments. This effect constitutes one of the factors in predicting fibrosis in patients with liver disease [12]. In regard to the activated parenchymal cells of liver release cytokines, such as PDGF (platelet derived growth factor), TGF- $\beta$ 1 (transforming growth factor  $\beta$ 1), TNF- $\alpha$  (tumor necrosis factor- $\alpha$ ) and IL-6 (interleukin-6), among these, TGF- $\beta$ 1 is the critical factor stimulating the transdifferentiation of quiescent HSC into fibrogenic active stellate cells, by way of the suppression of their degradation and the stimulation of the ECM components, especially collagen I fibers [11,18,20,21]. TGF- $\beta$ 1 is also produced by HSC, and this effect increases the number of active stellate cells in the paracrine and autocrine pathway. This brings about the increase of hepatocytes damage and inflammatory infiltration [11,15]. The resulting multiple microfilaments are located in the activated stellate cells, and consist of  $\alpha$ -smooth muscle actin. Thus, the immunoreactivity of this protein can be a reliable marker of HSC activation, as well as hepatic fibrosis identification [6,11,23]. In our study, we observed a positive reaction against  $\alpha$ -SMA in the cells of different shapes located in the perivenular area and in the portal spaces of the liver samples obtained from the experimental group. What is more, round cells displaying positive reaction against desmin, the marker of quiescent HSC, were located in the perisinusoidal spaces of Disse in the liver of both groups. The localization of the active cells correlates with the fact that thick connective tissue fibers form bridges between the hepatic triads and the central veins. Our results are similar to the results of Ionescu *et al.*, wherein the main concern was about the histopathological changes of the liver of patients with chronic viral hepatitis C. The present research, and that of Tomanovic *et al.* and Carpino *et al.*, demonstrates that the localization and the stage of fibrosis and cirrhosis correlate with the number and accumulation of  $\alpha$ -SMA positive cells [6,14,23]. We put forward that stellate cells concentration in the injured area is dependent upon the chemotaxis stimulated by cytokines such as PDGF, monocyte chemotactic protein (MCP-1), and the chemokine receptor CXCR3. Moreover, within the damaged area, chemotaxis is inhibited and the HSC are kept intact [15]. These results are confirmed by another study which explains the role of hepatic stellate cells in the liver fibrosis that is induced by different diseases [2,7,10,13,22]. HSC activated by liver injury increase ECM synthesis, and in the early stages of fibrosis, an accumulation of fibronectin and types III and IV collagen may be observed. Researchers have reported that liver fibrosis is accompanied by increased levels of synthesis of type I and type IV fibrillar collagen and elastin [5]. Simultaneously, active HSC stimulate the expression of tissue inhibitors of matrix metalloproteinases (TIMP-1 and TIMP-2), and this effect leads to the alteration of the balance between the production and degradation of ECM components, as well as its accumulation in the hepatic tissue [14]. Regression of liver fibrosis depends on the inactivation and apoptosis of hepatic stellate cells [16]. However, TIMP-1 inhibits HSC apoptosis, consequently,

increasing their number in the damaged area [15]. Besides fibrosis, HSC are closely associated with alcoholic liver steatosis and the immune responses expressed by the production of endocannabinoids and the presence of antigen and molecules [21]. HSC also directly interacts with the immune cells (the NK cells and T lymphocytes) and play a role in the liver diseases related to immune responses [21].

## CONCLUSION

The hepatic stellate cells play an important role in the fibrosis of a liver damaged by alcohol intake. In such a situation, the fibrosis stage and localization correlates with HSC activation. Since, the factors which inhibit stellate cells apoptosis lead to an increase of liver damage, substances which inactivate HSC could be effective in liver fibrosis protection.

## ACKNOWLEDGEMENTS

The authors do not declare any relationships (conflict of interests) that could affect the objectivity and credibility of the work.

## REFERENCES

- Ajakaiye M et al.: Alcohol and hepatocyte-Kupffer cell interaction (review). *Mol Med Rep.*, 4,4, 2011: 597-602, doi: 10.3892/mmr.2011.471.
- Bąk M. et al.: Toksyczne uszkodzenie wątroby - współczesny pogląd na etiopatogenezę. Część I. (Toxic liver injuries - a current view on pathogenesis. Part I. *Medycyna Pracy*, 62,1, 2011:47-55.
- Bioulac-Sage P., Balabaud Ch.: Proliferation and phenotypic expression of perisinusoidal cells. *Journal of Hepatology*, 15, 1992: 284-287.
- Britton R.S., Bacon B.R.: Role of free radicals in liver diseases and hepatic fibrosis. *Hepatogastroenterology*, 41, 4, 1994: 343-348.
- Burt AD, et al.: Ultrastructural localization of extracellular matrix proteins in liver biopsies using ultracycromicrotomy and immunogold labelling. *Histopathology*, 16,1, 1990:53-58.
- Carpino G et al.: Alpha-SMA expression in hepatic stellate cells and quantitative analysis of hepatic fibrosis in cirrhosis and in recurrent chronic hepatitis after liver transplantation. *Dig Liver Dis.*, 37, 5, 2005: 349-356.
- Chedid A. et al.: Prognostic factors in alcoholic liver disease. VA Cooperative Study Group. *Am J Gastroenterol.*, 86, 2,1991: 210-216.
- Conde de la Rosa L., Moshage H., Nieto N.: Hepatocyte oxidant stress and alcoholic liver disease. *Rev Esp Enferm Dig.*, 100, 2008:156-163.
- De Minicis S., Brenner D.A.: Oxidative stress in alcoholic liver disease: role of NADPH oxidase complex. *J Gastroenterol Hepatol.*, 23, 1, 2008: S98-S103.
- Flisiak R., Wiercińska Drapała A., Tynecka E.: Transforming growth factor beta in pathogenesis of liver diseases. *Wiad Lek.*, 53, 9-10, 2000:530-537.
- Friedman S.L.: Hepatic stellate cells: protean, multifunctional, and enigmatic cells of the liver. *Physiol Rev.*, 88, 1, 2008: 125-172, doi: 10.1152/physrev.00013.2007.
- Fujii H., Kawada N.: Fibrogenesis in alcoholic liver disease. *World J Gastroenterol.*, 7, 20, 25, 2014: 8048-8054. doi: 10.3748/wjg.v20.i25.8048.
- Gressner A.M.: Transdifferentiation of hepatic stellate cells (Ito cells) to myofibroblasts - a key event in hepatic fibrogenesis. *Kidney Int Suppl.*, 54, 1996: S39-S45.
- Ionescu A.G. et al.: Histopathological and immunohistochemical study of hepatic stellate cells in patients with viral C chronic liver disease. *Rom J Morphol Embryol.*, 54,4, 2013:983-991.
- Kasztelan-Szczerbińska B. et al.: Komórki gwiazdźdźiste jako główny regulator sygnalizacji międzykomórkowej w procesie włóknienia wątroby. (Stellate cells as a central regulator of intracellular signaling in the process of liver fibrosis). *Postępy Nauk Medycznych*, 1, 2010:69-74.
- Kisseleva T. et al.: Myofibroblasts revert to an inactive phenotype during regression of liver fibrosis. *Proc Natl Acad Sci U S A*, 12,109, 24, 2012: 9448-9453,doi: 10.1073/pnas.1201840109.
- Kmieć Z.: Cooperation of liver cells in health and disease. *Adv Anat Embryol Cell Biol.*,161, III-XIII, 2001: 1-151.
- Mormone E., George J., Nieto N.: Molecular pathogenesis of hepatic fibrosis and current therapeutic approaches. *Chem Biol Interact.*, 30, 193, 3, 2011:225-231, doi: 10.1016/j.cbi.2011.07.001.
- Page A. et al.: Alcohol directly stimulates epigenetic modifications in hepatic stellate cells. *J Hepatol.*, 62, 2, 2015: 388-397, doi: 10.1016/j.jhep.2014.09.033.
- Plewka K., Szuster-Ciesielska A., Kandefer-Szerszeń M.: Rola komórek gwiazdźdźistych w procesie alkoholowego włóknienia wątroby (Role of stellate cells in alcoholic liver fibrosis) *Postępy Hig Med Dosw.*, 63, 2009: 303-317.
- Suh Y.G., Jeong W.I.: Hepatic stellate cells and innate immunity in alcoholic liver disease. *World J Gastroenterol*, 28,17,20, 2011: 2543-2451, doi: 10.3748/wjg.v17.i20.2543.
- Szantova M., Kupcova V.: Biochemical markers of fibrogenesis in liver diseases. *Bratisl Lek Listy*, 100,1, 1999: 28-35.
- Tomanovic N.R. et al.: Activated liver stellate cells in chronic viral C hepatitis: histopathological and immunohistochemical study. *J Gastrointestin Liver Dis.*, 18, 2, 2009: 163-167.
- Tsukamoto H. et al.: Roles of oxidative stress in activation of Kupffer and Ito cells in liver fibrogenesis. *J Gastroenterol Hepatol.*, 10, 1, 1995:S50-S53.
- Tsukamoto H.: Oxidative stress, antioxidants and alcoholic liver fibrogenesis. *Alcohol.*, 10,6, 1993:465-467.
- Wan J. et al.: M2 kupffer cells promote hepatocyte senescence: an IL-6-dependent protective mechanism against alcoholic liver disease. *Am J Pathol.* 184,6, 2014:1763-1772, doi: 10.1016/j.ajpath.2014.02.014.