


DE GRUYTER
OPEN

Current Issues in Pharmacy and Medical Sciences

Formerly ANNALES UNIVERSITATIS MARIAE CURIE-SKŁODOWSKA, SECTIO DDD, PHARMACIA

journal homepage: <http://www.curiipms.umlub.pl/>

Littoral cell angioma mimicking metastatic tumors

JUSTYNA SZUMILO¹, ANNA OSTROWSKA^{1*}, MALGORZATA ZDUNEK¹, SŁAWOMIR RUDZKI²,
TOMASZ CHROSCICKI³, ELZBIETA CZEKAJSKA-CHEHAB⁴, FRANCISZEK BURDAN³¹ Chair and Department of Clinical Pathology, Medical University of Lublin, 8b Jaczewskiego, 20-090 Lublin, Poland² Chair and Department of General and Transplant Surgery and Nutritional Treatment, Medical University of Lublin, 8 Jaczewskiego, 20-954 Lublin, Poland³ Chair and Department of Human Anatomy, Medical University of Lublin, 4 Jaczewskiego, 20-090 Lublin, Poland⁴ 1st Department of Radiology, Medical University of Lublin, 8 Jaczewskiego, 20-954 Lublin, Poland

ARTICLE INFO

Received 05 October 2015
Accepted 03 November 2015**Keywords:**littoral cell angioma,
spleen,
splenic tumor,
splenic metastasis.

ABSTRACT

Littoral cell angioma is a rare primary, vascular tumor thought to originate from the endothelial cells lining the sinuses of the splenic red pulp (the "littoral cells"). It is a benign, usually asymptomatic lesion diagnosed incidentally. Ultrasound and tomography appearance is not characteristic and histopathological examination is required. This work provides a case-study of littoral cell angioma which was seen in a 55-year-old female who complained of non-specific upper abdominal pain. Computed tomography revealed multiple hypo-attenuated splenic lesions suggestive for metastasis. A splenectomy was performed and routine microscopic examination supported by immunohistochemistry reactions with CD68, CD34 and CD31 showed littoral cell angioma.

INTRODUCTION

Littoral cell angioma (LCA) is a rare primary splenic vascular tumor thought to originate from the red pulp sinus lining cells (the "littoral cells"). Like normal littoral cells, those deemed neoplastic show double endothelial and histiocytic differentiation based on immunohistochemical reactions. LCA is regarded as a benign lesion, but rare cases of malignant clinical course have been described [4]. It is more likely, however, that at least some of these cases were rather underdiagnosed angiosarcomas than typical LCAs. Nevertheless, recently, a strong association of LCA with many true malignancies has been reported [8], therefore, accurate diagnosis of LCA is important, and a long follow-up should be a standard procedure for patients with the tumor.

CASE REPORT

A new case of littoral cell angioma mimicking metastases to the spleen has been reported.

Herein, a 55-year-old female was admitted to the Department of General and Transplant Surgery and Nutritional Treatment, Medical University of Lublin, because of multiple low contrast-enhanced nodules that were revealed

via computed tomography (Fig. 1). She had firstly been referred to the outpatient clinic due to the presence of mild chronic abdominal pain localized in left epigastric area. Her previous medical history was unremarkable except for long term Hashimoto thyroiditis. Therein, laboratory tests revealed thrombocytopenia (90 G/l). In the initial diagnosis, metastatic tumors from an unknown primary lesion was presumed, and the patient underwent splenectomy. Her post-operative course was uneventful.

A macroscopic examination of a surgical specimen performed in the Department of Clinical Pathomorphology, Medical University of Lublin, revealed enlarged spleen (17×12×6 cm) with uneven external surface and increased consistency. The cross section was spongy with multiple, ill-defined mottled nodules (Fig. 2). Routine histopathological examination of multiple tissue samples with hematoxylin and eosin staining, as well as Gomori silver impregnation, showed numerous vascular spaces, partially filled with blood, occasionally with papillary projections (Fig. 3A). These were lined by two types of cells: tall columnar protruding to the lumina of the spaces and externally located flat lining cells (Fig. 3B). The former exhibited features mostly of histiocytic differentiation (CD68+, CD31-, CD34-) (Fig. 4A), whereas the latter demonstrated endothelial differentiation (CD31+, CD34+, CD68-) (Fig. 4B). Diagnosis of littoral cell angioma was then established.

* Corresponding author

e-mail: anna.ostrowska@umlub.pl
tel.: +48 81 448 65 30/32; fax: +48 81 448 65 31

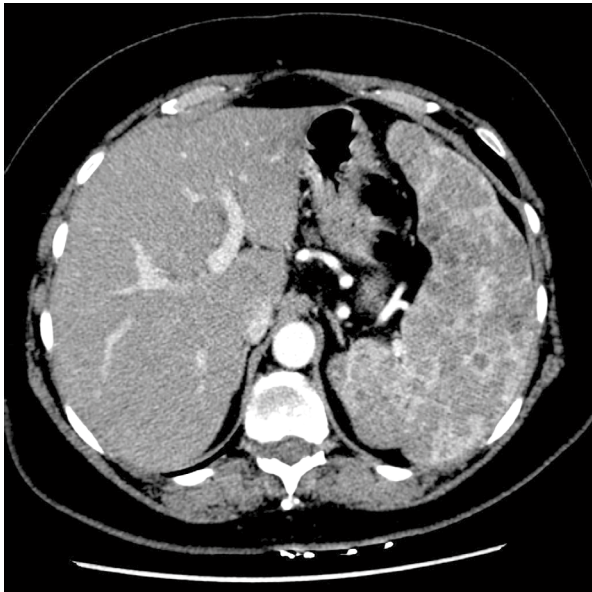


Figure 1. Enlarged spleen of heterogenic structure revealed via low contrast-enhanced CT (post-contrast venal phase)

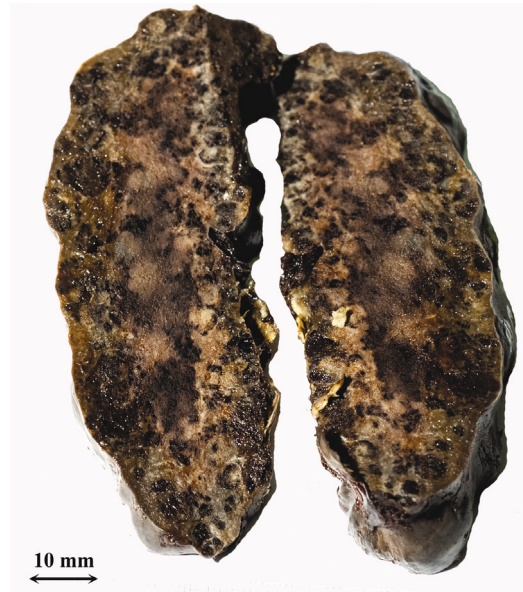
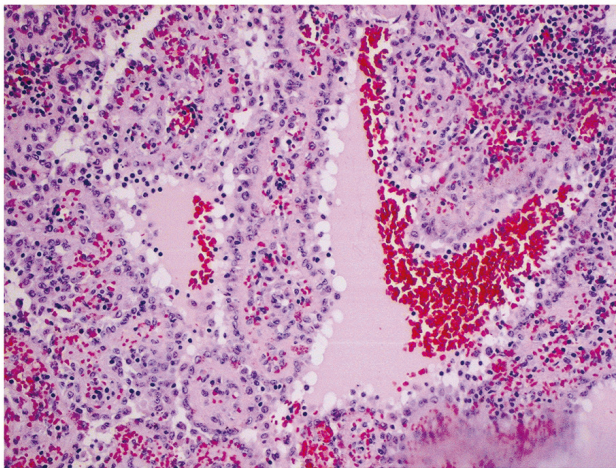
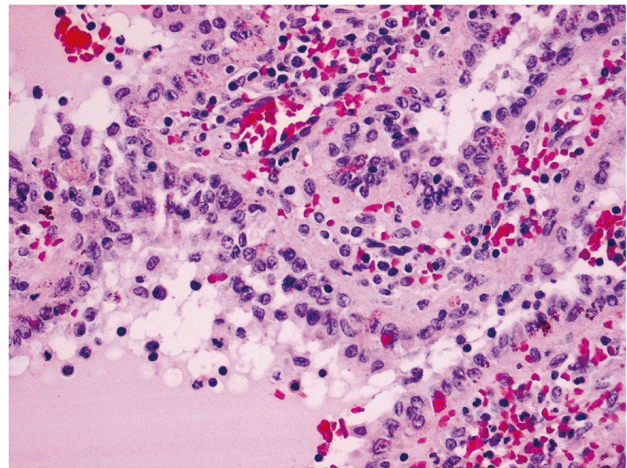


Figure 2. Gross aspect of littoral cell angioma – enlarged spleen with uneven external surface and spongy surface with multiple, ill-defined mottled nodules

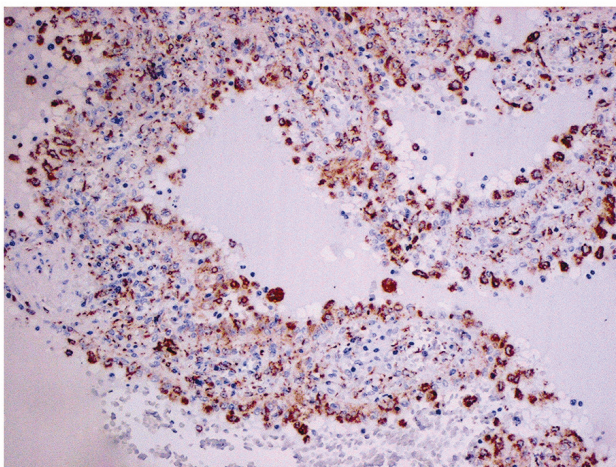


A

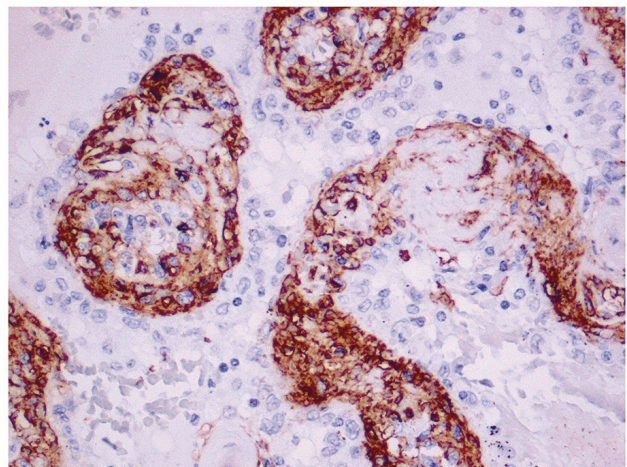


B

Figure 3. (A) Multiple irregular vascular spaces partly filled with blood, in the red pulp of the spleen, (B) lined by two types of cells – tall type protruding into the lumina, and externally located flat type - typical of littoral cell angioma (HE; objective magn. A – 10×; B – 20×)



A



B

Figure 4. Positive immunostaining for (A) CD68 in tall, and (B) CD31 in flat cells of littoral cell angioma (Dako EnVision™/HRP; objective magn. AB – 20×)

DISCUSSION

Littoral cell angioma is a rare benign neoplasm of the spleen that was firstly described by Falk *et al.* [4]. There is no age or gender predilection, although the typical age is about 49 years [4]. It is usually asymptomatic or associated with unspecific signs and symptoms such as chronic abdominal pain, splenomegaly, anemia or thrombocytopenia. Ultrasound or CT scans are not characteristic. LCA is typically seen as multiple nodules, rarely as a solitary lesion [7]. Differential diagnosis includes other benign or malignant splenic vascular neoplasms, among these being hemangioma, sclerosing angiomatous nodular tumor, hemangioendothelioma, Kaposi sarcoma and angiosarcoma, including rare littoral cell angiosarcoma, as well as splenomegaly due to various infections. Metastases to the spleen especially from breast, lung, colorectal, and ovarian carcinomas and melanoma have to be also excluded [3]. To confirm the diagnosis, histopathologic examination is necessary. The malignant potential of this lesion is also unknown, therefore, splenectomy is recommended in each case – both from diagnostic and therapeutic reasons. Many reports indicate the association of LCA with several malignancies, including lymphomas [4], as well as colorectal, pancreatic, renal, hepatocellular and pulmonary adenocarcinomas [1,2,8,11,12]. A coexistence with immune-dysregulation in the course of Crohn's disease [4,8,9], type A and B hepatitis [8] and Gaucher's disease [5,6] was also observed. Since such associations are noted in one third [2] to a half of all cases [8], careful follow-up for a synchronous or metachronous malignancy is recommended for patients with LCA.

REFERENCES

1. Bisceglia M., Sickel J.Z., Giangaspero F. et al.: Littoral cell angioma of the spleen: an additional report of four cases with emphasis on the association with visceral organ cancers. *Tumori.*, 84, 595, 1998.
2. Collins G.L., Morgan M.B., Taylor F.M.: Littoral cell angiomatosis with poorly differentiated adenocarcinoma of the lung. *Ann Diagn Pathol.*, 7, 54, 2003.
3. Comp  rat E. et al.: Splenic metastases: clinicopathologic presentation, differential diagnosis, and pathogenesis. *Arch Pathol Lab Med.*, 131, 965, 2007.
4. Falk S., Stutte H.J., Frizzera G.: Littoral cell angioma. A novel splenic vascular lesion demonstrating histiocytic differentiation. *Am J Surg Pathol.*, 15, 1023, 1991.
5. Forest F. et al.: Traumatic subcapsular splenic hematoma revealing littoral cell angioma and Gaucher's disease. *Ann Hematol.*, 89, 1061, 2010.
6. Gupta M.K. et al.: Littoral cell angioma of the spleen in a patient with Gaucher disease. *Am J Hematol.*, 68, 61, 2001.
7. Gupta P. et al.: Littoral cell angioma of spleen: an uncommon presentation of a rare neoplasm. *J Clin Imaging Sci.*, 2, 69, 2012.
8. Harmon R.L., Cerruto C.A., Scheckner A.: Littoral cell angioma: a case report and review. *Surg.*, 63, 345, 2006.
9. Johansson J., Bj  rnsson B., Ignatova S. et al.: Littoral cell angioma in a patient with Crohn's disease. *Case Rep Gastrointest Med.*, 2015:474969. doi: 10.1155/2015/474969.
10. Liang W. et al.: Littoral cell angioma mimicking hepatic tumor. *Acta Radiol Short Rep.* 2012. doi: 10.1258/arsr.2012.120031.
11. Lin C.H., Yu J.C., Shih M.L. et al.: Littoral cell angioma of the spleen in a patient with hepatocellular carcinoma. *J Formos Med Assoc.*, 104, 282, 2005.
12. Steensma D., Morice W.: Littoral cell angioma associated with portal hypertension and resected colon cancer. *Acta Haematol.*, 104, 131, 2000.