

PROBLEM – SOLVING ARTICLE

Diagnosis and Management of Blunt Pancreatic Trauma in Children

Edgars Zarembos*, Arnis Engelis **, Aigars Petersons**

*Rezekne Hospital, Latvia

**Riga Stradins University, Latvia, University Children's Hospital, Riga, Latvia

Summary

There are still diagnostics problems and variety of opinions about tactics in the treatment of blunt pancreatic injuries. The methods of surgery treatments are more and more replacing the methods of endoscopy and conservative therapy. There is a remarkable difference in the tactic of treatment between adults and children because of the anatomical physiological reasons. Delayed diagnosis of this wounding is connected with heightened morbidity and mortality.

Handlebars injury is the most frequent mechanism of the trauma. The most determinant role in the diagnostics has active examination tactic and arsenal of visual diagnostics methods. Therapy approach must be individualized depending from the hemodynamic status, seriousness of injury, existence of associated injuries and the experience in the institution. After traumatic pseudocysts can be successfully drained in US control or endoscopic to stomach. Children with such injuries must be concentrated if possible in the specialized centers.

Key words: children, blunt abdominal trauma, pancreatic trauma, posttraumatic pancreatitis, diagnosticēs, treatment, complications.

Abbreviations: CRP – C-reactive protein, US – ultrasonoscopy, CT – computer tomography, MR – magnetic resonance, ERCP – endoscopic retrograde cholangiopancreatography, AAST – American Association for the Surgery of Trauma.

INTRODUCTION

Although more than 180 years have already passed since the injury of the pancreas in case of a blunt abdominal cavity trauma has been described for the first time (*Travers, 1827*), there are still faced difficulties in diagnostics and diversity in opinions on treatment tactics. In the literature worldwide the opinions on the necessity for a surgical activity still differ (*Stringer, 2005; Mattix, 2007; Wood, 2010*); however, conventional surgical treatment methods are more and more frequently substituted by endoscopic methods and conservative therapy due to broader application of progressive visual diagnostics technologies and development of laboratory examination methods (*Loungnarath, 2001; Kouchi, 2009*). Significant differences in treatment tactics between adults and children have anatomically physiological background. Many researches clearly indicate that the reaction of a child's body to an injury differs from the reaction of an adult's body (*Gaines, 2009; Jobst, 2009*).

Up to 10% of children with a blunt abdominal cavity trauma have pancreatic injuries and the frequency of these occurrences tends to rise (*Matsuno, 2009*). Taking into account the very significant proportion of the trauma mechanism related to a bump to the bicycle handlebar and adoption of bicyclists' traditions of the "old Europe" in Latvia, considering our road infrastructure and drivers' intelligence, the future does not look like careless. The clinical scene and laboratory examinations during the first hours after the injury can be inconclusive. Diagnostics of traumatic pancreatic injuries is difficult. Delayed diagnostics of these injuries is related to increased morbidity and mortality. The

most frequently observed complications in case of pancreatic injuries are pancreatic fistulas, development of pancreatitis, formation of pseudo-cysts 3–4 weeks after the injury, abscesses (*Jurič, 2009*).

At the child age a blunt abdominal trauma is a leading reason for the injury of the pancreas, on the contrary, adults more often have a penetrating trauma. The pancreas is located retroperitoneal to the spinal column, thus 2/3 of the injury is localized in the body of the pancreas. The vulnerability of child's pancreas has a significant role due to softer tissues and weaker anatomic protection by the anterior abdominal wall and other organs.

A majority of children pancreatic injuries are minor and do not affect the pancreatic duct. In comparison to adults children more frequently have an isolated pancreatic trauma, which probably indirectly indicates greater vulnerability of pancreatic tissues. Probably the fact that children in general lack primary pathology of the pancreas has a crucial role in reaching better treatment results at the child age. An especially frequent trauma mechanism for an isolated injury of the pancreas is a bump by the bicycle handlebar to the anterior abdomen. Neither in publications, nor in our experience we have faced indications that the traumas caused by safety belts could have a significant role in the trauma mechanism.

Diagnosis

Clinical symptoms: abdominal pain, nausea, vomiting are not specific to the injury of the pancreas and do not correlate with the gravity of the injury (*Bosboom, 2006*). Laboratory examinations helping to diagnose (amilasis, lipasis) are non-specific and their indicators significantly

differ depending on the time of taking samples. Although there are described cases of adult traumas, when amylase have been normal having complete rupture of the pancreas and in some situations the indicators have been very high having slight contusions of the pancreas, the patients at the child age practically in 100% of cases have increased these laboratory indicators 2–3 hours after the injury (adults in 50–80% of cases) (Wittendorff, 2002; Matsuno, 2009). For children having a blunt abdominal trauma the increase of the serum amylase level above 200 and the lipase level above 1800 can indicate the injury of the pancreatic duct, the data about the increasing dynamics of these indicators can be especially useful (Nadler, 1999; Mayer, 2002; Adamson, 2003). Overall we consider that the available laboratory examinations cannot be applied for the gradation of the gravity of the injury; moreover, they cannot determine the therapeutic tactics, however, increased indicators of amylase and lipase can be considered as an indicator of possible pancreatic injury in case of a blunt abdominal trauma. The current researches on cytokines and oxidative stress (Pereda, 2006; Caronna, 2009; Escobar, 2009) can significantly increase surgeon's rely on laboratory examinations in the selection of tactics for treatment in the future.

Although in the literature significant attention is devoted to the latest US examination methods by application of contrasting, and they definitely remain as irreplaceable screening for any blunt abdominal trauma (Chirdan, 2007; Valentino, 2009), CT has a leading role in diagnostics of children intra-abdominal injuries by its 80% sensitivity and specificity (Ruszinko, 2000). If CT is performed early (<12 hours after the trauma), the obtained results can be insufficient because time is needed to visualize the changes of soft tissues (Smith, 1996; Wittendorff, 2002).. Direct indications of CT to the pancreatic injury are rupture or transection. It is often possible to visualize communication of fluid collections such as hematomas, pseudo-cysts, abscesses with the location of the pancreatic injury. The injury of the pancreas can be indicated by fluid in the lesser sac, extraperitoneal fluid, pancreatic edema or hematoma, thickening of anterior renal fascia or fluid in anterior pararenal space, and fluid between splenic vein and pancreas (Visrutaratna, 2008). However, the precision of CT is not always sufficient to diagnose the injury of the pancreas duct; quite often in CT there are described injuries of the pancreas duct, which are not confirmed by ERCP contrast examination. Obviously the main drawback of CT is children's exposure to substantial radiation.

Timely identification of the injuries of the pancreas duct is very important among adult patients, where more active surgical tactics is needed. In this case MR and ERCP shall be applied. ERCP identifies the duct injury or may preclude surgery if the ductal system is intact; its use is controversial. ERCP disposes patients to the risk of increasing morbidity (pancreatitis 3–14%, intra-abdominal fluid collection infection risk 10%) (Putnam, 1991; Brown, 1993; Rescorla, 1995).

Management

Children's pancreas injury therapy must be individual depending on the status of hemodynamics, gravity of injury, existence of associated injuries, as well as diagnostic and therapeutic equipment available at the institution, amassed experience must be taken into consideration as well (Fig.1., Table 1).

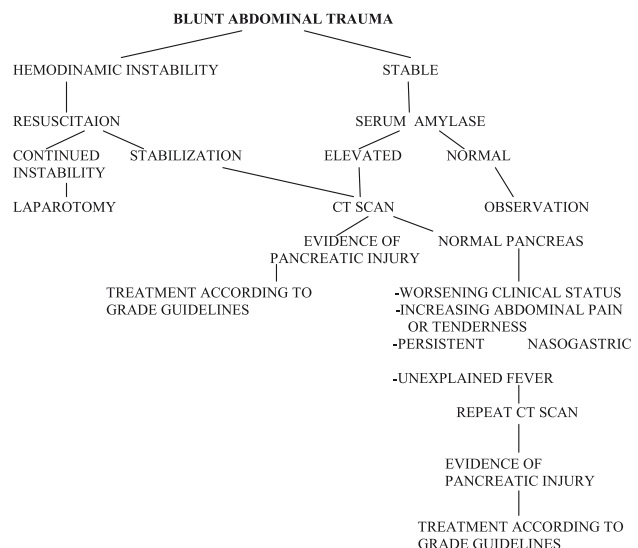


Fig. 1. The diagnostic approach to the patient with a suspected pancreatic injury

Table 1. Treatment according to pancreatic injury severity grade (AAST)

Grades	Injury	Management
I	Minor contusion or laceration without ductal injury	Do not require surgical intervention
II	Major contusion or laceration without a ductal injury	
III	Distal transection or parenchymal injury with ductal injury	May be treated nonoperative or with spleenpreserving distal pancreatectomy and drainage
IV	Proximal transection or injury involving duct or ampulla	May be surgically managed by distal pancreatectomy, internal
V	Massive disruption of the pancreatic head	enteric drainage, or wide external drainage; however, nonoperative management has also been described with acceptable outcomes

Nonoperative management of low-grade pancreatic injury is widely accepted. Management of major pancreatic parenchymal or ductal injury in children remains controversial.

The key to successful conservative treatment of a severe pancreatic injury among children is percutaneous

drainage of pseudo-cysts under US or CT control or by ERCP. Although many publications (*Shilyansky, 1998; Firstenberg, 1999; Wales, 2001; Shaked, 2003*) inform about successful conservative treatment of pancreatic injuries of III – IV degree, it requires detailed visual diagnostics and monitoring, which are possible only in well-equipped clinics having amassed experience. In general pancreatic injuries of the highest degree more often eventually require surgical treatment. Evidentiary there are benefits for application of a minimal invasive surgery for treatment of III–IV degree injuries, however, the value of a laparoscopic surgery shall be assessed very critically in each individual case, especially if there are injuries of the hollow organs, diaphragm, bile-ducts. Unstable hemodynamics requires conventional surgical intervention. During any surgery it is crucial to try to keep the spleen and use closed output drains, thus, relevantly reducing the risk of infection.

Antibacterial therapy shall be started for the patients without priory identified increased risk of infection (non-performed invasive manipulations, non-identified injuries of other organs, satisfactory intestinal passage) when inflammatory markers increase (leucocytosis, CRP). There is still a discussion on prophylactic usage of antibiotics or their usage upon clinical indications for the patients having pancreatic injuries; however, more and more convincingly doctors are expected to start prophylactic therapy of antibiotics only in cases of serious injuries having a high risk of infection (*Fritz, 2008*). In less serious cases there is used *ampicilin* or a combination of *ampicilin/gentamicin*, for more serious traumas there are used *cefuroxime*, *ceftazidime*, *ciprofloxacin*, their combination with *amikacin*, *metronidazol* or *imipenem*, *meropenem* monotherapy. Researches show that these medicines (*cefuroxime*, *ceftazidime*, *ciprofloxacin*, *imipenem*, *meropenem*) reduce the incidence of septic complications due to an opportunity to create high concentration in pancreatic tissues and necroses (*Pederzoli, 1993; Powell, 1998; Parakh, 2009*). Early enteral probe feeding (jejunum) has a crucial role in prevention of septic complications as it strengthens the intestinal mucous membrane, normalizes intestinal transit and protects retroperitoneal tissue and systemic blood circulation from bacteria. Although the usefulness of applying somatostatine (*octreotid*) is still being discussed (*Amirata, 1994; Nwariaku 1995; Sami El-Boghdadly, 2000*); we consider that reduction of pancreatic secretion can decrease the risk of pancreatic fistula development or facilitate their faster closure. We consider prolonged epidural anesthesia to be a useful element of the complex therapy.

Although cholecystostomy has been actively proposed as a routine method to relieve bile-ducts in cases of pancreatic injuries, especially for adult patients [*Wilson, 1967*], nowadays its physiological rationality remains unclear and this method has few supporters. After it bile-stones can appear.

Taking into consideration complicated clinical diagnostics and possible imprecision of laboratory and X-ray diagnostics, any patient of a child age having a

blunt abdominal injury, especially in case of a possible pancreatic injury, shall be hospitalized into the Intensive Therapy Department during the first 24 hours, where careful monitoring and examinations in dynamics shall be performed to identify a more precise diagnosis, a degree of gravity of the injury and a possible need for surgical treatment.

Separate US and CT examinations in dynamics show the reduction of the volume of the pancreas, possible fibrosis. Evidentiary such traumas anatomically cannot be without consequences; however, it seems that compensatory mechanisms at the early age are able to ensure a good pancreatic function. Theoretically intransient consequences of these traumas cannot be excluded; they might appear in adulthood having diseases requiring a compensatory pancreatic load.

CONCLUSIONS

1. Pancreatic injuries resulting from a blunt abdominal trauma are rare among children. The most frequent trauma mechanism is a bump to the bicycle handlebar.
2. In case of a blunt abdominal trauma active examination tactics and visual diagnostic methods arsenal have a significant role as one cannot forget about possible pancreatic injuries. The US method becomes standard screening; however, CT with intravenous contrasting has a crucial role as it is needed not only for the gradation of the gravity degree of the injury, but also for successful identification of the injuries of other organs and control of the effectiveness of therapy in dynamics.
3. The therapy of children pancreatic injuries shall be individual depending on the status of hemodynamics, gravity of injury, existence of associated injuries and experience of the institution. A majority of pancreatic injuries of I–IV degree of gravity among children can be treated conservatively. Overall the problems, which have appeared, can be successfully solved by application of a laparoscopic method. The need for a conventional surgery is determined to a large extent by unstable hemodynamics and serious injuries of other organs. Broad resections shall be avoided as much as possible. Surgical manipulations in case of pancreatic injuries shall be performed having antibacterial background.
4. Conservative treatment of more serious pancreatic injuries can associate with development of post-traumatic pseudo-cysts, which can resorb spontaneously or be successfully treated by transcuteaneous drainage under US control or be endoscopically drained to the stomach.
5. Individual surgeon's experience in treatment of children pancreatic injuries might be insufficient, thus successful examination and treatment tactics shall be based on the material summarized in publications. Children having such injuries shall be concentrated in specialized centers, which can provide high quality care in children intensive therapy unit and permanent monitoring of experienced children surgeons.

Conflict of interest: None

REFERENCES

- Adamson W., Hebra A., Thomas P. et al. Serum amylase and lipase alone are not cost-effective screening methods for pediatric pancreatic trauma // *J.Pediatr. Surg.*, 2003; 38 (3): 35 – 7
- Amirata E., Livingston D., Elcavage J. Octreotide acetate decreases pancreatic complications after pancreatic trauma // *Am. J. Surg.*, 1994; 168 (4): 345 – 7
- Bosboom D., Braam A., Blickman J., Wijnen R. The role of imaging studies in pancreatic injury due to blunt abdominal trauma in children // *Eur. J. Radiol.*, 2006; 59: 3–7
- Brown C., Werlin S., Greenen J. et al. The diagnostic and therapeutic role of endoscopic retrograde cholangiopancreatography in children // *J.Pediatr. Gastroenterol. Nutr.*, 1993; 17:19 –23
- Caronna R., Benedetti M., Morelli A. et al. Clinical effects of laparotomy with perioperative continuous peritoneal lavage and postoperative hemofiltration in patients with severe acute pancreatitis // *World J. Emergency Surg.*, 2009; 4: 45
- Chirdan L., Uba A., Yiltok S. Paediatric blunt abdominal trauma: challenges of management in a developing country // *Eur.J. Surg.*, 2007; 17 (2): 90 – 5
- Escobar J., Pereda J., Arduini A. et al. Cross – talk between oxidative stress and proinflammatory cytokines in acute pancreatitis; a key role for protein phosphatases // *Curr.Pharm. Des.*, 2009; 15 (26): 3027 – 42
- Firstenberg M., Volsko T., Sivit C. et al. Selective management of pediatric pancreatic injuries // *J. Of Pediatric Surgery*, 1999; 34 (7): 1142–1147
- Fritz S., Hartwig W., Lehmann R. et al. Prophylactic antibiotic treatment is superior to therapy on-demand in experimental necrotising pancreatitis // *Crit. Care*, 2008; 12(6): R141
- Gaines B. Intra- abdominal solid organ injury in children: diagnosis and treatment // *J.Trauma*, 2009; 67 (2): 135
- Jobst M., Canty T., Lynch F. Management of pancreatic injury in pediatric blunt abdominal trauma // *J. Pediatr. Surg.*, 2009; 34 (5): 818 – 824
- Jurič I., Pogorelić Z., Biocić M. et al. Management of blunt pancreatic trauma in children // *Surg. Today*, 2009; 39 (2): 115
- Kouchi K., Tanabe M., Yoshida H. et al. Nonoperative management of blunt pancreatic injury in childhood // *J. Pediatr. Surg.*, 2009; 34 (11): 1736 – 1739
- Mattix K., Tataria M., Holmes J. Pediatric pancreatic trauma: predictors of nonoperative management failure and associated outcomes // *J.Pediatr.Surg.*, 2007; 42 (2): 340
- Matsuno W., Huang C., Garcia N. et al. Amylase and lipase measurements in paediatric patients with traumatic pancreatic injuries // *Injury*, 2009; 40 (1): 66 – 71
- Mayer J., Tomczak R., Rau B. et al. Pancreatic injury in severe trauma: early diagnosis and therapy improve the outcome // *Dig.Surg.*, 2002; 19(4): 291 – 7
- Nadler E., Gardner M., Scall L. et al. Management of blunt pancreatic injury in children // *J. Trauma*, 1999; 47 (6): 1098 – 103
- Nwariaku F., Terracina A., Mileski W. et al. Is octreotide beneficial following pancreatic injury? // *Am. J. Surg.*, 1995; 170 (6): 582 – 5
- Parakh A., Krishnamurthy S., Battacharya M. Ertapenem // *Kathmandu Univ. Med. J. (KUMJ)*, 2009; 7(28): 454 – 60
- Pederzoli P., Bassi C. Randomised multicentre clinical trial of antibiotic prophylaxis // *Surg. Gynecol. Obstet.*, 1993; 175: 480
- Pereda J., Sabater L., Aparisi L. et al. Interaction between cytokines and oxidative stress in acute pancreatitis // *Curr. Med. Chem.*, 2006; 13 (23): 2775 – 87
- Powell J., Miles R. Antibiotic prophylaxis in the initial management of acute severe pancreatitis // *Br.J. Surg.*, 1998; 85
- Putnam P., Kochoshis S., Orenstein S. et al. Pediatric endoscopic retrograde cholangiopancreatography // *Am. J. Gastroenterol.*, 1991; 86: 824 – 830
- Rescorla R., Plumley D., Sherman S. et al. The efficacy of early ERCP in pediatric pancreatic trauma // *J.Pediatr.Surg.*, 1995; 30: 335 – 340
- Rusinko V., Willner P., Olah A. Pancreatic injury from blunt abdominal trauma in childhood // *Acta Chir. Belg.*, 2005; 105 (3): 283 – 6
- Sami El-Boghdady, Ziad al-Yousef, Khalid Al Bedah. Pancreatic injury: an audit and a practical approach // *Ann. R.Coll.Surg.Engl.*, 2000; 82: 258 – 262
- Shaked G., Kleiner O., Finally R. et al. Management of blunt pancreatic injuries in children // *European J.of Trauma*, 2003; 29:151 – 5
- Shilyansky J., Sena L., Kreller M. Et al. Nonoperative management of pancreatic injuries in children // *J.of P.Surg.*, 1998; 33 (2):343 – 9
- Smith D., Stanley R., Rue L. Delayed diagnosis of pancreatic transection after blunt abdominal trauma // *J.Trauma*, 1996; 40: 1009 – 1013
- Stringer M.D. Pancreatic trauma in children // *Br. J. Surg.*, 2005; 92 (4): 467 – 470
- Travers B. Rupture of the pancreas // *Lancet*, 1827; 12: 384
- Visrutaratna P., Na-Chiangmai W. Computed tomography of blunt abdominal trauma in children // *Singapore Med. J.*, 2008; 49 (4): 352–359
- Wilson R., Tagett J., Pucelik J., Walt A. Pancreatic trauma // *J.Trauma*, 1967; 7: 543 – 651

34. Wood J., Patrick D., Bruny J. et al. Operative vs nonoperative management of blunt pancreatic trauma in children // *J.Pediatr.Surg.*, 2010; 45 (2): 401
35. Loungnarath R., Blanchard H. Blunt injuries of the pancreas in children // <http://www.ncbi.nlm.nih.gov/pubmed/11803637> (sk.23.04.2010.)
36. Matsuno W., Huang C., Garcia N. et al. Amylase and lipase measurements in paediatric patients with traumatic pancreatic injuries // <http://www.ncbi.nlm.nih.gov/pubmed/19135195> (sk.20.04.2010.)
37. Valentino M., Serra C., Pavlica P. et al. Blunt abdominal trauma: diagnostic performance of contrast – enhanced US in children – initial experience // <http://radiology.rsna.org/content/246/3/903.long> (sk.20.04.2010.)
38. Wittendorff H., Fallentin E., Hansen M. Blunt isolated pancreatic trauma. Diagnostic problems – a clinical and radiological challenge // <http://www.ncbi.nlm.nih.gov/pubmed/12051048> (sk.23.04.2010.)

Address:

Edgars Zarembo
 Department of Surgery
 Rezekne Hospital
 18. Novembra Street 41,
 Rezekne, Latvia, LV-4600
 E-mail:zarembo@apollo.lv