

Berro A., Savin Silvia, Costea D., Tomita Maria, Nichifor Ana Maria, Nitu Th.S., Savin M., Sarbu V.

Intestinal fistulas occurred after the eventration's cure with alloplastic procedures

Faculty of medicine, University "Ovidius" Constanța

ABSTRACT

After eventrations' postoperative cure through alloplastic procedures, intestinal fistulas may occur.

The present study is examining a number of possible factors involved in the occurrence of intestinal fistula (type and location of the celiotomy following which appeared the eventration, the type of the net substitutes, co-morbidities and the method of the alloplastic substitution) and its treatment.

The analysis was retrospective and it covered 8 (eight) cases of intestinal fistula occurred after the installation of replacement nets for eventration postoperative cure.

Keywords: alloplastic substitution, intestinal fistula

Introduction

Postoperative incisional hernias, especially those with large parietal defects, are raising many issues regarding the surgery.

Without question, the best cases are those in which surgical treatment of incisional hernias can be achieved without the use of replacement nets. However, the cases where the cure is not possible without the use of this replacement nets are very common.

One of the most serious postoperative complications of alloplastic procedures is the intestinal fistula, whose treatment is very complex, as well medically as surgically. The present study examines a number of possible factors involved in the occurrence of intestinal fistula and its treatment.

Berro A.

Aleea Garofitei 19, Bl. L95, Sc.A, Ap.20, Constanta, 900177
+40 722 467567
ahmed_berro@yahoo.com

Materials and methods

We have analyzed retrospectively a total of 8 cases of intestinal fistula occurred after eventration's cure by fitting replacement nets. The study was conducted in the Department of Surgery of Constanta County Emergency Hospital for a period of 6 years (01.01.2007-31.12.2012), during which 418 operations were performed using alloplastic substitution.

We have followed several parameters: type and location of the celiotomy following which appeared the eventration, type of net substitutes, comorbidities, how to make alloplastic replacement, conditions of occurrence and diagnosis of fistula, the interventions performed and their consequences.

Results

Celiotomies after which incisional hernias occurred and which required alloplastic substitution were in all cases medians: overnavel - 2 cases (after gastric resection and colecystectomy), undernavel - 3 cases (hysterectomy) or over and undernavel (cure of umbilical hernia). Co-morbidities identified were: obesity associated with systemic atherosclerosis (3 cases), liver cirrhosis (1 case) or chronic bronchitis and diabetes (2 cases), systemic atherosclerosis associated with chronic hepatitis (2 cases).

The technique consisted in determining net alloplastic posterior muscular wall away from the edges of the parietal defect in 4 cases previously placed a fixation at the muscular wall in 2 cases, fixing the ends of the net directly at the muscular defect in 2 cases. Mesh fixation was done with separate threads using multifilament non-absorbable barrier in all cases. The nets were used as polyester (3 cases) and polypropylene (5 cases). Post substitution was in direct contact with the visceral mass in an individual

case, in which the great omentum was surgically absent.

Clinically, all fistulas were initially considered "granulomas thread" infected fistulising or in a prefistulisation stage. "Granulomas" fistulising (3 cases) were characterized by an evolving train externalization of relatively small amounts of purulent material (10-32ml/24h) following several attempts to extract sutures placed through the fistulous opening.

In two cases, the intestinal secretion has later become purulent, firstly at a rate which increased progressively, marking clearly the presence of communication with the intestine.

In another case, by exploring with contrast, fistulous orifice communicating with radiological small bowel was revealed (Figure 1).

For other 5 patients, the perforations were discovered during interventions targeting parietal excision of tumor formation, accompanied by local inflammatory phenomena, interpreted as the result of suppuration caused by sutures or even of incarcerated incisional hernias.

For 5 patients there was obvious recurrence of incisional hernias.

Intraoperative, we have found 2 situations: either the place of the substitution was parietal desinserted attachment sites (total desinsertion for 2 patients, partial desinsertion in 3 cases), cases in which perforation incisional hernias coexisted with relapsed or the place of the substitution was well secured and integrated within the wall (3 cases). For the 5 cases in which the place was separated from the abdominal wall, a marginal fragment of it has penetrated into the lumen of one or some intestinal loops.

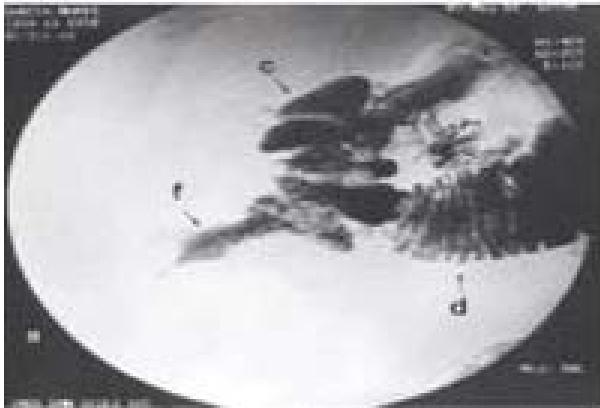


Figure 1 - Fistulous orifice communicating with small bowel (contrast radiologic exploration)

In two cases, excepting the perforation and without apparent connection with this one, were found voluminous “granuloma threads” (threads of resorbable, multifilament which set place). In all cases, the perforations were surrounded containing abscess pus more or less abundant as perforation, abscess and were not fistulising at the skin.

Location of perforation was in all cases enteral (8 ileal perforations, 2 jejunal perforations) and in 3 cases was a double perforation, ileal and colon (transverse colon). The perforations were unique enteral in 6 cases, the patient had two holes ileal found to 40cm away from each other, the other patients had 2 holes in the small bowel that were 10 cm from each other .

The enteral perforations were resolved in the majority of cases (7 cases) through a single segmental enterectomy(6cases)or double segmental enterectomy (1 case) and in a case through an enteroraphy. The restoration of intestinal continuity was made by entero - enteroanastomosys TT (6 cases) or LL (1 case), and in one case by enterocoloanastomosys TL. Colic fistulas were resolved by coloraphy. All anastomosis were made with separate threads of material nonabsorbable serosubmucosis. Postoperative was excised completely in 7 of the 8 cases, and in one case only partial excision was circumscribed around the fistula site.

The postoperative evolution was favorable in 5 cases and the other 3 cases were affected by the occurrence of anastomotic fistulas.

Fistulas occurred 7-9 days after surgery, causing localized peritonitis which was treated differently.

One of the three cases was a cirrhotic patient who underwent conservative treatment. The patient was hospitalized 82 days after surgery and was discharged with a fistulous opening through which pus oozing around 30ml daily requiring daily dressing. The patient returned 1 year after surgery requiring reoperation but abstention was the surgical indication.

Reintervention for anastomotic fistula in one case was the resulting LL enteroanastomosys after enterectomy with a new anastomotic fistula which required ileostomy practicing. Ileostomy was abolished after 6 months by implanting the ileum ascending colon without cure of the parietal defect, still remaining the incisional hernias.

In the third case of an anastomotic fistula, the first procedure was the ileostomy. The operation was performed under difficulty due to the presence of an inflammatory infiltrate in the enteral wall, reason why loop ileostomy was complicated by necrosis, which required iterative recovery enteral ileostomy. The postoperative evolution was unfavorable due to the appearance of ileostomy upstream of new enteric fistulas. Conservative treatment was instituted for 40 days after which the reintervention was necessary, practicing the entero–enteroanastomosys after enterectomy with LL. This time, the evolution was complicated by the appearance of anastomotic fistulas, which were treated conservatively until patient was discharged upon request, after 136 days of hospitalization. The patient died at home.

The attitude towards the abdominal wall after all interventions was limited to the simple suture of the skin above the visceral mass, obviously followed up by a free initial subcutaneous blocked evisceration, which in time led to the establishment of incisional hernias.

In 3 cases there were lots of skin necrosis covering blocked evisceration, and requiring necrectomy followed by spontaneous epithelization. (Table I)

Table I - Attitude in postoperative intestinal fistulas

N o	Initial intervention	Complication I	Complication II	Complication III	Complication IV	Hospitalisation days
1	Excision of the net Enterectomy TT anastomosys	Anastomotic fistula Reintervention Second entral anastomosys	Anastomotic fistula Reintervention II Ileostomy	Patchy skin necrosis Reintervention III Necrectomy	-	86
2	Excision of the net Enterectomy TT anastomosys	Anastomotic fistula Conservatory treatment	Patchy skin necrosis Reintervention I Necrectomy	-	-	82
3	Excision of the net Enterectomy TT anastomosys	Anastomotic fistula Reintervention I Ileostomy	Ileostomy necrosis Reintervention II Second ileostomy	Intestinal fistula Reintervention III Enterectomy Anastomosys LL	Anastomotic fistula Conservatory treatment	136 Death at home
4	Partial excision of the net Enteroraphy	Necrectomy	-	-	-	14
5	Net excision Enterectmy Enterocoloanasto- mosys TT	-	-	-	-	18
6	Net excision Enterectomy LL anastomosys	-	-	-	-	16
7	Net excision Enterectomy TL anastomosys	-	-	-	-	19
8	Net excision Enterectomy TT anastomosys	-	-	-	-	17

Discussions

Regarding the pathogenesis fistulas, two questions are arising. The first one concerns the role of comorbidity in their production. Even if we cannot quantify its influence in producing perforations, the presence of obesity at these patients, chronic liver disease and diabetes cannot be ignored [1]).

The second question concerns the direct mechanisms involved in producing perforations. The period of time from fitting the mesh to the moment that fistula appears (1 to 10 years) is excluding a possible accidental and unknown surgical intrusion produced at alloplastic substitution [2].

One such incident was followed by immediate postoperative complications (peritonitis). The analysis of the lesions found intraoperatively is suggesting two possible mechanisms in order to explain the late-occurring pathogenic intestinal fistulas: periprosthetic suppuration and direct mechanical trauma of the intestinal wall by mistake [3]. Periprosthetic suppuration was noted in all cases but it is quite difficult to determine whether it onset the fistula (infected granulomas of absorbable multifilament yarn that was fixed place) or was it just a consequence of perforation. The intestinal wall trauma appears to be involved in the 5 cases in which the net was totally or partially separated from the muscular wall and a portion of the net came in the intestinal lumen. Net penetration in the enteral lumen falls by otherwise

known foreign bodies tend to be eliminated by the body in “the natural way” that the perforation of hollow organs communicating with the outside [4]. In connection with the detection of parietal tissues nets, should be noted that this phenomenon was exclusive to the cases that used polyester nets.

Regarding the surgical treatment of perforation, the enterectomies were followed in 5 of 10 cases with entero-enteroanastomosis due to the dehiscence of anastomosis. The explanation of this complication seems to be linked to technical defects (bowel's devascularisation, anastomosis' voltage etc.). As possible mechanisms of the anastomosis' “failure”, may be taken into question, firstly, the locoregional sepsis secondary to fistula, similar with the “dangerous” anastomosis from peritonitis, and a possible harmful effect of loops cover only cutaneous-subcutaneous flaps without visceral mass protection in the parietal peritoneum [5].

Is it enterocoloanastomosis, enteroraphy or other better solution than entero-enteroanastomosis, as shown in the two cases with good development? The choice is obvious related to the type of the defect of the intestinal wall or near the ileocecal valve. Although ileostomy may seem unreasonable considering the enteric perforation, it proved itself viable only in two cases. We believe therefore that ileostomy is still a “crash” solution, reserved for the reinterventions for anastomotic fistula after enterectomy. To support this affirmation we have to look closely at the frequency of the multiple postoperative complications. Therefore, the question is if to accept the presence of a small fistula flow, easy to care through simple dressing, avoiding the risk of anastomosis or shortcomings in ileostomy? The decision would also belong to the patient, being related to age, firm associated activity, performance etc.

The contraindication for surgery is though difficult or almost impossible being accepted in the presence of a medium or high flow fistulas.

The attitude towards the abdominal wall also raises some questions. We believe that the complete removal of the prosthetic material is required when it is found off in whole or in part from the wall, bathed in a bath of pus with intestinal bacteria. Closing the muscular wall with alloplastic is never possible and the use of a new purse is unthinkable in the presence of

“dirty operations” and other threatening complications requiring early every time reinterventions. The simple suture of the skin remains the only gesture possible, but the risk of trauma involves the subjacent chances. Therefore, the recurrence is inherent and is occurring during the operation for solving the perforation. The surgically solving of the incisional hernias will be delayed for a while which cannot be certain and its completion is related to for the gut from the “bag” of the eventration.

The prevention of perforations using alloplastic substitution is required, considering the unsatisfactory results of their surgical treatment. Prophylaxis may be accomplished by avoiding the contact of the mesh with the intestines, whenever possible, by sparing and closing the peritoneum of the eventration bag or by omentum's determining the abdominal wall [6]. In situations where direct contact cannot be avoided, would be advisable to use nets two from one (placed in contact with the viscera) is slowly dissolving, “nontraumatic” and the other is nonabsorbable [7,8].

References

1. Abrahamson, J. (1998). *HERNIAS - Maingot's Abdominal Operations*, tenth edition, Vol. 1, 560-572
2. Berry, S.M. & Fischer, J.E. (1996). Classification and pathophysiology of enterocutaneous fistulas. *Surg Clin North Am.* 76(5), 1009-1018
3. Draus, J.M. Jr, Huss, S.A. & Harty, N.J. et al. (2006). Enterocutaneous fistula: are treatments improving?. *Surgery.* 140(4), 570-576; discussion 576-578
4. Leber, G.E., Garb, J.L., Alexander, A.I. & Reed, W.P. (1998). Long-term complications associated with prosthetic repair of incisional hernias. *Arch Surg.* 133, 378-382
5. Morris-Stiff, G.J. & Hughes, L.E. (1998). The outcomes of nonabsorbable mesh placed within the abdominal cavity: literature review and clinical experience. *J Am Coll Surg.* 186, 352-

6. Martinez, J.L., Luque-de Leon, E. & Ballinas-Oseguera, G. et al. (2012). Factors Predictive of Recurrence and Mortality after Surgical Repair of Enterocutaneous Fistula. *J Gastrointest Surg.* 16(1), 156-163; discussion 163-164
7. Soler, M., Verhaeghe, P., Essomba, A., Sevestre, H. & Stoppa, R. (1993). Le traitement des eventrations post-operatoires par prothese composee (polyester-polyglactin 910): etude clinique et experimentale. *Ann Chir.* 47, 598-608
8. Vrijland, W.W., Jeekel, J., Steyerberg, E.W., Den Hoed, P.T. & Bonjer, H.J. (2000). Intraperitoneal polypropylene mesh repair of incisional hernia is not associated with enterocutaneous fistula. *Br J Surg.* 87, 348-352