

Gheorghiu Irina-Maria¹, Mitran Loredana², Mitran Mihai³, Stoian Irina Maria⁴

Cervical root resorption

- case report -

¹ University assistant, Department of Operative dentistry, Faculty of Dentistry, UMF "Carol Davila" Bucharest

² MD, Department of Otorhinolaryngology, Elias Hospital Bucharest

³ University assistant, Department of Obstetrics and Gynecology, Faculty of Medicine, UMF "Carol Davila" Bucharest

⁴ Associate Professor, Department of Biochemistry, Faculty of Medicine, UMF "Carol Davila" Bucharest

ABSTRACT

Cervical resorption is an inflammatory-mediated external resorption of the root, which can be seen after trauma and following internal bleaching techniques. It is initiated in the periodontal ligament, but the exact pathogenesis is not known. Once triggered the resorption phenomenon can lead to fracture and loss of the tooth.

Keywords: cervical external root resorption; internal dental bleaching; tooth fracture; extraction.

Introduction

Dental resorption is also called root resorption. It is a physiological destructive process in deciduous teeth, allowing eruption of permanent teeth but it is a pathological phenomenon in permanent teeth, which induces the disappearance of hard tissues like dentin, cementum and bone. Etiopathogenesis of dental resorption is related to injury or irritation of the dental pulp or periodontal structures through: trauma or excessive pressure, mechanical stimulation (orthodontic movements), inflammatory or infectious conditions (bacteria from periodontal disease), internal teeth whitening, systemic disease or idiopathic causes [8]. Root resorption in permanent teeth can be internal and external, the latter being more common. Cervical (periodontal) inflammatory resorption or invasive cervical resorption, extracanal invasive resorption, cervical root resorption, and cervical inflammatory resorption are terms used to describe this form of external resorption [1,7]. Although the exact etiology has not been established,

Irina-Maria Gheorghiu,

Bd. Libertatii 18, bloc 104, sc.2, ap 23, sect V, Bucuresti
Tel. 0744305591
igheorghiu@hotmail.com

the authors grouped this condition with inflammatory resorptive conditions. Inflammatory cervical external root resorption is initiated in the periodontal ligament and occurs in the cervical area of the tooth.

The exact pathogenesis is not known.. Dental resorption process is similar with the bone resorption, the clasts cells are the dominant histologic element. They cause degradation of the crystalline structure and the structure of the organic component of hydroxyapatite (type I collagen). The problem is usually asymptomatic and discovered on routine X-rays examinations [6,9]. The cervical resorption lesions may develop above the crestal bone (supraosseous) or below the crestal bone (intraosseous).

Case report

A female patient, 35 years old, has presented in our dental practice for dental treatment. We noticed the discoloration in her upper right lateral incisor (Figure 1). The tooth has presented a distal massive incorrect filling. The information the patient has provided revealed the fact that the tooth had been endodontically treated due to caries in the childhood. No history of trauma was reported. Ten years ago, after the endodontic treatment, the tooth was internally bleached by sodium perborate and hydrogen peroxide. Due to an unsatisfactory bleaching result after a number of sessions, the treatment was supplemented with in-office bleaching. The radiographic exam confirmed the endodontic treatment. The X- rays exam also revealed an important cervical root resorption in association with periodontal sockets and bone resorption.

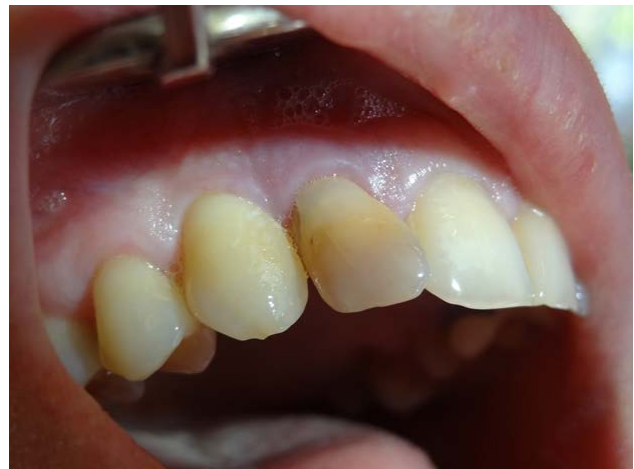

Figure 1 - Clinical view of the right upper lateral incisor showing discoloration

The aspect of cervical inflammatory resorption appears as a radiolucency superimposed over the root canal (Figure 2).

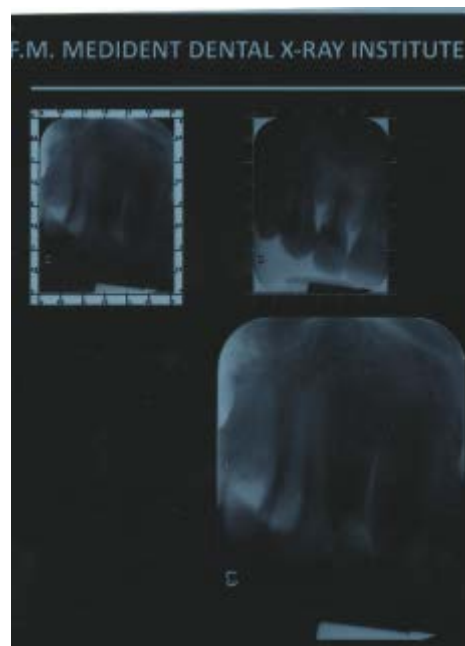


Figure 2 - Initial intraoral radiograph showing large cervical resorption

We have informed the patient about the situation and offered her methods of treatment, but she accepted no treatment for the condition of her

right upper lateral incisor. After 6 months the patient has presented to the dental office again for the fracture of the tooth (Figure 3).

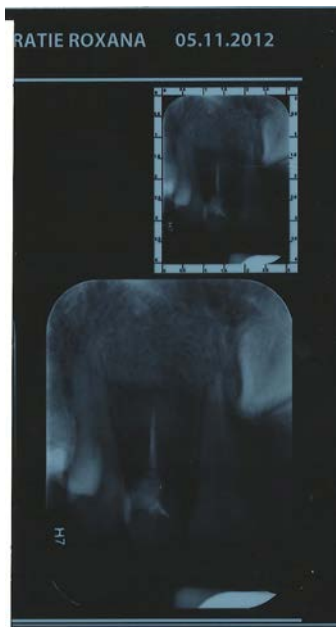

Figure 3 - Radiographic view of the fractured tooth

The fracture was incomplete but the bone condition and the root situation imposed the tooth extraction (Figures 4 and 5).

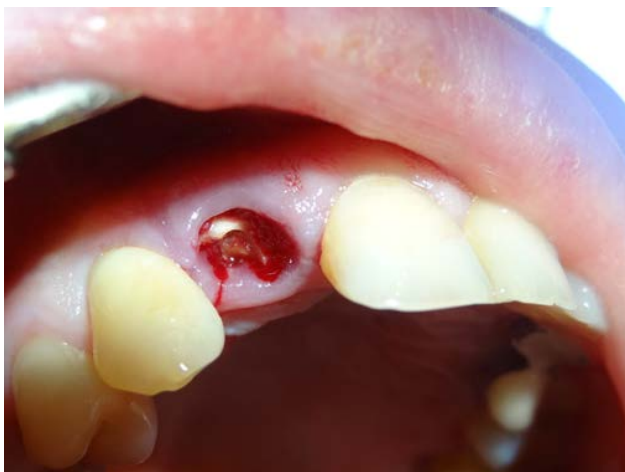

Figure 4 - Clinical view of the fractured tooth

The treatment of the absence of upper lateral incisor is mandatory for patient for aesthetic and functional reasons. The patient was given three options

to replace her missing teeth: a dental implant, a three unit bridge and a partial denture. The patient refused the dental implant because of financial reasons and the length of the treatment. The only option she has accepted was a dental bridge, although the classical treatment with a permanently bridge anchored on adjacent teeth: canine and central incisor involves an obvious massive sacrifice of healthy tooth substance.

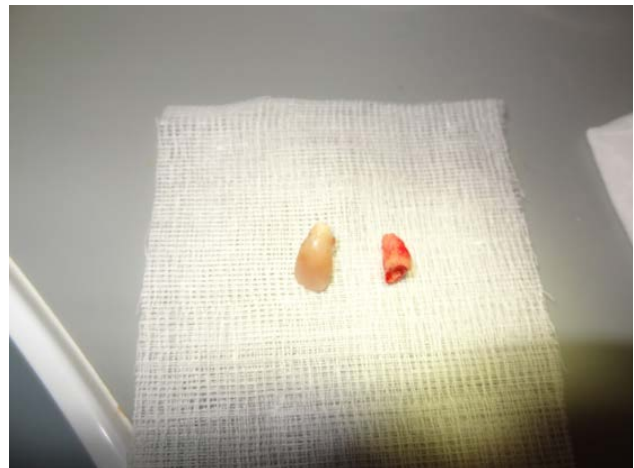

Figure 5 - Extracted tooth

Discussion

Several theories have been issued regarding the pathological mechanism of cervical resorption after intracoronary bleaching, especially in combination with heating [5]. Because the underlying mechanism for this effect is unclear it has been suggested that the bleaching agent reaches the periodontal tissue through the dentinal tubules and initiates an inflammatory reaction; another theory suggest that the bleaching agent, the peroxide, by diffusing through the dentinal tubules, denatures the dentin, which then becomes an immunologically different tissue and is attacked as a foreign body. In any case, cervical external resorption is treatable and can be resolved as long as it is caught early enough [2,10].

In the presented case the extent of the resorption lesion along with massive filling have created the conditions for the tooth fracture. But the patient's lack of interest in dental treatment has determined the outcome: loose of the tooth. What is important for patient is that cervical external resorption is treatable if the root destruction is not very extended. It is very difficult to treat when it is associated with large fillings which can weaken the tooth, like this case. Bleaching agents used in association with heat also reduces the hardness of the hard tissues like dentin and enamel. The accessibility to the cervical root lesion also influence the chances for treatment, the supraosseous lesions are easier to treat [3,4]. The lesions can be restored with glass ionomer cement. The condition is to detect the root resorption as earlier as possible; otherwise the only option is extraction.

Conclusions

Cervical root resorption is a pathologic consequence of different factors, including intracoronary bleaching techniques. It can be successfully treated as long as it is detected as earlier as it is possible by the means of x-rays exam. Otherwise the prognosis is tooth fracture and extraction.

References

1. Fuss Z., Tsesis I. & Lin S. (2003). Root resorption - diagnosis, classification and treatment choices based on stimulation factors. *Dent Traumatol.* 19(4), 175-182.
2. Gimlin D.R. & Schindler W.G. (1990). The management of postbleaching cervical resorption. *J Endod.* 16(6), 292-7.
3. Gulsahi A., Gulsahi K. & Ungor M. (2007). Invasive cervical resorption: clinical and radiological diagnosis and treatment of 3 cases. *Oral Surg Oral Med Oral Pathol Oral Radiol Endod.* 103(3), 65-72.
4. Heithersay G.S. (2007). Management of tooth resorption. *Aust Dent J.* 52(1suppl), 105-121.
5. JOE Editorial Board. (2008). Bleaching in endodontics: an online study guide. *J Endod.* 34(5Suppl), 111-6.
6. Loguercio A.D., Souza D., Floor A.S., Mesko M., Barbosa A.N. & Busato A.L. (2002). Clinical evaluation of external radicular resorption in non-vital teeth submitted to bleaching. *Odontol Bras.* 16(2), 131-5.
7. Marin P.D. (2006). Intra-coronal bleaching: the past, present and future. *Ann R Australas Coll Dent Surg.* 18, 36-9.
8. Patel S., Kanagasingam S. & Pitt Ford T. (2009). External cervical resorption: a review. *J Endod.* 35(5), 616-25.
9. Roig M., Morelló S., Mercadé M. & Durán-Sindreu F. (2010). Invasive cervical resorption: report on two cases. *Oral Surg Oral Med Oral Pathol Oral Radiol Endod.* 110(4), 64-9.
10. Schwartz R.S., Robbins J.W. & Rindler E. (2011). Management of invasive cervical resorption: observations from three private practices and a report of three cases. *Tex Dent J.* 128(11), 1173-87.