

Gheorghiu Irina-Maria¹, Mitran Loredana², Mitran M.³, Mironiuc-Cureu Magdalena⁴, Stoian Irina Maria⁵

Modern treatment of upper permanent canine absence - Case report

¹ University assistant, Department of Operative dentistry, Faculty of Dentistry, UMF "Carol Davila" Bucharest

² Md, Department of Otorhinolaryngology, Elias Hospital

³ University assistant, Department of Obstetrics and Gynecology, Faculty of Medicine, UMF "Carol Davila" Bucharest

⁴ University assistant, Department of Parodontology, Faculty of Dentistry, UMF "Carol Davila" Bucuresti Bucharest

⁵ Associate Professor, Department of Biochemistry, Faculty of Medicine, UMF "Carol Davila" Bucharest

ABSTRACT

The absence of upper definitive canine is relatively common in clinic. The edentulous area is problematic regarding the prosthetic treatment. In this study case it has been used a modern treatment by inserting a dental implant. This method has major advantages because is very conservative thinking the old prosthetic methods.

Keywords: deciduous upper canine; permanent upper canine; edentulous area; dental implant.

Introduction

The upper permanent canines are teeth with a very important value in the upper jaw. The absence of upper definitive canine is relatively common in clinic. Upper permanent canine eruption in malposition is often a consequence of the late eruption on dental arch age: 11-13 years, after the adjacent teeth: lateral incisor and first premolar, with consequent reduction of space available for canine. In the absence of adequate orthodontic treatment it is not possible for the canine to achieve the correct position. In the situations when it is not possible in any way to bring the permanent canine on the jaw, using orthodontic appliance and surgical methods, the only solution is to extract the tooth. The absence of upper definitive canine is often a result of impaction of permanent canine. Most times, in these cases, temporary canine remain on the dental arch on to adulthood. The edentulous area is problematic regarding the prosthetic treatment.

The treatment of the absence of upper permanent canine is mandatory for patient for aesthetic and functional reasons: participation of canine in physiognomy is remarkable; even more important is that this tooth participates in the canine or anterior-lateral guide, so it has great value in the

Irina-Maria Gheorghiu,

Bd. Libertatii 18, bloc 104, sc.2, ap 23, sect V, Bucuresti;
Tel. 0744305591;
e-mail: igheorghiu@hotmail.com

functional occlusal relationships. Classical treatment of canine absence is a permanently bridge anchored on adjacent teeth: lateral incisor, central incisor and first premolar, with an obvious massive sacrifice of healthy tooth substance.

By contrast, treatment of canine absence by inserting a dental implant with immediate, early or conventional delayed prosthetic loading is a very good treatment option, with predictable results and minimally invasive [1,2].

Case report

A patient, 39 years old, has presented in our dental practice for dental treatment. She was unhappy because of the mobility in her upper right canine and because of the discoloration of that tooth (Figure 1).

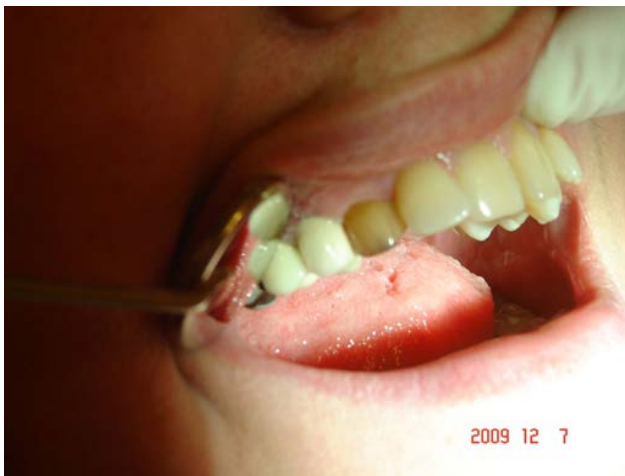

Figure 1 - Clinical preoperative view of the deciduous right upper canine

The clinical exam revealed the presence of a deciduous upper canine. The information the patient has provided revealed the extraction in the childhood of the permanent right upper canine due to its abnormal position. The radiographic exam confirmed the absence of the right permanent upper canine (Figure 2). A general exam of the patient has been

conducted, as well as the local hard and soft tissues.

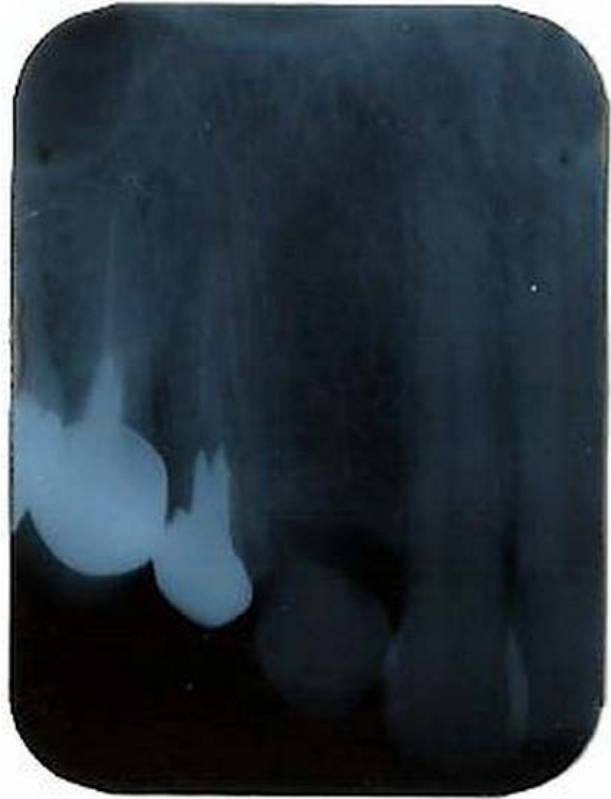

Figure 2 - Preoperative intraoral radiograph

The extraction of the deciduous canine has produced an edentulous area. We decided to treat that using a dental implant and a ceramic crown. The immediate insertion after extraction is now days a common method. It is very well scientifically documented and it has big advantages regarding bone conservation and osseointegration of the implant. In this case the bone structure allowed us to use this immediate placement of the implant type AB dental 3,75/13 mm. The implant has been covered with sutured soft tissues.

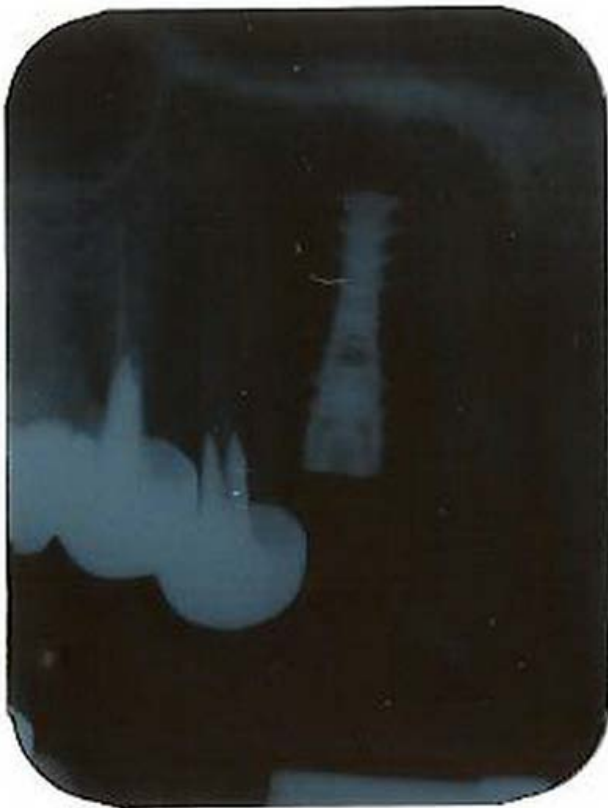

Figure 3 - Radiographic view of the implant immediate after insertion

After the three months period of osseointegration of the implant a clinical and radiographic exams have been conducted. At second stage surgery, 3 months three months after placement of the implants, titanium healing cap was connected. The final impression was made three weeks after second-stage surgery and the final ceramic restoration has been put into place. The patient was informed about the special care of a dental implant and the monitoring period at every six months.

After a period of three years the clinical aspect of the restoration and the radiological one are excellent (Figure 4, Figure 5).

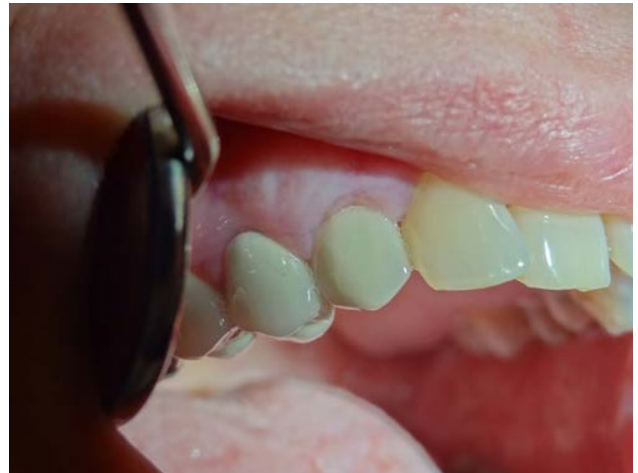

Figure 4 - Clinical situation 3 years after treatment

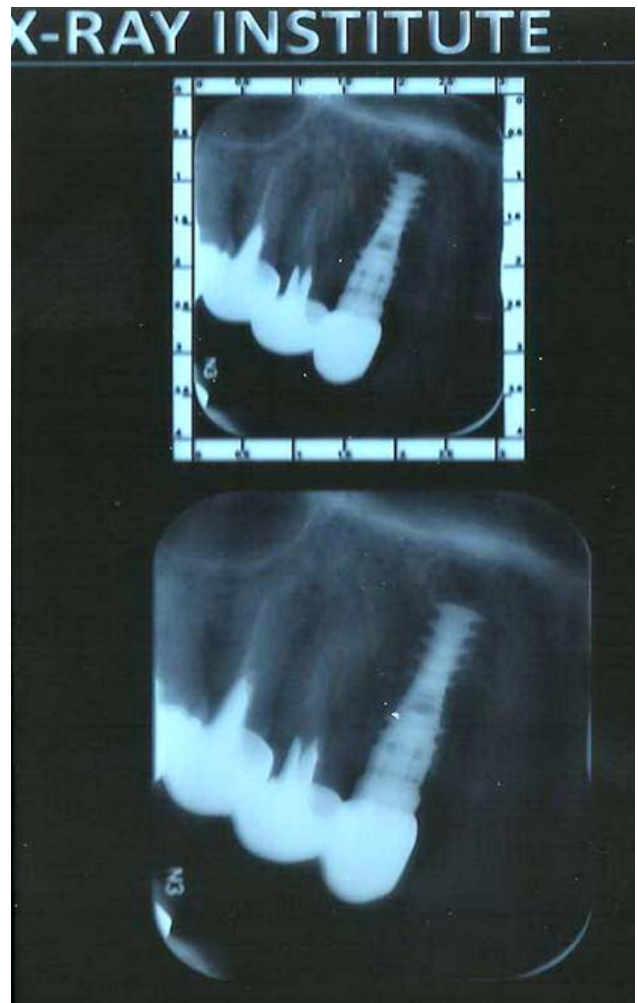


Figure 5 - Radiographic view of the implant and cemented crown 3 years after treatment

Discussion

The method of treatment the absence of upper definitive canine using a dental implant is very modern and very useful [3]. It is easily accepted by the patient and it is very conservative thinking the old prosthetic methods. Another great advantage is that the aesthetic result of the treatment is much closer to the natural than the one obtained with classic prosthetic method [4,5]. The modern method by placing a dental implant is definitely superior than prosthetic treatment, but it is conditioned by a number of factors: a general exam of the patient is needed, as well a local one, very carefully conducted; the treatment plan should be realistic and correctly [6,7]. The complete success is guaranteed by the precisely execution both of the surgical and prosthetic stages.

Conclusions

Single tooth replacement using implant therapy is a predictable and successful dental procedure. The modern method of treatment the absence of upper definitive canine using a dental implant is a better option in case of a patient with a good health and reactivity and a proper local bone and soft tissue structure.

References

1. Avila, É.D., de Molon, R.S., de Assis Mollo, F. Jr., de Barros, L.A., Capellozza Filho, L., de Almeida Cardoso, M. & Cirelli, J.A. (2012). Multidisciplinary approach for the aesthetic treatment of maxillary lateral incisors agenesis: thinking about implants? *Oral Surg Oral Med Oral Pathol Oral Radiol.* 114(5), 22-28
2. Wahlström, M., Sagulin, G.B. & Jansson, L.E. (2010). Clinical follow-up of unilateral, fixed dental prosthesis on maxillary implants. *Clin Oral Implants Res.* 21(11), 1294-1300
3. Ramsey, C.D. (2007). Single-tooth replacement of a maxillary central incisor via immediate implant placement. *Pract Proced Aesthet Dent.* 19(6), 355-357
4. Martin, W., Morton, D. & Ruskin, J. (2011). Planning for esthetics-part 1: single tooth bone level implant restorations. *Tex Dent J.* 128(12), 1298-1299
5. Cho, H.L., Lee, J.K., Um, H.S. & Chang, B.S. (2010). Esthetic evaluation of maxillary single-tooth implants in esthetic zone. *J Periodontal Implant Sci.* 40(4), 188-193
6. Garavaglia, G., Mojon, P. & Belser, U. (2013). Modern treatment planning approach facing a failure of conventional treatment. Part II: case report and discussion. *Eur J Esthet Dent.* 8(1), 68-87
7. Krennmair, G., Seemann, R., Weinländer, M., Wegscheider, W. & Piehslinger, E. (2011). Implant-prosthodontics rehabilitation of anterior partial edentulism: a clinical review. *Int J Oral Maxillofac Implants.* 26(5), 1043-1050
1. Avila, É.D., de Molon, R.S., de Assis Mollo, F. Jr., de Barros, L.A., Capellozza Filho, L., de Almeida Cardoso, M. & Cirelli, J.A. (2012). Multidisciplinary approach for the aesthetic treatment of maxillary lateral incisors agenesis: