

CASE REPORT

# Left bisegmentectomy for liver cirrhosis associated primary hepatic carcinoma with preoperative chemoembolization

Molnar C\*, Silaghi C, Rosca C, Marginean L, Butiurca VO, Tudor A, Copotoiu C

University of Medicine and Pharmacy, Tîrgu Mureş, Romania

**Introduction:** Hepatocellular carcinoma is the most frequent primary malignant tumor of the liver, being linked in 80% of cases with viral hepatitis "B" or "C". Treatment remains a challenge especially in cases with associated hepatic cirrhosis, where preoperative arterial chemoembolization followed by liver resection is recommended.

**Case report:** We discuss the case of a 64 years old cirrhotic patient, diagnosed by echography, computed tomography, magnetic resonance cholangiography with hepatocellular carcinoma (64x52x46 mm). Preoperative chemoembolization was performed with Lipiodol and 5-FU by supra-selective catheterization of left hepatic artery, followed by favorable radiologic response. Two weeks after embolization, the patient was admitted in Surgical Clinic No. 1 Targu Mures where an atypical resection of the left hepatic lobe (bisegmentectomy II-III) was performed with Harmonic Scalpel. Early and late postoperative evolution was favorable.

**Discussions:** The principle of arterial chemoembolization is based on the fact that vasculature of primary hepatic tumors is predominantly arterial. Arterial obstruction may lead to ischemic necrosis while tumor embolization combination with a chemotherapeutic agent significantly improves its local concentration. Decrease in tumor size and its vasculature allows for safe hepatic resection especially in the cirrhotic liver.

**Conclusion:** In case of tumoral cirrhotic liver preoperative chemoembolization decreases intra and postoperative bleeding risk, providing a safe and oncological resection.

**Keywords:** hepatocellular carcinoma, liver cirrhosis, preoperative chemoembolization, liver resection

Received: 17 October 2014 / Accepted: 21 November 2014

## Introduction

Hepatocellular carcinoma is the most common primary malignant tumor of the liver being associated in 80% of cases with hepatitis B or C [1]. Its treatment remains challenging, especially in cases associated with liver cirrhosis, where a hepatectomy is difficult to accomplish (major bleeding risk, exuberant portal vasculature).

Hepatic resection is the recommended treatment of hepatocellular carcinoma in all cases in which hepatic functional reserve permits, with a 5-year survival of 25 to 55% [2,3].

Tumor recurrence at 5 years is between 75 and 100 % of cases and represents the main cause of death in patients with hepatocarcinoma. Therefore the establishment of appropriate treatment strategies that could reduce the local recurrence is vital to improve the long-term survival [3].

Arterial chemoembolization, recommended treatment of unresectable hepatocellular carcinoma, induces ischemic tumor necrosis via selective arterial injection of chemotherapeutic substances and some embolic agents [4,5]. A variety of studies suggests the importance of this procedure as preoperative treatment, reducing tumor cell viability and therefore relapse.

Also a number of trials conducted failed to demonstrate significant benefits in terms of survival, so that the role of

preoperative arterial chemoembolization remains controversial.

Detection of hepatocellular carcinoma in early stages is more and more common due to periodically imaging and biological (tumor markers) evaluation of cirrhotic patients.

Among the many therapeutic procedures (resections of liver, liver transplantation, percutaneous alcohol injection, radiofrequency ablation chemoembolization pressure), the most feasible in our terms seems to be arterial chemoembolization followed by hepatectomy.

## Case report

We present the case of a 64 years old patient with known liver cirrhosis diagnosed with HCC in December 2013 after performing some routine periodic examinations.

Ultrasonography performed on 12.03.2013 can detect an increased liver size, increased echogenicity, non-homogenous echostructure, macronodular type and irregular outline. In the second liver segment it revealed a hypoechogenic formation, with irregular contour, non-homogenous with peripheral vascular signal with central calcification with dimensions of 64/52/46 mm diverging vascular and biliary structures in the vicinity. Computerized tomographic angiography examination performed on 27/12/2013 also highlighted the lesion with characters suggestive of a hepatocellular carcinoma, and also describing an increased spleno-portal axle with complete venous thrombosis of the left portal vein and repermeabilization of umbilical vein.

\* Correspondence to: Călin Molnar  
E-mail: molnar.calin@yahoo.com

On 08/01/2014 we performed chemoembolization with Lipiodol and 5- FU by supraseductive catheterization of left hepatic artery, with good radiologic response, after which, in an interval of two weeks, the patient was hospitalized in the Surgical Clinic 1, County Emergency Hospital Targu Mures for surgical treatment.

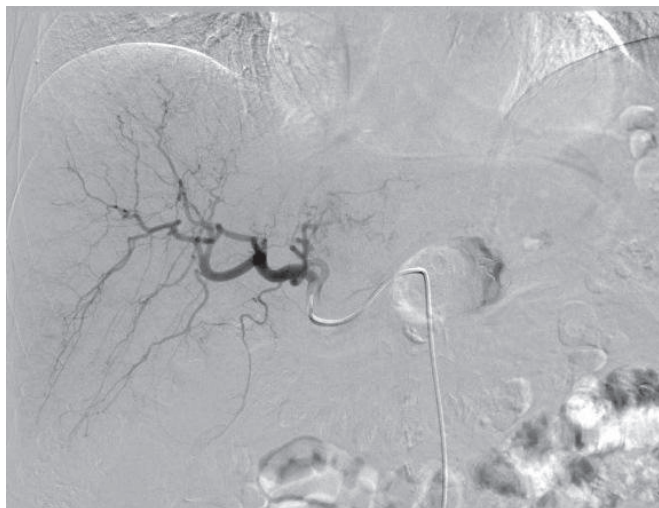


Fig. 1. Selective arteriography

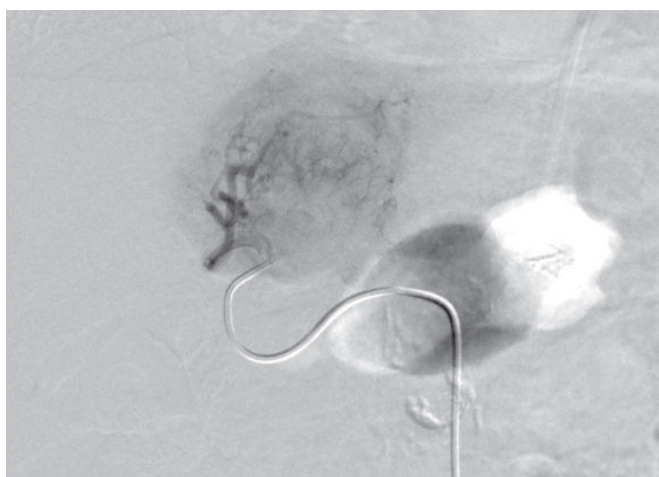


Fig. 2. Vizualisation of intra and peritumoral neoformation blood vessels

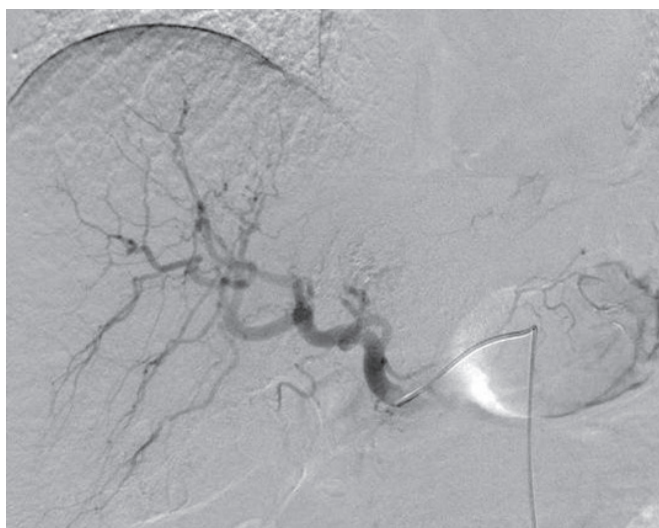


Fig. 3. Postembolization aspect

On admission the patient was hemodynamically and respiratory stable, the biological samples showing a hepatocytolysis and subjectively accusing continuous right upper quadrant pain. Physical examination detected a liver palpable at 4 cm under the costal margin, and an uncomplicated symptomatic umbilical hernia.

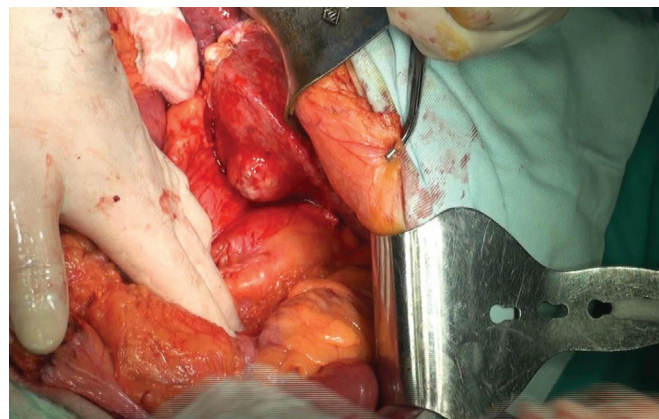


Fig. 4. Hepatic tumor in segments II-III

After an adequate preoperative preparation surgery was performed under general anesthesia with oro-tracheal intubation, a 6x6x5 cm tumor being detected intraoperatively, located in the segment II and III of the liver.

After the mobilization of the left liver by cutting the round and left triangular ligaments we performed an atypical liver resection of the left lobe (bisegmentectomy II -III) with Harmonic scalpel, classic retrograde cholecystectomy, umbilical hernia repair procedure Lawson Tait, TachoSil hemostasis in liver's resection bed and subhepatic drainage.

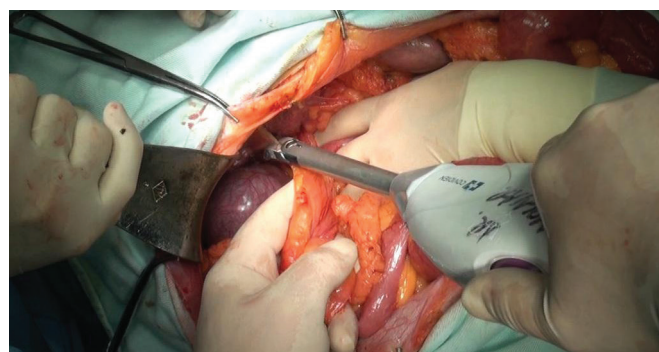

Fig. 5. Round ligament cutting

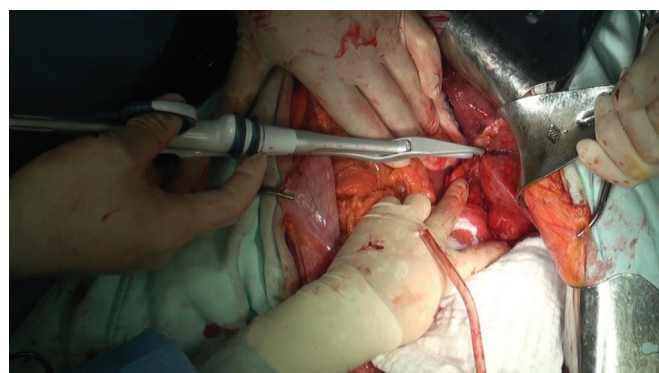


Fig. 6. Liver dissection with Harmonic Scalpel away from tumor (atypical left hepatectomy)



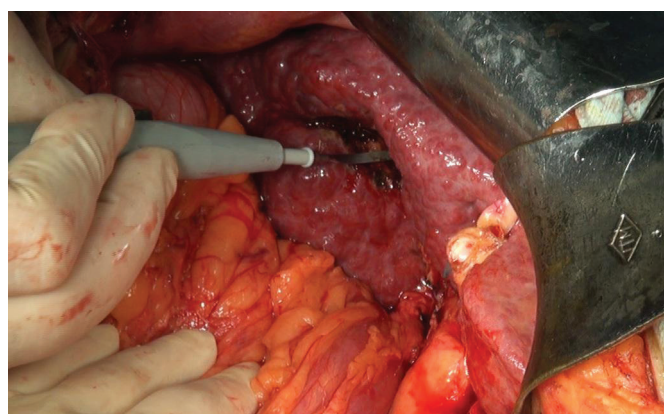


Fig. 7. Cirrhotic liver, hemostasis in the gallbladder bed

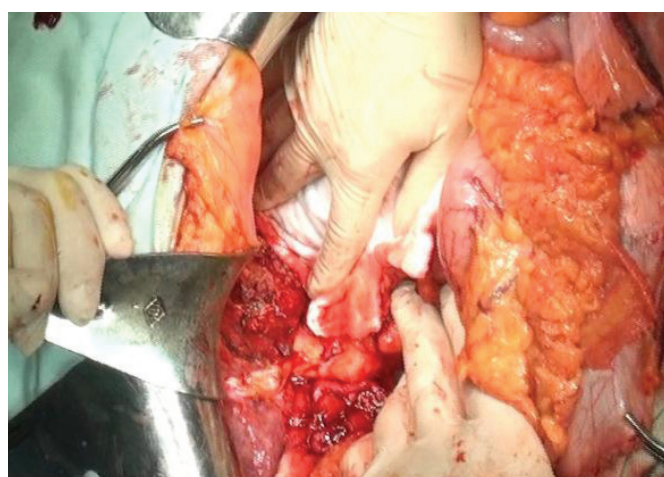


Fig. 8. Atypical left hepatectomy – final aspect

The patient did not require blood transfusion after surgery, intraoperative losses being minimal. Histopathological outcome of the resected liver has revealed a poorly differentiated hepatocellular carcinoma. The patient presented a favorable immediate postoperative evolution, being discharged on day 12, while late (9 months) postoperatively there was no evidence of tumor recurrence during his oncological hospitalisation.

## Discussion

Treatment of hepatocellular carcinoma in patients with chronic liver disease is a major challenge.

Hepatic resection has good results in terms of long-term survival and tumor relapse-free period. However, even in centers with experience postoperative mortality ranges between 1.6 and 10% [3].

Although significant results were obtained when liver transplant was performed for hepatocellular carcinoma, the small number of donors, the lack of accessibility and long waiting list makes this procedure to be reserved for only a small number of patients [3].

Arterial chemoembolization principle is based on the fact that primary liver tumor vasculature is done almost exclusively by the hepatic arteries. Arterial obstruction can induce ischemic tumor necrosis and embolization combined with a chemotherapeutic agent, drastically improv-

ing the local concentration of the substance chemotherapy [5,6,7].

In 2003 a meta-analysis of seven studies showed an overall survival at two years significantly increased compared to non-active treatment in patients with unresectable HCC, for which in 2005 was recommended as standard treatment in cases of unresectable tumors without vascular invasion or extrahepatic dissemination [8].

Although arterial chemoembolization is effective for the main tumors, intrahepatic metastasis, portal thrombosis and capsular invasion are considered risk factors contributing to tumor relapse.

Adachi and Harada described in their studies that preoperative chemoembolized subgroup who developed complete tumor necrosis showed a significantly higher overall survival than the group that did not perform preoperative therapy [9,10].

Adachi suggests that preoperative chemoembolization with partial necrosis of tumors may cause hematogenous dissemination of residual cancer cells in the surgical manipulation [9].

Chemoembolization is commonly used in unresectable HCC therapy. Several studies also describe its usefulness in patients operated as adjuvant preoperative therapy or as a preliminary stage for a liver transplant. Efficacy of preoperative chemoembolization is not generally accepted, but in the presented case remains the best therapeutic option [11,12,13].

Besides the decrease tumor recurrence by controlling dissemination intrahepatic portal system path, arterial chemoembolization is also useful in reducing tumor size. Dimensions decrease leads to a safer liver resection, reducing the amount of peritumoral liver tissue resected and the opportunity to bring in a resectable stage tumors initially declared inoperable [14,15].

Uchida, in his study shows that although preoperative chemoembolization reduced the number of deaths in a year and a half by tumor recurrence, in patients with liver cirrhosis survival at 4 years was significantly lower due to exacerbation of cirrhosis [10].

Meta-analyses performed failed to settle controversies related to preoperative chemoembolization, but most studies have agreed that in carefully selected patients with single tumors there was a significant benefit in terms of the survival and relapse-free period of preoperative liver chemoembolization [16,17,18].

In our case, the procedure had a favorable evolutionary response (tumor regression, absence of relapse).

## Conclusions

Preoperative chemoembolization of tumors in cases with cirrhotic liver decreases intra and postoperative bleeding risk.

Imaging examinations (CT, magnetic resonance cholangiography) performed regularly on cirrhotic patients allow detection of tumors in a resectable stage.

Postchemoembolization hepatectomy is mandatory in the presence of tumor regression.

## References

1. Grazi GL, Ercolani G, Pierangeli F, Del Gaudio M, Cescon M, Cavallari A, Mazziotti A: Improved results of liver resection for hepatocellular carcinoma on cirrhosis give the procedure added value. *Ann Surg* 2001, 234:71-78.
2. Kishi Y, Hasegawa K, Sugawara Y, Kokudo N. Hepatocellular carcinoma: current management and future development-improved outcomes with surgical resection. *Int J Hepatol*. 2011, 2011:728103.
3. Tabrizian P, Roayaie S, Schwartz E. Current management of hepatocellular carcinoma. *World J Gastroenterol* 2014, 20(30): 10223-10237.
4. Kaibori M, Tanigawa N, Matsui Y. Influence of transcatheter arterial chemoembolization on the prognosis after hepatectomy for hepatocellular carcinoma in patients with severe liver dysfunction. *Anticancer Res*. 2006, 26:3685-3692.
5. Zhou WP, Lai EC, Li AJ: A prospective, randomized, controlled trial of preoperative transarterial chemoembolization for resectable large hepatocellular carcinoma. *Ann Surg* 2009, 249:195-202.
6. Gerunda GE, Neri D, Merenda R: Role of transarterial chemoembolization before liver resection for hepatocarcinoma. *Liver Transpl* 2000, 6:619-626.
7. Wang X, Li J, Peng Y: Influence of preoperative transarterial chemoembolization on the prognosis for patients with resectable hepatocellular carcinoma: a meta-analysis of randomized trials. *Hepatogastroenterology*, 2011, 58:869-874
8. Bruix J., Sala M., Llovet J.M. Chemoembolization for hepatocellular carcinoma. *Gastroenterology*, 2004, 127: S179-188
9. Adachi, E., Matsumata, T., Nishizaki, T., Hashimoto, H., Tsuneyoshi, M. and Sugimachi, K. Effects of preoperative transcatheter hepatic arterial chemoembolization for hepatocellular carcinoma. The relationship between postoperative course and tumor necrosis. *Cancer*, 1993, 72: 3593-3598.
10. Uchida M, Kohno H, Kubota H: Role of preoperative transcatheter arterial oily chemoembolization for resectable hepatocellular carcinoma. *World J Surg* 1996, 20:326-331.
11. Dai H. Han; Gi H. Choi; Jun Y. Park; Sang H. Ahn; Kyung S. Kim; Jin S. Choi; Kwang-Hyub Han. Lesson from 610 liver resections of hepatocellular carcinoma in a single center over 10 years. *World Journal of Surgical Oncology*, 2014, 12(1).
12. Sasaki A, Iwashita Y, Shibata K. Preoperative transcatheter arterial chemoembolization reduces long-term survival rate after hepatic resection for resectable hepatocellular carcinoma. *Eur J Surg Oncol*. 2006, 32:773-779.
13. Kang JY, Choi MS, Kim SJ. Long-term outcome of preoperative transarterial chemoembolization and hepatic resection in patients with hepatocellular carcinoma. *Korean J Hepatol*. 2010, 16:383-388.
14. Kim IS, Lim YS, Lee HC. Pre-operative transarterial chemoembolization for resectable hepatocellular carcinoma adversely affects post-operative patient outcome. *Aliment Pharmacol Ther*. 2008, 27:338-345.
15. Lee KT, Lu YW, Wang SN. The effect of preoperative transarterial chemoembolization of resectable hepatocellular carcinoma on clinical and economic outcomes. *J Surg Oncol*. 2009, 99:343-350.
16. Choi GH, Kim DH, Kang CM. Is preoperative transarterial chemoembolization needed for a resectable hepatocellular carcinoma? *World J Surg*. 2007, 31:2370-2377.
17. Bruix J, Sherman M. Practice guidelines committee. American association for the study of liver diseases. Management of hepatocellular carcinoma. *Hepatology*. 2005, 42:1208-1236.
18. Paye F, Jagot P, Vilgrain V. Preoperative chemoembolization of hepatocellular carcinoma: a comparative study. *Arch Surg*. 1998, 133:767-772.