

OSTEONECROSIS OF THE JAWS IN PATIENTS RECEIVING ANTI-ANGIOGENIC DRUGS AND CHEMOTHERAPEUTICS: LITERATURE REVIEW AND CASE REPORTS

Z. Mihaylova, R. Ugrinov, E. Aleksiev, P. Stanimirov

Department of Oral and Maxillofacial Surgery, Faculty of Dental Medicine, Medical University – Sofia, Bulgaria

Abstract. Medication-related osteonecrosis of the jaw (MRONJ) is a relatively rare but serious pathology associated with the use of bisphosphonates (BPs) and antiresorptive drugs in patients with bone metastases, multiple myeloma and osteoporosis. Various cases of patients with jaw bone necrosis due to BPs have recently been reported in the literature. Anti-angiogenic drugs are novel anticancer agents prescribed to patients with renal carcinoma, lung carcinoma, soft tissue metastases, etc. Anti-angiogenic drugs target the vascular endothelial growth factor's (VEGF) signaling pathways via different mechanisms and thus inhibit tumor cell proliferation, neoangiogenesis and tumor growth. Several reports have suggested a higher incidence of MRONJ in patients treated with BPs in combination with anti-angiogenic drugs. However, there is currently no sufficient data in the literature about the risk of ONJ in patients taking anti-angiogenic drugs or cancer chemotherapy alone. We present two clinical cases of osteonecrosis of the jaw in patients treated with chemotherapy, but no history of BPs. In the first case the necrosis is related to the anti-angiogenic agent sunitinib in a patient with lung metastases and in the second case- to complex chemotherapy in a patient with acute myeloid leukemia. We recommend conservative treatment with antibiotics in both cases, together with antiseptics and surgical removal of the necrotic bone following total demarcation of the sequesters.

Key words: MRONJ, bisphosphonates, anti-angiogenic drugs, sunitinib, chemotherapy

Corresponding author: Zornitsa Mihaylova, DDS, PhD, e-mail: dr.z.mihaylova@gmail.com

INTRODUCTION

Medication-related osteonecrosis of the jaws (MRONJ) is a severe adverse drug reaction, presenting clinically with bone necrosis and destruction in the maxillofacial area.

Jaw bone necrosis, associated with medication therapy is first described by Ruggiero et al. in 2003 [1]. Within 12 months the authors identified over 35 cases of patients with bone necrosis. All the initial patients had history of malignant disease (i.e. breast cancer,

multiple myeloma, prostate cancer, lung cancer, uterine leiomyosarcoma, or leukemia), bisphosphonate (BP) exposure and no history of radiation therapy in the necrotic side. Osteonecrosis of the jaw (ONJ) is observed in approximately 5% of patients with multiple myeloma or bone metastasis (due to breast or prostate cancer) receiving high doses intravenous BPs [2]. BPs are classified into 2 groups based on the presence in the molecule of an amino functional group: aminoBPs and non-aminoBPs. Intravenous BPs are applied in the treatment of skeletal-related

events like bone metastasis from various solid tumors or bone lytic lesions in cases of multiple myeloma [3]. Oral BPs are used in the management of osteoporosis and Paget's disease [4]. Other medications associated with high risk of ONJ are anti-angiogenic drugs (bevacizumab, sunitinib, regorafenib, etc.) given alone or in combination with cytostatics or BPs and denosumab [5]. Denosumab is a human monoclonal antibody to the RANK (receptor activator of nuclear factor- κ B) ligand, involved in the osteoclastic activity. Anti-angiogenic drugs are able to impede new blood vessels formation, via blockage of the angiogenesis signaling pathways. Two types of anti-angiogenic drugs are known: monoclonal antibodies capable to block the VEGF (vascular endothelial growth factor) receptors (i.e. bevacizumab) and molecules capable to block the protein/tyrosine kinase receptors via binding (i.e. sunitinib, regorafenib).

The first definition of bisphosphonate-related osteonecrosis of the jaw (BRONJ) is described by the American Society of Bone and Mineral Research (ASBMR) as an area of exposed necrotic bone that can be probed through an intraoral or extraoral fistula in the maxillofacial region and lasts for at least 8 weeks in patients, who have been exposed to BPs and having no history of radiation therapy in the affected area [6]. A major disadvantage of this definition arises with the various clinical cases of ONJ associated with medications non-classified as BPs (anti-angiogenic drugs, denosumab, etc.). Therefore, in 2014 the American Association of Oral and Maxillofacial Surgeons (AAOMS) has suggested changing the nomenclature from BRONJ to MRONJ to accommodate the increasing number of jawbone necrosis cases due to antiresorptive (BPs, denosumab) and anti-angiogenic drugs [7].

MRONJ usually occurs several years after the anti-angiogenic and/or antiresorptive therapy has been withdrawn. Bone necrosis develops due to hypovascularity, hypocellularity and local tissue hypoxia. Long term follow-up of patients taking antiresorptive and anti-angiogenic drugs is obligatory.

The first clinical case of anti-angiogenic related ONJ is reported in 2008 [8]. Other reports demonstrate necrotic bone exposure in the jaws resulting from other medications like steroids, chemotherapeutics, methotrexate, infections, trauma, etc. [9, 10]. We present 2 rare cases of patients with a clinical presentation of exposed necrotic bone in the maxillofacial area and history of non-antiresorptive therapy.

Case 1

In September 2018, a 42-year-old male patient was referred to our clinic with complaints of pain and

swelling in the posterior left mandibular region. He had total nephrectomy for renal cancer in 2015. In January 2017 pulmonary metastases were reported and anticancer therapy was started. Sunitinib (25.0-50.0 mg daily) was given orally from March 2017 to October 2017. During this period a mandibular left wisdom tooth had been extracted. The patient visited our clinic a few months later with a non-healing extraction wound (Fig. 1).

Intraorally we revealed an 10x8 mm area of exposed necrotic, sharp-edged bone and non-healing extraction wound distally to the left second mandibular molar. Suppuration and granulation tissue were observed. The remaining teeth in the oral cavity were stable.

We first treated the exposed necrotic bone and the extraction wound conservatively for 5 weeks. On the second stage we performed sequestrectomy as soon as the necrotic bone was demarcated. Long term follow-up revealed no recurrence of ONJ and satisfactory postoperative results. The patient still visits our clinic every 3 months.

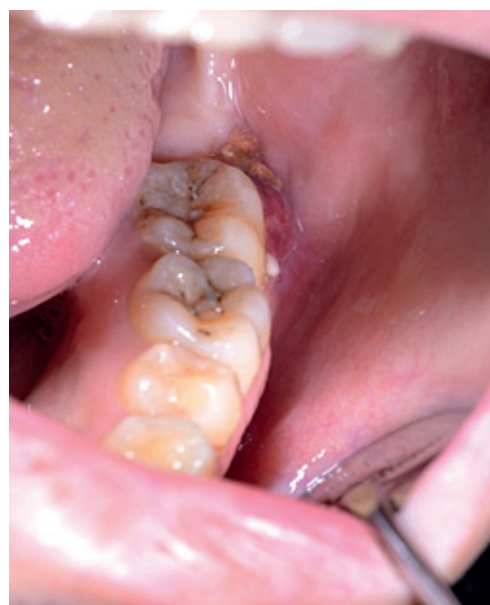

Fig. 1. Intraoral image showing exposed necrotic bone, redness and suppuration in the area of previously extracted mandibular left wisdom tooth

Case 2

A 31-year-old male patient presented in our clinic with exposed necrotic bone on the hard palate. In September 2018 the patient was diagnosed with acute myelogenous leukemia. He had received 2 courses of chemotherapy with MitoFLAG (Fludarabine, Arabinoside, cytosine arabinoside and Granulocyte colony-stimulating factor). During the second chemotherapy a painless, red and relatively fast-growing lesion appeared

spontaneously on the hard palate, followed by bone exposure. The patient had no history of trauma in the oral cavity and on the hard palate in particular. On the first clinical examination we found 3 x 2.6 cm necrotic bone on the hard palate with no symptoms of pain, suppuration or bleeding (Fig. 2). We recommended conservative treatment with systemic antibiotics and chlorhexidine for topical application, as well as a good oral hygiene. After the total demarcation of the necrotic bone we performed sequestrectomy – the sequester consisted of part of the hard palate and the nasal septum. A palatal obturator was used to occlude the oro-nasal communication.

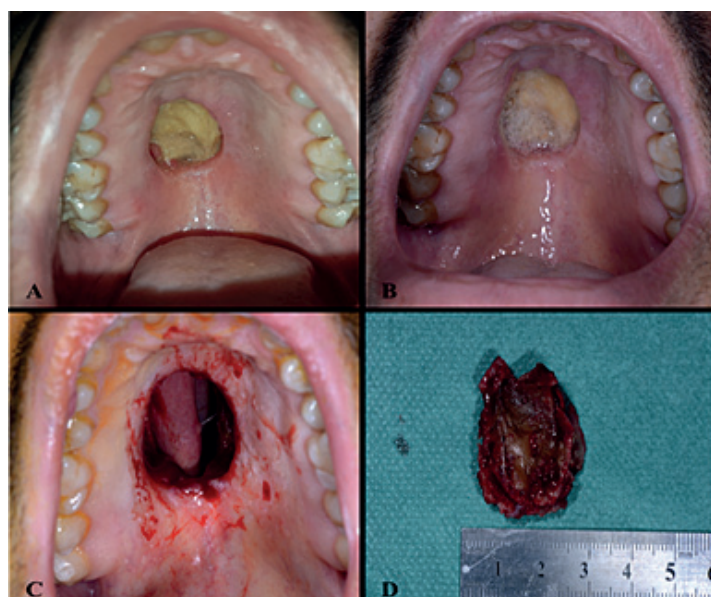


Fig. 2. Bone necrosis on the hard palate related to chemotherapy; **A**-before the demarcation of the necrotic bone; **B**-after the demarcation of the necrotic bone; **C**-immediately after sequestrectomy; **D**-the surgically removed sequester is shown

DISCUSSION

Despite the favorable outcomes with bisphosphonates therapy and anti-resorptive drugs, their application is associated with a high risk of complications that impair the quality of life. The main clinical symptoms of MRONJ are swelling, exposed necrotic bone, suppuration, halitosis, sequestration, fistulization, etc. [11]. MRONJ may evolve spontaneously or may result from invasive dental surgical procedures (i.e. tooth extraction, dental implant placement, incision). MRONJ is a relatively rare complication in osteoporotic patients taking antiresorptive drugs orally. In cancer patients with bone metastases, where BPs are used intravenously at higher doses in shorter intervals, the incidence of MRONJ is significantly higher. MRONJ is known to be related to the dose and the duration of exposure. A highly aggressive course of the disease is observed in patients with severe additional systemic diseases (i.e. rheumatic arthritis) [12].

Currently the data about the risk of MRONJ associated with anti-angiogenic drugs and chemotherapeutics is still insufficient.

Evidence suggests the anti-angiogenic effect of BPs as a key role in the development of MRONJ [13]. Thus, the adverse side effects of BPs on the tissue regeneration seem to be similar to the effects of the anti-angiogenic drugs. The formation of new blood vessels in tissues is controlled by the balance between pro- and anti-angiogenic factors. Vascular endothelial growth factor (VEGF) is an essential element for optimal progression of angiogenesis and neo-angiogenesis during the embryonic development, skeletal growth, and reproduction. VEGF also participates in the pathological neo-angiogenesis of tumor growth and metastasis [14]. Increased expression of VEGF in tumor cells is a poor prognostic marker [15, 16]. VEGF and its receptors (VEGF-R) are the main targets for multiple tyrosine kinase inhibitors, MAP-kinase modulators, and VEGF-signaling pathway modulating drugs [17]. Anti-angiogenic drugs are capable of interfering with VEGF's activity. Angiogenic inhibitors are more recently introduced in the clinical practice and are becoming a part of the antitumor therapy in patients with breast cancer, colorectal cancer, lung carcinoma, renal tumors and glioblastoma multiforme [18]. Based on their mechanism of action, three groups of anti-angiogenic drugs are well-known nowadays: anti-VEGF monoclonal antibodies (**bevacizumab**), medications, capable to directly block VEGF-R (**afibercept**) and tyrosine-kinase inhibitors (**sunitinib**, **sorafenib**) [19].

Our research is tightly concentrated on the mechanism of action of the anti-angiogenic drugs, the side effects and risk of jaw bone necrosis during or after their application in cancer patients.

Bevacizumab is a monoclonal antibody capable to block VEGF-molecules, as it interferes with their binding to VEGF-R [19]; thus it inhibits the neo-angiogenesis, tumor growth and metastases [20]. Bevacizumab is the first anti-angiogenic drug approved for clinical use by the Food and Drug Association (FDA). It is often prescribed to patients with renal carcinoma, colorectal carcinoma, lung carcinoma, etc. [19]. Common adverse side effects during or after bevacizumab therapy are thromboembolism, hypertension, hemorrhage, impaired wound healing [8, 18, 19]. There are reports in the literature about ONJ related to bevacizumab, with the first clinical case described by Estilo et al. in 2008 [8]. In their study bevacizumab

is given at a dose of 15 mg/kg every 3 weeks in a combination with other non-BPs therapeutic agents. Eight weeks after the 6th application of bevacizumab a necrotic zone had been observed. Total recovery of the necrotic bone was achieved once the medication had been withdrawn and chlorhexidine was applied. However, the authors reported newly formed zones of necrotic bone within the next couple of weeks. At the same time another case of a patient taking bevacizumab resulting in a non-healing extraction wound and ONJ on the upper jaw was published [21]. All the reported cases of ONJ in patients taking bevacizumab [8, 21, 22, 23, 24, 25, 26] reveal that cessation of the anti-angiogenic drug in combination with antibiotics with or without surgical debridement promote healing in the necrotic tissues. In some of the reported cases, surgical procedure with bone exposure (i.e. tooth extraction) precedes ONJ [21], but spontaneous necrosis is commonly found. However, long term follow-up is required to avoid local complications and newly formed necrotic zones.

It has been reported that bevacizumab as a monotherapy is not associated with the development of MRONJ in the jawbone [26, 27]. According to the authors, bevacizumab may cause MRONJ only if taken in a combination with BPs. It is reported in the literature that bevacizumab in combination with BPs increases the risk of spontaneous ONJ with 2-2,4% [28]. According to a meta-analysis the risk of spontaneous ONJ in patients taking bevacizumab as a single therapy and bevacizumab in a combination with BPs is 0,2% and 0,9%, respectively [23]. The risk of necrosis is significantly increased in patients with history of trauma or other invasive procedures in the oral cavity and the maxillofacial region. The increased risk of MRONJ due to bevacizumab therapy is probably related to the compromised vascular wall integrity and insufficient angiogenesis in the tissues. Blockage of the VEGF's active molecule results in: suppression of the of endothelial cells' mitotic activity of the blood vessels, increased vascular permeability and local tissue hypoxia [23]. However, the data is currently insufficient and further research is required to have a solid statement about the risk of developing spontaneous ONJ in patients taking bevacizumab monotherapy.

Cases of spontaneous osteonecrosis (non-induced by trauma or surgery) in other parts of the body (hips, shoulders), in patients treated with bevacizumab have been reported in the literature [29, 30]. According to the authors, the incidence of spontaneous osteonecrosis outside the maxillofacial region following treatment with anti-angiogenic drugs is 4 per 1 000 patients [30]. The number of these cases is expected

to increase as bevacizumab and its analogues have become commonly prescribed to cancer patients.

Other anti-angiogenic drugs are considered to be associated with increased risk of MRONJ (regorafenib, sunitinib, sorafenib) [31, 32, 33]. Sunitinib is an orally administered medication, classified as a tyrosine-kinase inhibitor, capable to suppress tumor cell proliferation and neo-angiogenesis, as its molecule inhibits the action of VEGF. It results in significant reduction of the tumor size. The most common side effects of sunitinib are fatigue, diarrhea, nausea and vomiting, heartburn, taste changes, hypertension (high blood pressure), low blood counts, skin discoloration, fever, bleeding, etc. These adverse effects could be sometimes managed with dose adjustment and no discontinuation of the therapy is needed.

The first clinical case of sunitinib related ONJ is described by Koch et al. (34). They report a case of 59-year-old patient with nephrectomy due to renal carcinoma and soft tissue metastases. At first the patient had taken interferon and vinblastine and when the relapse occurred the medication prescribed was sorafenib later replaced by sunitinib. ONJ was observed 1 year after the initial therapy with sunitinib. The patient is having no history of BPs or other antiresorptive drugs intake. Argillo et al. [35] reported 2 cases of patients with renal carcinoma, lung and bone metastases taking combined chemotherapy, together with zoledronic acid and sunitinib. In the first case painful swelling on the right maxilla and oro-antral communication appeared. A couple of months after surgery bone exposure and suppurative infection extended to the sphenoidal sinuses were observed. In the second case painful swelling, spontaneous bone exposure and teeth instability appeared on the lower jaw, followed by sequestration and a pathological fracture.

We assume that sunitinib exposure puts the patient at risk of jawbone necrosis. The risk of ONJ is expected to significantly increase when sunitinib is given in a combination with BPs. However, in case 1 our patient presented with jaw necrosis after tooth extraction and we found no other risk factors except for sunitinib given as a single therapy for lung metastases. We may conclude that anti-angiogenic drugs are capable to cause osteonecrosis when given alone. On the other hand we noticed that the ONJ in this case is self-limiting and relatively easy to manage with antibiotics, antiseptics and minor surgery, without any high risk of recurrence.

Chemotherapy taken by a wide range of patients with various neoplasms, usually impairs both the cellular and humoral immune response and destroys

rapidly proliferating cancer cells, as well as normal cells with short cell cycles (rapidly-dividing), i.e. bone marrow cells, epithelial cells, etc. In 1982 Schwartz [36] reported 2 unusual cases of osteonecrosis in edentulous patients with immune-compromised host defense due to cancer chemotherapy. Both patients developed mucosal infection beneath their dentures followed by bone necrosis. Inflammatory complications are expected in patients receiving BPs and/or chemotherapeutics due to malignancy. In most of the clinical cases, MRONJ occurs after a surgical procedure, like tooth extraction. It's been reported that tooth extraction precedes ONJ in 61.8% of the cases [37]. However, we report a case of a patient with spontaneously occurring necrosis on the hard palate, related to combined chemotherapy for acute myeloblastic leukemia. Inflammatory complications, like redness, swelling, suppuration, enlarged regional lymph nodes, were not observed during the patient's stay in our clinic and thereafter. We noticed the fact that the bone necrosis in this case is less aggressive and self-limiting when compared to MRONJ associated with BPs. However, the susceptibility of the bones to severe infections in patients who are receiving cytotoxic drugs is established.

The risk of MRONJ could be decreased or even eliminated when detailed inspection and assessment of the patients' oral status and total sanitation of the oral cavity are conducted prior and during the treatment with monoclonal antibodies, anti-angiogenic drug and chemotherapeutics. [38]. Teeth susceptible to inflammatory complications should be extracted 14-21 days prior to the medication therapy and the oral status should be monitored every 3 months during the first 2 years of onset of therapy and twice a year thereafter [38]. Cessation of the alcohol consumption and smoking is strongly recommended when reduction of the osteonecrosis risk is needed. At this point, the evidence is scarce (only single clinical cases are reported) and more systemic studies are needed for the better assessment of the risk of medication-related complications in cancer patients taking monoclonal antibodies and tyrosine kinase inhibitors.

The above mentioned cases illustrate the susceptibility of the jaw bones to inflammatory complications and osteonecrosis in patients receiving chemotherapeutic drugs. The treatment of choice we recommend is more conservative with a broad spectrum antibiotics and surgical debridement of the affected jaw bone, as well as sequestrectomy after the total demarcation of the necrotic bone. We strongly recommend avoidance of extensive surgical procedures when the necrotic bone is non-well demarcated. The

patients should be aware of trauma and injuries leading to bone exposure.

CONCLUSION

MRONJ is nowadays one of the most common pathologies in the maxillofacial region. The number of the case reports in the literature, of patients with ONJ showing no other cause but previous anti-resorptive and anti-angiogenic therapy due to cancer and bone metastasis is constantly increasing. However, systemic studies on MRONJ associated with chemotherapeutics, sunitib and its analogues are still insufficient. At this stage, it can certainly be concluded that prophylaxis, enhancement of the health culture and oral hygiene of patients reduce the risk of MRONJ. With the increased number of patients taking anti-resorptive and anti-angiogenic drugs, the cases of patients having complications like jawbone necrosis, swelling, suppuration, fistulization, etc. is expected to progressively expand. Long-term monitoring and care of patients taking anti-resorptive and anti-angiogenic therapy is required.

The purpose of our study is to review adequate information about the risk of MRONJ in the maxillofacial region and to compare the severity of the symptoms and clinical presentation of ONJ in patients on anti-angiogenic drugs and combined chemotherapy. Based on what we found in the literature and our clinical experience we see significant differences in the clinical course, progression and the outcomes of jawbone necrosis, related to BPs, monoclonal antibodies, anti-angiogenic drugs and chemotherapy. Monoclonal antibodies and antiresorptive drugs are associated with a risk of much more aggressive ONJ when compared with chemotherapy and sunitinib given alone. Therefore, the treatment and the prognosis of patients with MRONJ should be individually estimated and conducted.

Conflict of interest

The authors declare no conflict of interest.

REFERENCES

1. Ruggiero SL. Bisphosphonate-related osteonecrosis of the jaw (BRONJ): Initial discovery and subsequent development. *J Oral Maxillofac Surg.* 2009, 67, 13-18.
2. Reid IR: Osteonecrosis of the jaw: Who gets it, and why? *Bone,* 2009, 44, 4-10.
3. Berenson JR, Hillner BE, Kyle RA, et al. American Society Of Clinical Oncology Clinical Practice Guidelines: The role of

- bisphosphonates in multiple myeloma. *J Clin Oncol*. 2002, 20, 3719–36.
4. Delmas PD. The use of bisphosphonates in the treatment of osteoporosis. *Curr Opin Rheumatol*. 2005;17,462-466.
5. Aragon-Ching JB, Ning YM, Chen CC et al. Higher incidence of osteonecrosis of the jaw (ONJ) in patients with metastatic castration-resistant prostate cancer treated with antiangiogenic agents. *Cancer Invest*, 2009, 27, 221-226.
6. Khosla S, Burr D, Cauley J et al. American Society for Bone and Mineral Research: Bisphosphonate-associated osteonecrosis of the jaw: Report of a task force of the American Society for Bone and Mineral Research. *J Bone Miner Res*, 2007, 22, 1479-1491.
7. Ruggiero SL, Dodson TB, Fantasia J, et al. American Association of Oral and Maxillofacial Surgeons. American Association of Oral and Maxillofacial Surgeons position paper on medication-related osteonecrosis of the jaw – 2014 Update. *J Oral Maxillofac Surg*, 2014, 72(10), 1938-1956.
8. Estilo CL, Fornier M, Farooki A. et al. Osteonecrosis of the jaw related to bevacizumab. *J. Clin. Oncol*. 2008, 26, 4037-4038.
9. Horie N, Kawano R, Kaneko T, Shimoyama T. Methotrexate-related lymphoproliferative disorder arising in the gingiva of a patient with rheumatoid arthritis. *Austr Dent J*, 2015, 60(3), 408-411.
10. Sung EC, Chan SM, Sakurai K, Chung E. Osteonecrosis of the maxilla as a complication to chemotherapy: a case report. *Spec Care in Dentist*, 2002, 22(4), 142-146.
11. Poxleitner P, Engelhardt M, Schmelzeisen R, Voss P. The prevention of medication-related osteonecrosis of the jaw. *Deutsch Ärzteblatt Internat*, 2017, 114(5), 63-69.
12. Ebker T, Rech J, Von Wilmowsky C et al. Fulminant course of osteonecrosis of the jaw in a rheumatoid arthritis patient following oral bisphosphonate intake and biologic therapy. *Rheumatology*, 2013 52, 218-220.
13. Hansen T, Kunkel M, Weber A, James Kirkpatrick C. Osteonecrosis of the jaws in patients treated with bisphosphonates—histomorphologic analysis in comparison with infected osteoradionecrosis. *J Oral Pathol Medi*, 2006, 35(3), 155-160.
14. Ferrara N, Davis-Smyth T. The biology of vascular endothelial growth factor. *Endocr Rev*. 1997;18:4–25.
15. Maeda K, Chung YS, Ogawa Y, et al. Prognostic value of vascular endothelial growth factor expression in gastric carcinoma. *Cancer (Phila)*, 1996;77:858-63.
16. Yamamoto S, Yasui W, Kitadai Y, et al. Expression of vascular endothelial growth factor in human gastric carcinomas. *Pathol Int*, 1998;48:499-506.
17. Brunello A, Borgato L, Basso U, et al. Targeted approaches to triple-negative breast cancer: Current practice and future directions. *Curr Med Chem* 20: 605-612, 2013.
18. De Falco S, Antiangiogenesis therapy: an update after the first decade, *Korean J Int Med*, 2014, 29(1), 1-11.
19. Al-Husein B, Abdalla M, Trepte M, et al. Antiangiogenic therapy for cancer: an update, *Pharmacotherapy*, 2012 32(12), 1095-1111.
20. Hopp RN, Pucci J, Santos-Silva AR, Jorge J. ONM after administration of intravitreal bevacizumab. *J Oral Maxillofac Surg* 2012, 70, 632–635.
21. Greuter S, Schmid F, Ruhstaller T, Thuerlimann B. Bevacizumab-associated osteonecrosis of the jaw. *Ann Oncol* 2008, 19,2091-2092.
22. Serra E, Paolantonio M, Spoto G, et al. Bevacizumab-related osteonecrosis of the jaw. *Int J Immunopathol Pharmacol* 2009, 22, 1121–1123.
23. Guarneri V, Miles D, Robert N, et al. Bevacizumab and osteonecrosis of the jaw: Incidence and association with bisphosphonate therapy in three large prospective trials in advanced breast cancer. *Breast Cancer Res Treat* 2010, 122, 181-818.
24. Hopp RN, Pucci J, Santos-Silva AR, Jorge J. ONM after administration of intravitreal bevacizumab. *J Oral Maxillofac Surg* 2012, 70, 632-635.
25. Sato M, Ono F, Yamamura A, Onochi SN. A case of osteonecrosis of the jaw during treatment by bevacizumab for sigmoid colon cancer. *Shokakibyō Gakkai Zasshi* 2013, 110(4), 655-659.
26. Tzermpos F, Ismail A, Pavli M, Tosios KI. Osteonecrosis of the mandible in a patient with lung adenocarcinoma undergoing anti-angiogenic therapy with bevacizumab. *Oral Surg*, 2016, 9(1), 40-46.
27. McArthur HL, Estilo C, Huryn J, et al. Osteonecrosis of the jaw (ONJ) among intravenous (IV) bisphosphonate- and/or bevacizumab-treated patients (pts) at Memorial Sloan-Kettering Cancer Center (MSKCC). *J Clin Oncol* 2008; 26, 9588.
28. Van Poznak C. Osteonecrosis of the jaw and bevacizumab therapy. *Breast Cancer Res Treat*, 2010, 122, 189-191.
29. Fangusaro J, Gururangan S, Jakacki RI, et al. Bevacizumab-associated osteonecrosis of the wrist and knee in three pediatric patients with recurrent CNS tumors. *J Clin Oncol* 2013, 31, e24-e27.
30. Tabouret T, Gregory T, Dhooge M, et al. Long term exposure to antiangiogenic therapy, bevacizumab, induces osteonecrosis. *Invest new drugs*, 2015, 33(5), 1144-1147.
31. Antonuzzo L, Lunghi A, Giommoni E, et al. Regorafenib also can cause osteonecrosis of the jaw. *JNCI*, 2016,108(4).
32. Melloni C, Tuttolomondo A, Anfosso A, et al. Sunitinib related osteonecrosis of the jaw (SURONJ): a rare occurrence? *Eur J Plast Surg*, 2016, 39(2), 161-162.
33. Garuti F, Camelli V, Spinardi L, et al. Osteonecrosis of the jaw during sorafenib therapy for hepatocellular carcinoma. *Tumori Journal*, 2016, 102 (2_suppl), S69-S70.
34. Koch FP, Walter C, Hansen T, et al. Osteonecrosis of the jaw related to sunitinib. *Oral and maxillofacial surgery*, 2011, 15(1), 63-66.
35. Agrillo A, Nastro Siniscalchi E, Facchini A, et al. Osteonecrosis of the jaws in patients assuming bisphosphonates and sunitinib: two case reports. *Eur Rev Med Pharmacol Sci*, 2012 16(7), 952-957.
36. Schwartz HC. Osteonecrosis of the jaws: a complication of cancer chemotherapy. *Head & neck surgery*, 1982, 4(3), 251-253.
37. Saad F, Brown JE, Van Poznak C, et al. Incidence, risk factors, and outcomes of osteonecrosis of the jaw: integrated analysis from three blinded active-controlled phase III trials in cancer patients with bone metastases. *Ann oncol*, 2012, 23(5):1341-1347.
38. Owosho, AA, Liang, STY, Sax, AZ, et al. Medication-related osteonecrosis of the jaw: An update on the memorial sloan kettering cancer center experience and the role of premedication dental evaluation in prevention. *Oral Surg Oral Med Oral Pathol Oral Radiol Endod*, 2018, 125(5), 440-445.