

Scientific paper

DOI: 10.2478/10004-1254-64-2013-2322

## EFFECTS OF TAURINE AGAINST HISTOMORPHOLOGICAL AND ULTRASTRUCTURAL CHANGES IN THE TESTES OF MICE EXPOSED TO ALUMINIUM CHLORIDE

Ashraf M. ABDEL-MONEIM<sup>1,2</sup>

King Faisal University, College of Science, Department of Biological Sciences, Ahsaa, Saudi Arabia<sup>1</sup>, University of Alexandria, Faculty of Science, Department of Zoology, Alexandria, Egypt<sup>2</sup>

Received in November 2012

CrossChecked in April 2013

Accepted in June 2013

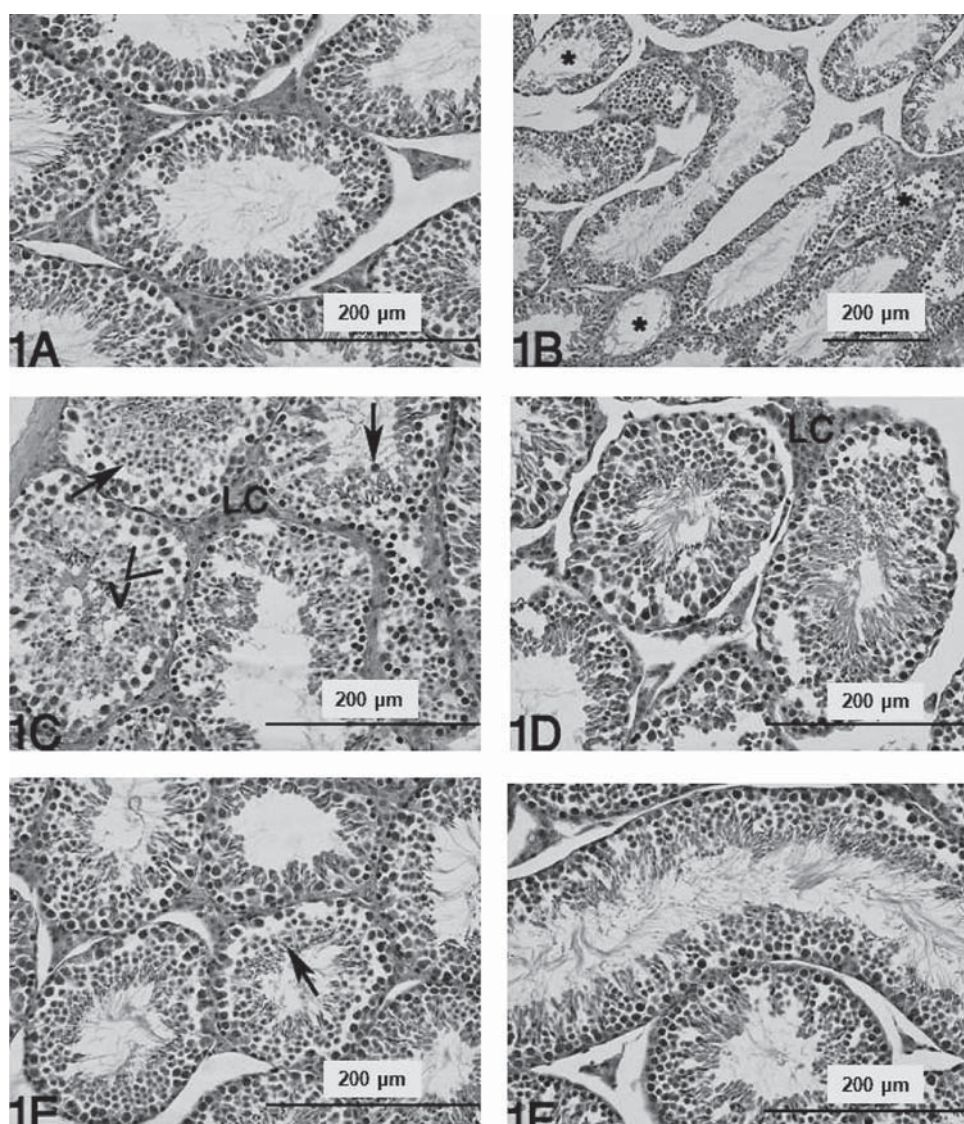
The aim of this study was to investigate the protective effects of taurine against histomorphological and ultrastructural changes in the testes of Swiss albino mice caused by acute *in vivo* exposure to  $\text{AlCl}_3$ . Light microscopy revealed that a single intraperitoneal (*i.p.*) dose of  $\text{AlCl}_3$  ( $25 \text{ mg kg}^{-1} \text{ Al}^{3+}$ ) was associated with sloughing, tubular atrophy, germ-cell degeneration, and foci of Leydig cell hyperplasia. In addition, transmission electron microscopy showed a destruction of inter-Sertoli cell tight junctions, apoptotic cell death of spermatogonia and primary spermatocytes, various types of abnormalities in spermatid morphology, accumulation of lipid droplets, reduction of the smooth endoplasmic reticulum (sER), and mitochondrial damage in Leydig cells. Taurine post-treatment at *i.p.* dose of  $1 \text{ g kg}^{-1}$  diminished these changes and significantly reduced the number of affected tubules compared to Al-poisoned mice. This is the first study to evidence that taurine protects against pathological changes in the testicular tissue of Al-treated mice.

**KEY WORDS:** *histopathology, male reproductive system, spermatogenesis, toxic metal, ultrastructure*

There is an increasing concern about aluminium (Al) poisoning in humans. Aluminium accumulates more frequently in patients receiving long-term haemodialysis or Al-containing medications (1). Al toxicity contributes to several human diseases such as microcytic hypochromic anaemia, encephalopathy, osteomalacia, and Alzheimer's disease (2-5). Other studies have pointed to the hepatotoxicity and genotoxicity of Al (6, 7). Moreover, it was proposed that Al exposure might interfere with male reproductive capacity (8). High concentrations of Al in human semen, seminal plasma, spermatozoa, blood, and urine have been linked to poor sperm quality and viability (8-10). In addition, exposure to Al has been reported to affect testicular development and testosterone

synthesis in experimental animals (11-15). Although it was shown that Al is capable of compromising male fertility by inducing a state of oxidative stress in the testes (14, 16), other mechanisms such as inhibition of microtubule assembly (17) could also be involved in Al-induced testicular damage.

Natural antioxidants can reduce the risk of various diseases and also protect tissues and organs from various environmental contaminants. In this regard, taurine (TAU) might be a promising agent in the treatment of Al poisoning. It is a conditionally essential amino acid, not involved in protein synthesis, and mostly unbound or found in simple peptides. Its structure is different from most biological amino acids in that it contains a sulphur group instead of carboxylic



**Figure 1** Photomicrographs of mice testicular cells stained with haematoxylin and eosin. (A) Control group showing regularly arranged seminiferous tubules and interstitium. (B-D) Al-treated group; note tubular atrophy (asterisk, in B), arrows point to sloughing of degenerated germ cells into tubule lumen, LC: Leydig cells, V: tubule vacuolisation (in C), focal hyperplasia of Leydig cells (LC) is seen adjacent to damaged tubule (in D). (E) Al+TAU group showing almost normal spermatogenesis. Arrow illustrates sloughing of seminiferous epithelium. (F) TAU alone group is comparable to control. Scale bar: 200 µm (A-F).

acid and that it is a beta-amino acid as opposed to alpha-amino acid. Taurine is known to participate in several metabolic actions, including formation of bile salts in the liver, membrane stabilisation, osmoregulation, and modulation of neurotransmission and intracellular calcium influx (18). Several studies (19-22) have demonstrated the therapeutic effects of taurine against heavy metals and some drugs (23-24), but its action against Al-induced testicular damage has not been studied so far. The aim of this study was to fill in this gap by looking into the therapeutic effects of taurine against Al overdose through histopathological and ultrastructural changes in testis cells of mice.

## MATERIALS AND METHODS

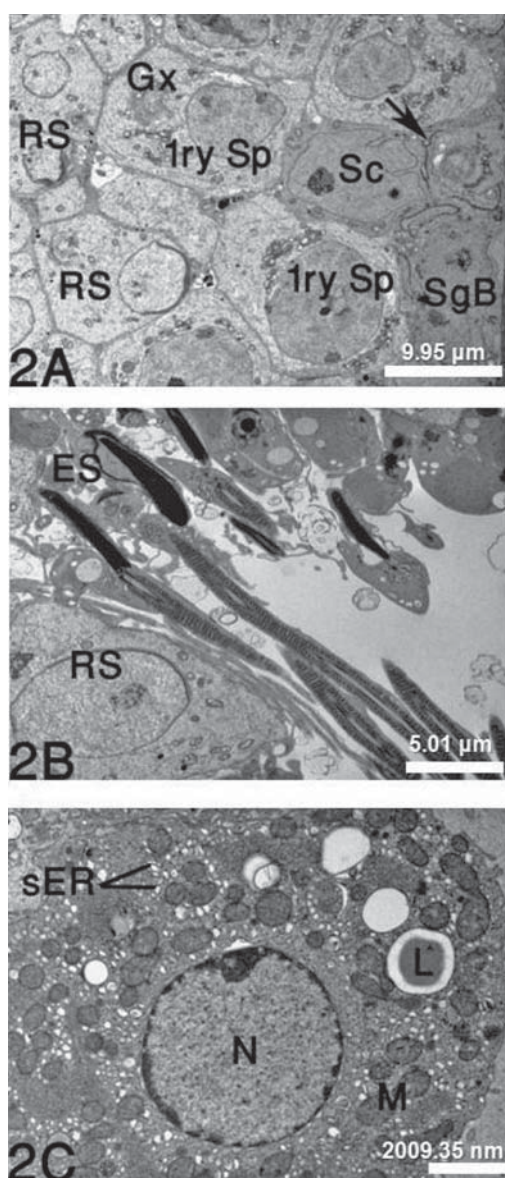
### Chemicals

$\text{AlCl}_3$ , taurine, and other reagents used in this experiment were supplied by Sigma-Aldrich Corporation (St. Louis, MO, USA).

### Animals and treatments

Male Swiss albino mice weighing 15 g to 20 g were procured from the College of Veterinary Medicine, King Faisal University, Saudi Arabia. The animals were housed in polypropylene cages and





**Figure 2** Transmission electron micrographs of control mice testicular cells. (A) Sertoli cell (Sc), spermatogonia type B (SgB), primary spermatocyte (1ry Sp) with a well-developed Golgi complex (Gx), and round spermatids (RS). Tight junctions between adjacent Sertoli cells are indicated by arrow. (B) Round spermatids (RS) and elongated spermatids (ES) in the adluminal compartment. (C) Leydig cell with few lipid droplets (L), numerous mitochondria (M) and abundant smooth ER (sER). N: nucleus. Scale bars: 10  $\mu$ m (A), 5  $\mu$ m (B), 2  $\mu$ m (C).

maintained under controlled temperature ( $25 \pm 2$ )  $^{\circ}$ C, relative humidity ( $50 \pm 15$ ) %, and 12/12-hour light/dark cycle. The animals had free access to standard pellet diet and drinking water. After a 10-day acclimatisation, the animals were randomly assigned to four groups with five animals each. The control group received a single intraperitoneal (*i.p.*) injection of physiological saline. The Al group received an *i.p.*

injection containing 25 mg  $\text{kg}^{-1}$  of  $\text{Al}^{3+}$ . In addition to  $\text{Al}^{3+}$ , the Al+TAU group received a single *i.p.* dose of 1 g  $\text{kg}^{-1}$  of taurine, shortly after  $\text{AlCl}_3$  injection. The TAU group received a single *i.p.* injection of taurine alone (1 g  $\text{kg}^{-1}$ ). The doses were selected based on earlier *in vivo* studies (19, 25). Mice from each group were killed by cervical decapitation under light ether anaesthesia 24 h after injection. Experimental design conformed to the NIH standards for the care and use of laboratory animals.

#### Light microscopy

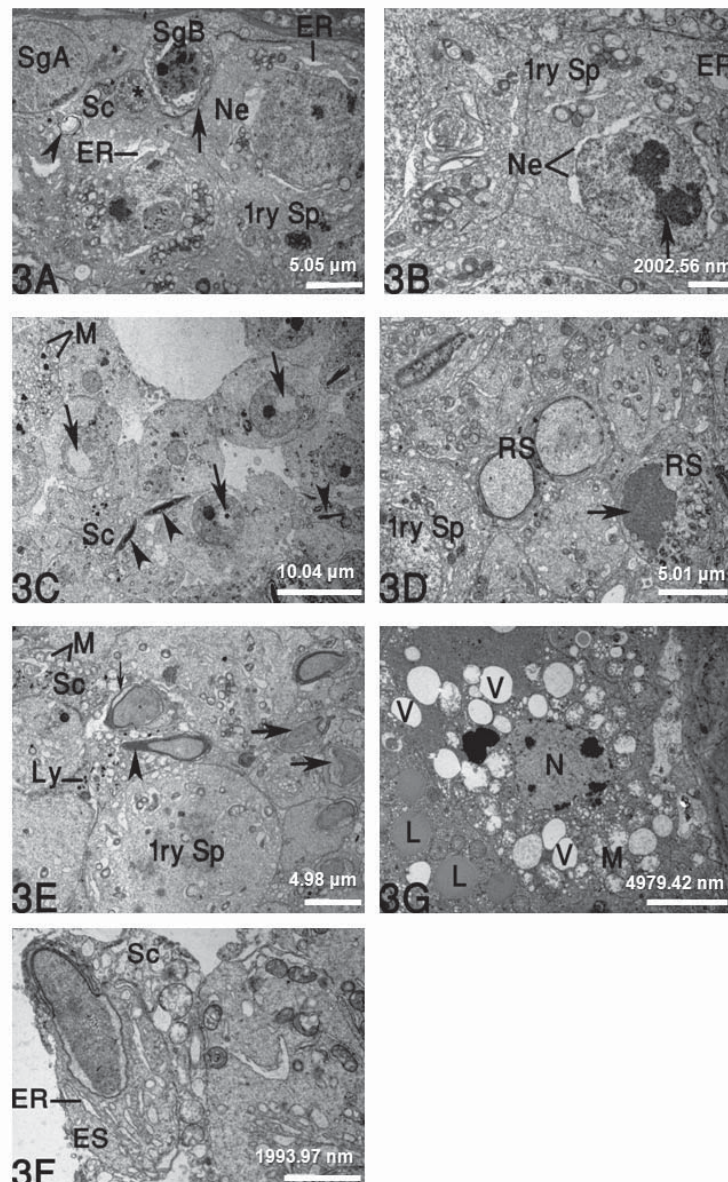
Testicular tissue samples were immediately fixed in 10 % buffered formalin, dehydrated in ascending grades of ethanol, and embedded in paraffin. Five to six micrometer thick sections were sliced using a rotary microtome, stained with haematoxylin and eosin, and examined under a light microscope (Olympus America Inc., Center Valley, PA, USA). Quantitative histopathological analyses of seminiferous tubules was blinded according to the method of Sayim (26) and included 100 tubules per animal to be categorised as follows: “normal”, “sloughing” with broken cellular association, “atrophic” with scarce or no germ cells, and “germ-cell degeneration” with multinucleated giant cells.

#### Electron microscopy

Small pieces of 1 mm thick testes samples were fixed in 2.5 % glutaraldehyde in sodium cacodylate buffer (pH 7.2) for (24 to 48) h, postfixed for 2 h in 1 % osmium tetroxide solution at 4  $^{\circ}$ C, dehydrated in graded ethanol series, and embedded in Epon-araldite mixture (Embed-812). Ultra-thin sections (40 nm to 60 nm thick) were sliced with a diamond knives using a Leica EM UC6 ultramicrotome (Leica Co., Austria), transferred to 200 mesh copper grids, and double-stained with 2 % uranyl acetate and lead citrate. Grids were viewed on a transmission electron microscope (Jeol JEM 1011, Jeol Ltd., Japan) operated at 80 kV.

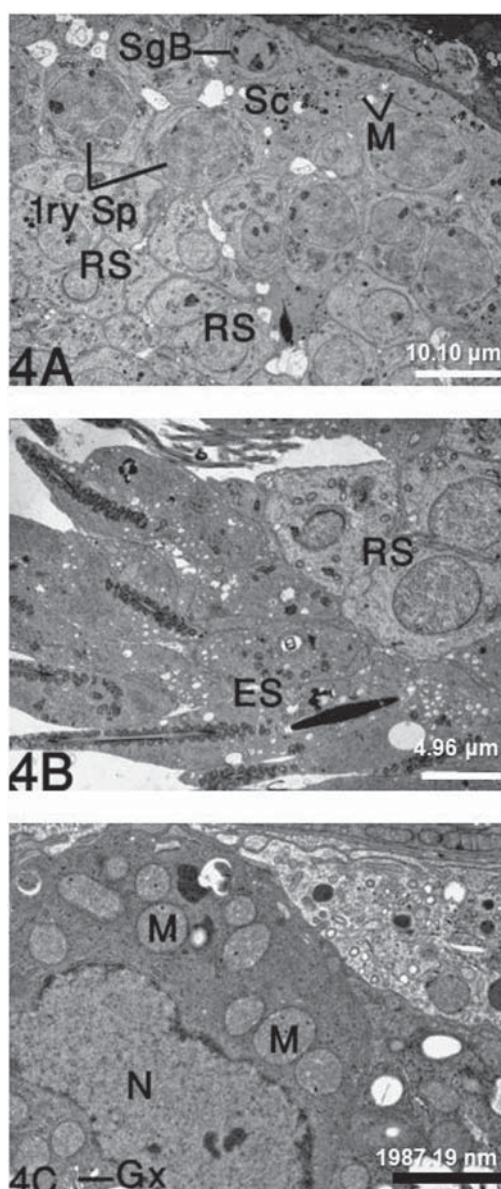
#### Statistics

Data obtained with histopathological analyses were evaluated with the Kruskal-Wallis variance analysis and post-hoc Mann-Whitney U-test using SPSS software (version 17.0; SPSS Inc., Chicago, IL, USA). A *p* value  $< 0.05$  was considered significant.



**Figure 3** Transmission electron micrographs of the testicular cells in Al-treated mice. (A) Spermatogonia type B (SgB) displays morphological characteristics of apoptosis, including cell shrinkage, blebbing or swelling of nuclear envelope, and excessive chromatin condensation. Also note damaged primary spermatocytes (1ry Sp) with notable swelling of the nuclear envelope (Ne) and dilatations of endoplasmic reticulum (ER). Inter-Sertoli cell tight junctions show numerous membrane discontinuities (arrow). Sc: Sertoli cell, arrowhead points to a myelin figure, (\*) indicates phagocytic vesicle, SgA: spermatogonia type A. (B) Apoptotic primary spermatocyte (1ry Sp) presenting large bodies of condensed chromatin (arrow), swelling of nuclear envelope (Ne), and enlargement of ER membranes. (C) Round spermatids with abnormal positioning of many acrosomal vesicles (arrows). Elongated spermatids (arrowheads) can be seen embedded in the Sertoli cell (Sc) cytoplasm, which also contains swollen mitochondria with degenerated or missing cristae (M). (D) Early-stage spermatids with deleterious nuclear changes. Note intense chromatin density in spermatid nucleus (arrow). 1ry Sp: primary spermatocyte, RS: round spermatids. (E) Elongated spermatids at the initial stage of chromatin condensation. Note various nuclear invaginations in acrosome-deficient spermatids (thick arrows), wide subacrosomal space (thin arrow), and sharply pointed acrosome (arrowhead). 1ry Sp: primary spermatocyte, Sc: Sertoli cell, M: mitochondria, Ly: lysosomal elements. (F) Elongated spermatid (ES) near the tubule lumen still shows markedly dilated ER. Sc: Sertoli cell. (G) Leydig cell showing accumulation of large lipid droplets (L). Note disintegrated mitochondria (M), large cytoplasmic vacuoles (V), and nucleus (N) with perinuclear chromatin condensation. Scale bars: 5  $\mu$ m (A, D, E, G, H), 2  $\mu$ m (B, F), 10  $\mu$ m (C).





**Figure 4** Transmission electron micrographs of the testicular cells in mice treated with Al+TAU. (A) Spermatogonia B (SgB) have normally shaped nucleus. Primary spermatocytes (1ry Sp) show normally dispersed chromatin without cytoplasmic vacuolisation. Round spermatids (RS) have a normally shaped acrosomal cap. Sertoli cell (Sc) cytoplasm contains normal mitochondria (M). (B) Note undamaged round spermatids (RS) and elongated spermatids (ES) with normal contact with the Sertoli cell. (C) Intact Leydig cell. N: nucleus, M: mitochondria, Gx: well-developed Golgi complex. Scale bars: 10 µm (A), 5 µm (B), 2 µm (C).

## RESULTS

### Histopathology

The testes of control mice had a normal histological pattern, with well-organised seminiferous tubules

containing spermatogenic cells at different stages of maturation. Leydig cells presented as scattered clusters in the interstitial tissue (Figure 1A). In the Al-treated mice, the seminiferous tubules were mostly irregular in shape, and some of the tubules were atrophied with moderate to severe loss of spermatogenic cell layers (Figure 1B). Degenerated cellular material with darkly stained nuclei was sloughed into the lumen of tubules, indicating a breach in the blood-testis barrier (Figure 1C). The seminiferous tubules displayed focal areas of vacuolar degenerative changes in the cytoplasm of spermatogenic cells and in the Sertoli cells. Foci of Leydig cell hyperplasia were also observed (Figure 1D). Acute lesions caused by Al were substantially remedied by taurine in the Al+TAU group (Figure 1E). The number of affected tubules was significantly lower than in the Al group (Table 1). Tubular atrophy and cellular degeneration were not seen in the seminiferous tubules, but a mild detachment (*i.e.*, sloughing) of germ cells was still noted. The testicular histoarchitecture in mice treated with taurine alone was normal and without changes in germ cell shape and organisation (Figure 1F).

### Ultrastructural changes

In control mice, electron micrographs showed the normal structure of seminiferous tubules (Figure 2A-B). Sertoli cells were identified by their large indented nuclei, numerous mitochondria, rough endoplasmic reticulum (rER), and lipid inclusions. These Sertoli cells, closely connected by many tight junctions, separated spermatogonia from primary spermatocytes. Two types of spermatogonia could be distinguished: type A spermatogonia, with ovoid and lightly stained nuclei, and type B spermatogonia, with smaller, spherical nuclei of a more electron-dense nucleoplasmic matrix. In primary spermatocytes, the nuclei had fine chromatin accumulation and the cytoplasm was copious with a well-developed Golgi complex and aggregated mitochondrial structures. The adluminal compartment of seminiferous tubules contained round spermatids in the Golgi phase and in different stages of acrosomal cap formation, elongations of condensed nuclei, and normal tail formation during spermiogenesis. Leydig cells in the control group (Figure 2C) had spherical euchromatic nuclei, many mitochondria with tubular cristae, abundant smooth endoplasmic reticulum (sER), and a few lipid droplets.

In Al-treated mice, electron microscopy showed progressive changes in testicular tubules. In the Sertoli cells, mitochondria were dramatically swollen with

**Table 1** Percentage of tubular histopathologies in the testes of mice exposed to different treatment conditions

Parameters	Group			
	I Control	II 25 mg Al <sup>3+</sup>	III 25 mg Al <sup>3+</sup> + 1 g TAU	IV 1 g TAU
Intact	97.3±0.3	32.8±4.1 <sup>a,b,c</sup>	77.9 ±2.8 <sup>a,c</sup>	98.1±0.5
Sloughing	2.7±0.3	48.5±6.8 <sup>a,b,c</sup>	22.0±3.5 <sup>a,c</sup>	1.9±0.4
Tubular atrophy	—	15.7±3.6 <sup>a,b,c</sup>	—	—
Germ-cell degeneration	—	2.9±1.2 <sup>a,b,c</sup>	—	—

Statistical significance of data obtained in histopathological analyses was evaluated by Kruskal-Wallis variance analysis and post-hoc Mann-Whitney U-test.

<sup>a</sup>  $p \leq 0.05$  vs the control group.

<sup>b</sup>  $p \leq 0.05$  vs the Al+TAU group.

<sup>c</sup>  $p \leq 0.05$  vs the TAU group.

collapsed cristae, and their cytoplasm contained many myelin figures and large phagosomes. Inter-Sertoli cell junctions were completely lacking or partly deleted (Figure 3A). Spermatogonia and spermatocytes showed morphological changes typical of apoptosis, including cell shrinkage, membrane blebbing, and excessive chromatin condensation (Figure 3A-B). Distortions of developing spermatids were also common after Al treatment. In some slides, the acrosomal vesicle or cap was dislocated into spermatid nucleus (Figure 3C). Round spermatid nuclei had more dense patches of heterochromatin, and in cases of severe structural damage chromatin was fully condensed (Figure 3D). A variety of spermatids, including round and elongated cells, had oddly shaped nuclei with acrosome defects (Figure 3E). This was seldom seen in control spermatids. Near to the tubule lumen, deformed spermatids had a markedly dilated endoplasmic reticulum (ER) (Figure 3F). In the interstitium, the cytoplasm of Leydig cells (Figure 3G) was almost filled by lipid droplets, whereas smooth endoplasmic reticulum (sER) decreased. Several Leydig cells frequently presented condensed chromatin at the nuclear margin, vacuolisation of the cytoplasm, and swollen, vacuolated mitochondria with disarranged or discontinuous cristae.

The testicular ultrastructure of animals treated with Al+TAU showed a significant improvement over the Al group. There were normal Sertoli cells, spermatogonia, spermatocytes, round spermatids with intact acrosomal cap, and elongated spermatids in the tail formation stages (Figure 4A-B). In addition, most Leydig cells appeared normal, similar to control (Figure 4C).

## DISCUSSION

Many toxic metals damage testicular germinal epithelium (27-29). Our main findings in Al-treated mice were deformations of the Sertoli cells, epithelial sloughing, tubular atrophy, and abnormal germ cells. These observations confirm and extend previous reports on gonadotoxic effects of Al in male animal models (30-33). According to Hess and Nakai (34), sloughing of immature germ cells is caused by a disruption of microtubules and intermediate filaments of the Sertoli cells. Kim et al. (35) reported that downregulation of cell adhesion proteins such as cadherin in the Sertoli cells increased sloughing of seminiferous epithelial cells, which is likely to lead to tubular atrophy (36).

The morphological hallmarks of apoptosis, which have been detected in spermatogonia and primary spermatocytes after Al administration, might primarily result from microtubule targeting and mitotic arrest, as described before (37, 38). Al treatment also elicited broad cytotoxic effects in the Leydig cells of mice. The presence of multiple lipid droplets in these cells could eventually lower secretory activity, probably by decreasing the use of free cholesterol for steroidogenesis (39-41). Two recent studies (42, 43) have shown that intact mitochondria with active respiration are essential for LH-induced Leydig cell steroidogenesis. Accordingly, mitochondrial membrane potential, mitochondrial ATP synthesis, and mitochondrial pH are considered the key elements mediating acute steroid biosynthesis. Kumar et al. (44) reported large bioenergetic deficits, mitochondrial dysfunction, and depletion of cellular ATP in different regions of rat brain after chronic Al exposure. In theory, the

mitochondrial cytopathy observed in our study by electron microscopy of Leydig cells could lead or contribute to low testosterone secretion by these cells. Besides, the state of microtubule polymerisation and/or tubulin can influence steroidogenesis, as observed in rat Leydig cells (45, 46).

An alternative way for Al to suppress testosterone is to induce nitric oxide (NO) (11). Inhibition of LH-stimulated steroidogenesis may be reinforced by NO in Leydig cells (47). A well characterised consequence of stress induced by testicular NO is the decrease in steroidogenic enzyme activities (48). Guo et al. (13) showed that Al-induced excessive NO compounds might decrease the production of testicular adenosine 3,5-cyclic monophosphate (cAMP), which helps to transport cholesterol to the inner mitochondrial membrane. The result is lower testosterone release. Reduced steroidogenesis results in altered spermatogenesis and spermatid failure (49, 50). All this suggests that the degenerative changes in germ cells found in this study might be due to hormonal deficiency.

Several studies (14, 16, 31, 32) have demonstrated the role of antioxidants in Al-induced reproductive toxicity. Our findings suggest that taurine counters Al-induced testicular lesions. In an earlier study, Das et al. (20) reported that oral administration of taurine was effective in counteracting arsenic-induced oxidative stress and attenuating testicular damage, and apoptosis of testicular tissue in Wistar rats by controlling the reciprocal regulation of Bcl-2/Bad, phospho-ERK1/2, phospho-p38, phospho-Akt, and NF- $\kappa$ B. Furthermore, Manna et al. (22) reported that taurine pre-treatment could prevent cadmium-induced testicular pathophysiology in mice. Taurine has been shown to stimulate testicular steroidogenesis *in vivo* and *in vitro* (51) and to promote spermatogonial proliferation and/or meiosis (52). It is considered a capacitating agent (53, 54), and as a sperm motility factor (55, 56).

In summary, our results suggest that Al may act as an endocrine disruptor in male mice and has the potential to induce adverse changes in Leydig cell ultrastructure. These morphological alterations provide a reasonable explanation why Al lowers the fertility index in males. For the first time, our results have also demonstrated that taurine can antagonise the pathological effects of acute Al poisoning in male genital organs, acting as an antioxidant. However, further investigation is required to pin-point the

biochemical and molecular mechanisms of these countereffects.

#### Acknowledgement

This work was partially supported by the Deanship of Scientific Research, King Faisal University, Saudi Arabia.

#### REFERENCES

1. Baydar T, Nagymajtényi L, Isimer A, Sahin G. Effect of folic acid supplementation on aluminum accumulation in rats. *Nutrition* 2005;21:406-10. doi: 10.1016/j.nut.2004.07.008
2. Ganrot PO. Metabolism and possible health effects of aluminium. *Environ Health Perspect* 1986;65:363-441. PMID: PMC1474689
3. Yokel RA, McNamara PJ. Aluminium toxicokinetics: an updated minireview. *Pharmacol Toxicol* 2001;88:159-67. PMID: 11322172
4. Nayak P. Aluminum: Impacts and disease. *Environ Res* 2002;89:101-15. doi: 10.1006/enrs.2002.4352
5. Buraimoh AA, Ojo SA. Effects of aluminium chloride exposure on the histology of lungs of wistar rats. *J App Pharm Sci* 2013;3:108-12. doi: 10.7324/JAPS.2013.30121
6. Kakimoto M, Kobayashi A, Fukuda R, Ono Y, Ohta A, Yoshimura E. Genome-wide screening of aluminum tolerance in *Saccharomyces cerevisiae*. *BioMetals* 2005;18:467-74. doi: 10.1007/s10534-005-4663-0
7. El-Sayed WM, Al-Kahtani MA, Abdel-Moneim AM. Prophylactic and therapeutic effects of taurine against aluminum-induced acute hepatotoxicity in mice. *J Hazard Mater* 2011;192:880-6. doi: 10.1016/j.jhazmat.2011.05.100
8. Hovatta O, Venalainen ER, Kuusimäki L, Heikkilä J, Hirvi T, Reima I. Aluminum, lead and cadmium concentrations in seminal plasma and spermatozoa, and semen quality in Finnish men. *Hum Reprod* 1998;13:115-9. PMID: 9512240
9. Reusche E, Lindner B, Arnholdt H. Widespread aluminum deposition in extracerebral organ systems of patients with dialysis-associated encephalopathy. *Virchows Arch* 1994;424:105-12. doi: 10.1007/BF00197400
10. Dawson EB, Evans DR, Harris WA, Powell LC. Seminal plasma trace metal levels in industrial workers. *Biol Trace Elem Res* 2000;74:97-105. doi: 10.1385/BTER:74:2:97
11. Guo CH, Huang CJ, Chen ST, Hsu G-S W. Serum and testicular testosterone and nitric oxide products in aluminum-treated mice. *Environ Toxicol Pharmacol* 2001;10:53-60. PMID: 11382556
12. Guo CH, Huang CJ, Chiou YL, Hsu GS. Alteration of trace element distribution and testis ACE activity in mice with high peritoneal aluminum. *Biol Trace Elem Res* 2002;86:145-57. doi: 10.1385/BTER:86:2:145
13. Guo CH, Lu YF, Hsu GS. The influence of aluminum exposure on male reproduction and offspring in mice. *Environ Toxicol Pharmacol* 2005;20:135-41. doi: 10.1016/j.etap.2004.11.007
14. Yousef MI, El-Morsy AM, Hassan MS. Aluminium-induced deterioration in reproductive performance and seminal



- plasma biochemistry of male rabbits: protective role of ascorbic acid. *Toxicology* 2005;215:97-107. doi: 10.1016/j.tox.2005.06.025
15. Yousef MI, Kamel KI, El-Guendi MI, El-Demerdash FM. An *in vitro* study on reproductive toxicity of aluminium chloride on rabbit sperm: The protective role of some antioxidants. *Toxicology* 2007;239:213-23. doi: 10.1016/j.tox.2007.07.011
  16. El-Demerdash FM. Antioxidant effect of vitamin E and selenium on lipid peroxidation, enzyme activities and biochemical parameters in rats exposed to aluminium. *J Trace Elem Med Biol* 2004;18:113-21. PMID: 15487771
  17. Shevtsov PN, Burbaeva G Sh. The Effects of aluminum ions on the phosphorylation of tubulin and microtubule proteins in the brain. *Neurosci Behav Physiol* 2001;31:183-4. PMID:11388372
  18. Huxtable RJ. Physiological actions of taurine. *Physiol Rev* 1992;72:101-63. PMID: 1731369
  19. Boşgelmez II, Söylemezoğlu T, Güvendik G. The protective and antidotal effects of taurine on hexavalent chromium-induced oxidative stress in mice liver tissue. *Biol Trace Elem Res* 2008;125:46-58. doi: 10.1007/s12011-008-8154-3
  20. Das J, Ghosh J, Manna P, Sinha M, Sil PC. Taurine protects rat testes against NaAsO<sub>2</sub>-induced oxidative stress and apoptosis via mitochondrial dependent and independent pathways. *Toxicol Lett* 2009;187:201-10. doi: 10.1016/j.toxlet.2009.03.001
  21. Gürer H, Özgünes H, Saygin E, Ercal N. Antioxidant effect of taurine against lead-induced oxidative stress. *Arch Environ Contam Toxicol* 2001;41:397-402. doi: 10.1007/s002440010265
  22. Manna P, Sinha M, Sil PC. Cadmium induced testicular pathophysiology: prophylactic role of taurine. *Reprod Toxicol* 2008;26:282-91. doi: 10.1016/j.reprotox.2008.09.009
  23. Alam SS, Hafiz NA, Abd El-Rahim AH. Protective role of taurine against genotoxic damage in mice treated with methotrexate and tamoxifen. *Environ Toxicol Pharmacol* 2011;31:143-52. doi: 10.1016/j.etap.2010.10.001
  24. Dogru-Abbasoglu S, Kanbagli O, Balkan J, Cevikbaş U, Aykac-Toker G, Uysal M. The protective effect of taurine against thioacetamide hepatotoxicity of rats. *Hum Exp Toxicol* 2001;20:23-7. PMID: 11339621
  25. Vieželiënė D, Rodovičius H, Ivanov L. Effect of aluminum ions on the activities of tRNA<sup>Leu</sup> and leucyl-tRNA synthetase in mouse liver *in vivo* and *in vitro*. *Biologija* 2006;4:28-30.
  26. Sayim F. Histopathological effects of dimethoate on testes of rats. *Bull Environ Contam Toxicol* 2007;78:479-84. doi: 10.1007/s00128-007-9196-5
  27. Abdel-Moneim AM, Al-Rawi MM, Abu El-Saad AM, Sorour JM. Changes in oxidative stress, testicular enzymes, histological and ultrastructural characteristics of seminiferous epithelium and semen quality of rats after *in vivo* exposure to lead and/or cadmium. *J Exp Zool India* 2008;11:341-52.
  28. das Neves RN, Carvalho F, Carvalho M, Fernandes E, Soares E, de Bastos ML, de Pereira ML. Protective activity of hesperidin and lipoic acid against sodium arsenite acute toxicity in mice. *Toxicol Pathol* 2004;32:527-35. doi: 10.1080/01926230490502566
  29. Fahim MA, Tariq S, Adeghate E. Vitamin E modifies the ultrastructure of testis and epididymis in mice exposed to lead intoxication. *Ann Anat* 2013;195:272-7. doi: 10.1016/j.aanat.2012.11.001
  30. Khattab FKI. Histological and ultrastructural studies on the testis of rat after treatment with aluminium chloride. *Aust J Basic Appl Sci* 2007;1:63-72.
  31. Kutlubay R, Oğuz EO, Can B, Güven MC, Sinik Z, Tuncay OL. Histological and ultrastructural evidence for protective effects on aluminium-induced kidney damage by intraperitoneal administration of  $\alpha$ -Tocopherol. *Int J Toxicol* 2007;26:95-101. doi: 10.1080/10915810701221173
  32. Yousef MI, Salama AF. Propolis protection from reproductive toxicity caused by aluminium chloride in male rats. *Food Chem Toxicol* 2009;47:1168-75. doi: 10.1016/j.fct.2009.02.006
  33. Buraimoh AA, Ojo SA, Hambolu JO, Adebisi SS. Histological study of the effects of aluminium chloride exposure on the testis of wistar rats. *Am Int J Contemporary Res* 2012;2:114-22.
  34. Hess RA, Nakai M. Histopathology of male reproductive system induced by the fungicide benomyl. *Histol Histopathol* 2000;15:207-24. PMID: 10668211
  35. Kim JM, Ghosh SR, Weil ACP, Zirkin BR. Caspase-3 and caspase-activated deoxyribonucleases are associated with testicular germ cell apoptosis resulting from reduced intra testicular testosterone. *Endocrinology* 2001;142:3809-16. doi: 10.1210/en.142.9.3809
  36. Vardi N, Parlakpınar H, Ates B, Cetin A, Otlu A. Antiapoptotic and antioxidant effects of  $\beta$ -carotene against methotrexate-induced testicular injury. *Fertil Steril* 2009;92:2028-33. doi: 10.1016/j.fertnstert.2008.09.015
  37. Pellegrini F, Budman DR. Review: tubulin function, action of antitubulin drugs, and new drug development. *Cancer Invest* 2005;23:264-73. PMID: 15948296
  38. Zuse A, Prinz H, Müller K, Schmidt P, Günther EG, Schweizer F, Prehn JH, Los M. 9-Benzylidene-naphtho(2,3-b)thiophen-4-ones and benzylidene-9(10H)-anthracenones as novel tubulin interacting agents with high apoptosis-inducing activity. *Eur J Pharmacol* 2007;575:34-45. PMID:17707367
  39. Sanguinetti RE, Ogawa K, Kurohmaru M, Hayashi Y. Ultrastructural changes in mouse Leydig cells after streptozotocin administration. *Exp Anim* 1995;44:71-3. PMID: 7705483
  40. Dees JH, Gazouli M, Papadopoulos V. Effect of monoethylhexyl phthalate on MA-10 Leydig tumor cells. *Reprod Toxicol* 2001;15:171-87. PMID: 11297876
  41. Saraiva KL, Silva VA Jr, Torres Dde O, Donato MA, Peres NG, Souza JR, Peixoto CA. Changes in mouse Leydig cells ultrastructure and testosterone secretion after diethylcarbamazine administration. *Micron* 2008;39:580-6. doi: 10.1016/j.micron.2007.06.003
  42. Allen JA, Shankara T, Janus P, Buck S, Diemer T, Hales KH, Hales DB. Energized, polarized, and actively respiring mitochondria are required for acute Leydig cell steroidogenesis. *Endocrinology* 2006;147:3924-35. doi: 10.1210/en.2005-1204
  43. Midzak AS, Liu J, Zirkin BR, Chen H. Effects of myxothiazol on Leydig cell steroidogenesis: inhibition of luteinizing hormone-mediated testosterone synthesis but stimulation of basal steroidogenesis. *Endocrinology* 2007;148:2583-90. doi: 10.1210/en.2006-1488



44. Kumar V, Bal A, Gill KD. Impairment of mitochondrial energy metabolism in different regions of rat brain following chronic exposure to aluminium. *Brain Res* 2008;1232:94-103. doi: 10.1016/j.brainres.2008.07.028
45. Clark MA, Shay JW. The role of tubulin in the steroidogenic response of murine adrenal and rat Leydig cells. *Endocrinology* 1981;109:2261-3.
46. Saltarelli D, De la Llosa-Hermier MP, Tertrin-Clary C, Hermier C. Effects of antimicrotubular agents in cAMP production and in steroidogenic response of isolated rat Leydig cells. *Biol Cell* 1984;52:259-66. PMID: 6273135
47. Dobashi M, Fujisawa M, Yamazaki T, Okuda Y, Kanzaki M, Tatsumi N, Tsuji T, Okada H, Kamidono S. Inhibition of steroidogenesis in Leydig cells by exogenous nitric oxide occurs independently of steroidogenic acute regulatory protein (star) mRNA. *Arch Androl* 2001;47:203-9. PMID: 11695844
48. Kostić TS, Andrić SA, Marić D, Kovačević RZ. Inhibitory effects of stress-activated nitric oxide on antioxidant enzymes and testicular steroidogenesis. *J Steroid Biochem Mol Biol* 2000;75:299-306. PMID: 11282286
49. Cicero TJ, Bell RD, Meyer ER, Badger TM. Ethanol and acetaldehyde directly inhibit testicular steroidogenesis. *J Pharmacol Exp Ther* 1980;213:228-33. PMID: 6767838
50. Van Thiel DH, Cobb CF, Herman GB, Perez HA, Estes L, Gavalier JS. An examination of various mechanisms for ethanol-induced testicular injury: studies utilizing the isolated perfused rat testes. *Endocrinology* 1981;109:2009-15. PMID: 7308139
51. Yang J, Gaofeng Wu, Ying Feng, Qiufeng Lv, Shumei Lin, Jianmin Hu. Effects of taurine on male reproduction in rats of different ages. *J Biomed Sci* 2010;17(Suppl 1):S9. doi: 10.1186/1423-0127-17-S1-S9
52. Higuchi M, Celino FT, Tamai A, Miura C, Miura T. The synthesis and role of taurine in the Japanese eel testis. *Amino Acids* 2012;43:773-81. doi: 10.1007/s00726-011-1128-3.
53. Meizel S. Molecules that initiate or help stimulate the acrosome reaction by their interaction with the mammalian sperm surface. *Am J Anat* 1985;174:285-302. PMID: 3934955
54. Meizel S, Lui CW, Working PK, Mrsny RJ. Taurine and hypotaurine: their effects on motility, capacitation and the acrosome reaction of hamster sperm in vitro and their presence in sperm and reproductive tract fluids of several mammals. *Develop Growth Differ* 1980;22:483-94.
55. Fraser LR. Both taurine and albumin support mouse sperm motility and fertilizing ability *in vitro* but there is no obligatory requirement for taurine. *J Reprod Fertil* 1986;77:271-80. PMID: 3755176
56. Boatman DE, Bavister DB, Cruz E. Addition of hypotaurine can reactivate immotile golden hamster spermatozoa. *J Androl* 1990;11:66-72. PMID: 2312401

**Sažetak****DJELOVANJE TAURINA PROTIV HISTOMORFOLOŠKIH I ULTRASTRUKTURNIH PROMJENA U TESTISIMA MIŠEVA IZLOŽENIH ALUMINIJEVU KLORIDU**

Cilj je ovog istraživanja bio proučiti zaštitno djelovanje taurina od histomorfoloških i ultrastrukturnih promjena u testisima švicarskih albino miševa akutno izloženih  $\text{AlCl}_3$ . Svjetlosnom je mikroskopijom utvrđena povezanost između jednokratne intraperitonealne (*i.p.*) doze  $\text{AlCl}_3$  ( $25 \text{ mg kg}^{-1} \text{ Al}^{3+}$ ) i odvajanja nekrotičnoga tkiva, atrofije tubula, degeneracije zametnih stanica te žarišta hiperplazije Leydigovih stanica. Usto su se elektronskom mikroskopijom mogli vidjeti razoreni čvrsti spojevi između Sertolijevih stanica, apoptoza spermatogonija i primarnih spermatocita, različite morfološke abnormalnosti spermatida, nakupljanje lipidnih kapi, stanjenje glatkog endoplazmatskog retikuluma (sER) te oštećenje mitohondrija u Leydigovim stanicama. Naknadna primjena taurina u *i.p.* dozi od  $1 \text{ g kg}^{-1}$  ublažila je ove promjene i značajno smanjila broj zahvaćenih tubula u odnosu na miševe otrovane aluminijem. Ovo je prvo istraživanje koje potvrđuje zaštitno djelovanje taurina protiv patoloških promjena na tkivu testisa miševa uzrokovanih aluminijem.

**KLJUČNE RIJEČI:** *histopatologija, muški reproduktivni sustav, spermatogeneza, toksični metali, ultrastruktura*

**CORRESPONDING AUTHOR:**

Ashraf M. Abdel-Moneim  
King Faisal University, College of Science  
Department of Biological Sciences  
Ahsaa, Saudi Arabia  
E-mail: [aabdelmoneim@kfu.edu.sa](mailto:aabdelmoneim@kfu.edu.sa);  
[ashraf\\_abdelmoneim@yahoo.com](mailto:ashraf_abdelmoneim@yahoo.com)