

*Short communication***HAEMORRHAGIC BOWEL SYNDROME IN FATTENIG PIGS**

NOVOTNÝ Jaroslav^{1*}, REICHEL Peter¹, KOVAČOCYOVÁ Katarína¹,
CIGÁNKOVÁ Viera², ALMÁŠIOVÁ Viera², ŠIPOŠ Dioníz³

¹Clinic for Swine, University of Veterinary Medicine and Pharmacy, Košice Slovak Republic;

²Department of Anatomy, Histology and Physiology, University of Veterinary Medicine and Pharmacy, Košice, Slovak Republic; ³Private Veterinary Doctor, Strážske, Slovak Republic

(Received 11 June; Accepted 28 October 2015)

The aim of this work was to determine the possible causes of sudden death in fattening pigs associated with haemorrhagic bowel syndrome (HBS) in a commercial pig farm (Eastern Slovakia). The etiology and pathogenesis of haemorrhagic bowel syndrome is not clearly defined within the scientific community. For this reason, clinical examination and sampling from 90 kg finisher pigs was done. Samples of blood, faeces, and rectal swabs were taken for haematological, serological, bacteriological, virological, and parasitological examination. Necropsy and sampling was also conducted on the carcasses of 90 kg finisher pigs that died peracutely during the investigation period. Three weeks later, during slaughter of the same group of pigs, goal-directed investigation and sampling from the gastrointestinal system for histological examination was performed. Results show the presence of bloody diarrhoea caused by *L. intracellularis*, *C. perfringens* typ A and haemolytic *E. coli*. Inflammation and loss of blood led to moderate normochromic (haemoglobin 12.85 ± 0.95 g.dl⁻¹) normocytic anaemia (erythrocytes 3.38 ± 0.17 T.l-1), hydremia (haematocrit 0.17 ± 0.01 l.l-1) and mild leukocytosis (18.7 ± 4.68 G.l-1). Diagnostic necropsy confirmed the picture of "haemorrhagic bowel syndrome,, caused by infection and subsequent enterotoxemia without presence of gastric or intestinal displacement. Slaughter examination showed picture of proliferative ileitis typical for *L. intracellularis*. On the basis of our examinations, a major role in haemorrhagic bowel syndrome played infectious agents such as *L. intracellularis*, *C. perfringens* typ A and haemolytic *E. coli*. Negative findings of salmonellosis, dysentery, feed mycotoxins, intestinal parasites, and pollution of drinking water exclude these factors from the etiology of haemorrhagic bowel syndrome.

Key words: fattening pigs, haemorrhagic bowel syndrome

INTRODUCTION

Over the past years, infrequent explosive outbreaks of grower pigs sudden deaths on farms with good management systems have been reported [1-5]. Grower pigs die acutely without prodromal signs. Severe abdominal distension is present shortly after

*Corresponding author: e-mail: jaroslav.novotny@uvlf.sk

death. This syndrome is referred to as haemorrhagic bowel syndrome (HBS) or ‘red gut’, as a result of the intense red discolouration of the intestinal tract. Although mortality does not spread within a group of animals, it tends to affect the best grown pigs close to market age, making it an expensive disease [5]. It primarily affects rapidly growing pigs between 4 and 6 months of age – 70 to 120 kg [6].

Hemorrhagic bowel syndrome is not clearly defined within the scientific community due to the inability to recreate consistently the syndrome. The culmination of several things lead to mortality and most producers and veterinarians accept that there are many triggers which can lead to mortality from hemorrhagic bowel in large pigs [7].

The purpose of this paper was to determine the possible causes of sudden deaths associated with haemorrhagic bowel syndrome on the examined farm.

MATERIAL AND METHODS

Rearing conditions: The observed farm belongs to a commercial pig grower/finisher unit and is located in the eastern part of Slovakia. At the time of examination there were 700 sows, 66 gilts, 1150 sucking piglets, 2120 weaning piglets, 3800 of fattening pigs (crossbreed Large White x Landrace). Fattening pigs were divided into two groups (30 – 60 kg pigs, and 60– 115 kg pigs) fed a different composition of the dry feed mixture (VUL 1, VUL 2). Technology of housing (fully slatted floors), feeding (dry feeding systems), water supply, as well as hygiene were satisfactory. A certain shortage was a comparatively fine grinding of the feed mixture (VUL 2).

Prevention and control of diseases: Piglets vaccination against PCV-2, mycoplasma, PRRS and sows vaccination against atrophic rhinitis, parvovirus, erysipelas, colibacillosis, and PRRS was carried out on the farm.

Diagnostic sampling of biological material: was realized from four living pigs with observed bloody diarrhoea, and we took samples of:

- blood for haematological and serological tests,
- faeces for parasitological, bacteriological and virological examinations,
- feed mixtures for the detection of mycotoxins,
- water for microbiological and chemical analysis.

All samples were processed in diagnostic laboratories (Clinic for Swine, and Department of the Environment UVLF Košice, Vetservis s.r.o. Nitra).

Diagnostic necropsy: was performed on two 90 kg finisher pigs that died peracutely on the day of the investigation. HBS pathological picture was present in both cases, so there was an indication for sampling lymph nodes, small and large intestines for bacteriological and virological examinations.

Macroscopic and histological examination: Three weeks later, during slaughter of the same stable-room group of pigs (112 animals), goal-directed macroscopic investigation and sampling from the gastro intestinal tract (GIT) was performed. Tissue samples of

the ileum, mid-section of the jejunum, and the cecum were taken from 10 pigs and immediately processed by a common histological technique. They were fixed in 10% neutral buffered formalin and embedded in paraffin. Then 5-7 μ m thick tissue sections were stained with haematoxylin and eosin (H&E) and photodocumented under a light microscope Zeiss Axio lab A1.

RESULTS AND DISCUSSION

Reduced numbers of red blood cells that leads to moderate, normochromic, normocytic anaemia, hydremia and mild leukocytosis was found by haematological testing (Table 1).

Table 1. The average haematological profile values of pigs with bloody diarrhoea

	Le (G.l-1)	Er (T.l-1)	Hb (g.dl-1)	Hkt (l.l-1)	MCV (fl)
Norm	11 – 18	5 – 8	10 – 14	0.38 – 0.42	50 – 68
x \pm sd	18.7 \pm 4.68	3.38 \pm 0.17	12.85 \pm 0.95	0.17 \pm 0.01	51 \pm 1.83

The bacteriological examination of faeces samples, intestinal contents, and feed mixture showed a positive finding for haemolytic *E. coli* in the faeces, *Clostridium perfringens* type A in the faeces, intestinal content and feed mixtures (Table 2). Conversely, a negative result for *Salmonella spp.* in the faeces, intestinal content, and dry feed mixture was recorded.

Table 2. Examination of the of faeces samples by PCR method

Bacteria	Presence of the gene	Absence of the gene
<i>E. coli</i>	heat-stable enterotoxin (Sta)	heat-labile enterotoxin (LT)
	shigatoxin (stx1)	shigatoxin (stx2)
		adherent factor intimin (eaeA)
		enterohemolysin (hlyA)
<i>C. perfringens</i>	α toxin	

Mycological examination of the feed mixture – concentrations of fungi *Fusarium spp.* and *Penicillium spp.* were detected by the cultivation method. Mycotoxins Deoxynivalenol (DON) and Zearalenone were recorded by ELISA, but these toxic substances did not reach harmful concentrations.

Parasitological examination of faecal samples for detection of parasites' eggs was negative.

Serological examination was positive for PRRS, PCV2 (consequence of vaccinations) and *L. intracellularis*.

The result of microbiological and chemical analysis of water samples corresponds to the quality of drinking water.

Autopsy finding of dead pigs (autopsied shortly after death – still warm, fresh carcasses) was identical, namely:

- Very good nutritional status (90 kg body weight), with a distended abdomen (Figure 1)
- Significant *meteorism* in all sections of the intestines (figure 2), marked *hemorrhagic enteritis* (Figure 3) with the same intensity, sparse intestinal contents, *melena* with no atypical odour.
- Stomach filled by *ingesta* without sensory changes, mucosa of the gastric fundus of one pig was with moderate catarrhal hemorrhagic gastritis, the other without pathological changes – intussusception, volvulus or gastric ulceration.
- The liver, spleen, kidneys, bladder, peritoneum and internal serosae of the abdominal cavity without manifested macroscopic pathological changes, abdominal cavity without a pathologically increased effusion.
- Thoracic cavity with slight circumscribed, unilateral adhesions without increased effusion, lungs “clean”, moderate dilatation of the heart, oesophagus, trachea, oral and nasal cavity without pathological changes.

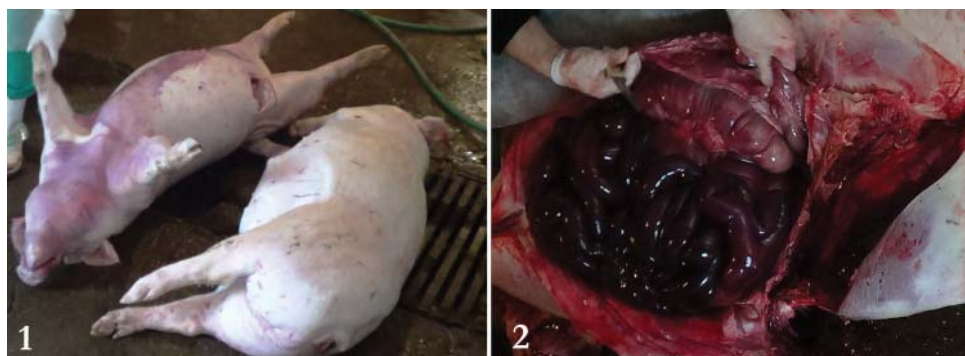

Figure 1. Pronounced distension of the abdomen of fresh carcasses – necropsy

Figure 2. Severe distension and red discoloration of intestinal tract – necropsy

PCR screening of intestine and lymph nodes: In the samples from the intestines the finding was negative for *Lawsonia intracellularis* and *Brachyspira hyodysenteriae*. In the mesenteric lymph nodes the result for PCV2 was negative and positive for PRRSV.

Slaughter macroscopic examination showed thickening and proliferation of ileum (Figure 4). This finding was presented in 15 % of slaughtered pigs.

Histological examination revealed serious mucosal damage of all investigated intestine sections. The intestinal villi of the ileum and jejunum were constantly damaged and often with a broken or completely missing epithelial layer. The connective tissue of the *lamina propria* was extensively infiltrated by inflammatory cells (Figures 5, 6, 7). The cecum section contained affected apical parts of the intestinal crypts, while the basal

portions of the intestinal crypts had a relatively characteristic structure. Connective tissue of the *lamina propria* was infiltrated by inflammatory cells (Figure 8).

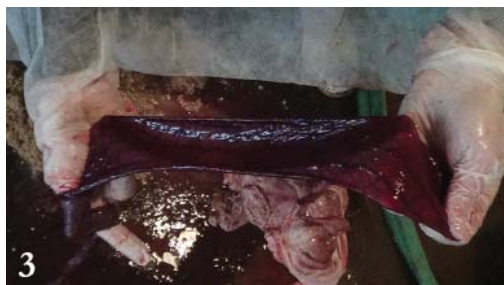

Figure 3. Hemorrhagic enteritis of small intestine – necropsy

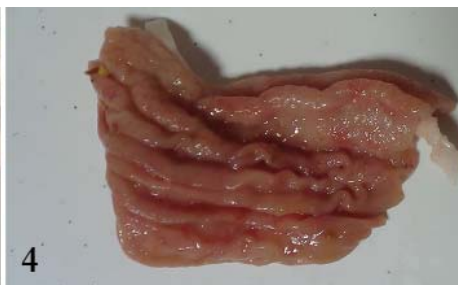

Figure 4. Corrugated appearance of the ileum – slaughterhouse examination

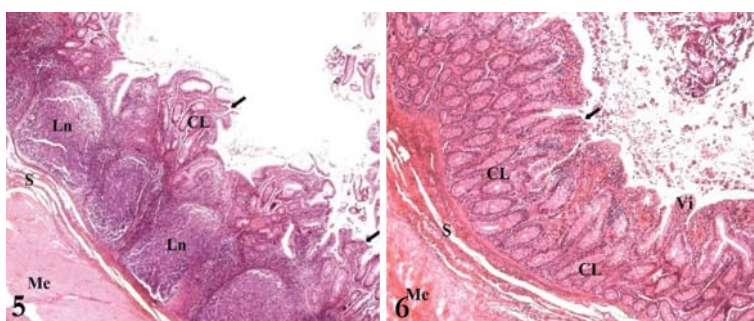


Figure 5. Ileum - the intestinal villi destruction – light microscopy (H&E; Magn. 100 x)

Legend: Arrows – destruction of villi intestinales; CL – Crypt of Lieberkühn, Ln – Lymphatic nodules (Peyer's patches); S – Submucosa; Me – Muscularis externa

Figure 6. Jejunum - the intestinal villi destruction, proliferation of the Lieberkühn crypts – light microscopy (H&E; Magn. 100 x)

Legend: Arrow – destruction of villi intestinales; Vi - villi intestinales; CL – Crypts of Lieberkühn; S – Submucosa; Me – Muscularis externa

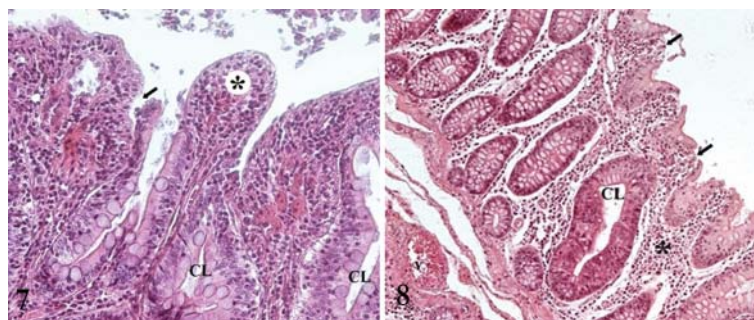


Figure 7. Ileum – intestinal villi with damaged or completely missing epithelial layer – light microscopy (H&E; Magn. 400 x)

Legend: Arrow – destruction of villi intestinales; CL – Crypts of Lieberkühn; asterisk – villus with missing epithelial layer

Figure 8. Cecum – damaged intestinal crypts – light microscopy (H&E; Magn. 200 x)

Legend: Arrows – destruction of apical portion of intestinal crypts; CL – relatively unaffected deeper sections of Crypts of Lieberkühn; asterisk – lymphocytes in lamina propria; v – vein in submucosa

The term “hemorrhagic bowel syndrome” has been applied when finishing swine die suddenly without premonitory evidence of diarrhoea or other clinical signs. *Post mortem* examination of a recently dead animal is typical marked pallor of the skin and pronounced distension of the abdomen [6]. Necropsy on our farm showed similar changes – a markedly distended abdomen with the severely distended intestinal tract without evidence of gastric or intestinal displacement. Indication of a peracute disease was the stomach filled with fresh feed.

The exact etiology and pathogenesis of “HBS” is still an object of speculations and discussions, mainly in consequence of peracute mortality. Mortalities tended to occur in the early hours of the morning accompanied by symptoms of abdominal distension, respiratory distress (open mouth breathing), and cyanosis [5]. Some *authors indicated that HBS could have an infectious* etiology [2,5] or this condition can be the result of intestinal volvulus – rotation of intestines about the mesentery [1,6]. Supporters of the infectious etiology assumed, that HBS arises from overgrowth and (or) alterations of bacteria such as *Clostridium* or *E. Coli* in the GI tract with consequent over-production of toxic substances and damaging compounds. This is well documented in ruminants, where various risk factors contribute to the overgrowth of normal intestinal flora, with sequelae such as acidosis, endotoxemia, enterotoxemia, and death [8,9]. *C. perfringens* is a common cause of mortality in neonatal pigs but has not yet been recognized as an important cause of disease in grower pigs [10]. According to findings from South Africa this pathogen plays a major role in HBS in rapidly growing pigs [5].

Even though the clinical and pathological picture is not a lot of times typical, many veterinarians thought that *Lawsonia intracellularis* infection was at least in part responsible for this syndrome. This belief stemmed from the fact that *L. Intracellularis* infections are known to be endemic on the affected farms and are known to cause acute mortalities in this age group [11-13]. Our examinations results support these statements, because *Lawsonia intracellularis* was also detected. Antimicrobials are variably effective decreasing incidence of HBS in some herds. For instance, feed administration of chlortetracycline or bacitracin is very effective in the reduction of HBS mortality [14]. However, the problem lies in the correct timing of administration.

Identifiable volvulus of the intestine has been a variable finding in necropsies of pigs with HBS [6]. Partial or complete volvulus as a common cause of death has pathological features typical of those described for HBS [2]. However, thoroughgoing diagnosis of intestinal volvulus is often complicated and possible only on the basis of palpation of the mesenteric root before complete opening the abdomen (palpation through a small incision in the abdominal wall) [6].

Whereas literature [1,6] alleged higher rates of death due to HBS for pigs finished during the summer and with a liquid feeding system (especially whey – a highly fermentable substrate), peracute mortality on our farm was in the winter season (January) and with usage of dry feeding system.

It is clear that hemorrhagic bowel syndrome does not have a single cause of origin, therefore further more extensive research is necessary for clarifying factors that are important for its incidence and pathogenesis.

CONCLUSION

On the basis of our performed examinations – focused on determination of etiology HBS in fattening pigs is obvious:

- Growth, multiplication and toxin production of bacteria as *E. coli* and *C. perfringens* typ A bring about enterotoxaemia and together with *L. intracellularis*, may cause peracute mortality
- On the other hand, negative findings of salmonellosis, dysentery (*Brachyspira hyodysenteriae*), feed mycotoxins, intestinal parasites, and pollution of drinking water place out these causes from the aetiology of sudden deaths associated with HBS.

Authors' contributions

All authors equally contributed to this work, read and approved the final manuscript.

Declaration of conflicting interests

The author(s) declared no potential conflicts of interest with respect to the research, authorship, and/or publication of this article.

REFERENCES

1. Häni H, Zimmermann W, Huber A, Schmidt J: Das "häorrhagische Intestinalsyndrom" (HIS) des Schweines: Klinische, pathologisch-anatomische und ätiopathogenetische Aspekte. Schweiz Arch Tierheilk 1993, 135:117–124.
2. Schwartz KJ: Hemorrhagic bowel syndrome (HBS): A diagnostic laboratory perspective, Proceedings of the 33rd Annual Meeting of the American Association of Swine Veterinarians, Kansas City, Kansas, 02–05 March 2002, 405 – 408.
3. Van Metre DC, Callan RJ, Dennison AC: Hemorrhagic bowel syndrome: What we do and don't know, Proceedings of the North American Veterinary Conference, Orlando, Florida, 08–12 January 2005, 47 – 48.
4. Pejsak, Z: Krwotoczny zespół jelitowy u świń [Haemorrhagic bowel syndrome in pigs], Zycie Weterynaryjne 2007, 82: 398 – 400.
5. Labuscagne A, Spencer BT, Picard JA, Williams MC: An investigation to determine the cause of haemorrhagic enteritis in commercial pig grower units in the northern parts of South Africa, J S Afr Vet Assoc 2012, 83(1): 19, 6 pages. doi: 10.4102/jsava.v83i1.19.
6. Straw BD C, Kober, J, Henry SC: Factors associated with death due to hemorrhagic bowel syndrome in two large commercial swine farms, J *Swine Health Prod* 2002, 10: 75-79.
7. Hollis WL: Will nutrition and management stop hemorrhagic bowel syndrome? A veterinarian's perspective. Midwest Swine Nutrition Conference 2006, 38 – 41.

8. Kersting KW, Thompson JR. Diseases of the ruminant forestomach. In: Howard JL, Smith RA, eds. Current Veterinary Therapy. 4th ed. Philadelphia, Pennsylvania: WB Saunders Co; 1999, 507–510.
9. Dennison AC, VanMetre DC, Callan RJ, Dinsmore P, Mason GL, Ellis RP: Hemorrhagic bowel syndrome of adult dairy cattle: 22 cases (1997-2000). J Am Vet Med Assoc 2002, 221:686-689.
10. Nülo L: *Clostridium perfringens* in animal disease, a review of current knowledge, Can Vet J. 1980, 21, 141–148.
11. Labuscagne A: Elisa profiles of *L. Intracellularis* on pig farms in Southern Africa, Proceedings of the 20th International Pig Veterinary Society Congress, Durban, South Africa, 22–26 June 2008, 145.
12. Byung-Yong P, Kwan-Seob S, Won-Il K, Md Mukter H, Bumseok K, Jungkee K, Choi-Kyu P, Sung-Jin C, Inho J, Ho-Seong C: Rapid and sensitive detection of *Lawsonia intracellularis* in pigs by real-time loop-mediated isothermal amplification Acta Vet-Beograd 2015, 65 (1), 20-29.
13. Kovačociová K, Reichel P, Seidel H, Brenesselová M, Kósa B: Influence of beta-glucan and vaccination against *Lawsonia intracellularis* on selected immune indices in weaned piglets Acta Vet-Beograd 2014, 64 (1), 105-11
14. Schultz RA, Daniels GN: Use of BMD to control hemorrhagic bowel syndrome in swine. Vet Med. 1984;79, 253–256.

SINDROM HEMORAGIČNOG ENTERITISA KOD SVINJA U TOVU

NOVOTNÝ Jaroslav, REICHEL Peter, KOVAČOCYOVÁ Katarína, CIGÁNKOVÁ Viera, ALMÁŠIOVÁ Viera, ŠIPOŠ Dioníz

Cilj rada je bio da se ispitaju mogući uzroci uginuća kod svinja u tovu, a koji su povezani sa sindromom hemoragičnog enteritisa. Ispitivanje je obavljeno na jednoj komercijalnoj farmi svinja u Istočnoj Slovačkoj. Etiologija i patogeneza sindroma hemoragičnog enteritisa do sada nisu u potpunosti razjašnjeni. Iz tog razloga, obavljeno je kliničko ispitivanje kao i uzimanje uzoraka od svinja pri kraju tova, telesne mase od 90 kg. Uzimani su uzorci krvi, fecesa kao i briševi rektuma, a za hematološka, serološka, bakteriološka, virusološka i parazitološka dijagnostička ispitivanja. Istovremeno, obavljene su obdukcije svinja telesne mase od 90 kg, koje su uginule posle perakutnog toka, tokom perioda ispitivanja. Tri nedelje kasnije, tokom klanja iste grupe svinja, obavljeno je ciljano ispitivanje i uzimanje uzoraka iz gastrointestinalnog sistema u cilju histološkog pregleda tkiva. Rezultati su pokazali da je postojala hemoragična dijareja izazvana sa *L. intracellularis*, *Cl. perfringens* tip A i hemolitičkim sojem *E. coli*. Zapaljenska reakcija kao i gubitak krvi su uslovili normohromatsku (hemoglobin $12,85 \pm 0,95$ g.dl⁻¹) normocitnu anaemiju (eritrociti $3,38 \pm 0,17$ T.l-1), hydremiju (hematokrit $0,17 \pm 0,01$ l.l-1) kao i blagu leukocitozu ($18,7 \pm 4,68$ G.l-1). Dijagnostičko

postmortalno ispitivanje je potvrdilo dijagnozu: infektivnog “sindrom hemoragičnog enteritisa” sa posledičnom enterotoksemijom bez prisustva promene situsa želuca i creva. Ispitivanja prilikom klanja su pokazala prisustvo proliferativnog ileitisa koji je tipičan simptoma za infekciju sa *L. intracellularis*. Na osnovu naših ispitivanja, najznačajniji uzročnici sindroma hemoratičnog enteritisa jesu infektivni agensi kao što su to *L. intracellularis*, *Cl. perfringens* tip A i hemolitički soj *E. coli*. Negativni nalazi u odnosu na salmonelozu, dizenteriju, mikotoksine iz hrane, intestinalne parazite i kontaminacija vode za piće ukazali su da ovi uzroci nisu etiološki faktori u nastanku sindroma hemoragičnog enteritisa.