

Clinical report

A fatal case of intestinal capillariasis due to misleading investigations

Yotsapon Thewjitcharoen^a, Sunee Medhajirapat^a, Vivornpun Sanprasert^b, Wilai Saksirisampant^b, Surang Nuchprayoon^b

^aDepartment of Medicine, ^bDepartment of Parasitology, and Chula MRC, Faculty of Medicine, Chulalongkorn University, Bangkok 10330, Thailand

Background: Intestinal capillariasis is an important agent in the differential diagnosis of chronic diarrhea and protein-losing enteropathy. The disease is uncommon and possibly under-diagnosed in Thailand and neighboring countries.

Objective: Report a fatal case of intestinal capillariasis that underwent misleading diagnostic efforts for six months. We also reviewed previous cases of intestinal capillariasis from our hospital.

Patient and Method: A descriptive study of a fatal case of intestinal capillariasis, and review of patients admitted for capillariasis during the past 10 years.

Conclusion: This case highlights the importance of adequate and repeated microscopic stool examinations before proceeding to other sophisticated investigations that may cause delay in diagnosis and confusing results that result in inappropriate therapy.

Keywords: Diagnosis, fatal, intestinal capillariasis

Capillaria philippinensis can cause severe morbidity and mortality in cases of delayed diagnosis or inappropriate treatment. Clinical manifestations include chronic watery diarrhea and hypoalbuminemia from malabsorption syndrome [1]. The diagnosis of intestinal capillariasis relies on the detection of characteristic peanut shaped parasitic ova with flattened bipolar plugs and a striated shell [2]. Because the eggs of *C. philippinensis* are excreted sporadically in stool, multiple stool samples must be obtained and examined before other etiologies for malabsorption syndromes are considered.

We describe a case of intestinal capillariasis who had been undiagnosed for almost six months because *C. philippinensis* was not seriously considered in the differential diagnosis. It is of interest to note that precursory stool examinations had been performed before the patient was referred to our hospital (King Chulalongkorn Memorial Hospital, Bangkok, Thailand). The pitfalls of serological tests to exclude autoimmune disorders also could cause harmful treatment as depicted in this case. We reviewed our

experience in another nine cases of intestinal capillariasis that had been admitted to our hospital during the past 10 years to emphasize the importance of *C. philippinensis* as a cause of severe chronic diarrhea in Thailand.

Case report

A previously healthy 44-year-old male construction worker was referred to our hospital after an evaluation of a 6-month history of chronic watery diarrhea. He had been living in Nakhonsawan province, located in the central part of Thailand. Six months prior to admission, he had occasional vague abdominal pain, intermittent watery diarrhea three or four times per day, and generalized edema for one month. He reported no blood or mucus in stool. He denied having fever, anorexia, or vomiting. During the preceding months, the patient had been repeatedly visiting nearby hospitals without diagnosis or improvement in his symptoms. A simple microscopic stool examination had been performed at a local hospital. He received multiple empirical antibiotics but symptoms remained. The diarrhea became more frequent (six to seven times per day), and he then developed steatorrhea (sticky and odoriferous stools). There was now a weight loss of 30 kilograms over three months.

Correspondence to: Prof. Surang Nuchprayoon, Department of Parasitology, Faculty of Medicine, Chulalongkorn University, Bangkok 10330, Thailand. E-mail: fmedstt@gmail.com

He was next admitted to a provincial hospital for further investigation. Initial blood tests revealed a very low level of serum albumin (1.9 g/dL) without proteinuria. The result of HIV tests was negative. Initial microscopic stool examination revealed no white or red cells, and was reported as negative for parasites and ova. Gastroscopy and colonoscopy were done and revealed mildly swollen gastric, duodenal, and jejunal mucosa. A biopsy specimen of the proximal small bowel did not show any parasites or other abnormalities. Abdominal computed tomography (CT) scan showed a smooth circumferential thickened bowel wall, mainly of the duodenum and jejunum. No enlargement of intra-abdominal lymph nodes was detected. During the second week of hospitalization, he developed dry gangrene at the left fifth toe without preceding known symptoms or injury. A computed tomographic angiogram of the lower extremities revealed no vascular abnormality. Histology of skin, at the gangrenous site, showed normal small vessels. A definitive diagnosis could not be made, but vasculitis was still suspected as a cause of his symptoms. In order to rule out an autoimmune disorder, the panel of blood tests included anti-nuclear antibody (ANA), perinuclear anti-neutrophilic cytoplasm (p-ANCA), and cytoplasmic anti-neutrophilic antibody (c-ANCA). The result of c-ANCA by an indirect immunofluorescent test was positive. This resulted in administration of intravenous dexamethasone based on a presumptive diagnosis of autoimmune disease. However, diarrhea persisted with progression of the dry gangrene of his toe.

He was referred to our hospital, for further investigation and treatment. On detailed questioning, he had a history of frequently eating raw freshwater fish and shellfish. On admission, the patient appeared extremely emaciated, pale, and there was marked pitting edema of both legs. Vital signs revealed low-grade fever (37.8°C), hypotension (80/50 mmHg), a heart rate of 120 beats/minute, and a respiratory rate of 25. Other physical findings were within normal limits except of dry gangrene at the left fifth toe. Blood tests revealed mild anemia (hemoglobin 10 g/dL) and a white blood cell count of 3,150 cells/mm³ (neutrophil 84%, eosinophil 1%). Serum albumin and potassium were 1.7 g/dL and 2.2 mEq/L, respectively. The other blood tests, including liver and renal function tests, were all within normal ranges. Microscopic stool examinations by simple smear and by concentration technique on the first day of admission were negative for ova and parasites. The patient was admitted with a provisional diagnosis of protein-losing enteropathy, probably due to autoimmune disorder or malignancy. Repeated blood tests for ANA, anti-dsDNA, p-ANCA, c-ANCA were negative. Anti-myeloperoxidase (Anti-MPO) and anti-proteinase 3 (Anti-PR3) tests were also negative. Hemocultures were taken and intravenous ceftriaxone was given as empirical treatment of unknown bacterial infections, and the dexamethasone was tapered off. The patient had been treated with dexamethasone for 1 week before the admission. Repeat stool examination for parasites on the second day of admission revealed *C. philippinensis* eggs and an adult female (Figure 1). No Charcot-Leyden crystals were seen.

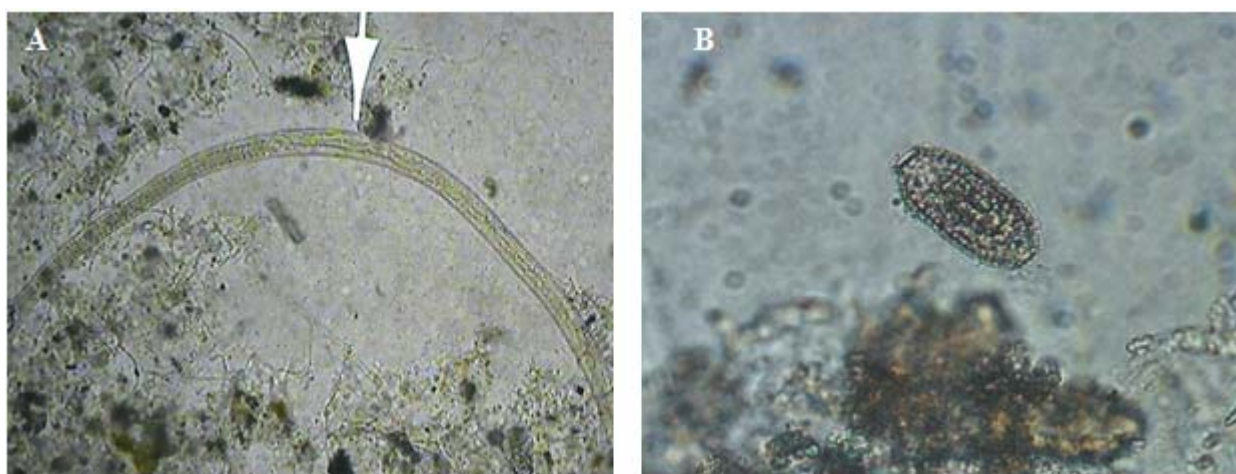


Figure 1. Stool examination revealed (A) adult female and (B) peanut shaped, pitted shell and bipolar plugs ova of *C. philippinensis*

Oral mebendazole 400 mg/day was then started, however, his general clinical condition deteriorated rapidly, he developed *Acinetobacter baumannii* septicemia with pulmonary abscess and died in spite of 10 days in the intensive care unit. Autopsy findings showed generalized atrophy of small bowel wall without presence of parasitic ova, larva, or adult worms.

All family members and 113 villagers from the same district were examined for parasites by formalin-ether concentration technique and no other cases of *C. philippinensis* infection were identified.

Discussion

The first case of intestinal capillariasis was reported by Chitwood et al. in 1964 [1], and cases have subsequently been reported from many parts of the world including Southeast Asia [2-9]. Because chronic diarrhea and protein-losing enteropathy carries a broad differential diagnosis, *C. philippinensis* infections can be overlooked due to an unawareness and a lack of experience in detection of parasitic ova in stools. Delayed diagnosis might result in fatal outcomes, which were reported in past epidemic outbreaks in the Philippines and Thailand [10, 11]. Most of these patients died from electrolyte depletion, cardiac arrhythmia and/or superimposed bacterial infections. During an epidemic in the Philippines, the mortality rates were reported as high as 35% of infected patients [10]. Therefore, a definite diagnosis by identifying the parasitic ova and prompt treatment with oral mebendazole or albendazole are essential in saving lives.

Repeated stool examinations are needed to identify the ova as they are present intermittently. Examinations have to be done by well trained technicians. If eggs, larvae, or adult *C. philippinensis* are not found in stools, endoscopic examinations might be required to obtain biopsy specimens for histopathological examination [12]. Moreover, an enzyme-linked immunosorbent assay (ELISA) has also been reported to have a high sensitivity and specificity for detections of antibodies against *C. philippinensis* [13, 14]. In case of unavailability of *C. philippinensis* antigen, immunoblot using *Trichinella spiralis* antigen is useful as a screening test of human intestinal capillariasis [15]. However, a positive test should be confirmed either by stool examinations or by more specific tests. Awareness

of this disease is obviously the most important factor in making an early diagnosis. Our unfortunate patient underwent extensive investigations, including gastroscopy, colonoscopy, abdominal CT scan, and serological tests for autoimmune disorders. All of those were non-diagnostic and led to inappropriate treatments. The cause of the digital gangrene in this patient remains unexplained but we suspect that thrombosis might be likely. Autopsy findings did not reveal any evidence of vasculitis, which was seriously considered due to the false positive result of c-ANCA test. The c-ANCA and p-ANCA are immuno-fluorescent tests that require interpretation in the context of clinical findings [16, 17]. However, blood tests alone cannot establish a diagnosis of vasculitis without confirmation by histological findings. The inappropriate interpretation of these serologic tests caused harmful treatment from immunosuppressive medications.

We also reviewed our experience with intestinal capillariasis during 2000-2010 (**Table 1**). Among 10 cases (including this case), the gender ratio between male and female was 1.25:1 (six males: four females). Patients' ages ranged from 11 to 59 years, with mean of 37.7 ± 16.3 years. Most patients reported having a history of raw fish consumption. Most had voluminous watery diarrhea for four days to two years (mean nine months) with a consistent finding of hypoalbuminemia in all cases. The mean plasma albumin level was only 1.6 g/dL in our patients. The associated symptoms were many borborygmi, vague abdominal pain, and mean weight loss of 17 kilograms. Fever was an unusual feature. The presence of *C. philippinensis* eggs in stools was seen in nine cases, and stool examinations were repeated six times before *C. philippinensis* eggs were found in one case. One patient was diagnosed by histopathology. Larvae and adults of *C. philippinensis* were found in specimens obtained from the distal ileum by colonoscopy. *Strongyloides stercoralis* and *Opisthorchis* ova were also found in one case. The diagnosis of *C. philippinensis* infection was made more than six months after initial presentation to general practitioners in four of patients. Once the diagnosis was made all patients were treated with oral mebendazole 400 mg/day for 21 to 30 days. No relapses had been found in these cases. There were two deaths (including this reported case) due to superimposed bacterial infection from delayed diagnosis.

Table 1. Clinical characteristics of 10 intestinal capillariasis patients

No	Age (year)	Gender	Duration of symptoms (month)	Frequency of stools (per day)	Weight loss (kg)	History of raw fish consumption	Serum albumin (g/dL)	Plasma potassium (mEq/L)
1	36	M	5	7	40	+	1.8	3.2
2	11	M	24	4	8	+	0.9	4.1
3	58	F	24	10	35	+	1.5	1.9
4	14	F	3	4	6	+	1.4	4.9
5	59	M	4 days	4-10	-	-	3.2	4.1
6	43	F	12	10	10	+	1.0	2.9
7	27	M	7	4	11	+	1.5	3.5
8	39	F	5	4	11	+	1.1	3.6
9	46	M	5	3	14	+	1.5	3.8
10*	44	M	6	7	38	+	1.7	2.2

+ = present, - = absent, * = the present case

Conclusion

This devastating case highlights the importance of performing adequate repeated stool examinations in cases of chronic diarrhea, before proceeding to other sophisticated investigations that may result in delay and a wrong diagnosis with harmful treatment. Intestinal capillariasis needs to be considered in patients who present with symptoms of chronic watery diarrhea and hypoalbuminemia from malabsorption. The diagnosis can usually be made by finding characteristic ova in stools by repeated stool examinations. If left untreated, intestinal capillariasis can lead to severe morbidity and death.

Acknowledgements

The authors gratefully thank the relatives of the patient who permitted us to publish this case. We also appreciate Ms. Jaruratt Prownebon and Ms. Uthaitip Bunkasem for their technical assistance in the field and laboratory work. The authors have no competing financial or personal interests.

References

- Chitwood MB, Valesquez C, Salazar NG. *Capillaria philippinensis* sp. n. (Nematoda: Trichinellida), from the intestine of man in The Philippines. J Parasitol. 1968; 54:368-71.
- Pradatsundarasar A, Pecharanond K, Chintanawongs C, Ungthavorn P. The first case of intestinal capillariasis in Thailand. Southeast Asian J Trop Med Public Health. 1973; 4:131-4.
- Whalen GE, Rosenberg EB, Strickland GT, Gutman RA, Cross JH, Watten RH. Intestinal capillariasis: a new disease in man. Lancet. 1969; 1:13-6.
- Dronda F, Chaves F, Sanz A, Lopez-Velez R. Human intestinal capillariasis in an area of nonendemicity: case report and review. Clin Infect Dis. 1993; 17: 909-12.
- Lee SH, Hong ST, Chai JY, Kim WH, Kim YT, Song IS, et al. A case of intestinal capillariasis in the Republic of Korea. Am J Trop Med Hyg. 1993; 48:542-6.
- Bair MJ, Hwang KP, Wang TE, Liou TC, Lin SC, Kao CR, et al. Clinical features of human intestinal capillariasis in Taiwan. World J Gastroenterol. 2004; 10:2391-3.
- Chichino G, Bernuzzi AM, Bruno A, Cevini C, Atzori C, Malfitano A, et al. Intestinal capillariasis (*Capillaria philippinensis*) acquired in Indonesia: a case report. Am J Trop Med Hyg. 1992; 47:10-2.
- Saichua P, Nithikathkul C, Kaewpitoon N. Human intestinal capillariasis in Thailand. World J Gastroenterol. 2008; 14:506-10.
- Soukhathammavong P, Sayasone S, Harimanana AN, Akkhavong A, Thammasack S, Phoumindr N, et al. Case report: Three cases of intestinal capillariasis in Lao People's Democratic Republic. Am J Trop Med Hyg. 2008; 79:735-8.
- Cross JH, Banzon TC, Murrell KD, Watten RH, Dizon JJ. A new epidemic diarrheal disease caused by the nematode *Capillaria philippinensis*. Industry and Tropical Health. 1970; 7:124-31.
- Kunaratnapruk S, Iam-Ong S, Chatsirimongkol C, Dhirasut C, Laohanuwat C. Intestinal Capillariasis in Province: A report of 100 cases. Ramathibodi Med J. 1983; 6:253-8.
- Sangchan A, Wongsanook A, Kularbkaew C, Sawanyawisuth K, Sukeepaisarnjaroen W, Mairiang

- P. The endoscopic pathologic findings in intestinal capillariasis: a case report. *J Med Assoc Thai.* 2007; 90: 175-8.
13. Intapan PM, Maleewong W, Sukeepaisarnjaroen W, Morakote M. An enzyme-linked immunosorbent assay as screening tool for human intestinal capillariasis. *Southeast Asian J Trop Med Public Health.* 2010; 41:298-305.
14. El Dib NA, Sabry MA, Ahmed JA, El-Basiouni SO, El-Badry AA. Evaluation of *Capillaria philippinensis* coproantigen in the diagnosis of infection. *J Egypt Soc Parasitol.* 2004; 34:97-106.
15. Intapan PM, Maleewong W, Sukeepaisarnjaroen W, Morakote N. Potential use of *Trichinella spiralis* antigen for serodiagnosis of human capillariasis philippinensis by immunoblot analysis. *Parasitol Res.* 2006;98:227-31.
16. Rowshani AT, Schot LJ, Ten Berge IJM. c-ANCA as a serological pitfall. *Lancet.* 2004; 363:782.
17. Hoffman GS, Specks U. Antineutrophil cytoplasmic antibodies. Review. *Arthritis Rheumatism.* 1998; 41: 1521-37.