

Clinical report

Benefits from genetic test in descendants of familial adenomatous polyposis syndrome: report of a family in southern Thailand

Worawit Wanitsuwan^{a,b}, Teeranut Boonpipatanapong^{a,b}, Samornmas Kanngern^{a,c}, Walawee Chaiyapan^{a,b}, Podchanapond Graidist^{a,d}, Surasak Sangkhathat^{a,b,d}

^aTumor Biology Research Unit; ^bDepartment of Surgery; ^cDepartment of Pathology; ^dDepartment of Biomedical Sciences, Faculty of Medicine, Prince of Songkla University, Hat Yai, Songkhla 90110, Thailand

Background: Familial adenomatous polyposis (FAP) is an inherited colorectal cancer predisposing syndrome that has an autosomal dominant mode of inheritance with complete penetrance. Although the disease-causing gene of FAP, the adenomatous polyposis coli (APC) gene, is well understood, genetic testing for FAP remains uncommon in Thailand, possibly because of its high cost.

Objective: Present a family in southern Thailand that had benefited from this test.

Subject and methods: The proband was a 31-year-old man who had rectal cancer with profuse adenomatous polyposis of his colon.

Results: APC mutation screening revealed a novel mutation at codon 1249 (TGC1249TAA) that could predict a premature stop codon. On screening of three siblings in the same generation who were alive and 11 members of the descendant generation, four cases were positive for the mutation. The positive members were confirmed to have a type of diffuse colonic polyposis by endoscopy, and a prophylactic colectomy was performed without complications for every affected individual.

Conclusion: A genetic test is cost-effective. It should be considered for FAP, especially when the number of at-risk family members is high.

Keywords: Adenomatous polyposis syndrome, APC gene, familial adenomatous polyposis coli

Colorectal cancer (CRC) ranks as the third most common cancer in Thailand [1-3]. According to the Thai cancer registry, 8,000 new cases of CRC are expected each year, and the incidence is increasing [4]. Although the etiology of CRC is multifactorial, it was estimated that about 5% of CRCs are an inherited condition. The most widely-known CRC-associated hereditary syndrome is familial adenomatous polyposis (FAP), a cancer predisposing syndrome that inadvertently leads to development of CRC [5].

It is recommended that a patient with FAP should be screened for APC mutations, but such genetic

testing is not common in low-income countries, especially in rural areas where resources for sophisticated tests are limited [6]. The cost of an adenomatous polyposis coli (APC) test is around 285-1,650 USD [5]. It is not covered by National Health Insurance of Thailand. A unit cost is high, which remains an important barrier for a genetic study [7, 8].

In this report, we present the case of an FAP family in southern Thailand that had clear benefit from the test. We hope that cases, such as this, will help persuade policy-makers that this test, although expensive, is worth the cost.

Family report

This study was approved by the Ethics Committee of Songklanagarind Hospital.

Correspondence to: Surasak Sangkhathat, MD, PhD, Tumor Biology Research Unit, Department of Surgery, Faculty of Medicine, Prince of Songkla University, Hat Yai, Songkhla 90110, Thailand. E-mail: surasak.sa@psu.ac.th

The index patient and his family history

The proband (case II.5, **Figure 1**) was a 31-year-old male farmer who presented to Colorectal Clinics of Songklanagarind Hospital, with a complaint of chronic bloody diarrhea for 10 months.

A colonoscopy revealed profuse polypoid masses at the rectosigmoid colon, resulting in a near complete luminal obstruction (**Figure 2**).

A total proctocolectomy with ileal pouch anal anastomosis was done. The histopathology showed adenocarcinoma of the proximal rectum of 4 cm size, invading pericolic tissue. There was nodal metastasis in five out of 44 nodes at the N1 level. A chest computerized tomography scan showed multiple small nodules, about 0.5 cm in size at the right upper lung, which did not progress during the follow-up period. An esophagogastroscope also found small sessile polyps in the stomach and duodenum. After surgery, the patient received a complete course of chemotherapy and did well up to 24 months of follow-up.

The patient had positive family history of colon cancer. His mother died of colon cancer at the age of 32 years. There are five siblings in his generation, and one of his elder sisters died of colon cancer at the age of 34 years. There are 11 members in the descending generation, aged 8-26 years old. Except for the member PIII.1 who reported chronic

abdominal pain, none of the members had significant gastrointestinal symptoms (see **Figure 1**).

APC genotyping study

Whole coding sequence genotyping of the APC gene, including deletion/duplication tests were outsourced to Gendia, Belgium (test reference number 2009.1309). The study found a novel mutation of the APC gene at the exon 15, codon 1249 (nucleotides 3746-3747 GC substituted by AA) (**Figure 3**). This substitution mutation alters an amino acid cysteine into a premature stop codon (Cys1249X). Beta-catenin immunohistochemistry of the tumor tissue from the index case showed a generalized nuclear accumulation pattern, which supported an activation of a Wnt-signaling pathway as a result of the APC mutation and suggested that the mutation was disease-causing.

We used a primer pair spanning the reported mutation [APC15F 5'GAG GCA GAA TCA GCT CCA TC 3' and APC15R 5' TCT GCT TCC TGT GTC GTC TG 3'] to re-amplify the segment of interest in the family members. The polymerase chain reaction (PCR) products were analyzed with restriction fragment length polymorphism (RFLP) using a restriction enzyme Tru9I (Promega Inc, Wisconsin, USA) and direct nucleotide sequencing. All genetic studies were repeated twice.

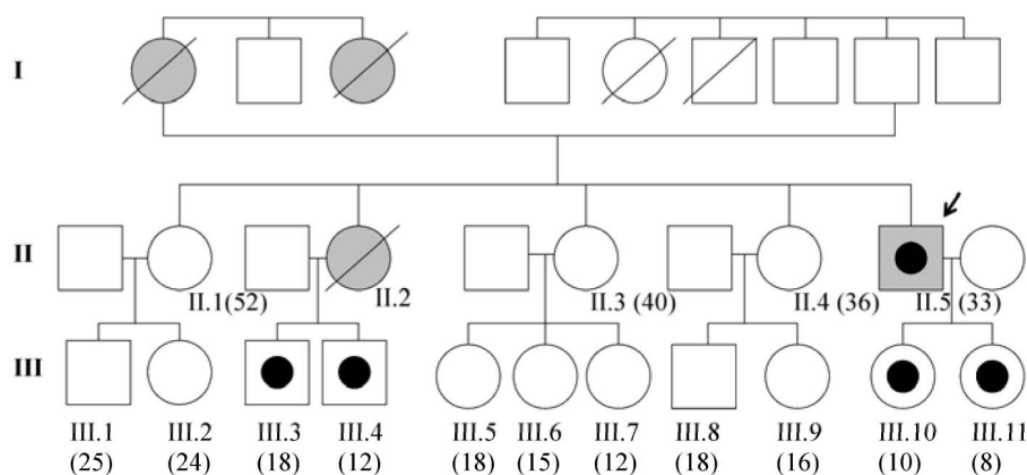


Figure 1. Pedigree of the reported family. Four members in generation three, found to have inherited the APC mutation from their parents, had colonic polyposis. (Shaded objects=colorectal cancer patients, objects with black dot=individuals with the mutation, in parentheses: age)

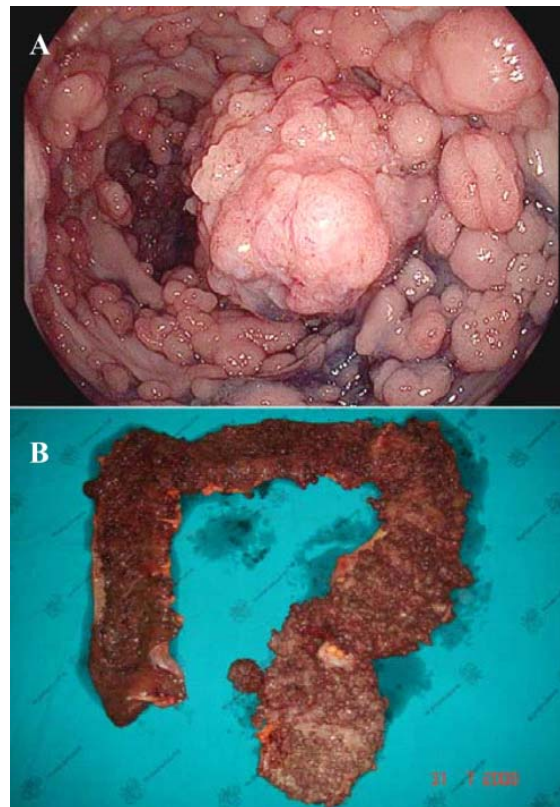


Figure 2. Colonoscopic finding of the proband patient (A) and his colectomy specimen, showing profuse polyposis lesions along the entire length of colon (B)

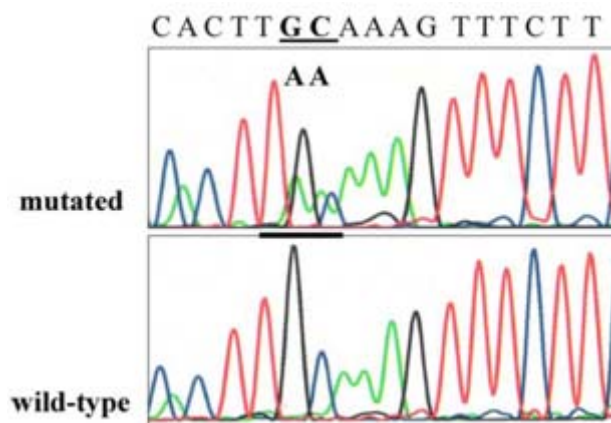


Figure 3. Electropherograms demonstrating a two-base substitution at the nucleotides 3746-3747 of the APC gene (GC substituted by AA). This mutation leads to a premature truncation of translation at codon 1249 (Cys1249X)

Familial screening

First-degree family members including siblings and their children were invited for counseling and genetic testing under informed consent. Except for case II.2 that had died of colorectal cancer prior to

the study, all related members at the same generation as the index case and their children participated the genetic test. The study found the same APC mutation in two male children of the case II.2 and two daughters of the index patient.

Colonoscopies have been performed on the four cases with positive mutations. The study revealed multiple sessile polyps along the entire length of the colon in all cases. Biopsies homogeneously showed tubular adenoma in all the patients. A prophylactic total colectomy and a straight ileoanal anastomosis were performed on the children with polyposis. The surgical specimen from each patient showed profuse colonic polyposis, attenuating at the rectosigmoid region. The number of polyps in each case was less than that found in the index case; all of them had more than 1,000 lesions.

Economic analysis

If at-risk family members of FAP do not have access to a genetic study, they are encouraged to be periodically screened by an endoscopy for an occurrence of polyposis. A standard guideline for endoscopic screening in such patients suggests an annual endoscopy from the age of 10-24 years, after which, if no polyps have been found, the surveillance intervals are increased thereafter [9]. Based on the actual situation of this family, if the family had no known mutations, each of the seven negative cases in the descendant generation would have required at least 1 to 10 endoscopies or 34 unnecessary endoscopic studies before they reached their 25 years. Setting aside accessory expenditures such as anesthetic cost and travel expenses, the total endoscopic cost would be 2,300 Thai Baht x 34, or 78,200 Thai Baht (approximately 2,370 USD). The cost is 160% of the fixed costs of APC whole-coding sequence genotyping in the proband at 49,000 Thai Baht (approximately 1,480 USD). Although the cost of additional spot genetic testing performed in 16 members in the generation P2 and P3 generations (200 Thai Baht x 16 = 3,200 Thai Baht) was counted, the overall cost per family remained much lower.

Discussion

From an economic point of view, to invest in preventive care is more cost-effective than therapy, especially when any preventive measure is given to the patients at risk. FAP is a single-gene condition that invariably has an autosomal dominant mode of inheritance with complete penetrance [5]. For this reason, identification of family members who have inherited the FAP genetic pathology theoretically provides an early exclusion of unaffected cases and allows those who have mutations to enroll into more

intensive work-ups and prophylactic surgery. However, such genetic diagnosis is not a common practice in Thai health care setting, possibly due to the high cost of the whole-gene genotyping and the attitude of physicians regarding the test. Studies from the United States have also demonstrated that awareness of a health care provider and insurance coverage were factors that significantly determined surveillance behaviors among members of FAP families [7, 8]. Surprisingly, a survey indicated that less than 30% of primary care physicians in the US recommended FAP family members to begin polyposis screening at puberty [10].

In this family, we have shown a clear economic benefit from the genetic test. With the current standard of mutation study, including a combination of nucleotide sequencing and deletion test, APC mutations can be identified in 85-95% of FAP patients [5]. Considering this technical limitation, cost needed per positive yield will exceed the actual test cost. The cost can be balanced against the substituting cost of unnecessary endoscopies for unaffected members. In addition, family members with negative results can be released from psychological stress caused by the cancer risk. To understand the full benefit of a high cost genetic test such as the APC test, a health care provider needs to view the big picture of the whole family. The more at-risk members a family has, the more cost-effective the test scores.

The APC genotyping in our index case revealed a deletion mutation at codon 1249, which leads to a premature stop. Although the mutation at the same codon has been reported by Miyoshi et al. [11], the details of the nucleotide alteration were not alike. Positive beta-catenin nuclear accumulation could be interpreted as indicating that Wnt-signaling was activated in our patient, which was evidence that supports a disease-causing role of the mutation. The high number of polyps in our patients undergoing colectomy at their varying ages contradicts a previous speculation that codon 1249 is a boundary in the gene that distinguishes APC mutations that are correlated with sparse polyposis from the profuse type [12].

Intestinal adaptation after resection progresses well in the childhood period. Because of that, it is suggested that a prophylactic colectomy should be done as soon as the diagnosis of adenomatous polyposis can be confirmed. In our experience, an ileal pouch ileoanal anastomosis does not provide more impressive outcomes than a straight ileoanal

anastomosis. In addition, the ileal pouch reconstruction holds a greater risk of complications such as ischemia and infection of the pouch. This surgical opinion is consistent with that of some other authors [13, 14]. However, a study comparing ileal pouch and ileoanal anastomosis techniques reported that although FAP patients who underwent straight ileoanal anastomosis had better functional outcome, they had more long-term failure and such patients need to be followed carefully [15]. We chose a protective ileostomy not only to protect the anastomosis but also to provide some time for intestinal adaptation.

In conclusion, we presented the case of a family with FAP that had benefit from APC genotyping. The test was able to identify cases that would benefit from early surgical intervention. The model encourages the implementation of such genetic tests to standard care.

Acknowledgement

Cost of genetic study was funded by Songklanagarind Hospital. The authors want to thank Dr. Anyarat Tangkitngamwong for her help in constructing a complete pedigree and Mr. David Patterson for language editing.

References

1. Sriamporn S, Wiangnon S, Suwanrungruang K, Rungsrikaji D, Sukprasert A, Thipsuntornsak N, et al. Risk factors for colorectal cancer in northeast Thailand: lifestyle related. *Asian Pac J Cancer Prev*. 2007; 8: 573-7.
2. Srisukho S, Srivatanakul P, Sumitsawan Y. Colon and rectum. In: Khuhaprema T, Srivatanakul P, Sriplung H, et al. editors. *Cancer in Thailand*. Vol. IV, 1998-2000. Bangkok: Bangkok Medical Publisher; 2007; p. 34-5.
3. Khuhaprema T, Srivatanakul P. Colon and rectum cancer in Thailand: an overview. *Jpn J Clin Oncol*. 2008; 38:237-3.
4. Sriplung H. Projection of cancer problems. In: Khuhaprema T, Srivatanakul P, Sriplung H, et al. editors. *Cancer in Thailand*. Vol. IV, 1998-2000, Bangkok: Bangkok Medical Publisher; 2007. p. 81-3.
5. Kaz AM, Brentnall TA. Genetic testing for colon cancer. *Gastroenterol Hepatol*. 2006; 3:670-9.
6. Savithri HS, Venkatesha Murthy HS, Baskaran G, Appaji Rao N, Kool D, Edkins E, et al. Predictive testing for familial adenomatous polyposis in a rural South Indian community. *Clin Genet*. 2000; 58:57-60.
7. Kinney AY, Hicken B, Simonsen SE, Venne V, Lowstuter K, Balzotti J, Burt RW. Colorectal cancer surveillance behaviors among members of typical and attenuated FAP families. *Am J Gastroenterol*. 2007; 102:153-62.
8. Levine FR, Coxworth JE, Stevenson DA, Tuohy T, Burt RW, Kinney AY. Parental attitudes, beliefs, and perceptions about genetic testing for FAP and colorectal cancer surveillance in minors. *J Genet Couns*. 2010; 19:269-79.
9. National Comprehensive Cancer Network Colorectal Screening Panel (2009). Hereditary syndromes: familial adenomatous polyposis syndromes. NCCN Practice Guidelines in Oncology: Colorectal Cancer Screening, v.1.2009 [cited 2010 Apr 15]. Available from: http://www.nccn.org/professionals/physician_gls/PDF/colorectal_screening.pdf.
10. Schroy PC 3rd, Barrison AF, Ling BS, Wilson S, Geller AC. Family history and colorectal cancer screening: a survey of physician knowledge and practice patterns. *Am J Gastroenterol*. 2002; 97:1031-6.
11. Miyoshi Y, Nagase H, Ando H, Horii A, Ichii S, Nakatsuru S, et al. Somatic mutations of the APC gene in colorectal tumors: mutation cluster region in the APC gene. *Hum Mol Genet*. 1992; 1:229-33.
12. Nagase H, Miyoshi Y, Horii A, Aoki T, Ogawa M, Utsunomiya J, et al. Correlation between the location of germ-line mutations in the APC gene and the number of colorectal polyps in familial adenomatous polyposis patients. *Cancer Res*. 1992; 52:4055-7.
13. Seetharamaiah R, West BT, Ignash SJ, Pakarinen MP, Koivusalo A, Rintala RJ, et al. Outcomes in pediatric patients undergoing straight vs J pouch ileoanal anastomosis: a multicenter analysis. *J Pediatr Surg*. 2009; 44:1410-7.
14. da Luz Moreira A, Church JM, Burke CA. The evolution of prophylactic colorectal surgery for familial adenomatous polyposis. *Dis Colon Rectum*. 2009; 52: 1481-6.
15. Soravia C, Klein L, Berk T, O'Connor BI, Cohen Z, McLeod RS. Comparison of ileal pouch-anal anastomosis and ileorectal anastomosis in patients with familial adenomatous polyposis. *Dis Colon Rectum*. 1999; 42:1028-33.