

Brief communication (Original)

Accuracy of ultrasound in pediatric undescended testes

Teerasak Phewplung, Atchara Mahayosnond, Panruethai Trinavarat

Department of Radiology, Faculty of Medicine, Chulalongkorn University, Bangkok 10330, Thailand

Background: The undescended testis represents a common condition affecting male infants with significant clinical implications such as infertility and testicular malignancy. There is controversy as to the diagnosis when a clinical examination fails to identify a testis.

Objective: Investigate the value of ultrasound in the diagnosis of undescended testis, and evaluate the correlation between the preoperative ultrasonographic data and operative findings.

Material and method: Thirty-nine boys (age: 3 months -12 years) with undescended testes were examined between January 2003 and December 2007. All the boys had undergone a sonogram performed for localizing the undescended testes. Only 20 boys were sent for inguinal exploration, or other surgical procedures for localizing the undescended testes. We calculated specificity, sensitivity, positive predictive value (PPV), negative predictive value (NPV), and the accuracy of ultrasonographic diagnosis in boys with undescended testes.

Results: Twenty-nine undescended testes were included in this study. Ultrasonography had a sensitivity of 82%, a specificity of 0%, PPV of 96%, NPV of 0%, and accuracy of 79% in the diagnosis of the undescended testis.

Conclusions: The sensitivity and specificity including NPV of ultrasound had the unsatisfactory outcomes.

Keywords: Accuracy, pediatric, testis, ultrasound, undescended

The undescended testis represents a common condition affecting male infants with significant clinical implications such as infertility and testicular malignancy. This condition corresponds to 1 to 6% of full-term neonates and approximately 0.8% of infants at one year old [1]. The overall incidence is higher in preterm infants. Most comprehensive studies cite a frequency of 21 to 23% for male neonates with a birth weight <2.5 kg [2, 3]. The higher frequency of undescended testes in premature infants is largely related to birth before the completion of testicular inguinoscrotal migration. This normally begins in the 28th week of pregnancy and is not typically complete until 40 weeks of gestation [4]. Although most are commonly found unilaterally, two undescended testes are found in nearly 10% of patients [5]. Approximately 20% of undescended testes are non-palpable on physical examinations [6].

In the group of non-palpable testes, approximately 50% are abdominal, 45% are atrophic, and only 5% are in the inguinal canal [8, 9]. The atrophic testis is known as the vanishing testis, and is usually in the inguinal canal. An undescended testis is prone to infertility and testicular malignancy [4].

There is currently controversy as to the diagnosis when a clinical examination fails to identify a testis. Ultrasound is the most common study by diagnostic imaging. This study employs the evaluation of undescended testes for several reasons. These are that most undescended testes lie within the inguinal canal and are therefore readily accessible for evaluation, there is non-ionizing radiation, and the technology is portable and widely available.

In this study, we investigated the value of ultrasound in the diagnosis of undescended testes, and evaluated the correlation between the preoperative ultrasonography data and the operative findings.

Material and method

The study was approved by the Ethics Committee of the Faculty of Medicine, Chulalongkorn University.

Correspondence to: Assoc. Prof. Atchara Mahayosnond, Department of Radiology, Faculty of Medicine, Chulalongkorn University, Bangkok 10330, Thailand. E-mail: atchara.m@chula.ac.th

Data were collected retrospectively between January 2003 and December 2007 of 58 boys under the age 15 years. The boys had been physically examined for undescended testes. We excluded boys who had had a previous inguinal surgical procedure such as a hernia repair or orchidopexy. Nineteen boys had bilateral undescended testes, and 20 boys had a unilateral undescended testis.

All boys had undergone a sonogram performed for localizing the undescended testes using an imaging system (Acuson Sequoia 512 ultrasound system with Acuson 15L8 linear transducer). The examination was performed by a pediatric radiologist or the resident in radiology under pediatric radiologist control. An undescended testis appears hypoechoic and may be round or ovoid depending upon location. The mediastinum testis was identified for confident diagnosis (see **Fig 1**).

Only 20 boys were sent for inguinal exploration, or other surgical procedures for localizing the undescended testis. Eight boys had bilateral undescended testes, and 13 boys had a unilateral undescended testis, resulting in 29 testes.

We used a two-by-two table for calculating

specificity, sensitivity, positive predictive value (PPV), negative predictive value (NPV), and the accuracy of ultrasonographic diagnosis in boys with undescended testes.

Results

Results of ultrasound and surgical findings of 29 undescended testes are shown in **Table 1**. Twenty-four testes had positive ultrasound findings. Of these, twenty-two testes were located within the inguinal canal, and two testes were found in the scrotal sac. The other five testes were not found by ultrasound. Of the 24 testes that were found by ultrasound, there was one false positive result, which the ultrasound placed in the inguinal canal.

In breaking down further the location of the testes, the 22 testes found by ultrasound in the inguinal canal were found in surgery as 19 inguinal testes, two abdominal testes, and one negative surgical findings. The two scrotal testes by ultrasound were found as one inguinal testes and one scrotal testis. Of the five ultrasound-negative results, two testes were in inguinal canal, and three testes were located in the abdomen. (**Table 2**).

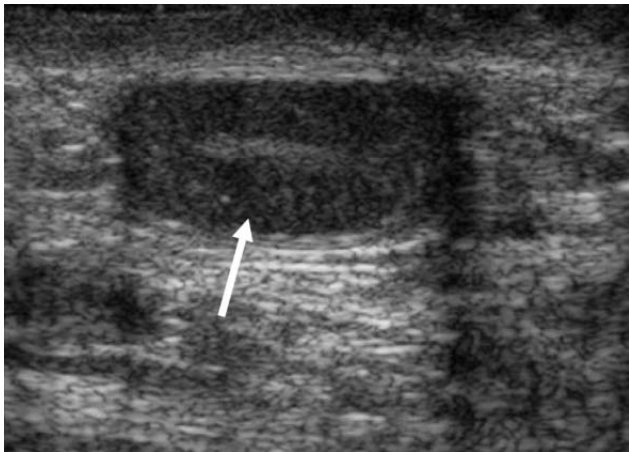


Fig. 1 Ultrasonic imaging of a one-year old boy with an undescended testis. This image shows normal size, oval-shaped hypoechoic testis with thin central hyperechoic line, representing a mediastinal testis (indicated by arrow) located in the inguinal canal.

Table 1. Ultrasound and surgical findings of 29 undescended testes.

	Surgical positive	Surgical negative	Total
Ultrasound positive	23	1	24
Ultrasound negative	5	0	5
Total	28	1	29

Table 2. Findings of ultrasound and surgical exploration in boys with undescended testes.

Ultrasonographic locations	Surgical locations
5 testes (not visualized)	2 inguinal testes (1 atrophic) 3 abdominal testes
22 inguinal testes	1 absence on surgery 19 inguinal testes 2 abdominal testes
2 scrotal testes	1 inguinal testis 1 high scrotal testis

Based on this, using the two-by-two table, the ultrasound had a sensitivity of 82%, a specificity of 0%, NPV of 0%, PPV of 95.8% and an accuracy of 79.3% in the diagnosis of undescended testes.

Discussion

Many studies have investigated the value of ultrasound in the diagnosis of undescended testes. There have been 12 studies evaluating the usefulness of ultrasound in undescended testes. However, their conclusions are far from unified. In fact, some authors recommended ultrasound for its feasibility and potential to settle the subsequent operative procedure [10-16]. Others are skeptical because they observed a poor outcome for non-palpable testis and the necessity for laparotomy were not excluded by ultrasound [8, 17-19]. Most of the studies included only a small group of patients [10, 14-15, 17, 18]. The study by Sagrid MP Nijs et al. [9] included the largest group of patients (about 152 testes) and suggested ultrasound as the first modality to evaluate non-

palpable testes in boys for determination of the location to facilitate planning the surgical procedure. Most studies compared ultrasound results with the operative findings [8, 11-13, 15-16]. Others compared computed tomography and/or magnetic resonance imaging with ultrasound [10, 14, 19]. The sensitivity and specificity including accuracy of ultrasound is different among these studies.

In our study, five testes in a group of negative ultrasounds were localized as three abdominal testes, and one atrophic testis. This corresponds to previous studies that showed 50% of clinically undescended testes as abdominal testes and 45% as atrophy [8, 9]. In two abdominal testes, ultrasound located them deep in the inguinal canal, which could be sliding between deep inguinal ring and intra-abdomen. The same postulation occurred for one inguinal testis that ultrasound showed in a high scrotal sac. Only one false positive result was ultrasound located in the inguinal canal, which could be a lymph node enlargement, as shown in **Fig. 2**.

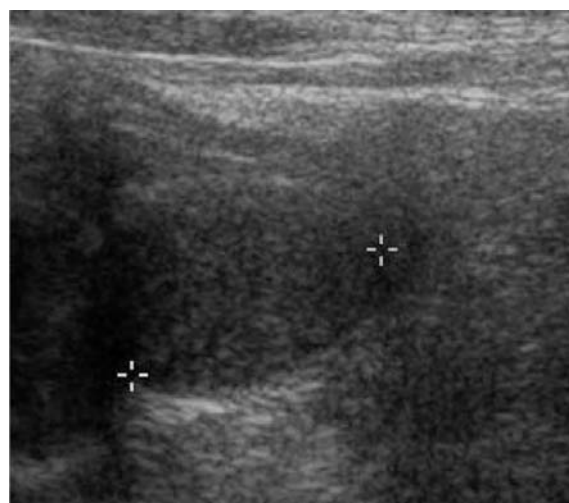


Fig. 2 Ultrasonic image of a one-year old boy with an undescended testis. 1.7-cm hypoechoic lesion (indicated by *) in the right inguinal canal are shown by ultrasound. After inguinal exploration, the absence of right testis in the inguinal region is noted. This suggests that this hypoechoic lesion could be an inguinal node.

The feasibility of ultrasound, non-ionizing radiation, and portability may convince us to recommend ultrasound for the first modality in the diagnosis of undescended testes. However, the present results of sensitivity and specificity showed unsatisfactory outcomes. Five false negative results of laparotomy or inguinal exploration in our study should not be omitted even if the ultrasound shows the absence of testis.

In conclusion, the sensitivity and specificity including NPV of ultrasound had an unsatisfactory outcomes.

The authors have no conflict of interest to declare in this study.

References

1. Friedland GW, Chang P. The role of imaging in the management of the impalpable undescended testis. *Am J Roentgenol*. 1988; 151:1107-11.
2. John Radcliffe Hospital Cryptorchidism Study Group. Cryptorchidism: a prospective study of 7500 consecutive male births, 1984-8. *Arch Dis Child*. 1992; 67:892-9.
3. Scorer CG. The descent of the testis. *Arch Dis Child*. 1964; 39:605-9.
4. Christensen JD, Dogra VS. The undescended testis. *Semin Ultrasound CT MR*. 2007; 28:307-16.
5. Frush DP, Sheldon CA. Diagnostic imaging for pediatric scrotal disorders. *Radiographics*. 1998; 18:969-85.
6. Guvenc BH, Sozubir S, Ekingen G, Senel U. Advantages of video-assisted approach in detecting epididymal anomalies and treatment of nonpalpable testis. *Urol Int*. 2005; 74:127-34.
7. Gearhart JP, Jeffs RD. Diagnostic maneuvers in cryptorchidism. *Semin Urol*. 1988; 6:79-83.
8. Elder JS. Ultrasonography is unnecessary in evaluating boys with a nonpalpable testis. *Pediatrics*. 2002; 10:748-51.
9. Nijs SM, Eijsbouts SW, Madern GC, Leyman PM, Lequin MH, Hazebroek FW. Nonpalpable testes: is there a relationship between ultrasonographic and operative findings? *Pediatr Radiol*. 2007; 37:374-9.
10. Wolverson MK, Houttuin E, Heiberg E, Sundaram M, Shields JB. Comparison of computed tomography with high-resolution real-time ultrasound in the localization of the impalpable undescended testis. *Radiology*. 1983; 146:133-6.
11. Graif M, Czerniak A, Avigad I, Strauss S, Wolfstein I, Itzchak Y. High-resolution sonography of the undescended testis in childhood: an analysis of 45 cases. *Isr J Med Sci*. 1990; 26:382-5.
12. Cain MP, Garra B, Gibbons MD. Scrotal-inguinal ultrasonography: a technique for identifying the nonpalpable inguinal testis without laparoscopy. *J Urol*. 1996; 156(2 Pt 2):791-4.
13. Kanemoto K, Hayashi Y, Kojima Y, Maruyama T, Ito M, Kohri K. Accuracy of ultrasonography and magnetic resonance imaging in the diagnosis of non-palpable testis. *Int J Urol*. 2005; 12:668-72.
14. Maghnie M, Vanzulli A, Paesano P, Bragheri R, Palladini G, Preti P, et al. The accuracy of magnetic resonance imaging and ultrasonography compared with surgical findings in the localization of the undescended testis. *Arch Pediatr Adolesc Med*. 1994; 148:699-703.
15. Weiss RM, Carter AR, Rosenfield AT. High resolution real-time ultrasonography in the localization of the undescended testis. *J Urol*. 1986; 135:936-8.
16. Kullendorff CM, Hederstrom E, Forsberg L. Preoperative ultrasonography of the undescended testis. *Scand J Urol Nephrol*. 1985; 19:13-5.
17. Malone PS, Guiney EJ. A comparison between ultrasonography and laparoscopy in localising the impalpable undescended testis. *Br J Urol*. 1985; 57: 185-6.
18. Pekkafuli MZ, Sahin C, Ilbey YO, Albayrak S, Yildirim S, Basekim CC. Comparison of ultrasonographic and laparoscopic findings in adult nonpalpable testes cases. *Eur Urol*. 2003; 44:124-7.
19. Hrebinko RL, Bellinger MF. The limited role of imaging techniques in managing children with undescended testes. *J Urol*. 1993; 150(2 Pt 1):458-60.