

Mini-Review**Blindness as a result of acid attacks in Cambodia**

Vicky Hsin-Ju Lu, James Gollogly, Soryoun Soeung, Thorn Pok
Children's Surgical Center, Phnom Penh, Cambodia

Background: Fifty-three patients who had been attacked with acid were treated over the last three years, and 45% suffered blindness in one or both eyes as a result.

Objective: Review the charts of all 53 patients to see if the proximate cause of the blindness could be determined to prevent it happening to others.

Results: Three principal causes of blindness were direct damage from acid, limbal stem cell loss leading to later eyeball perforation, and delayed corneal abrasion from eyelid deformity. Only the latter cause could be prevented at this time, since the strength of the acid used in the attack could not be controlled, nor could limbal stem cell transplants be performed.

Conclusion: Assessment of the ophthalmic injuries revealed three main categories of visual impairment, only one of which could be treated effectively at this stage.

Keywords: Acid attack, blindness, Cambodia, limbal stem cells

Acid assaults are premeditated acts, usually in retaliation for perceived wrongdoings. The acid is aimed at the face with the deliberate intent of causing severe pain and disfigurement, often resulting in severe impairment of function.

Lack of effective first-aid and delayed presentation add to the complexity of injury and care, providing major challenges to health care systems. Many patients become blind in one or both eyes.

In this article, we reviewed ophthalmic injuries in patients who had been attacked with acid and subsequently were treated at the Children's Surgical Center (CSC), Phnom Penh, over a three-year period. Causes for blindness were sought, and a literature review of management of these conditions was performed.

Method

A retrospective review of medical records at CSC was conducted for patients who presented between

January 2007 and January 2010, with acid burn injury and facial involvement. Ophthalmic data was specifically collected to determine the presence or absence of blindness, and the possible reasons for blindness. Visual acuities were recorded in Snellen format, converted to LogMAR for analysis. Statistical analyses were performed using SPSS 17.0 (IBM SPSS, Chicago, USA).

Results

Between January 2007 and 2010, 53 patients presented to Children's Surgical Centre (CSC) with acid burn injuries involving the face. There were 28 females and 25 males, with a mean age 31 years (median: 32 years, SD: 12.0 years).

Thirty-two patients had involvement of one or both eyes and twenty-four patients were blind in one or both eyes (**Table 1**). A further four patients had corneal scarring, which did not affect visual acuity at time of examination. One patient was noted to have had a previous keratoplasty at another centre following acid burn, prior to presentation at CSC.

Table 2 outlines the causes of visual deterioration or blindness in 38 eyes of 24 patients.

Correspondence to: James Gollogly, MB, FACS, FRCSC, Children's Surgical Center, PO Box 1060, Phnom Penh, Cambodia. E-mail: jim@csc.org

Table 1. Eye injury and blindness in patients (n=53).

Injury	Number (%)
Eye injury	32 (60.6)
Blindness	24 (45.3)
Right eye	5 (9.4)
Left eye	5 (9.4)
Both	14 (26.4)

Twenty-nine patients had vision recorded for one or both eyes. Nineteen eyes had visual acuities (VA) of hand movement or greater, with a mean VA of 6/40 (nine right eyes) and 6/18 (10 left eyes). On subsequent review, the number of patients with visual acuity of hand movement or greater had decreased to nine eyes (four right eyes and five left eyes), with VA of 6/49 and 6/75 respectively. Four eyes of two patients were noted to have deterioration of visual acuity resulting in no light perception, secondary to limbal cell ischaemia within two weeks of initial review.

Non-surgical treatment was the initial standard of care provided to all patients. This consisted of the local application of topical steroids, antibiotics, and lubricants into the eyes. Surgery was performed as outlined in **Table 3**.

Two deaths were reported in the 53 patients treated. One was from overwhelming sepsis secondary to infection, and the other was from inadequate ventilation due to a markedly restricted airway during the induction of anesthesia.

Discussion

Acid assaults are deliberate criminal acts, mostly aimed at inflicting pain and causing permanent disfigurement [1]. Even in small volumes [2], acid can cause significant physical damage, with subsequent psychosocial impairment, posing a major economic burden on stretched health care services [3].

Perpetrators of acid attacks favour a cheap agent with easy accessibility [4, 5]. In Cambodia and other Southeast Asian countries, sulphuric acid is readily available for use in car batteries and in the textile industry [3], nitric acid is used by jewelers, and hydrochloric acid is used in the rubber trade.

Forty-five percent of patients became blind in one or both eyes because of acid attack, according to the results of our study. This is comparable with literature rates of 14-63% [1, 2, 6]. In our study, the causes for visual impairment were subsequently categorized into immediate damage from acid exposure to the eye(s), limbal cell ischaemia with or without subsequent perforation, and corneal scarring from eyelid dysfunction.

Direct damage from acid attack

The extent of immediate injury on presentation is dependent on a number of factors including the concentration and volume of the acid entering the eyes, as well as the duration of exposure of ophthalmic tissues. First aid would ideally include immediate irrigation of the eyes with flowing water, continuing then for at least 60 minutes in order to minimize ocular

Table 2. Causes of visual deterioration or blindness.

Visual deterioration or blindness subsequent to presentation	Number (%)
Damage from direct contact with acid	14 (36.8)
Persistent epithelial defect and opacity secondary to limbal cell ischaemia	9 (23.6)
With subsequent perforation	4 (10.5)
Eyelid dysfunction leading to scarring of visual axis	15 (39.5)
Total	38

Table 3. Types of operation carried out in 29 operations on the eyes of 21 patients.

Total eyes	Number (%)
Tarsorrhaphy	4 (13.8)
Release of contracture	1 (3.4)
With full-thickness skin graft	22 (75.9)
Ectropion repair	2 (6.9)
Total	29

damage [2, 4]. However, this occurred infrequently in our population, with time from injury to irrigation ranging from jumping into a river soon after the attack to not starting irrigation until several hours later [5].

Limbal stem cell Ischaemia

Some patients in our series appeared to have limited immediate damage to their corneas, but developed corneal perforation within a week or two. Research in the literature revealed this to be due most likely to the death of limbal stem cells (LSC), which are essential for healthy corneal epithelium [8]. LSC ischaemia manifests itself with epithelial defects, corneal vascularisation, and opacification, and, in severe cases, perforation from corneal melt [9, 10]. Although we are now aware of LSC transplantation as described below, it has not yet been possible for us to apply this technique in our patients.

Several studies have shown successful regression of neovascularisation and improvement of corneal transparency [11] with LSC grafting for partial or total LSC deficiency (LSCD). In some cases, patients have managed to preserve part of their corneal and ocular surfaces during an assault, as they instinctively close their eyes [12]. In these instances, ipsilateral limbal cell graft may be possible, redistributing LSCs and

thus promoting epithelialisation. In total LSCD, where the entire circumference of the cornea is damaged, transplantation of LSC grafts can be performed with autologous cells from an uninjured eye, or allograft transplantation can be carried out. Autologous transplantations, first introduced by Kenyon and Tseng [13], involve transfer of LSC grafts from the healthy contralateral eye to the injured eye. Conventionally, two large free grafts of 5-7 mm limbal length are taken, although the exact optimal size is not known. Although occurring rarely, there is a risk in the donor eye of corneal keratitis and infection, and even perforation due to the development of LSCD [11]. When both eyes are involved, allograft transplantation (LSC from living donor or cadaveric eyes) may be considered. However, this adds the risk of graft rejection and systemic immune-suppression would be required. Amniotic membrane, an immunologically inert tissue, promotes epithelialisation and suppresses inflammation, and may be useful in the surgical treatment of eye burn injury. It can serve as a patch or graft in partial LSCD (following primary insult or as a result of graft harvest) [11], and provides an inflammation-free environment in which epithelial cells can proliferate in LSC grafting [9]. Some features of LSCD are shown in **Fig. 3-6**.

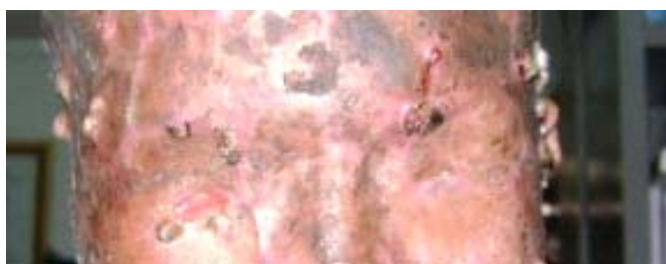

Fig. 1 Direct insult of acid to the ocular region.

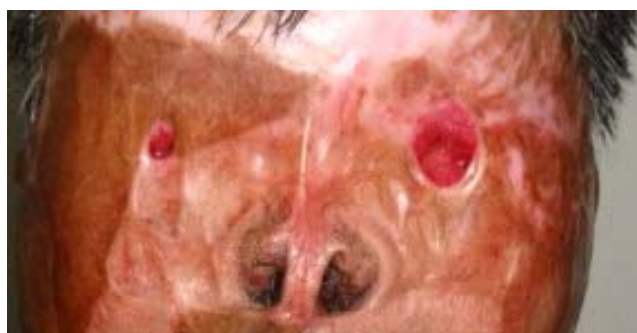

Fig. 2 Direct insult of acid to the ocular region.

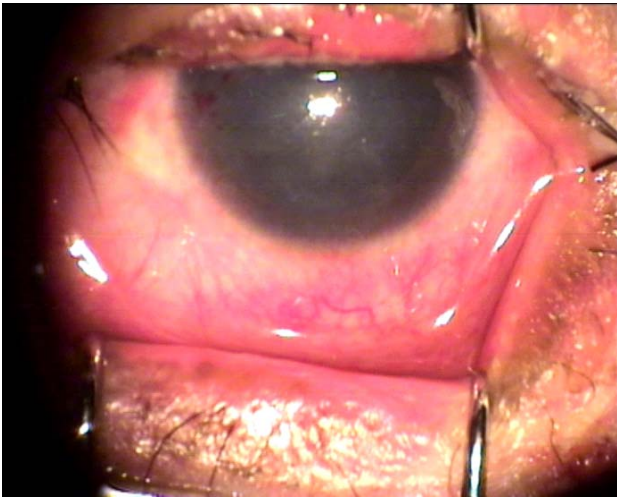


Fig. 3 Limbal cell ischaemia with corneal haziness and corneal vascularisation.

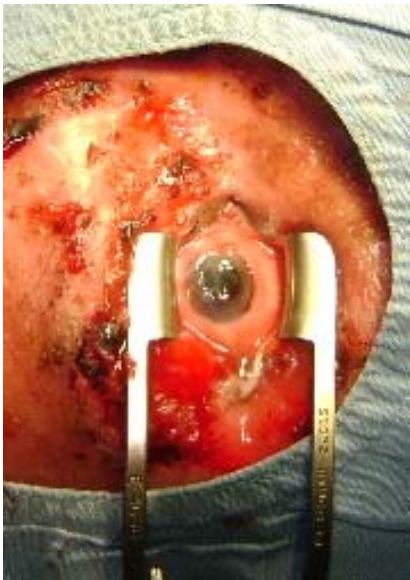


Fig. 4 Corneal haziness from limbal stem cell ischaemia.

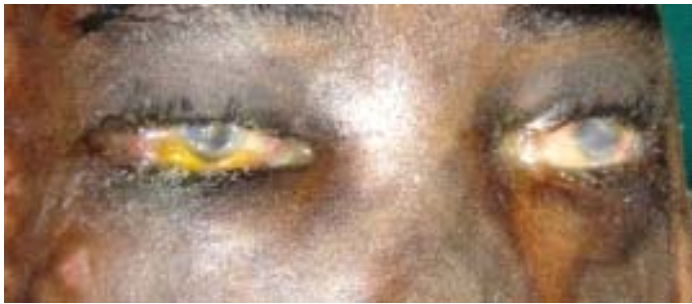

Fig. 5 Corneal haziness from limbal cell ischaemia and total ischaemia both eyes.

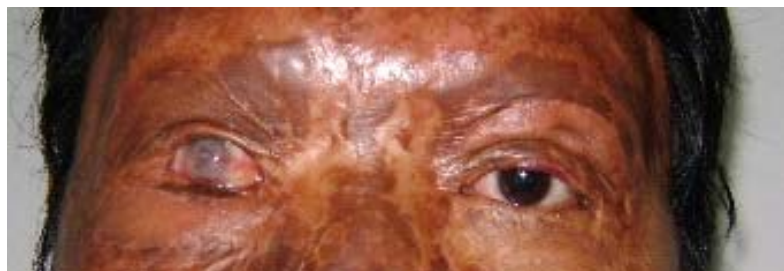

Fig. 6 Conjunctivalisation and corneal vascularisation from limbal stem cell deficiency following ischaemia.

Eyelid deformities causing secondary blindness

Eyelids serve to protect the anterior surface of the globe and distribute the tear film [3], but these functions are lost with scarring and/or contracture of the eyelids, increasing the risk of corneal abrasion with subsequent opacification and thus visual impairment [14]. Blindness can thus result as a secondary phenomenon, due to impaired function of the eyelids. It was relatively easy to surgically prevent this cause of blindness, as long as the patient presented in a timely

fashion. Tarsorrhaphy, of several different types, was used to maintain lubrication of the eye, and prevent contracture of the lids. Entropions can damage the cornea by physical irritation of intumed eyelashes, but eyelash removal or surgical correction of the entropion could prevent corneal scarring and diminished vision. Ectropions impaired lubrication of the eyes, but again could be easily corrected with surgical releases and skin grafting or flap reconstructions. **Figures 7-9** illustrate a typical case.

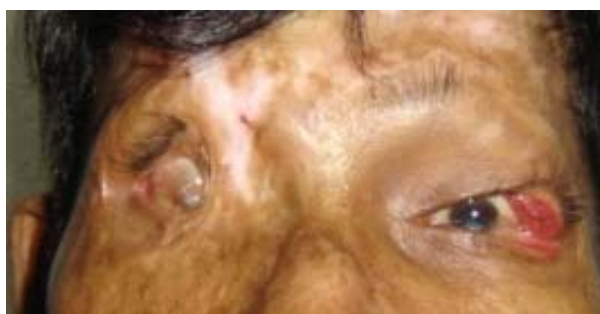

Fig. 7 Ectropion left eye and right eye phthisis following globe perforation secondary to limbal stem cell deficiency.

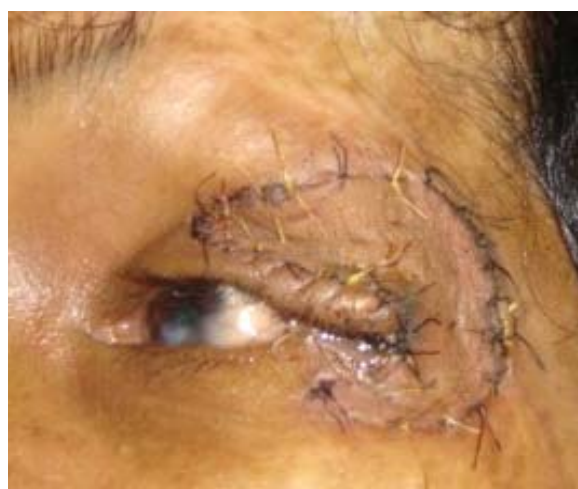

Fig. 8 Left eye ectropion repair with full-thickness skin graft.

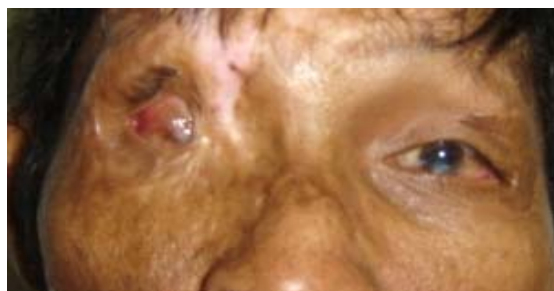

Fig. 9 Three months post repair.

Conclusion

Acid assault causes devastating and complex physical and psychological injuries. Unfortunately, due to suboptimal first aid and late presentations, eye involvement can often be severe with irreversible visual impairment. Increase in public awareness regarding the harmful effects of acid burn [12]. Education on effective first-aid and timely presentation to health care will be imperative in minimizing acid assault related problems [13]. In our institution, assessment of the ophthalmic injuries revealed three main categories of visual impairment, only one of which can be treated effectively at this stage. We are interested in the potential for LSC auto/allograft to improve or decrease deterioration of visual function in appropriate patients.

Acknowledgements

All authors contributed to the care of these patients and have no conflict of interest to declare. The Children's Surgical Canter is a non-profit facility that provides free care to patients in Cambodia and trains local medical graduates. Volunteer physicians from abroad often rotate through this hospital in Phnom Penh.

References

1. Asaria J, Kobusingye OC, Khingi BA, Balikuddembe R, Gomez M, Beveridge M. [Acid burns from personal assault in Uganda](#). *Burns*. 2004; 30:78-81.
2. Young RC, Ho WS, Ying SY, Burd A. Chemical assaults in Hong Kong: a 10-year review. *Burns*. 2002; 28:651-3.
3. Milton R, Mathieu L, Hall AH, Maibach HI. [Chemical assault and skin/eye burns: two representative cases, report from the Acid Survivors Foundation, and literature review](#). *Burns*. 2010; 36:924-32.
4. Mannan A, Ghani S, Clarke A, Butler PE. [Cases of chemical assault worldwide: a literature review](#). *Burns*. 2007; 33:149-54.
5. Yeong EK, Chen MT, Mann R, Lin TW, Engrav LH. Facial mutilation after an assault with chemicals: 15 cases and literature review. *J Burn Care Rehabil*. 1997; 18:234-7.
6. Ho WS, Ying SY, Chan HH, Chow CM. [Assault by burning-a reappraisal](#). *Burns*. 2001; 7:471-4.
7. Xie Y, Tan Y, Tang S. Epidemiology of 377 patients with chemical burns in Guangdong province. *Burns*. 2004; 30:569-72.
8. Cotsarelis G, Cheng SZ, Dong G, Sun TT, Lavker RM. [Existence of slow-cycling limbal epithelial basal cells that can be preferentially stimulated to proliferate: implications on epithelial stem cells](#). *Cell*. 1989; 57:201-9.
9. Stoiber J, Muss WH, Pohla-Gubo G, Ruckhofer J, Grabner G. [Histopathology of human corneas after amniotic membrane and limbal stem cell transplantation for severe chemical burn](#). *Cornea*. 2002; 21:482-9.
10. Ucakhan OO, Koklu G, Firat E. [Nonpreserved human amniotic membrane transplantation in acute and chronic chemical eye injuries](#). *Cornea*. 2002; 21:169-72.
11. Kheirkhah A, Raju VK, Tseng SC. [Minimal conjunctival limbal autograft for total limbal stem cell deficiency](#). *Cornea*. 2008; 27:730-3.
12. Nishiwaki-Dantas MC, Dantas PE, Reggi JR. [Ipsilateral limbal translocation for treatment of partial limbal deficiency secondary to ocular alkali burn](#). *Br J Ophthalmol*. 2001; 85:1031-3.
13. Kenyon KR, Tseng SC. Limbal autograft transplantation for ocular surface disorders. *Ophthalmology*. 1989; 96:709-22; discussion: 722-3.
14. Merle H, Donnio A, Ayebooua L, Michel F, Thomas F, Ketterle J, et al. Alkali ocular burns in Martinique (French West Indies) evaluation of the use of an amphoteric solution as the rinsing product. *Burns*. 2005; 31:205-11.