

Brief communication (Original)

Outcomes of hepatic resection for hepatocellular carcinoma with major portal or hepatic vein tumor thrombosis: retrospective cohort study

Wipusit Taesombat, Boonchoo Sirichindakul, Bunthoon Nonthasoot, Jade Suphapol, Methee Sutherasan, Supanit Nivatvongs

Department of Surgery, Faculty of Medicine, King Chulalongkorn Memorial Hospital, Chulalongkorn University, Bangkok 10330, Thailand

Background: Major vascular invasion by hepatocellular carcinoma (HCC) is a poor prognostic factor. The outcome of hepatic resection for this advanced stage tumor remains unclear.

Objectives: To clarify the outcome of hepatic resection for HCC with vascular invasion.

Methods: Between January 2005 and May 2013, 13 of 272 patients who underwent hepatic resection of HCC had a confirmed major portal or hepatic vein tumor thrombosis. The perioperative and long-term outcomes of this cohort of patients were retrospectively reviewed.

Results: Ten of the 13 patients underwent preoperative transarterial chemoembolization (TACE). None showed tumor progression or liver function deterioration. All underwent hepatic resection with complete removal of tumor thrombus. The vascular resection margin was microscopically negative in all patients. Postoperative complications occurred in 62%. Most complications were pleural effusion, which necessitates percutaneous drainage. No perioperative mortality occurred. The median follow up time was 38.5 months (range 10–112). The median overall survival was 38.5 months. The 1-, 3-, and 5-year recurrence free survival was 93%, 36%, and 36%, respectively. The 1-, 3-, and 5 year-overall survival was 93%, 76%, and 48%, respectively. Nine patients had intrahepatic tumor recurrence, extrahepatic recurrence, or both. Five with recurrence underwent TACE, radiofrequency ablation, or surgical resection. On univariate analysis, the only factor that tended to relate to worse overall survival was underlying liver cirrhosis ($P = 0.056$).

Conclusions: Hepatic resection for HCC with invasive thrombosis, combined with careful patient selection, close postoperative follow up, and early treatment of recurrence offers a chance of long-term survival.

Keywords: Hepatocellular carcinoma, preoperative TACE, surgical resection, survival outcomes, tumor thrombus

Hepatocellular carcinoma (HCC) is one of the most common cancers and a leading cause of cancer-related death worldwide [1]. Evidence of invasion of a major vessel, such as a portal or hepatic vein tumor thrombus is poor prognostic factor for patient survival [2-4]. Untreated patients with HCC who have portal vein tumor thrombus have short median survival, reported to be 2.7 months [5].

The optimal treatment for this advanced staged HCC is controversial. The only treatment option that offers a chance of prolonged survival in selected patients is complete hepatic resection [6-8].

The objective of this study was to clarify the outcomes of complete surgical resection for HCC with

a major portal vein or hepatic vein tumor thrombus in selected patients with this advanced staged HCC.

Methods

The present retrospective cohort study was approved by the Institutional Review Board (IRB) of the Faculty of Medicine, Chulalongkorn University (certificate of approval No. 252/2015, IRB No. 608/57). After approval, we reviewed the medical records of patients who underwent liver resection for HCC between January 2005 and May 2013 at King Chulalongkorn Memorial Hospital, Bangkok, Thailand. Only data from patients who had a pathologically confirmed hepatocellular carcinoma-tumor thrombus in a major portal vein or hepatic vein were eligible for inclusion in the study.

Baseline history and physical examination were noted. Preoperative laboratory testing included

Correspondence to: Wipusit Taesombat, Department of Surgery, Faculty of Medicine, King Chulalongkorn Memorial Hospital, Bangkok 10330, Thailand. E-mail: wipusit.t@chula.ac.th

complete blood count, blood urea nitrogen, serum creatinine, liver function test, prothrombin time, partial thromboplastin time, and liver imaging (triple phase computed tomography (CT) or magnetic resonance imaging (MRI) of the abdomen) and chest radiography. Patients with a hepatic vein tumor thrombus or with suspected lesions on chest radiographs had undergone CT of the chest. Liver function reserve was assessed using Child–Pugh scores, platelet counts, and evidence of significant portal hypertension. Residual liver volume was calculated by CT volumetry.

Preoperative transarterial chemoembolization (TACE) was performed using conventional lipiodol embolization in selected patients with borderline liver function preservation or as a bridging treatment before surgery.

All patients whose data were included had undergone hepatic resection. Anatomical hepatic resection had been performed according to the extent and location of tumor under limited liver mobilization. Pringle's maneuver had been used intermittently during the parenchymal transection.

Tumor thrombi in a portal or hepatic vein had been removed according to the extent and location of the thrombi. If a tumor thrombus had been located within the resection line, it was removed together with the hepatic parenchymal transection. Where a tumor thrombus had extended beyond the hepatic parenchymal transection line, such as extension to the main portal vein or inferior vena cava, it had been removed from the opened stump of the vein. Vascular resection had not been necessary in any patient.

All patients had been followed up postoperatively with serum α -fetoprotein (AFP) measurements and CT or MRI of the abdomen every 2–3 months. Chest radiography or CT of the chest had been performed in selected patients.

Stata, version 13 (StataCorp, College Station, TX, USA) was used for all statistical analyses. Patient and tumor characteristics are described as mean (standard deviation, SD). Actuarial survival was calculated by using the Kaplan–Meier method. Univariate analysis to identify prognostic factors related to recurrence free and overall survival outcomes was conducted by using Cox proportional hazards models. $P < 0.05$ was considered significant.

Results

During the period examined, 13 (4.8%) of 272 patients who underwent hepatic resection for HCC had a pathologically confirmed tumor thrombus in a major portal vein or hepatic vein.

Patient and tumor characteristics

The baseline patients and tumor characteristics are shown in **Table 1**. The majority of patients had hepatitis B-related liver disease and had a tumor thrombus in the first branch of a portal vein (right or left portal vein). All patients had Child–Pugh class A reserve function and high serum AFP levels. All patients had a pathologically proven tumor thrombus and 8 had pathologically proven liver cirrhosis.

Table 1. Patient and tumor characteristics

Characteristic	n (%) or mean (standard deviation)
Age (years)	51.4 (9.5)
Male sex	12 (92)
Underlying liver disease	
Hepatitis B virus (HBV)	7 (54)
HBV and hepatitis C virus (HCV)HBV	2 (15)
and hepatitis C infection (HCV)	4 (31)
Non-HBV/HCV	
Tumor diameter (cm)	11.2 (5.9)
Child–Pugh A	13 (100)
α -Fetoprotein at diagnosis (IU/mL)	13615 (41129)
Tumor thrombus location	
2 nd branch portal vein (PV)	3 (23)
1 st branch PV (right or left PV)	4 (31)
Main PV	3 (23)
Hepatic vein/inferior vena cava	3 (23)

Ten patients (77%) underwent preoperative TACE. The median number of TACE sessions was 2 (range 1-4). None of these patients had tumor progression or liver function deterioration after TACE.

Surgical outcomes and prognostic factors

Anatomical hepatic resections for HCC including tumor thrombectomy had been performed in 13 patients. Eleven (85%) underwent major hepatic resection (≥ 3 Couinaud segments). The perioperative outcomes are shown in **Table 2**. Postoperative complications were occurred in 62%. The most common complication was pleural effusion, which necessitated percutaneous drainage. No perioperative death occurred. Ten patients had complete microscopic surgical resection (R0). Three patients had microscopically positive resection margins at hepatic parenchymal cut surface, but not at vascular resection margins.

All patients had complete postoperative follow up. The median follow up time was 38.5 months (range

10-112 months). The median overall survival was 38.5 months. The 1-, 3-, and 5 year-overall survival was 93%, 76% and 48%, respectively (**Figure 1**). The median recurrence free survival was 16 months. The 1-, 3-, and 5-year recurrence free survival was 93%, 36%, and 36%, respectively (**Figure 2**). Nine patients had tumor recurrence, 2 had intrahepatic recurrences, 4 had extrahepatic recurrences, and 3 had intra- and extrahepatic recurrences. For patients with isolated hepatic or extrahepatic recurrence, particularly lung metastases, we performed surgical resection.

Univariate Cox proportional hazards model analysis was conducted to determine prognostic factors related to recurrence free and overall survival (**Table 3**). The only factor that tended to be related to worse overall survival was underlying liver cirrhosis. However, this relationship was not quite significant ($P = 0.056$).

Table 2. Perioperative outcomes

	n (%) or mean (standard deviation)
Operative procedure	
Posterior sectionectomy	2 (15)
Right/left hepatectomy	10 (77)
Right trisectionectomy	1 (8)
Operative time (min)	323 (122.9)
Estimated blood loss (mL)	1439 (1372.7)
Length of stay (days)	14 (5.7)
Complications	
Wound infection	2
Pleural effusion	5
Intraabdominal collection	1
Bile leakage	1
Pathological results	
Resection margins	
R0 (free margins)	10 (77)
R1 (microscopically positive)	3 (23)
Tumor differentiation	
Moderate	5 (39)
Poor	8 (62)
Satellite nodule positive	3 (23)

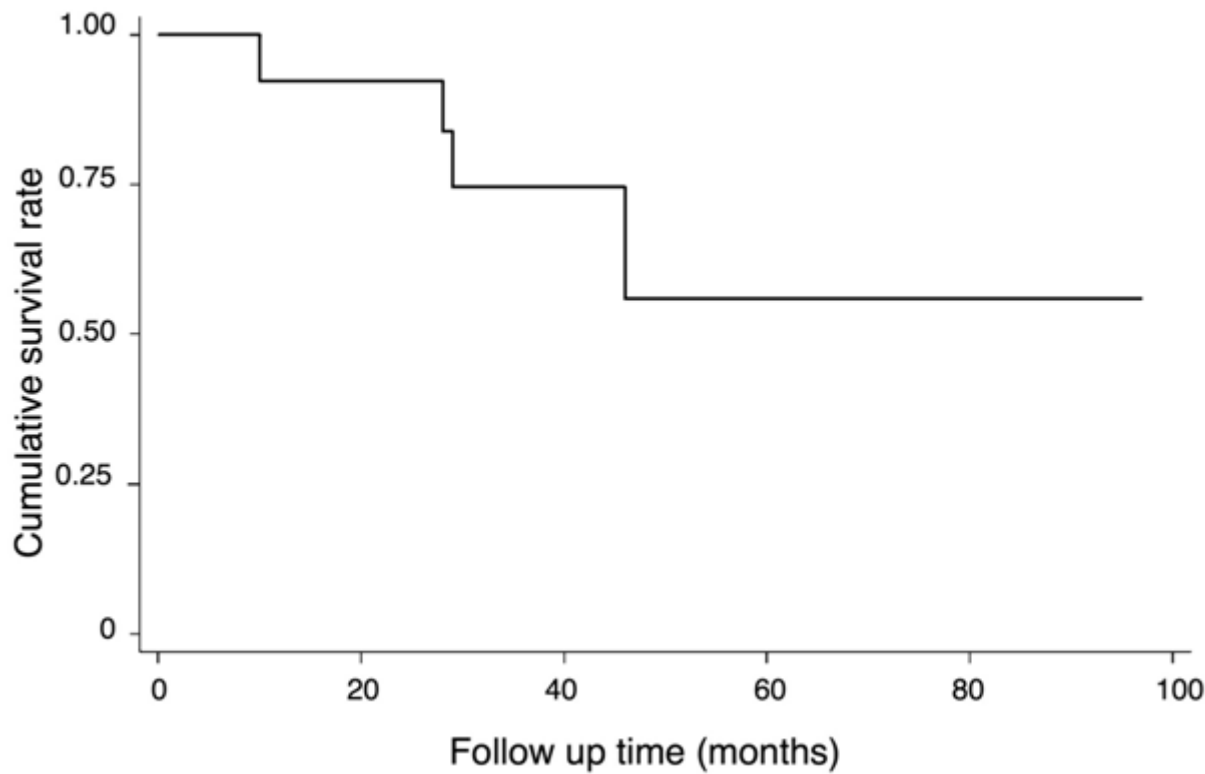


Figure 1. Overall survival after hepatic resection with tumor thrombectomy

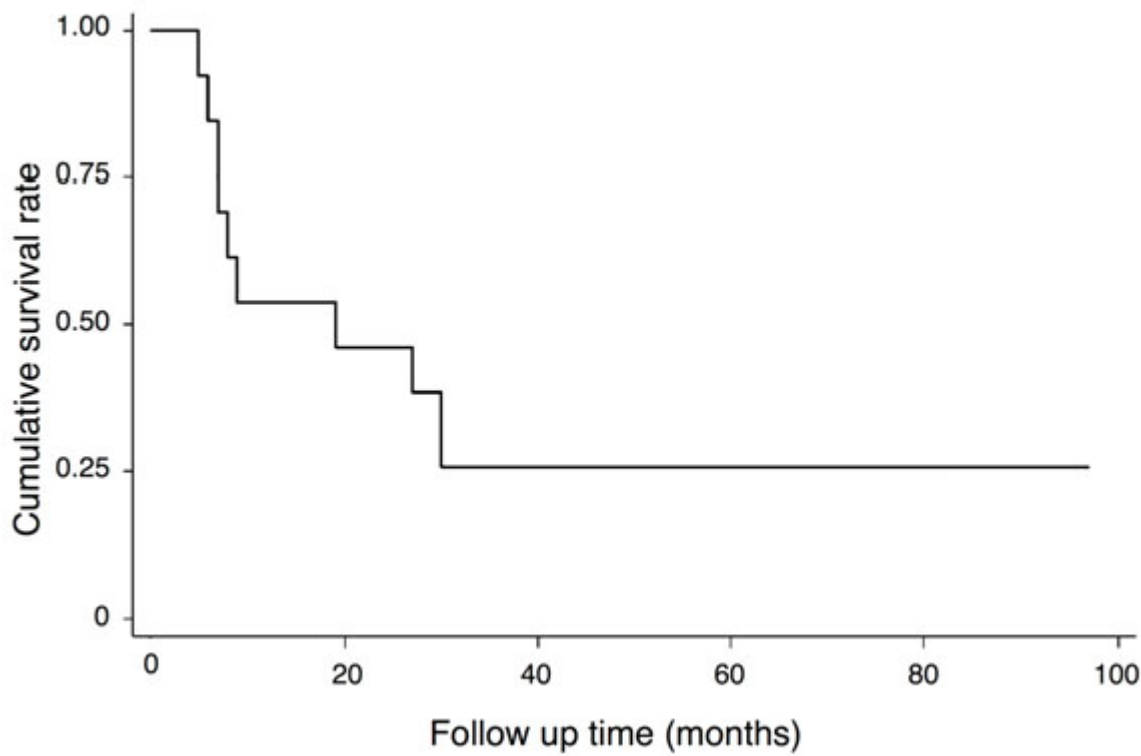


Figure 2. Recurrence-free survival after hepatic resection with tumor thrombectomy

Table 3. Univariate Cox proportional hazards model analysis to identify prognostic factors related to recurrence free and overall survival

Recurrence free survival HR (95% CI), <i>P</i>	Overall survival HR (95% CI), <i>P</i>	Prognostic factor
0.81 (0.20 to 3.25), 0.76	0.70 (0.09 to 5.09), 0.72	Tumor size ≥10 cm
2.07 (0.41 to 10.45), 0.37	3.54 (0.50 to 25.28), 0.21	R0, tumor free resection margin
2.80 (0.56 to 14.02), 0.18	^a 0.056	Liver cirrhosis
3.62 (0.44 to 30.04), 0.20	^b 0.24	Preop transarterial chemoembolization

HR, hazard ratio; CI, confidence interval

P < 0.05 considered significant

^a*P*, no death of patients without cirrhosis during follow up

^b*P*, no death of patients without preoperative transarterial chemoembolization during follow up

Discussion

Hepatocellular carcinoma with major vascular invasion is associated with a poor prognosis [2]. Hepatic resection has remained the mainstay of treatment that offers a better chance of survival than alternative treatments [7, 8]. The present study showed a favorable 5-year overall survival of 48%. Other studies have found a 5-year overall survival of 20%-31.3% [8-10]. However, in general, the survival outcomes of hepatic resection for this advanced staged HCC are improving. Other treatment options for this group of patients, such as TACE alone or sorafenib had worse survival outcomes than hepatic resection [8, 11, 12].

Preoperative TACE was not associated with better overall survival in resectable hepatocellular carcinoma [13, 14]. However, preoperative TACE was a safe and efficacious procedure with high rates of pathological response [13]. The role of preoperative TACE for treatment of hepatocellular carcinoma with tumor thrombus remains controversial. In the present study, 10 patients had received preoperative TACE, and none of them had tumor progression. However, the present study did not show any benefits of preoperative TACE in terms of improved prognosis for survival outcomes. A possible benefit of preoperative TACE was the better selection of patients with questionable liver function reserve for surgery. Liver function markedly deteriorates after TACE in patients with borderline liver function reserve. These patients may not be good candidate for hepatic resection. No patients in the present study had deteriorated liver function after TACE, and so

had undergone hepatic resection as planned without postoperative liver failure.

Patients whose data were included in the present study only underwent tumor thrombectomy, and the resection of vessels was not attempted, except where the vessel wall was obviously invaded by the tumor. In the present study, 3 patients had a microscopically positive resection margin at the hepatic parenchymal cut surface, but not a major vascular resection margin. Two patients underwent postoperative radiation therapy. Survival outcomes of patients with a free resection margin (R0) were not significantly different to those in patients with a positive resection margin (R1). However, the reliability of this outcome is limited by the availability of data from only a small number of patients.

Postoperative surveillance is important for the early detection of either intrahepatic or extrahepatic tumor recurrence. Liver CT or MRI and serum AFP tests were performed every 2–3 months especially during the first 2 postoperative years. Seven of 9 patients with tumor recurrence underwent various treatments according to site and number of tumor recurrences, liver function reservation, and performance status of patients. Treatment options included surgical resection, ablation, TACE, and systemic treatment. We recommend considering early aggressive treatment of tumor recurrence in all patients.

The main limitations of this study were the availability of data from only a small number of patients and possible some selection bias of patients with favorable risk and well-preserved liver function. Nevertheless, in the selected patients, the present

study shows favorable long-term survival outcomes for complete surgical resection of hepatocellular carcinoma with tumor thrombus.

Conclusion

Hepatic resection and complete tumor thrombectomy in patients with advanced-stage hepatocellular carcinoma, combined with careful preoperative patient selection, close postoperative follow up, and early treatment of the recurrent tumor may offer a chance of long-term survival for some patients.

Acknowledgement

We thank Dr. Piyawan Kittiskulnam for statistical consultation and analysis. This study was presented at the 11th World Congress of the International Hepato-Pancreato-Biliary Association, March 22–27, 2014, Seoul, Korea. Poster PPL24-081. Taesombat W, Sirichindakul B, Nonthasoot B, Suphapol J, Niwatwongs S. Favorable outcomes of complete surgical resection for hepatocellular carcinoma with major portal vein or hepatic vein tumor thrombus. HPB 2014; 16 (Suppl. 2): 435.

Conflict of interest statement

All authors in this study declared that they do not have anything to disclose regarding funding or conflict of interest with respect to this manuscript.

References

1. Bosch FX, Ribes J, Cleries R, Diaz M. Epidemiology of hepatocellular carcinoma. *Clin Liver Dis.* 2005; 9: 191-211.
2. Vauthey JN, Lauwers GY, Esnaola NF, Do KA, Belghiti J, Mirza N, et al. Simplified staging for hepatocellular carcinoma. *J Clin Oncol.* 2002; 20:1527-36.
3. Kokudo T, Hasegawa K, Yamamoto S, Shindoh J, Takemura N, Aoki T, et al. Surgical treatment of hepatocellular carcinoma associated with hepatic vein tumor thrombosis. *J Hepatol.* 2014; 61:583-88.
4. Pawarode A, Voravud N, Sriuranpong V, Kullavanijaya P, Patt YZ. Natural history of untreated primary hepatocellular carcinoma: a retrospective study of 157 patients. *Am J Clin Oncol.* 1998; 21:386-91.
5. Llovet JM, Bustamante J, Castells A, Vilana R, Ayuso MC, Sala M, et al. Natural history of untreated nonsurgical hepatocellular carcinoma: rationale for the design and evaluation of therapeutic trials. *Hepatology.* 1999; 29:62-7.
6. Shi J, Lai CH, Li N, Guo WX, Xue J, Lau WY, et al. Surgical treatment of hepatocellular carcinoma with portal vein tumor thrombus. *Ann Surg Oncol.* 2010; 17:2073-80.
7. Pawlik TM, Poon RT, Abdalla EK, Ikai I, Nagorney DM, Belghiti J, et al. Hepatectomy for hepatocellular carcinoma with major portal or hepatic vein invasion: Results of a multicenter study. *Surgery.* 2005; 137: 403-10.
8. Yoshidome H, Takeuchi D, Kimura F, Shimizu H, Ohtsuka M, Kato A, et al. Treatment strategy for hepatocellular carcinoma with major portal vein or inferior vena cava invasion: a single institution experience. *J Am Coll Surg.* 2011; 212:796-803.
9. Liu W, Wang K, Bao Q, Sun Y, Xing BC. Hepatic resection provided long-term survival for patients with intermediate and advanced-stage resectable hepatocellular carcinoma. *World J Surg Oncol.* 2016; 14:62.
10. Yamamoto Y, Ikoma H, Shoda K, Konishi H, Murayama Y, Komatsu S, et al. Post-hepatectomy survival in advanced hepatocellular carcinoma with portal vein tumor thrombosis. *World J Gastroenterol.* 2015; 21: 246-5.
11. Ye JZ, Zhang YQ, Ye HH, Bai T, Ma L, Xiang BD, et al. Appropriate treatment strategies improve survival of hepatocellular carcinoma patients with portal vein tumor thrombus. *World J Gastroenterol.* 2014; 20: 17141-7.
12. Lee JM, Jang BK, Lee YJ, Choi WY, Choi SM, Chung WJ, et al. Survival outcomes of hepatic resection compared with transarterial chemoembolization or sorafenib for hepatocellular carcinoma with portal vein tumor thrombosis. *Clin Mol Hepatol.* 2016; 22: 160-7.
13. Chua TC, Liauw W, Saxena A, Chu F, Glenn D, Chai A, et al. Systematic review of neoadjuvant transarterial chemoembolization for resectable hepatocellular carcinoma. *Liver Int.* 2010; 30:166-74.
14. Shi HY, Wang SN, Wang SC, Chuang SC, Chen CM, Lee KT. Preoperative transarterial chemoembolization and resection for hepatocellular carcinoma: a nationwide Taiwan database analysis of long-term outcome predictors. *J Surg Oncol.* 2014; 109:487-93.